

Measles–rubella vaccine–associated MOG-antibody positive acute demyelinating encephalomyelitis with optic neuritis in a child

Madhumati Otiv, Abhijeet Botre  and Pawan Shah

Ther Adv Vaccines Immunother

2022, Vol. 10: 1–3

DOI: 10.1177/
25151355221115016

© The Author(s), 2022.
Article reuse guidelines:
sagepub.com/journals-
permissions

Abstract: Measles–rubella (MR) vaccine–associated encephalopathy is rare and coexistence with optic neuritis (ON) has never been reported. Only two patients (one child and one adult) had ‘MR Vaccine–associated myelin-oligodendrocyte-glycoprotein antibody (MOGAb) positive encephalopathy’. Myelin oligodendrocyte glycoprotein (MOG), a surface myelin protein, is the target of the immune system in this disease. We describe a critical unique case of ‘post-MR Vaccine, MOG-antibody positive Acute Disseminated Encephalo-Myelitis (ADEM) with optic neuritis’, who recovered with immunotherapy.

Keywords: ADEM, measles–rubella vaccine, methylprednisolone, MOG antibodies, optic neuritis

Received: 30 March 2022; revised manuscript accepted: 6 July 2022.

Introduction

A well-grown, normally developed, 11-year-old girl received a scheduled MR vaccine. After 2 days, she developed high-grade fever, followed by headache, drowsiness, irrelevant talk, urine retention, and generalized seizure over a span of 12 days. Her past history was insignificant. Suspecting infectious etiology, she received ceftriaxone, amikacin, and intravenous (IV) fluids. Her sensorium deteriorated, however; hence referred to tertiary care hospital.

She had fever, heart rate (HR) 120/min, respiratory rate (RR) 25/min regular, capillary refill time (CRT) 2s, blood pressure (BP) 110/70, and SpO₂ 100% in room air. Other than central nervous system (CNS), all other systems were found to be normal. She was disoriented with low Glasgow Coma Scale (GCS) (10/15) and positive meningeal signs. Her pupils, fundus, and cranial nerves examination was normal. Lower limbs had paucity of movements with absent deep reflexes as compared with upper limbs, with loss of abdominal and plantar superficial reflexes. Fundus

examination was normal. Initial investigations showed hemoglobin (Hb) 12.6 gm, total leukocyte count (TLC) 27,750/cmm, neutrophil (N) 87%, lymphocyte (L) 10%, platelet 4.02l/cmm, normal renal function test (RFT), liver function test (LFT), electrolytes, and blood gas. *Rickettsia* and dengue serology were negative. Cerebrospinal fluid (CSF) showed 700 cells/cmm, L 70%, protein 156 mg/dl, and glucose 56 mg/dl [body sugar level (BSL) 104] with normal lactate. Serum ammonia and antinuclear antibody (ANA)/double stranded DNA (DsDNA) were normal. Electroencephalogram (EEG) showed background slowing without electrographic seizures. CSF polymerase chain reaction (PCR) panel [herpes, chickenpox, cytomegalovirus (CMV), Epstein–Barr virus (EBV), enterovirus, para-echo, mumps, and rubella], gram/Zn stain, bacterial antigen latex agglutination, and cultures were negative. Magnetic resonance imaging (MRI) brain with spine revealed leptomenigeal enhancement and non-specific white matter hyperintensities with normal spine. We continued empirical IV antibacterial, antiviral, and supportive care awaiting investigations.

Correspondence to:
Abhijeet Botre
Pediatric Neurologist, KEM
Hospital, Mudliyar Road,
Rasta Peth, Pune 411011,
Maharashtra, India.
drabhijeetbotre@gmail.com

Madhumati Otiv
KEM Hospital, Pune, India
Pawan Shah
Synergy Kids' Hospital,
Ahmedabad, India

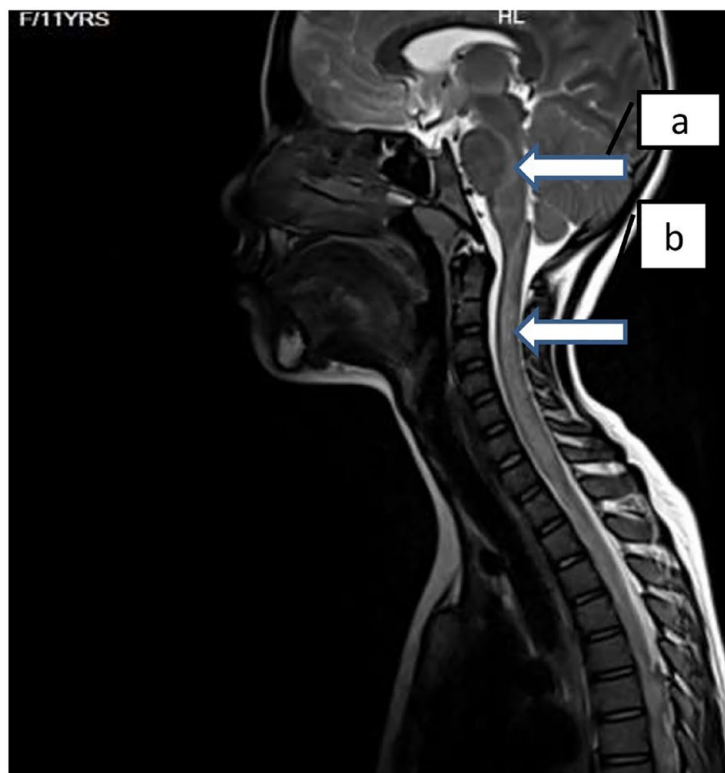


Figure 1. MRI brain spine (sagittal view T2) showing (a) brainstem and (b) cervical cord hyperintense signals.

Child worsened within 2 days, however; child had no vocalization, no eye opening, and no motor response needing mechanical ventilation. Repeat MRI surprisingly showed diffuse non-enhancing hyperintensity in entire spinal cord and brain stem without any signal in optic nerves (Figure 1). Repeat CSF showed 30 cells/cmm, L 95%, proteins 44 mg/dl, and glucose 60 mg/dl. Demyelination panel revealed high immunoglobulin G (IgG) and positive anti-MOG and negative neuromyelitis optica (NMO) antibodies; for which we administered IV immunoglobulin and IV methylprednisolone. Her sensorium, walking, and bladder control improved over 10 days, 4 weeks, and 6 weeks, respectively. She was discharged on oral steroids.

A fortnight later, steroids were unintentionally stopped by parents, and she came back with complete visual loss. She was only perceiving hand movements and could not count fingers from 1 feet distance. Her clinical evaluation showed normal sized sluggishly reacting pupils without relative afferent papillary defect (RAPD). Visual evoked potential (VEP) was delayed with fundus

examination showed papillitis confirming bilateral optic neuritis (ON) without other neuro-deficit. We escalated immunotherapy to rituximab, continued steroids for 6 months with slow tapering. During last 3 years follow-up, she is asymptomatic, with intact intelligence and vision with no neuro-deficit or seizure. Written and informed consent of the parents have been taken.

Discussion

This is a case of MR vaccine-associated MOGAb positive ADEM who developed ON upon initial steroid tapering, recovered after subsequent prolonged therapy of steroids and rituximab. Only other child reported is a 6-year-old Japanese boy who had MR and Japanese encephalitis (JE) vaccine-associated MOGAb positive encephalopathy without ON. This child worsened during tapering of steroids like our child and needed prolonged therapy.¹ Two other adult patients had vaccine [diphtheria, pertussis, and tetanus (DPT) + influenza + Polio] triggered MOGAb positive encephalopathy,² who needed prolonged immunotherapy too. It thus appears MOGAb positive patients, triggered by any vaccine may need prolonged therapy, slower tapering, and to watch for relapse.² Complete or partial recovery from most vaccine-associated encephalopathies is 45.8% and 90.3%, respectively, and the outcome was unknown in 7%.³ Ryu *et al.*⁴ described similar case of 6-year-old girl with post-measles, mumps, and rubella (MMR) vaccine ADEM treated with IV methyl prednisolone only for 3 days who presented with right ON (CSF oligoclonal band and NMO negative) within 3 weeks. She completely recovered with 7 days with 6 months follow-up. While our case received intravenous immunoglobulin (IVIG) and steroid for 4 weeks in view of stormy clinical course and MOG positivity in first admission itself. Bilateral ON appeared 15 days after stoppage of steroids. Considering aggressive course of disease and relapsing nature of MOG-related demyelination, the third-line immunotherapy (injection rituximab) was instituted.²

Many vaccines are associated with neuromyelitis optica spectrum disorder (NMOSD), ADEM, ON, and transverse myelopathy,³ but rarely MR vaccine.^{1-3,5} Pathogenesis of this disease seems immunologically mediated, namely, molecular mimicry (viral or vaccine antigen and MOG); local activation of antigen presenting cells and overprocessing of antigens; infectious agents,

induction of autoimmunity *via* polyclonal activation of B lymphocytes or bystander activation which enhances cytokine production and further induces the expansion of autoreactive T-cells.² Some cases are aquaporin-4 or MOGAb positive, which are likely to have multiphasic illness needing a close follow-up.

Infectious etiology is the commonest treatable cause of encephalopathy, and usually treated empirically with antibiotics, antivirals awaiting specific investigations as per local epidemiological evidence. Possibility of immune-mediated CNS disease must be considered if there is recent exposure to infection or vaccine, MRI brain favoring diffuse cortical-subcortical or patterned findings,² motor signs with CSF pleocytosis,² and exclusion of infectious etiology. Early identification of antibody-mediated autoimmune disorders is paramount for good outcomes. Commonest immunotherapy used is steroids followed by IVIG, plasma exchange, rituximab, or a combination.^{2,3}

Conclusion

Serious adverse events are a liability for the vaccine program. Early referral to a designated tertiary care center in the event of a Serious Adverse Event needs to be inbuilt of the program. Our case indicates that critical care support and rapid evaluation can enable appropriate immunotherapy as most such events may be immune-mediated. Timely detection of antibodies like MOG and NMO should be advocated to diagnose and treat these rare disorders post-vaccination. Prolonged therapy with a close follow-up can lead to complete recovery, and premature termination can be detrimental.

Declarations

Ethics approval and consent to participate

Not applicable.

Consent for publication

Written and informed consent of the parents have been taken.

Author contributions

Madhumati Otiv: Conceptualization; Data curation; Formal analysis; Methodology; Supervision; Visualization; Writing – original draft; Writing – review & editing.

Abhijeet Botre: Conceptualization; Data curation; Formal analysis; Methodology; Supervision; Visualization; Writing – original draft; Writing – review & editing.

Pawan Shah: Conceptualization; Data curation; Methodology; Visualization; Writing – original draft; Writing – review & editing.

Acknowledgements

None.

Funding

The authors received no financial support for the research, authorship, and/or publication of this article.

Competing interests

The authors declared no potential conflicts of interest with respect to the research, authorship, and/or publication of this article.

Availability of data and materials

Not applicable.

ORCID iD

Abhijeet Botre  <https://orcid.org/0000-0002-8536-6153>

References

1. Azumagawa K, Nomura S, Shigeri Y, *et al.* Post-vaccination MDEM associated with MOG antibody in a subclinical Chlamydia infected boy. *Brain Dev* 2016; 38: 690–693.
2. Jarius S, Ruprecht K, Kleiter I, *et al.* MOG-IgG in NMO and related disorders: a multicenter study of 50 patients. Part 2: epidemiology, clinical presentation, radiological and laboratory features, treatment responses, and long-term outcome. *J Neuroinflammation* 2016; 13: 280.
3. Kumar N, Graven K, Joseph NI, *et al.* Postvaccination anti-myelin oligodendrocyte glycoprotein neuromyelitis optica spectrum disorder: a case report and literature review of postvaccination demyelination. *Int J MS Care* 2020; 22: 85–90.
4. Ryu WY, Sohn EJ, Kwon YH, *et al.* Acute disseminated encephalomyelitis without optic neuritis followed by optic neuritis in a child due to the sudden cessation of steroid therapy. *Semin Ophthalmol* 2014; 29: 18–21.
5. Moradian S and Ahmadi H. Early onset optic neuritis following measles–rubella vaccination. *J Ophthalmic Vis Res* 2008; 3: 118–122.