

Cutaneous Small-vessel Vasculitis after ChAdOx1 COVID-19 Vaccination: A Report of Five Cases

The International Journal of Lower Extremity Wounds
2022, Vol. 21(2) 193–196
© The Author(s) 2022
Article reuse guidelines:
sagepub.com/journals-permissions
DOI: 10.1177/15347346221078734
journals.sagepub.com/home/ijl



Ji An Uh, MD¹ , Soo Kyung Lee, MD¹, Joong Ho Kim, MD¹, Jae Ho Lee, MD¹, Myoung Shin Kim, MD¹, and Un Ha Lee, MD¹

Abstract

Amidst the Coronavirus Disease 2019 (COVID-19) pandemic, vaccination against severe acute respiratory syndrome 2 (SARS-CoV-2) is recommended for everyone over 18 years in South Korea, with the exception of pregnant women. Unexpected adverse cutaneous reactions after the COVID-19 vaccination have been recently reported. Cutaneous small-vessel vasculitis (CSVV) predominantly affects small blood vessels, defined as small intraparenchymal arteries, arterioles, capillaries, and venules, without any detectable involvement of non-cutaneous organs. We report five cases of CSVV after the ChAdOx1 COVID-19 vaccination in 44- to 68-year-old women. The symptoms commonly appeared within 2 days after vaccination. The lesion was localized to the lower limbs in four patients and spread to the upper limbs in one patient. All patients demonstrated a favorable response to oral methylprednisolone, antihistamines, and topical steroids. Considering the importance of the COVID-19 vaccination, clinicians should be aware of CSVV as a potential adverse event. Further studies are required to elucidate the causative link and pathogenesis.

Keywords

autoimmunity, ChAdOx1 COVID-19 vaccine, COVID-19, vasculitis

Amidst the Coronavirus Disease 2019 (COVID-19) pandemic, vaccination against severe acute respiratory syndrome 2 (SARS-CoV-2) is recommended for everyone over 18 years of age in South Korea, except pregnant women. Unexpected adverse cutaneous reactions after the COVID-19 vaccination have been reported. Cutaneous small-vessel vasculitis (CSVV) predominantly affects small blood vessels without any detectable involvement of the non-cutaneous organs. Vasculitis is primarily caused by infections, autoimmune diseases, and immunosuppressive treatment.¹ Although the exact causal relationship has not been elucidated, several vasculitis cases have been reported after various types of vaccination.¹ CSVV following COVID-19 vaccination have been reported; however, the causative link remains unclear.^{2–7} In this study, we report the clinical events in five cases of CSVV after the ChAdOx1 COVID-19 vaccination.

Case Reports

Case 1

A 64-year-old woman without any underlying disease presented with a three-day history of palpable purpuric papules on the lower limb that occurred one day after her first dose of the ChAdOx1 COVID-19 vaccine (Figure 1A, Table 1).

Her face was reportedly slightly swollen after the vaccination. Apart from occult blood in the urine, which resolved a month later, no other pathological findings were detected. Oral antihistamines and topical steroids were prescribed. After 2 weeks of follow-up, the lesion resolved.

Case 2

A 44-year-old woman without any underlying disease presented with a petechial lesion on the lower limb (Figure 1B–D, Table 1). Two days before the onset of symptoms, she received a second dose of the ChAdOx1 COVID-19 vaccine and reported no associated systemic symptoms. She reported a similar episode after her first dose. Apart from a slight decrease in her complement C3 levels, her blood and urine tests demonstrated no pathological findings of C4 complement, CH50, antinuclear antibody (ANA), anti-neutrophil cytoplasmic autoantibodies (ANCA), or cryoglobulins. Topical steroids were prescribed. After two weeks of

¹Inje University Sanggye Paik Hospital, Seoul, Republic of Korea

Corresponding Author:

Un Ha Lee, Department of Dermatology, Sanggye Paik Hospital, 1342, Dongil-ro, Nowon-Gu, Seoul 01757, Korea.
Email: dermalee@paik.ac.kr/woods75@hanmail.net

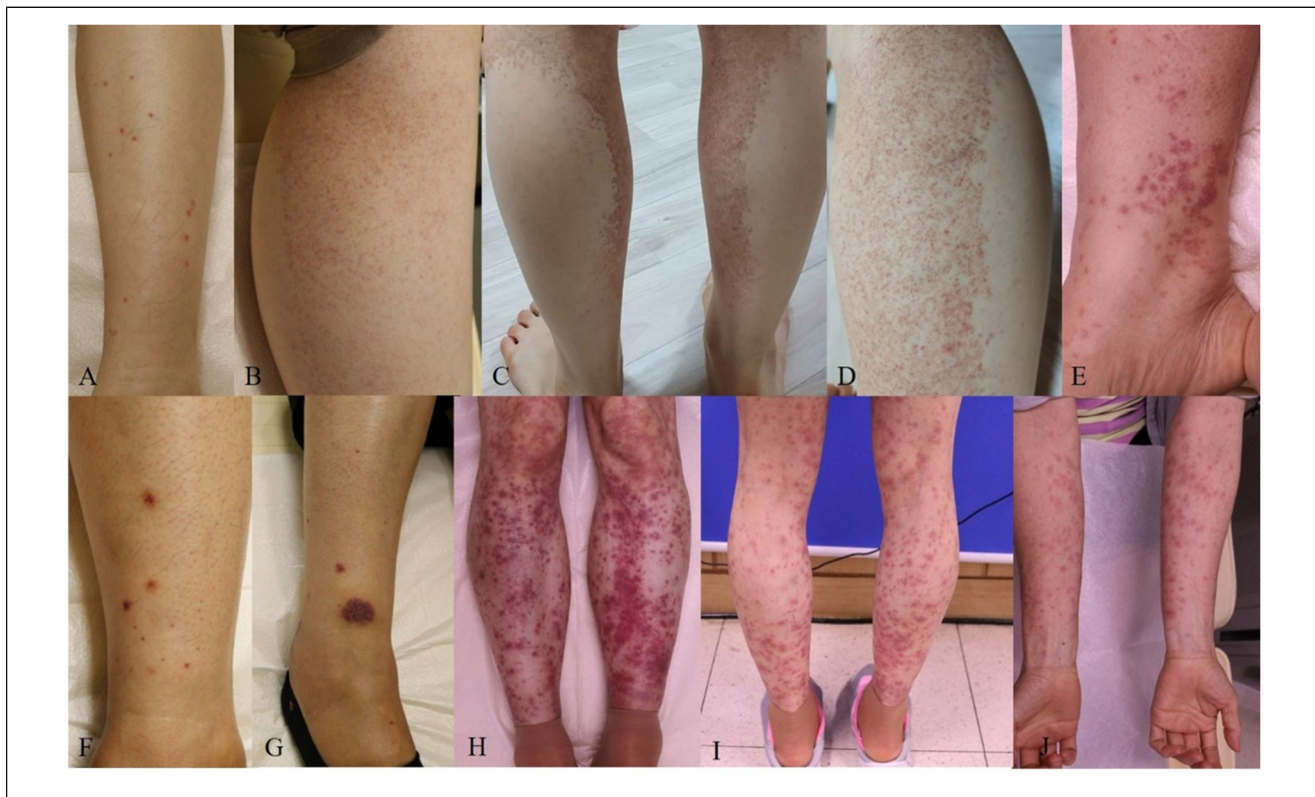


Figure 1. Clinical photographs. (A) Case 1. (B) Case 2. (C) and (D) Case 2: aggravation during follow-up. (E) Case 3. (F) and (G) Case 4. (H)–(J) Case 5.

Table 1. Summary of Five Cutaneous Vasculitis Cases Caused by Administration of the ChAdOx1 COVID-19 Vaccination.

Case no.	Sex	Age	PMHx	Duration (days)	Location	Additional features
1	F	64	(–)	1	Lower limbs	Swollen face Pruritus (+) Delayed large local reaction
2	F	44	(–)	2	Lower limbs	Similar episode at first dose of vaccination
3	F	68	Dyslipidemia	2	Lower limbs	Pruritus (+)
4	F	67	Hypertension	9	Lower limbs	Injection site pain Pain and erosion along the gingiva
5	F	59	Hypertension Dyslipidemia	20	Upper limbs Lower limbs	Pruritus (+)

Abbreviations: PMHx, past medical history; Duration, duration between vaccination and symptom onset.

follow-up, the skin lesion resolved with hyperpigmentation. However, two weeks later, she presented with an aggravated petechial lesion on the lower limb. Her laboratory tests revealed no other abnormalities. Oral methylprednisolone (8 mg/day) and antihistamines were prescribed for one week, after which the lesion resolved.

Case 3

A 68-year-old woman with a history of dyslipidaemia presented with a nine-day history of erythematous-to-purpuric

papules on the limbs, which occurred nine days after her first dose of the ChAdOx1 COVID-19 vaccine (Figure 1E, Table 1). She reported no other systemic symptoms. Blood tests demonstrated a slight increase in white blood cell count, blood urea nitrogen, C4 complement, and CH50 levels. No pathological findings were detected in her blood test for C3 complement, ANA, ANCA, or cryoglobulins, or her urine test. Oral methylprednisolone (12 mg/day for six days, then 8 mg/day for four days), antihistamines, and topical steroids were prescribed. After 10 days of follow-up, the lesion resolved with mild post-inflammatory hyperpigmentation.

Case 4

A 67-year-old woman with a history of hypertension presented with a 14-day history of violaceous indurated patches on the lower limb, which occurred 20 days after her first dose of the ChAdOx1 COVID-19 vaccine (Figure 1F and G, Table 1). She reported severe pain at the injection site on the day of vaccination, and pain and erosion along the gingiva. Histological examination revealed neutrophil-predominant perivascular infiltration and eosinophilic fibrinoid necrosis in the upper dermis, which was consistent with leukocytoclastic vasculitis. Blood tests identified a slight increase in the C4 complement and CH50 levels but did not detect C3 complement, ANA, ANCA, or cryoglobulins. Occult blood was found in her urine sample. Oral methylprednisolone 4 mg/day, pentoxifylline 800 mg/day, antihistamines, and topical steroids were prescribed. After two weeks, the lesion had nearly resolved.

Case 5

A 59-year-old woman with a history of hypertension and dyslipidaemia presented with a three-day history of erythematous-to-purpuric maculopapular rash on the limbs that occurred two days after her first dose of the ChAdOx1 COVID-19 vaccine (Figure 1H–J, Table 1). She reported no other systemic symptoms. The blood test demonstrated a slight increase in CRP and CH50 levels, and the urine test indicated the presence of occult

blood. No pathological C3/C4 complement, ANA, ANCA, or cryoglobulins were observed. Oral methylprednisolone 8 mg/day, antihistamines, and topical steroids were prescribed. After four days of follow-up, the lesion demonstrated partial resolution.

Discussion

CSVV is triggered by various primary autoimmune diseases, drugs, toxins, malignancies, and infections.¹ It predominantly affects small blood vessels without any detectable involvement of the non-cutaneous organs. Its clinical features include palpable purpura in gravity-dependent areas.⁸

Although vasculitis is not the primary cutaneous manifestation of COVID-19,⁹ a few authors have suggested that SARS-CoV-2 infection can cause vasculitis.¹⁰ *De novo* vasculitis and vasculitis flares after COVID-19 vaccination have been reported; however, the causative link remains unclear (Table 2).^{2–7,11} A systematic review reported the occurrence of vasculitis following various types of vaccinations such as influenza, hepatitis B, HPV, etc; however, a causative link between the vaccine and vasculitis was unclear.¹ Some authors have hypothesized that the SARS-CoV-2 infection and mRNA vaccines might induce autoimmunity.^{10,12} Vaccine-induced autoimmunity can be due to cross-reactivity between the vaccine product and the self-antigen.¹³

Table 2. Summary of Previous Reports of Cutaneous Vasculitis After COVID-19 Vaccination.^{2–7}

	No.	Sex	Age	PMHx	Duration (days)	Location	Additional features
AZ	1	F	57	Hypertension Hypothyroidism	1	Lower limbs	Fever Myalgia General malaise
Janssen	2	M	65	Hypertension Dyslipidemia *s/p AVR	7	Left arm Abdomen Lower limbs	Pruritus (+) Pain (+)
Pfizer	3	F	40	Hashimoto's thyroiditis	20	Gluteal lesion	Second dose *Hx of IUI
	4	F	42	Hypertension	4	Lower limbs	(–)
	5	F	46	LCV Psoriasis Psoriatic arthritis IBS	2	Upper limbs Lower limbs	Occurred with both the first dose and second dose
Moderna	6	F	78	IgA vasculitis LCV	7	Lower limbs	Hx of renal and gastrointestinal involvement
COVAXIN	7	F	31	(–)	4	Left leg	Second dose
Inactivated vaccine	8	M	33	(–)	3	Upper limbs Abdomen Lower limbs	Hx of SARS-CoV-2 infection (3 months ago)

Abbreviations: PMHx, past medical history; duration, duration between vaccination and symptom onset; AZ, AstraZeneca; s/p AVR, status post-aortic valve replacement; Hx of IUI, history of intrauterine insemination (14 days before manifestation); LCV, leukocytoclastic vasculitis; IBS, irritable bowel syndrome.

Here, all the patients were 44- to 68-year-old women. In a previous report, six out of eight cases were female aged between 22 and 78 years. This may be because cutaneous vasculitis generally has a slight female predominance,⁸ and the ChAdOx1 vaccine is recommended for people >50 years in South Korea. The period from the vaccination to the onset of symptoms varied from one day to 20 days, with symptom development taking one day in one patient, two days in three patients, and 20 days in one patient. Similarly, in a previous report, the time of symptom onset after the vaccination was between 1 to 20 days, and the symptoms in all but one case occurred within one week of vaccination. The lesion was localized to the lower limbs in four patients and spread to the upper limbs in one patient in this case series. In a previous report, the locations of the lesions in six out of eight cases were limited to the lower extremities, and two demonstrated an involvement of the upper extremities and abdominal skin. Three patients complained of mild pruritus, and two patients did not report any subjective symptoms in our study. Apart from the recent vaccination, no other factors were identified as triggers.

CSVV lesions are usually limited to the skin; therefore, they do not always require medical treatment. However, CSVV lesions result in hyperpigmentation, which may cause a cosmetic problem. All patients demonstrated a good response to oral methylprednisolone, antihistamines, and topical steroids.

Conclusions

Considering the importance of COVID-19 vaccination, clinicians should be aware of CSVV as a potential adverse event. Reports of vasculitis caused by the ChAdOx1 COVID-19 vaccine are few, and this scarcity may be related to the fact that mRNA vaccines are primarily used in developed countries with advanced medical care. Therefore, reporting new cases might help characterize vaccine security profiles. Further studies are required to elucidate the causative link and the pathogenesis.

Acknowledgments

None.

Declaration of Conflicting Interests

The author(s) declared no potential conflicts of interest with respect to the research, authorship, and/or publication of this article.


Funding

The author(s) received no financial support for the research, authorship and/or publication of this article.

Ethical Approval

Not applicable, because this article does not contain any studies with human or animal subjects.

ORCID iD

Ji An Uh  <https://orcid.org/0000-0002-4202-9843>

Supplemental Material

Supplemental material for this article is available online.

References

1. Bonetto C, Trotta F, Felicetti P, et al. Vasculitis as an adverse event following immunization—systematic literature review. *Vaccine*. 2016;34(51):6441-6451.
2. Erler A, Fiedler J, Koch A, Heldmann F, Schütz A. Clinical images: leukocytoclastic vasculitis after vaccination with a SARS-CoV-2 vaccine. *Arthritis & Rheumatology*, 2021;73(12): 2188-2188.
3. Hines AM, Murphy N, Mullin C, Barillas J, Barrientos JC. Henoch-Schönlein purpura presenting post COVID-19 vaccination. *Vaccine*. 2021;39(33):4571-4572.
4. Berry CT, Eliliwi M, Gallagher S, et al. Cutaneous small vessel vasculitis following single-dose Janssen Ad26.COV2.S vaccination. *JAAD Case Rep*. 2021;15:11-14.
5. Guzmán-Pérez L, Puerta-Peña M, Falkenhain-López D, et al. Small-vessel vasculitis following Oxford-AstraZeneca vaccination against SARS-CoV-2. *J Eur Acad Dermatol Venereol*. 2021;35(11):e741-e743. doi:10.1111/jdv.17547
6. Kharkar V, Vishwanath T, Mahajan S, Joshi R, Gole P. Asymmetrical cutaneous vasculitis following COVID-19 vaccination with unusual eosinophil preponderance. *Clin Exp Dermatol*. 2021;46(8):1596-1597. doi:10.1111/ced.14797
7. Bostan E, Gulseren D, Gokoz O. New-onset leukocytoclastic vasculitis after COVID-19 vaccine. *Int J Dermatol*. 2021;60-(10):1305-1306.
8. Martins-Martinho J, Dourado E, Khmelinskii N, Espinosa P, Ponte C. Localized forms of vasculitis. *Curr Rheumatol Rep*. 2021;23(7):49.
9. Freeman EE, McMahon DE, Lipoff JB, et al. The spectrum of COVID-19-associated dermatologic manifestations: an international registry of 716 patients from 31 countries. *J Am Acad Dermatol*. 2020;83(4):1118-1129.
10. Vojdani A, Kharratian D. Potential antigenic cross-reactivity between SARS-CoV-2 and human tissue with a possible link to an increase in autoimmune diseases. *Clin Immunol*. 2020;217:108480.
11. Cohen SR, Prussick L, Kahn JS, Gao DX, Radfar A, Rosmarin D. Leukocytoclastic vasculitis flare following the COVID-19 vaccine. *Int J Dermatol*. 2021;60(8):1032-1033.
12. Talotta R. Do COVID-19 RNA-based vaccines put at risk of immune-mediated diseases? In reply to “potential antigenic cross-reactivity between SARS-CoV-2 and human tissue with a possible link to an increase in autoimmune diseases”. *Clin Immunol*. 2021;224:108665.
13. Segal Y, Shoenfeld Y. Vaccine-induced autoimmunity: the role of molecular mimicry and immune crossreaction. *Cell Mol Immunol*. 2018;15(6):586-594.