



# Central Nervous System Involvement of Epstein Barr Virus Associated Lymphoproliferative Disorder in a Child with Acute Lymphoblastic Leukemia: Successful Treatment with Rituximab and Interferon-Alpha

## *Akut Lenfoblastik Lösemili bir Çocukta EBV İlişkili Lenfoproliferatif Hastalığın Santral Sinir Sistemi Tutulumu: Rituximab ve İnterferon Alfa ile Başarılı Tedavi*

Berna Atabay, Meral Türker, Can Öztürk, Sümer Sütçüoğlu, Haldun Öñiz, Esra Arun Özer

*Tepecik Training and Research Hospital, Department of Pediatrics Clinic, İzmir, Turkey*

### Abstract:

Central nervous system (CNS) involvement of Epstein-Barr virus (EBV)-associated lymphoproliferative disease is a rare and serious complication in children with leukemia. Although rituximab therapy seems to be promising in these cases, persistent hypogammaglobulinemia may appear after treatment due to complete depletion of normal B lymphocytes in the peripheral blood. Here we report isolated CNS involvement of EBV-associated lymphoproliferative disorder in a 4-year-old boy with acute leukemia. The patient was treated with rituximab and interferon alpha; however, persistent hypogammaglobulinemia developed as a complication. Given the rarity of the complication in children receiving these agents, our experience with such a case may be helpful to others.

**Keywords:** Epstein-Barr virus, Lymphoproliferative disorder, Rituximab, Children, Leukemia

### Özet:

Santral sinir sisteminin EBV ilişkili lenfoproliferatif hastalığı nadir bir durum olup, çocukluk çağı lösemilerinin ciddi bir komplikasyonudur. Bu olgularda rituximab tedavisi faydalı olmakla birlikte, periferik kanda normal B lenfositlerinin tam kaybı sonucunda persistan hipogamaglobulinemi ortaya çıkabilmektedir. Burada akut lösemili 4 yaşında bir erkek çocukta, EBV ilişkili lenfoproliferatif hastalığın izole santral sinir sistemi tutulumu sunulmaktadır. Hasta rituximab ve alfa interferon ile tedavi edilmiş, ancak komplikasyon olarak persistan hipogamaglobulinemi gelişmiştir. Bu ilaçları kullanan çocuklarda nadir görülen bir komplikasyon olması nedeniyle, bu olgu ile elde ettiğimiz deneyimin diğerlerine yardımcı olacağını düşünmekteyiz.

**Anahtar Sözcükler:** Epstein-Barr virus, Lenfoproliferatif hastalık, Rituximab, Çocuk, Lösemi

**Address for Correspondence:** Esra ARUN ÖZER, M.D.,

Tepecik Training and Research Hospital, Department of Pediatrics Clinic, İzmir, Turkey  
Phone: +90 232 469 69 69 E-mail: eozer@deu.edu.tr

Received/Geliş tarihi : December 21, 2011

Accepted/Kabul tarihi : May 21, 2012

## Introduction

Epstein-Barr virus (EBV)-associated lymphoproliferative disorder (LPD) is a severe and fatal complication of patients with immune deficiency [1]. The clinical picture of EBV-associated LPD is quite variable, and isolated central nervous system (CNS) involvement is rare. There are scanty data in the literature concerning the management of this disorder. Rituximab is a monoclonal antibody against CD20-positive B cells and is widely used in EBV-related lymphomas and diseases [2].

Here we report isolated CNS involvement of EBV-associated LPD in a 4-year-old boy with acute leukemia. The patient was treated with rituximab; however, hypogammaglobulinemia developed as a complication. Given the rarity of the complication in children receiving this agent, our experience with such a case may be helpful to others.

## Case Report

A 4-year-old boy was referred to our hospital in February 2007 for the treatment of biphenotypic acute leukemia. There was no family history of immunodeficiency, fatal infectious mononucleosis, or lymphomas. At the time of diagnosis he had no blasts in the cerebrospinal fluid (CSF) examination. The bone marrow aspirate confirmed the diagnosis of biphenotypic acute leukemia. His initial diagnostic flow cytometry results were: CD45, 72.5%; CD34, 71.8%; CD19, 77.9%; CD10, 72.5%; CD22, 69.4%; CD7, 15.8%; CD33, 72.7%; CD13, 76.3%; CD3, 13.3%; CD2, 18.8%; CD15, 4.7%; CD117, 4.1%; MPO, 10.3%; TdT, 42.7%; CD10+CD19, 71.6%. Cytogenetic analysis of his bone marrow was normal. His serum immunoglobulin levels were: IgA, 83 mg/dL (normal value: 14-159 mg/dL); IgM, 161 mg/dL (normal value: 43-207 mg/dL); and IgG, 1150 mg/dL (normal value: 345-1236 mg/dL). Lymphocyte subsets were not calculated initially. EBV serology was positive for viral capsid antigen (VCA) IgG, negative for VCA IgM, and consistent with a prior EBV infection. The patient was enrolled in a Berlin-Frankfurt-Munster-derived protocol [3]. Complete remission was attained after induction and was maintained with consolidation.

Maintenance therapy was initiated in October 2007, consisting of daily 6-mercaptopurine and weekly methotrexate administered orally on an outpatient basis. No cranial irradiation was administered. On the second month of maintenance therapy, the patient presented with a 3-day history of fever, malaise, and sore throat. Physical examination was unremarkable except for high fever (39 °C) and whitish tonsillar exudate. Maintenance therapy was ceased and systemic antibiotic therapy was administered. Three days after therapy, the patient was better and afebrile.

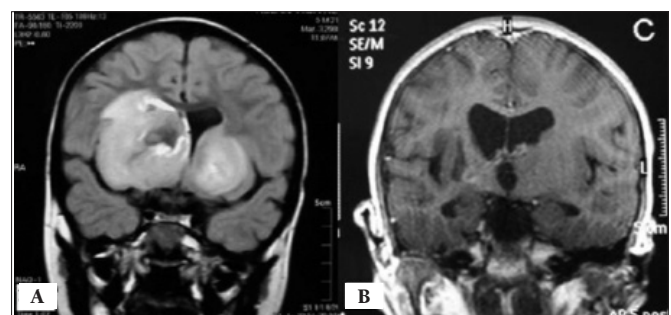
After 3 weeks, the patient presented with vomiting, diarrhea, and high fever (39 °C). Physical examination was normal. Laboratory tests showed hemoglobin of 9.4 g/dL, white blood cell count of  $2 \times 10^9/L$  with 43% segmented neutrophils, 3% bands (absolute neutrophil count of 860/ $\mu L$ ), 4% eosinophils, 16% monocytes, and 34% lymphocytes. Blood biochemical profile and chest X-ray were normal. The child was admitted to the hospital for antibiotic therapy.

On the 10<sup>th</sup> day of hospitalization, he presented with left hemiparesis and central facial paresis. Brain magnetic resonance imaging (MRI) revealed 2 masses located in the periventricular area (Figure 1A). Bone marrow aspirate and CSF examination were not suggestive of a leukemic relapse. Thorax and abdomen computerized tomography (CT) were unremarkable. Serum EBV VCA IgM and IgG were positive, whereas anti-Epstein-Barr nuclear antigen IgM and p22 antigen were negative. Human immunodeficiency virus and cytomegalovirus serology were also negative. Serum immunoglobulin levels were normal. The stereotactic brain biopsy showed an atypical lymphoid infiltrate composed predominantly of CD79a-positive B cells involving brain parenchyma with a prominent perivascular distribution. The infiltrate was negative for CD10, CD34, TdT, MPO, CD117, and lysozyme. The biopsy was positive for EBV-encoded small nonpolyadenylated RNAs by in situ hybridization test. The patient was diagnosed with localized EBV-associated LPD and administered weekly anti-CD20 monoclonal antibody (rituximab, 375 mg/m<sup>2</sup>) for 4 weeks and alpha-interferon 3 times per week ( $3 \times 10^6$  units/m<sup>2</sup>) for 6 months due to the infiltration of CD20-positive B cells. The therapy was well tolerated and the patient's neurologic condition did not show deterioration. After therapy serum immunoglobulin levels were low (IgG, 200 mg/dL; IgM, 8 mg/dL; and IgA, <6 mg/dL). The lymphocyte subset panel was normal (CD19, 12%; CD20, 18%; CD3, 76%; CD4, 28%; CD8, 4%; and CD16+56, 15%). The patient was administered monthly intravenous immunoglobulin at 0.5 g/kg to achieve at least 500 mg/dL IgG levels. After 2 months of therapy, the patient's neurological signs had disappeared. Cranial MRI showed complete resolution of the masses (Figure 1B).

For the subsequent 3 years of follow-up, the patient received no chemotherapy. The disease is in remission but intravenous immunoglobulin therapy is still given every 4 or 6 weeks because of IgG deficiency.

## Discussion

EBV-associated LPD is an uncommon and often fatal complication of patients with inherited or acquired immune deficiency [4]. Its clinical presentation is marked by serologic



**Figure 1:** **A)** MRI of the brain showing 2 huge masses in the periventricular area. Mild brain edema was seen around the lesion. **B)** MRI showed complete resolution of the masses after treatment.

evidence of active EBV proliferation, attributable either to a primary EBV infection or the reactivation of a latent infection. There are 10 cases of EBV-associated LPD in children with acute leukemia previously reported [5,6,7,8,9,10,11,12]. Of those, 2 cases were presented with CNS involvement. The age at diagnosis of the cases ranged between 3 to 16, and 3 patients died. Most of the patients treated by Bernard et al. received supportive therapy, whereas only one patient was given rituximab [5]. Despite good response to the therapy, that patient died with relapsed leukemia after 6 months. Incidence of brain involvement is more common in cases with EBV besides acute lymphoblastic leukemia [13].

Different treatments for EBV-associated LPD have been proposed. Therapies have targets including the decrease of immunosuppression and improvement of immune function, or the removal of the lymphoproliferative lesion. Another strategy is to eliminate EBV-infected B cells with chemotherapy or antiviral drugs or with the infusion of polyclonal donor-derived T cells specific for EBV proteins in the bone marrow of transplant recipients [14]. Recently the use of monoclonal anti-B cell antibodies has been proposed because of the expression of these antigens on the surface of EBV-transformed B cells [5,15].

Our patient received rituximab because the infiltration consisted predominantly of CD20-positive B cells. His neurological signs disappeared and cranial MRI showed complete resolution of

the masses. Since rituximab targets normal B cells as well as neoplastic B cells, almost complete depletion of normal B lymphocytes in the peripheral blood is observed for an average of 6 to 9 months after starting the therapy [16,17,18]. However, hypogammaglobulinemia related to B cell depletion after rituximab treatment is not usually problematic and is not associated with any clinical morbidity. Recently a prolonged hypogammaglobulinemia was reported in some patients receiving the therapy as an adjuvant to autologous stem cell transplantation [19,20]. Additionally in most cases, the level of hypogammaglobulinemia is mild, although it sometimes persists for over 2 years. Irie et al. [21] reported a 60-year-old woman diagnosed with follicular lymphoma who received rituximab therapy. She developed hypogammaglobulinemia persisting for 6 years. Nishio et al. [22] analyzed the phenotypes of B cells in patients receiving rituximab and showed that recovery of memory B cells was delayed and naive B cells failed to differentiate into memory cells or plasma cells upon stimulation with SAC, IL-2, IL-10, and CD40L in vitro. In addition, they reported that FC-gamma-RIII-alpha gene polymorphism was related to the immunoglobulin level. We think that the naive B cells of our patient also failed to differentiate into memory B cells or plasma cells.

Although the reason for B cell differentiation arrest is still unclear, there are 2 possible explanations for this phenomenon.

**Table 1:** Clinical data of the published cases with acute leukemia that had development of EBV-associated lymphoproliferative disorder.

Age	Sex	Involvement site	Treatment	Outcome	Reference
9 years	Male	Lymph node, liver, spleen	Prednisone, supportive therapy	Exitus	Look AT, 1981 [14]
4.5 years	Male	Ileum, lung, tonsil, trachea, eyelid	Supportive therapy	Exitus	Hardy C, 1984 [1]
4 years	Female	Lung	Acyclovir	Recovered	Joncas JH, 1990 [15]
4 years	Male	Ileum, liver	Radiotherapy, surgery	Recovered	Joncas JH, 1990 [15]
3 years	Female	CNS	Chemotherapy, radiotherapy	Recovered	Rohrlich P, 1993 [16]
7 years	Male	Lung	Steroid, chemotherapy, alpha-INF	Recovered	Perkkiö M, 1997 [17]
6 years	Male	Liver, spleen, kidney, lung	IFN, IVIG, acyclovir	Recovered	Mustafa MM, 1997 [18]
15 years	Female	Ileum, liver, spleen, kidney	Rituximab	Recovered, but 6 months later died of relapsed leukemia	Bernard F, 2000 [4]
16 years	Male	Ileum, liver	IVIG, acyclovir	Recovered	Pondarre C, 2000 [19]
6 years	Male	Lymph node, CNS, liver	IVIG, acyclovir, surgery	Recovered	Drury S, 2000 [20]

CNS: central nervous system, IFN: interferon, IVIG: intravenous immunoglobulin.

First, genetic aberration of a factor essential for immunoglobulin rearrangement may have occurred in lymphoid progenitor cells after combination chemotherapy. Second, rituximab combined chemotherapy may be associated with a risk of persistent differentiation arrest and apoptosis of B cell lineage in patients with a specific genetic background [21]. Since our patient was also treated with alpha-interferon and chemotherapy, those might have contributed to hypogammaglobulinemia. Because interferon is widely used for decreasing immunosuppression and improving immune function, it is also speculated that alpha-interferon may have contributed to remission of leukemia in this case [23].

X-linked lymphoproliferative disease is a rare immunodeficiency disease that is characterized by a prediction for fatal or near-fatal EBV-induced infectious mononucleosis in childhood, subsequent hypogammaglobulinemia, and a markedly increased risk of lymphoma or other lymphoproliferative diseases [24]. A definitive diagnosis of X-linked lymphoproliferative disease is with mutation analysis for the SH2D1A and XIAP genes mutation. However we did not exclude the diagnosis of X-linked lymphoproliferative disease because the mutation analysis could not be performed in our case.

In conclusion, EBV-associated LPD in leukemia is a serious complication and extremely rare clinical entity. The present case was treated successfully with rituximab and alpha-interferon. Although rituximab therapy seems to be promising in these cases, persistent hypogammaglobulinemia may appear after treatment. Physicians treating this disease with rituximab should be aware of this rare potential complication. The chemotherapy and alpha-interferon treatment may contribute to hypogammaglobulinemia. In addition, further studies are needed to elucidate the pathogenesis of hypogammaglobulinemia after rituximab administration.

### References

- Hardy C, Feusner J, Harada S, Sanger W, Von Schmidt B, Yetz J, Saemundsen A, Lennette E, Linder J, Seeley JK, et al. Fatal Epstein-Barr virus-induced lymphoproliferation complicating acute lymphoblastic leukemia. *J Pediatr* 1984;105:64-67.
- Taj MM, Hadzic N, Height SE, Wotherspoon A, Burke M, Hobson R, Viskaduraki M, Pinkerton CR. Long term outcome for immune suppression and immune related lymphoproliferative disorder: Prospective data from the UK CCLG Registry 1994-2004. *Leuk Lymphoma* 2012;53:842-848.
- Yuksel-Soycan L, Aydogan G, Tanyeli A, Timur C, Erbay A, Oniz H, Patiroglu T, Yesilipek A, Soker M, Vural S, Pekun F, Bor O, Sarper N, Cetingul N, Guler E, Polat A, Biner B, Caglar K, Goksan B, Gedikoglu G. BFM-TR ALL 2000: First Turkish multicentric study in the treatment of pediatric acute lymphoblastic leukemia. *Pediatr Blood Cancer* 2006;47:426-427.
- Rezk SA, Weiss LM. Epstein-Barr virus-associated lymphoproliferative disorders. *Hum Pathol* 2007;38:1293-1304.
- Bernard F, Sarran N, Margueritte G, Barneon G, Astruc J. Successful treatment of an Epstein-Barr virus-associated B-cell lymphoproliferative disease in a child with acute lymphoblastic leukemia using an anti-CD20 monoclonal antibody. *Med Pediatr Oncol* 2001;36:329-331.
- Look AT, Naegele RF, Callihan T, Herrod HG, Henle W. Fatal Epstein-Barr virus infection in a child with acute lymphoblastic leukemia in remission. *Cancer Res* 1981;41:4280-4283.
- Joncas JH, Russo P, Brochu P, Simard P, Brisebois J, Dube J, Marton D, Leclerc JM, Hume H, Rivard GE. Epstein-Barr virus polymorphic B-cell lymphoma associated with leukemia and with congenital immunodeficiencies. *J Clin Oncol* 1990;8:378-384.
- Rohrlich P, Lescoeur B, Rahimy C, Vilmer E, Brousse N, Foulon E. Epstein-Barr virus associated B-cell lymphoproliferation in an infant treated for acute lymphoblastic leukemia. *Blood* 1993;81:264.
- Perkkiö M, Riikonen P, Seuri R, Vornanen M. Successful treatment of monoclonal, aggressive Epstein-Barr virus-associated B-cell lymphoproliferative disorder in a child with acute lymphoblastic leukemia. *Med Pediatr Oncol* 1999;32:447-449.
- Mustafa MM, Winick NJ, Margraf LR. Epstein-Barr virus lymphoproliferative disorder in children with leukemia: case report and review of the literature. *J Pediatr Hematol Oncol* 1997;19:77-81.
- Pondarre C, Kebaili K, Dijoud F, Basset T, Philippe N, Bertrand Y. Epstein-Barr virus-related lymphoproliferative disease complicating childhood acute lymphoblastic leukemia: no recurrence after unrelated donor bone marrow transplantation. *Bone Marrow Transplant* 2001;27:93-95.
- Drury S, Sathiapalan R, Warriar RP. Central nervous system involvement of Epstein-Barr virus lymphoproliferative disease in a patient with acute lymphocytic leukemia. *J Pediatr Hematol Oncol* 2000;22:167-170.
- Carbone A, Gloghini A, Dotti G. EBV-associated lymphoproliferative disorders: classification and treatment. *Oncologist* 2008;13:577-585.
- Rooney CM, Smith CA, Ng CY, Loftin SK, Sixbey JW, Gan Y, Srivastava DK, Bowman LC, Krance RA, Brenner MK, Heslop HE. Infusion of cytotoxic cells for the prevention and treatment of Epstein-Barr virus-induced lymphoma in allogeneic transplant recipients. *Blood* 1998;92:1549-1555.
- Benkerrou M, Jais JP, Leblond V, Durandy A, Sutton L, Bordigoni P, Garnier JL, Le Bidois J, Le Deist F, Blanche S, Fischer A. Anti-B-cell monoclonal antibody treatment of severe posttransplant B-lymphoproliferative disorder: prognostic factors and long-term outcome. *Blood* 1998;92:3137-3147.
- Quartier P, Brethon B, Philippet P, Landman-Parker J, Le Deist F, Fischer A. Treatment of childhood autoimmune haemolytic anemia with rituximab. *Lancet* 2001;358:1511-1513.

17. Verschuuren EA, Stevens SJ, van Imhoff GW, Middeldorp JM, de Boer C, Koeter G, The TH, van Der Bij W. Treatment of posttransplant lymphoproliferative disease with rituximab: the remission, the relapse and the complication. *Transplantation* 2002;73:100-104.
18. Shimoni A, Hardan I, Avigdor A, Yeshurun M, Raanani P, Ben-Bassat I, Nagler A. Rituximab reduces relapse risk after allogeneic and autologous stem cell transplantation in patients with high-risk aggressive non-Hodgkin's lymphoma. *Br J Haematol* 2003;122:457-464.
19. Shortt J, Spencer A. Adjuvant rituximab causes prolonged hypogammaglobulinemia following autologous stem cell transplant for non-Hodgkin's lymphoma. *Bone Marrow Transplant* 2006;38:433-436.
20. Imashuku S, Teramura T, Morimoto A, Naya M, Kuroda H. Prolonged hypogammaglobulinemia following rituximab treatment for post transplant Epstein-Barr virus-associated lymphoproliferative disease. *Bone Marrow Transplant* 2004;33:129-130.
21. Irie E, Shirota Y, Suzuki C, Tajima Y, Ishizawa K, Kameoka J, Harigae H, Ishii T. Severe hypogammaglobulinemia persisting for 6 years after treatment with rituximab combined chemotherapy due to arrest of B lymphocyte differentiation together with alteration of T lymphocyte homeostasis. *Int J Hematol* 2010;91:501-508.
22. Nishio M, Fujimoto K, Yamamoto S, Endo T, Sakai T, Obara M, Kumano K, Minauchi K, Yamaguchi K, Takeda Y, Sato N, Koizumi K, Mukai M, Koike T. Hypogammaglobulinemia with a selective delayed recovery in memory B cells and an impaired isotype expression after rituximab administration as an adjuvant to autologous stem cell transplantation for non-Hodgkin lymphoma. *Eur J Haematol* 2006;77:226-232.
23. Anguille S, Lion E, Willemsen Y, Van Tendeloo VF, Berneman ZN, Smits EL. Interferon- $\alpha$  in acute myeloid leukemia: an old drug revisited. *Leukemia* 2011;25:739-748.
24. Chaganti S, Ma CS, Bell AI, Croom-Carter D, Hislop AD, Tangye SG, Rickinson AB. Epstein-Barr virus persistence in the absence of conventional memory B cells: IgM + IgD + CD27 + B cells harbor the virus in X-linked lymphoproliferative disease patients. *Blood* 2008;112:672-678.