

H Syndrome - A Case Report

Abstract

This case report describes a case of H syndrome with characteristic cutaneous hyperpigmentation, hypertrichosis, sclerodermatous thickening, and multisystem involvement such as hearing loss and heart anomaly in an Indian patient. There are around 100 cases of this rare, autosomal recessive genodermatosis reported in the literature, out of which 10 cases are from the Indian population. The aim of this paper is to increase awareness about this novel inherited form of histiocytosis and insist on the role of dermatologists to identify such patients in our population where consanguinity is prevalent.

Keywords: *H syndrome, hyperpigmentation, hypertrichosis, rare case, sclerodermatous*

Introduction

H syndrome (OMIM # 602782) is an autosomal recessively inherited form of histiocytosis that occurs due to mutations in SCL29A3 gene that encodes human equilibrative nucleoside transporter 3 (hENT3).^[1] The characteristic cutaneous findings seen in this syndrome are Hyperpigmentation, Hypertrichosis, and induration. The specific systemic manifestations associated are Hearing loss, Heart anomalies, Hepatomegaly, Hypogonadism, Hyperglycemia (diabetic mellitus), low Height (short stature), Hallux valgus (flexion contractures), and Hematological abnormalities.^[2] There are around 100 cases of this syndrome reported in the literature, out of which 10 cases are from the Indian population.

Case History

A 12-year-old girl, first born of second degree consanguineous marriage presented with a history of hyperpigmentation over the thighs from birth. History of skin thickening over the buttocks, thighs, and legs was present for past 3 months. There was also a history of recurrent fever associated with swelling of legs. History of bilateral hearing loss was present since 5 years of age, and her other developmental milestones were normal. She had attained her menarche at 11 years of age and has

had regular menstrual cycles. There was no history of a similar illness in the family.

Her general physical examination showed low height for age, proptosis, webbing of neck, hepatomegaly, and normal genitalia. Skeletal examination was normal. Auditory evaluation revealed bilateral sensorineural hearing loss. On mucocutaneous examination well-defined, bilaterally symmetrical hyperpigmented, indurated plaques with hypertrichosis were present over medial and lateral aspect of thighs and legs sparing knees and feet [Figure 1a and b]. Similar lesions were present over the gluteal region bilaterally.

Routine laboratory investigations revealed ESR - 75, CRP - 81, microcytic anemia with hemoglobin levels of 10.1 g/dl, and a platelet count of 5.14 lakhs/cu.mm. Serum protein electrophoresis showed increased gamma fraction of 29.8 suggestive of polyclonal gammopathy. Investigations for the cause of fever revealed no positive findings. Thyroid profile, fasting, and post-prandial blood sugar levels were normal. Anti-nuclear antibodies' titer was negative. Skin biopsy showed thickened collagen bundles with lymphocytic and histiocytic infiltrates in the dermis extending to the subcutaneous tissue with few areas of fibrosis [Figure 2a]. Immunohistochemistry studies showed CD68 positivity in dermal perivascular histiocytic infiltrate [Figure 2b]. An ultrasound abdomen revealed hepatomegaly.

This is an open access journal, and articles are distributed under the terms of the Creative Commons Attribution-NonCommercial-ShareAlike 4.0 License, which allows others to remix, tweak, and build upon the work non-commercially, as long as appropriate credit is given and the new creations are licensed under the identical terms.

For reprints contact: reprints@medknow.com

How to cite this article: Yesudian P, Sarveswari KN, Karrunya KJ, Thomas K. H syndrome - A case report. Indian Dermatol Online J 2019;10:300-2.

Received: May, 2018. **Accepted:** December, 2018.

Patrick Yesudian,
K. N. Sarveswari¹,
K. J. Karrunya¹,
Kuruvilla Thomas²

Consultant Dermatologist,
Apollo Hospital, Departments of
¹Dermatology and ²Pediatrician,
Sundaram Medical Foundation,
Dr. Rangarajan Memorial
Hospital, Chennai, Tamil Nadu,
India

Address for correspondence:

Dr. K. J. Karrunya,
3A, Newry Maple Apts,
Old No. 61, New No. 30,
AH Block, 5th Street, Shanthy
Colony, Chennai - 600 040,
Tamil Nadu, India.
E-mail: coolkarru@gmail.com

Access this article online

Website: www.idoj.in

DOI: 10.4103/idoj.IDOJ_187_18

Quick Response Code:



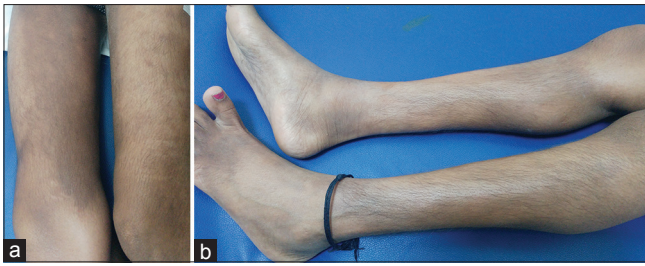


Figure 1: (a) Ill defined hyperpigmented, indurated large plaques on both thighs. (b) Hypertrichosis on legs

Chest radiography was normal, and an echocardiography revealed anomalous drainage of left pulmonary vein to innominate vein. In view of the constellation of findings summarized in Table 1, we made the diagnosis of H syndrome.

Discussion

The H syndrome is a rare autosomal recessive genodermatosis, first described by Molho-Pessach in 2008 with characteristic clinical and laboratory findings.^[1] The disorder is due to biallelic mutations in SLC29A3 gene that encodes hENT3 that facilitates transport of nucleosides, enabling cells that lack de novo synthesis to rely on salvage pathway.^[3] There are around 100 cases of H syndrome reported in the literature; mostly in Arab population, out of which 10 cases are from the Indian population.^[4]

Initially, from the cutaneous findings, the differential diagnoses thought of were morphea profunda and pseudoscleroderma, but later on the constellation of signs and histopathology guided us to the diagnosis of H syndrome.^[5]

Cutaneous hyperpigmentation with sclerodermatous thickening and hypertrichosis mainly on the lower limbs is the hallmark finding in 68% of patients and is also present in our case. It usually begins in 1st or 2nd decade of life. We did not see in our patient flexion contracture of fingers; the second most common feature seen in other cases. The next common features in form of hearing loss,^[6] short stature, hepatomegaly, cardiac anomalies, proptosis, and hematological abnormalities were present in our case. The webbing of neck seen in our patient was unique and not reported in other cases. Lymphadenopathy (24%), insulin-dependent diabetes (23%), and hypogonadism (16%) were absent in our case.^[7]

We noted recurrent fever and edema in our patient, which they have reported only in 5% of cases. Those cases were considered as a monogenic auto-inflammatory syndrome, now grouped under H syndrome.^[7] The systemic inflammation confirmed by the elevated inflammatory parameters could probably cause the recurrent fever in the daytime. We noted the characteristic histopathology of lympho-histiocytic infiltrate with CD68+ histiocytes and fibrosis in our patient. We could not verify the

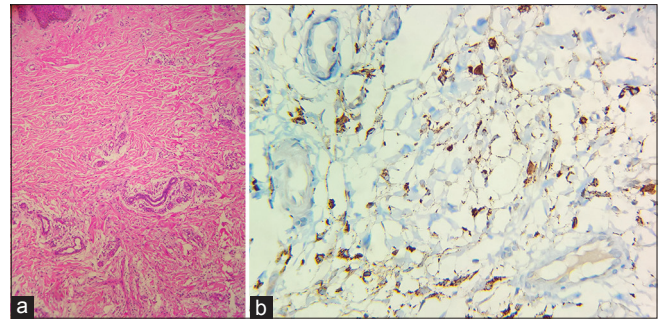


Figure 2: (a) Thickened collagen bundles with lymphohistiocytic infiltrates in upper and lower dermis extending to subcutis (H and E, 10x). (b) Immunohistochemistry showing CD68+ perivascular histiocytic infiltrate in dermis

Table 1: Findings in index case

Clinical features	Present/Absent
Hyperpigmentation	+
Hypertrichosis	+
Sclerodermatous thickening	+
Hepatomegaly	+
Hearing loss	+
Heart anomalies	+
Hematological changes	+
Short stature with webbing of neck	+
Histopathology- Dense dermal and subcutaneous infiltrate of histiocytes and later fibrosis	+
Hypogonadism	-
Hyperglycemia	-
Hallux valgus	-

+ (present) and - (absent)

mutation analysis of SCL29A3 gene because of cost restraints. However, we made the diagnosis of H syndrome confidently with the constellation of characteristic features. The genetic diagnosis is important to confirm uncertain cases and will help in guiding the genetic counseling and management.

We are reporting one more case of this rare syndrome from south India. The clinical phenotype variability seen in patients of H syndrome can lead to underdiagnosis of this condition. Hence, the dermatologist should be aware of the characteristic cutaneous findings, so they can screen the patient earlier for the systemic involvement in our population where consanguinity is prevalent. Genetic diagnosis and genetic counseling may play an important role in management.

Declaration of patient consent

The authors certify that they have obtained all appropriate patient consent forms. In the form the patient(s) has/have given his/her/their consent for his/her/their images and other clinical information to be reported in the journal. The patients understand that their names and initials will not be published and due efforts will be made to conceal their identity, but anonymity cannot be guaranteed.

Financial support and sponsorship

Nil.

Conflicts of interest

There are no conflicts of interest.

References

1. Molho-Pessach V, Lerer I, Abeliovich D, Agha Z, Libdeh AA, Broshtilova V, *et al.* The H syndrome is caused by mutations in the nucleoside transporter hENT3. *Amer J Human Genetics* 2008;83:529-34.
2. Molho-Pessach V, Agha Z, Aamar S, Glaser B, Doviner V, Hiller N, *et al.* The H syndrome: Agenodermatosis characterized by indurated, hyperpigmented, and hypertrichotic skin with systemic manifestations. *J Am Acad Dermatol* 2008;59:79-85.
3. Molho-Pessach V, Suarez J, Perrin C, Chiaverini C, Doviner V, Tristan-Clavijo E, *et al.* The H syndrome: Two novel mutations affecting the same amino acid residue of hENT3. *J Dermatological Science* 2010;57:59-61.
4. Molho-Pessach V, Varma M, Godbole K, Kamath N, Zlotogorski A. H syndrome-Four new patients from India. *Indian J Dermatol Venereol Leprol* 2014;80:579.
5. Mehta S, Masatkar V, Mittal A, Khare AK, Gupta LK. The H syndrome. *Indian J Paediatr Dermatol* 2015;16:102.
6. Ramot Y, Sayama K, Sheffer R, Doviner V, Hiller N, Kaufmann-Yehezkel M, *et al.* Early-onset sensorineural hearing loss is a prominent feature of H syndrome. *Int J Pediatr Otorhinolaryngol* 2010;74:825-7.
7. Molho-Pessach V, Ramot Y, Camille F, Doviner V, Babay S, Luis SJ, *et al.* H syndrome: The first 79 patients. *J Am Acad Dermatol* 2014;70:80-8.