

Osteosynthesis of ununited femoral neck fracture by internal fixation combined with iliac crest bone chips and muscle pedicle bone grafting

D D Baksi, A K Pal¹, D P Baksi²

ABSTRACT

Background: Ununited femoral neck fracture is seen commonly in developing countries due to delayed presentation or failure of primary internal fixation. Such fractures, commonly present with partial or total absorption of femoral neck, osteonecrosis of femoral head in 8–30% cases with upward migration of trochanter posing problem for osteosynthesis, especially in younger individuals. Several techniques for treatment of such conditions are described like osteotomies or nonvascularized cortical or cancellous bone grafting provided varying degrees of success in terms of fracture union but unsatisfactory long term results occurred due to varying incidence of avascular necrosis (AVN) of femoral head. Moreover, in presence of AVN of femoral head neither free fibular graft nor cancellous bone graft is satisfactory. The vascularized bone grafting by deep circumflex iliac artery based on iliac crest bone grafting, free vascularized fibular grafting and muscle pedicle periosteal grafting showed high incidence of success rate. Osteosynthesis is the preferred treatment of choice in ununited femoral neck fracture in younger individuals.

Materials and Methods: Of the 293 patients operated during the period from June 1977 to June 2009, 42 were lost to followup. Seven patients with gluteus medius muscle pedicle bone grafting (MPBG) were excluded. Thus, out of 244 patients, 208 (85.3%) untreated nonunion and 36 (14.7%) following failure of primary internal fixation were available for studies. Time interval between the date of injury and operation in untreated nonunion cases was mean 6.5 months and in failed internal fixation cases was mean 11.2 months. Ages of the patients varied from 16 to 55 years. Seventy patients had partial and 174 had subtotal absorption of the femoral neck. Evidence of avascular necrosis (AVN) femoral head was found histologically in 135 (54.3%) and radiologically in 48 (19.7%) patients. The patients were operated by open reduction of fracture, cannulated hip screw fixation, iliac crest bone chips and quadratus femoris MPBG.

Results: The mean followup is 12.5 years (range 3-35). The union of fractures occurred in 202 (82.8%), delayed union in 18 (7.3%), and established nonunion in 24 (9.8%) patients. Full weight bearing was permitted at 16–22 weeks after union of fractures. Mean Harris hip score at the longest followup was 85.5. Among the complications, superficial wound infection occurred in 20 (8.2%), deep infection in seven (2.9%), and coxa vara in 39 (16%) patients. Preoperative radiodensity of femoral head disappeared mostly after the union of fracture whereas fresh radiodensity of femoral head appeared in 20 (8%) patients; nine (45%) of them developed segmental collapse.

Conclusion: Ununited femoral neck fracture is characterized by absorption of femoral neck, posterior cortical defect, smoothing and overriding of fracture surfaces with intervening fibrous tissues associated with or without AVN of femoral head. The above method of osteosynthesis rectified the above pathology and provided satisfactory results with union of fractures in 90.1% patients at long term followup.

Key words: Femoral neck fracture, muscle pedicle bone graft, nonunion

MeSH terms: Femoral neck fractures, grafting, bone, osteonecrosis, osteosynthesis

Department of Orthopaedics, MGM Medical College, Kishanganj, Bihar,
¹Department of Orthopaedics, IPGMER, ²Department of Orthopaedics,
 Medical College and Hospital, Kolkata, West Bengal, India

Address for correspondence: Dr. D D Baksi,
 DA-3, Sector-I, Salt Lake City, Kolkata - 700 064, West Bengal, India.
 E-mail: ddbaksiorth12@gmail.com

Access this article online	
Quick Response Code: 	Website: www.ijoonline.com
	DOI: 10.4103/0019-5413.185591

This is an open access article distributed under the terms of the Creative Commons Attribution-NonCommercial-ShareAlike 3.0 License, which allows others to remix, tweak, and build upon the work non-commercially, as long as the author is credited and the new creations are licensed under the identical terms.

For reprints contact: reprints@medknow.com

How to cite this article: Baksi DD, Pal AK, Baksi DP. Osteosynthesis of ununited femoral neck fracture by internal fixation combined with iliac crest bone chips and muscle pedicle bone grafting. Indian J Orthop 2016;50:366-73.

INTRODUCTION

Ununited femoral neck fracture is seen commonly in developing countries due to delayed presentation or failure of primary internal fixation. Such fractures, commonly present with partial or total absorption of femoral neck,¹ osteonecrosis of femoral head in 8–30% cases² with upward migration of trochanter posing problem for osteosynthesis. Several techniques for treatment of such conditions is described like osteotomies³⁻⁹ or nonvascularized cortical¹⁰⁻¹⁴ or cancellous bone grafting¹⁵ provided varying degrees of success in terms of fracture union but unsatisfactory long term results due to varying incidence of avascular necrosis (AVN) of femoral head. Moreover, in presence of AVN of femoral head neither free fibular graft¹¹⁻¹⁴ nor cancellous bone graft¹⁵ is satisfactory. The vascularized bone grafting by deep circumflex iliac artery based on iliac crest,¹⁶ free vascularized fibular grafting,¹⁷ and muscle pedicle periosteal grafting¹⁸ showed high incidence of success rate.

With the knowledge of preservation of vascularity and viability of muscle pedicle bone graft in animal experiment,¹⁹⁻²¹ its use in fresh fractures of femoral neck^{14,22} was reported with successful results, though was contradicted in a small series.²³ Later on, its use in delayed fractures²⁴ and in ununited fractures with or without AVN femoral head^{25,26} was reported with success.

The use of muscle pedicle bone grafting (MPBG) with improved surgical techniques in ununited fracture of neck of femur with or without AVN in a large series of patients is now being reported with long term results.

MATERIALS AND METHODS

Two hundred ninety three ununited fracture neck of femur were operated separately by three authors between June 1977 and June 2009. Forty two of them were lost to followup and seven patients where gluteus medius MPBG was used were excluded from these studies. Therefore, 244 patients were available for evaluation. The inclusion criteria were the nonobese, physiologically active patients between 16 and 55 years of age having ununited femoral neck fractures with proximal fragment of fractures having 2.5 cm. or more length available for adequate subarticular bone stock (Type I and II absorption) without significant overriding of fragment. The exclusion criteria were the patients with associated osteoarthritis (OA) or rheumatoid arthritis, inadequate bone stock, especially following failed dynamic hip screw fixation, radiological evidence of AVN with segmental collapse of femoral head and overriding of fracture fragments as evidenced by position of lesser

trochanter at a level higher than inferior articular surface of acetabulum. The consent of the ethical committee was obtained for these studies. Twenty four patients of the previously reported series²⁶ were included.

Among 244 patients, 208 (85.3%) were ununited and untreated fractures and 36 (14.7%) had failed primary internal fixation. The mean time interval between the date of injury and surgery among ununited and untreated cases was 6.5 (range 3-25) months, whereas in failed cases of primary internal fixation it was 11.2 (range 3-36) months. The mean age of the patients was 43.3 (range 16-55) years. Absorption of the femoral neck was determined radiographically in all and by computed tomography scan in selected cases. Accordingly, they were divided into three categories: Type I - partial absorption of femoral neck where either proximal or distal or both fracture fragments were absorbed minimally with a gap <1 cm. Type II - subtotal absorption where similar absorption of the same fragments was seen with a gap 1–2 cm. Type III - total absorption of femoral neck where gap was more than 2 cm. Size of proximal fragment (subarticular bone segment) is determined from upper part of fovea to the center of fracture surface. Type III cases were not included in this series.

Among 244 patients, 70 had partial (Type I) and 174 subtotal (Type II) absorption of femoral neck.

Overriding of fracture fragments was recognized among untreated neglected patients who were walking with or without support. Histological specimen taken from the femoral head during operation showed AVN in 135 (55.3%) of patients. Radiological evidence of AVN as evidenced by the presence of mottled or zone of density of femoral head was seen in 48 (19.7%) patients. There were 132 males and 112 females. One hundred and sixteen fractures were on the right and 128 on the left side. Twenty two patients had associated asthma, old myocardial ischemia, hypertension, or psychological problem and required medical management prior to their operation. The mean shortening of the affected lower limb was 2.5 (range 1.5 – 3) cm. One hundred and twenty five patients having 2 cm shortening were treated by skeletal traction with 5–10 kg weight for 7–10 days to stretch contracted soft tissues.

Operative procedure

The technique described by Baksi²⁶ was updated as follows: The patient was placed prone on a fracture table. An incision was made along the line of the gluteus maximus muscle fibers overlying the trochanteric crest. The muscle was splitted to expose the underlying short rotators muscles. The upper and posterior origins of segment of vastus lateralis

were detached and retracted forward and downward to expose subtrochanteric aspect of shaft of femur.

Quadratus femoris (QF) MPBGs (including a segment of intertrochanteric crest and the adjacent bone was prepared with bony portion (2 cm wide and 1.5 cm deep).

The common tendinous insertion of obturator internus and gemelli was cut close to their insertion and reflected medially. The capsule was opened over the posterior surface of the femoral head and neck through an inverted "T" shaped incision, the stem of which started from the acetabular labrum. Special care was taken not to damage the capsule superiorly to save lateral epiphyseal artery. The posterior cortical defect of the femoral neck was often encountered. The fracture surfaces were cleared of fibrous tissues and infolded tags of periosteum interposed between them. The smooth or sclerosed fracture surfaces were then freshened. Any tilt or rotation of the femoral head was corrected. Varying degrees of absorption of femoral neck and cupping of the fracture surfaces were noted, through which multiple drill holes were made to ensure thorough decompression of the necrotic bone of the femoral head.

Biopsy specimens were taken from femoral head for histological examination. Before open reduction of fracture, a piece of silk thread was placed transversely between the fracture surfaces close to anterior surface of the femoral neck but within the articular capsule [Figure 1] for fixation of the MPBG around the fixation screws. Free cancellous bone chips taken from posterior iliac crest were packed between the reduced fracture surfaces [Figure 1]. There

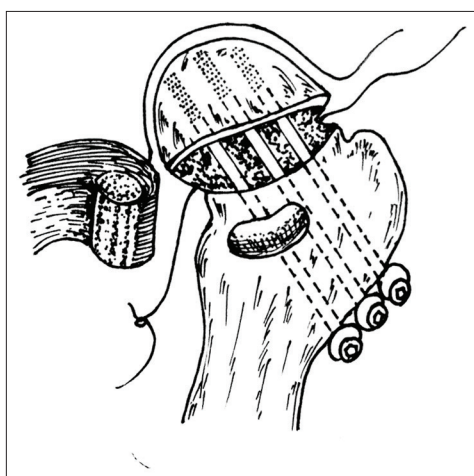


Figure 1: Schematic diagram showing that quadratus femoris muscle pedicle bone graft is seen on the left. Fracture surfaces are seen freshened and multiple drill holes are made through fracture surface of the femoral head. A piece of silk thread is placed transversely between the fracture surfaces close to the anterior surface of the femoral neck but within the articular capsule. The fracture gap is packed with cancellous bone chips and fixed internally by three cannulated hip screws

is inclusion of 24 patients of our previous reports²⁶ where modified Hagie pins for fracture fixation were used. With the awareness of bending, breaking, loosening and migration of these pins, subsequently cannulated screws as available since 1990 were used under control of image intensifier till date. The fracture was then fixed internally by three 6.5 mm cannulated cancellous screws [Figure 1] under direct vision supplemented by image intensifier. In cases of revision operation after failure of primary internal fixation, refixation with new screws was found sometimes difficult due to paucity of healthy cortex in the subtrochanteric region. Then, the silk thread was used for fixation of the graft passing through the already isolated MPBG which was then impacted into a gutter made in the posterior aspect of the head and neck of the femur avoiding the tension or torsion of the muscle pedicle [Figure 2]. The silk thread was then tied tightly over the graft around the screws drawing together the cut margins of the articular capsule to ensure better fixation of the graft [Figure 2]. The common tendon of obturator internus and gemelli was now reattached to its original site of insertion, covering the graft, and also sutured to the QF muscle fibers to provide the additional security to the graft. A suction drain was placed over the posteroinferior aspect of the femoral neck deep to the gluteus maximus muscle. After wound closure, a shoe with derotation bar was applied.

Postoperative management

Two to three units of blood transfusion were often necessary during or after the operation. Intermittent passive movements of hip were encouraged during the early postoperative period. Suction drain was removed after 72 hours. On removal of stitches after 2 weeks, the operated hip was immobilized in abduction hip brace for 5–6 weeks, till the adjacent bone grafts around the fracture site become

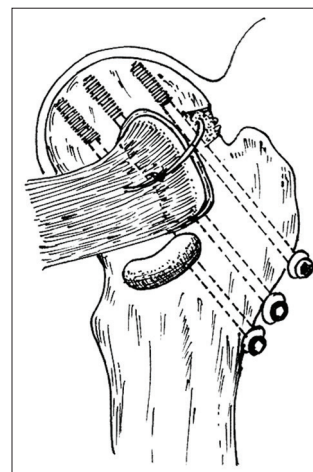


Figure 2: Schematic diagram showing that after placement of the muscle pedicle bone graft in a gutter made on the posterior aspects of femoral head and neck, the silk thread already passed through it and around the screws is tied altogether over the graft

firm. Nonweight bearing crutch walking was allowed at 12–16 weeks after the operation. Full weight bearing was allowed 16–22 weeks after radiological evidence of satisfactory fracture union.

RESULTS

Two hundred forty four patients were followed up for mean 12.5 (range 3–35) years. The results were evaluated based on clinical and radiological criteria [Table 1]. The results in different age groups are shown in Table 2. About 202 (82.8%) patients achieved satisfactory union [Figures 3-6] in mean 4.5 (range 4-5.5) months. Satisfactory union was evidenced clinically by painless hip motions on weight bearing and radiological obliteration of fracture gap

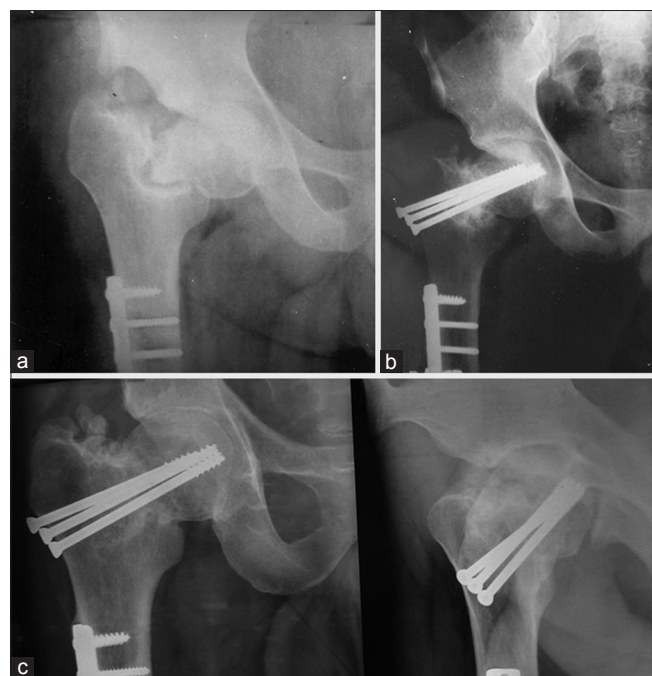

Figure 3: (a) Preoperative radiograph (R) hip joint anteroposterior view of a 34-year-old male showing 22 months old, neglected ununited femoral neck fracture with partial absorption and varus deformity (b) Postoperative radiograph of the above patient 4 months after open reduction and internal fixation, and quadratus femoris muscle pedicle bone grafting showing of the fracture (c) Postoperative radiograph after 13.5 years, showing satisfactory union of fracture without any evidence of avascular necrosis of femoral head

seen by bridging bony trabeculae across the fracture line. Eighteen (7.3%) patients with subtotal (Type II) absorption of femoral neck showed delayed fracture union till 6–7 months postoperative period. Two of them having fixation failure needed abduction femoral osteotomy for union of fracture.

Coxa vara with 10°–30° reduction of femoral neck shaft angle compared to normal hip was seen in 39 (17.7%)

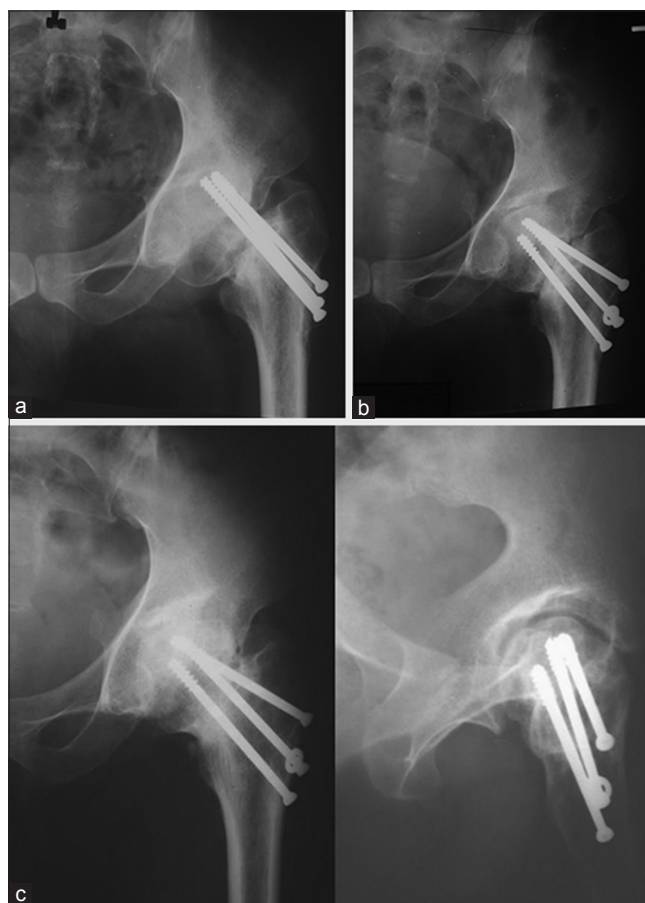

Figure 4: (a) Radiograph of left hip joint anteroposterior view of a 43-year-old male showing 13 months old ununited fracture with subtotal absorption of femoral neck following the failure of compression hip screw fixation. (b) Postoperative radiograph of the above patient, 3 months after open reduction and internal fixation, free and quadratus femoris muscle pedicle bone grafting showing visible fracture line. (c) Postoperative radiograph of the above patient 10 years followup showing satisfactory union of the fracture and no evidence of avascular necrosis of femoral head

Table 1: Criteria of gradation of results

Grade	Clinical features				Radiological features		
	Pain	Shortening (cms.)	Hip movements	Walking ability	Nonunion	AVN	Coxa vara
Excellent	None	<1	Almost full	Full	None	None	None
Good	None	1-2	Flexion 90° Rotation 10-30°	Full	None	None	None
Fair	Intermittent	2-3	Flexion 90° or less Rotation 10-20°	Partly restricted	None	AVN No collapse	10-20°
Poor	Constant	>3	Gross restriction	None Without aid	Present	AVN With collapse	>20°

patients which was caused by persistent absorption of femoral neck, inadequate correction of original varus deformity or early weight bearing after operations. However, 10°–20° loss of neck shaft angle did not appreciably affect the functional outcome.

Forty eight (19.7%) patients who had preoperative radiodensity showed gradual clearance after union of fracture. However, twenty (11%) patients after union of fracture showed appearance of fresh radiodensity of femoral

head of which 9 (45%) developed segmental collapse. The mean shortening of the operated limb after union of fracture was 2 (range 1-2.5) cm.

The hip motions at final followup were mean flexion 90.2° (range: 90°–115°), extension mean 15° (range 10°–20°), abduction mean 30.5° (range 15°–40°), adduction mean 30° (range 10°–40°), external rotation mean 30° (range 20°–40°) and internal rotation mean 10° (range 5°–20°). The Harris hip score²⁷ at longest followup was mean 85.5 (range 55-92).

Table 2: Age distribution and their results

Age distribution (years)	No. of patients	Total patients %	Results			
			Excellent	Good	Fair	Poor
10-20	6	2.5	2	3	1	0
21-30	24	9.8	9	12	2	1
31-40	44	18	20	18	3	3
41-50	102	41.8	38	48	4	12
51-60	68	27.9	24	32	4	8
Total	244	100	93 (38.1%)	113 (46.3%)	14 (5.8%)	24 (9.8%)

Complications

Among minor complications, superficial wound infection occurred in 20 (8.2%), limb length discrepancy mean 2 cm (range 1-2.5 cm) in 204 (83.6%), coxa vara 39 (16%), bending of screws in two patients resulted in delayed union, and pericapsular new bone formation occurred in one.

Among major complications, 24 patients (9.8%) had established nonunion at mean 12 months (range 10–15 months). Deep-seated infection occurred in

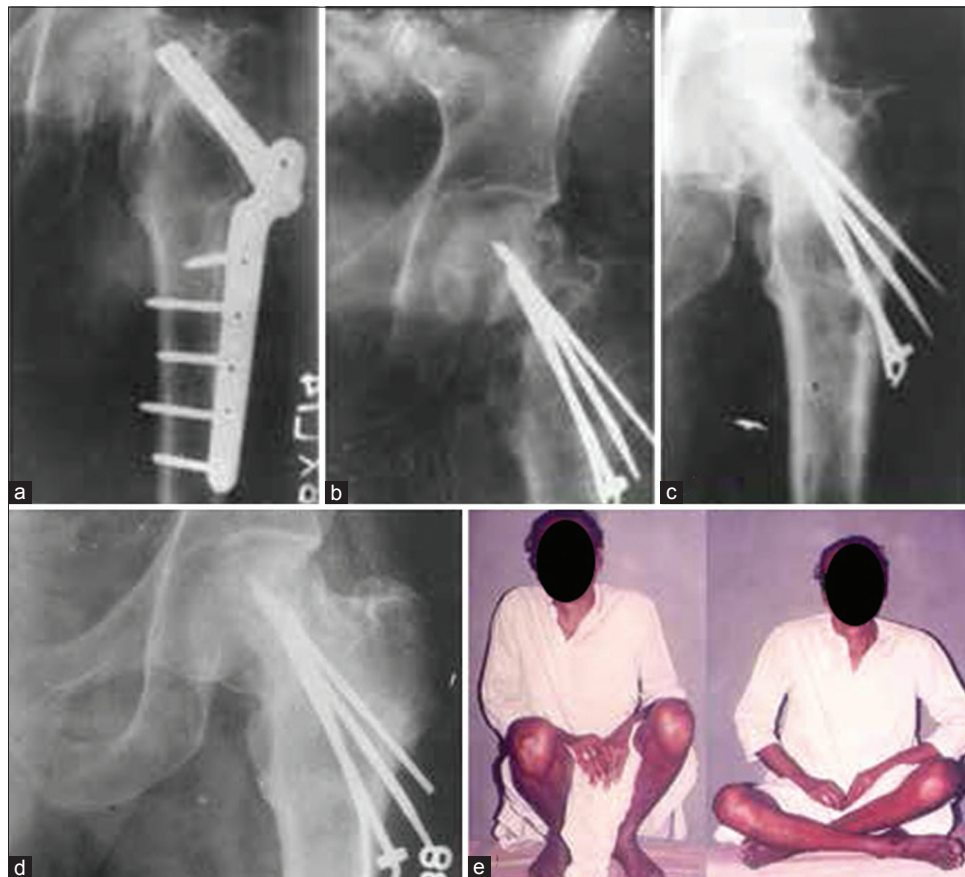


Figure 5: (a) X-ray of left hip joint anteroposterior view of a forty seven years old male patient who had 36 months old ununited fracture neck femur with the subtotal absorption of femoral neck after the failure of internal fixation with Mc Laughlin's nail plating done in July 1989. Zone of the density of femoral head noted. (b) Six weeks old postoperative skiagram showing four modified Hagie pins fixation combined with free iliac crest bone chips and quadratus femoris muscle pedicle bone grafting of the patient. (c) Four months old postoperative skiagram of the patient showing the satisfactory union of the fracture. (d) Twenty two years postoperative skiagram of the patient showing satisfactory union of femoral neck fracture and clearance of density of femoral head. (e) Twenty two years postoperative clinical photograph of the patient showing squatting cross legged sitting.

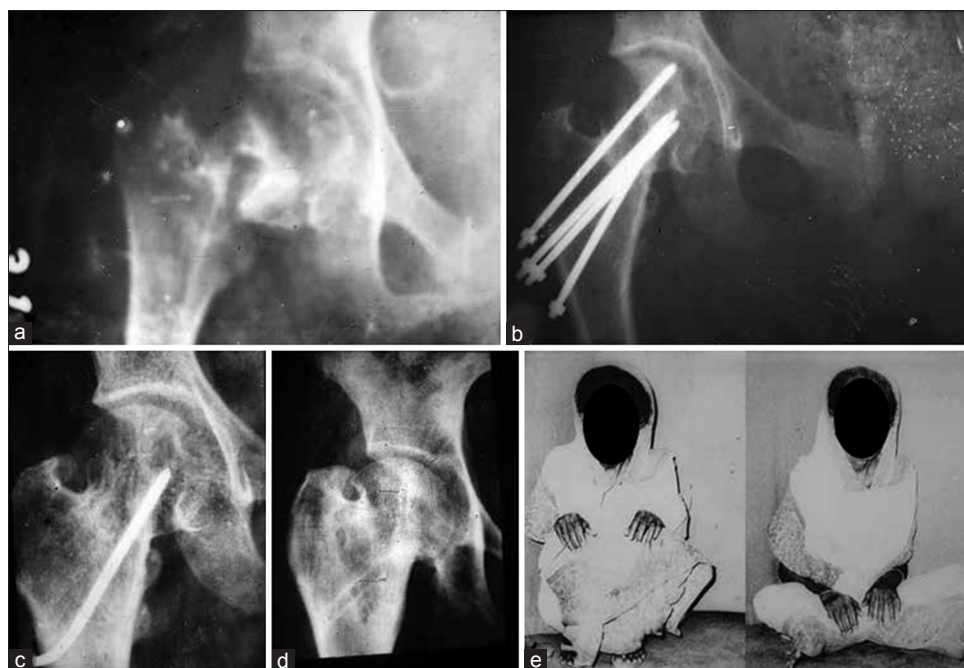


Figure 6: (a) Preoperative radiograph (Rt) anteroposterior view of hip joint of a 50-year-old female showing an untreated and ununited fracture of neck of femur of 24 months duration with subtotal (Type II), absorption of femoral neck, and mottled density of femoral head noted. (b) Twelve weeks postoperative skiagram showing the union of fracture neck of femur. (c) Eleven years followup skiagraph of the patient showing the union of fracture with left out one Hagie pin. (d) Twenty four years followup skiagraph of the patient showing the union of fracture and clearance of radiodensity of femur head and all pins used for fracture fixation already removed (e) Twenty one years followup clinical photographs of the female showing squatting and sitting cross legged

seven (2.9%) patients resulted in septic nonunion. Other cases had aseptic nonunion, five of them were due to failure of fracture fixation.

AVN of femoral head as evidenced by fresh radiodensity was seen in 20 (8%) patients of which 9 (45%) had collapsed. Postoperative early OA hip was noted though asymptomatic in almost all cases which had more than 10 years followup.

Of these, four were salvaged by hemiarthroplasty, six of these patients required total hip replacement due to acetabular changes found peroperatively. Two patients were salvaged by a repeat osteosynthesis supplemented by a sartorius MPBG.²⁵ They went to uneventful union 11–15 months after the index procedure. Of the remaining patients, seven had persistent nonunion due to deep seated infection and five had persistent nonunion with no infection. The patients with nonunion were either salvaged by total hip replacement or were able to function adequately with vigorous rehabilitation to achieve independent activities of daily living with minimal disabilities.

DISCUSSION

Several attempts of osteosynthesis have been made using nonvascularized and vascularized bone grafts

along with internal fixation by different investigators [Table 3].^{6,10,12,13,16-18,24,26,28-31}

Nonvascularized free fibular bone grafting¹⁰⁻¹³ may help in osteosynthesis of fracture of <3 months old¹⁰ and if the femoral head is viable, vascular and without significant absorption of femoral neck.^{10,11} Pauwel's valgus osteotomy may give high union rate 80.4% and equally higher incidence (59.5%) of AVN of femoral head⁶ because valgus position of femoral head shortens the abduction lever arm of the abducted femoral neck and predisposed to avascular necrosis.⁷⁻⁹

The vascularized iliac crest,¹⁶ fibular,¹⁷ and periosteal grafting¹⁸ procedures were not popular because they were time consuming, technically demanding and beyond the competency of average orthopedic surgeons. Furthermore, though the series of such vascularized bone grafting showed high incidence of union rate in their small series and shorter followup, it is too early to predict the future occurrence of AVN in those patients. On the other hand, our technique provided accurate reduction of ununited fracture in majority of the patients. The closed methods of reduction of ununited fracture neck femur in the presence of displacement with tilting or twisting of fracture fragments is not possible in the presence of 65–90% posterior cortical defect¹⁴ and interposed fibrous tissues between

Table 3: Comparative results with other described methods for delayed/ununited fractures of femoral neck

Authors	Number of patients	Methods of treatment	Union (%)	AVN (%)	Coxa vara (%)	Comments
King, T (1939) ¹⁰	30	SP nail and fibular graft	68.75	25	-	OA 23%
Henderson (1940) ²⁸	77	CR and OR and SP nail + tibial or fibular graft	68.6	-	-	Failure 28.3%
Patrick (1941) ²⁹	47	CR + SP nail fibular graft	-	12.8	-	21.3% OA
Bonfiglio and Voke (1968) ³⁰	77	CR-pinning phemister graft	-	7	-	80% Good results
Nagi et al. (1968) ¹²	52	OR, cannulated screw fix fibular graft	95	17.5	27.5	AVN with collapse 12.5%
H. S. Sandhu (2005) ¹³	168	CR + Int. Fix. + fibular grft (single or double)	88	3.6	-	Failure 20 OA 207%
Marti et al. (1989) ⁶	50	Pauwel's abd. osteotomy	80.4	59.5	-	
Mayer's et al. (1974) ²⁴	32	Int. Fix.+ MPBG	84.4	-	-	-
Baksi D P (1986) ²⁶	56	Int. Fix.+ MPBG	82	3.6	14.3	-
Gupta et al. (2008) ³¹	32	Int. Fix.+ MPBG	89.65	6.89	3.1	-
Gupta (2007) ¹⁸	20	Muscle-pedicle Periosteal Grafting	100	5	5	-
Leong and chen (1993) ¹⁶	Small series	ORIF+deep circumflex iliac fem. artery based	100	-	-	Excellent iliac crest
Lecroy et al. (2002) ¹⁷	21	Int. Fix. + free vascular fibular graft	91-100	-	-	Excellent
Baksi et al.	Present series 244	Int. fix. + iliac crest bone chips and MPBG	90.1	8	16	OA (asymptomatic)

CR=Closed reduction, OR=Open reduction, AVN=Avascular necrosis, OA=Osteoarthritis, MPBG=Muscle-pedicle bone graft, Int=Internal, Fix=Fixation, SP=Smith-Petersen

the fracture surfaces. Their clearance and reconstruction with free iliac crest bone chips can better be done through posterior approach under direct vision. There is theoretical possibility of damaging the posterior retinacular vessels and ascending branch of posterior circumflex femoral artery through the posterior approach, but in the presence of hypovolemic femoral head³² with its compromised blood supply, posterior approach may not add any extra harm. Peroperative correction of varus deformity, tilting, or twisting of e femoral head for apposition with the distal fracture fragment under direct vision was necessary for anatomical restoration of head and neck of femur. Multiple drilling through the fracture surface of femoral head decompressed the osteonecrosis of femoral head wherever present and helped in growth of vascular granulation tissues [Figure 1].

The placement of MPBG behind the femoral head and neck served several purposes: It acted as a strut across the posterior cortical defect, prevented posterior tilt of the femoral head, and acted as a vascular viable inlay graft encouraged osteosynthesis and revascularization of femoral head.²⁶ Fixation of MPBG around the screws by silk thread appeared more effective than achieved by a screw fixation in the presence of absorbed femoral neck. Use of postoperative hip abduction brace for about 6 weeks is an added advantage for the security of internal fixation of fracture till adjacent bone grafts likely become firm. Occurrence of fresh radiodensity of femoral head in 20 (11%) patients after union of fracture and 9 (45%) of them showing segmental collapse may be due to revascularization of the necrotic area by the use of QF MPBG, placed behind the femoral head and neck; but because of its short muscle length, its vascular supply failed to reach the center of necrotic anterosuperior part of femoral head. Among all the methods described [Table 3],

use of vascularised bone grafts¹⁶⁻¹⁸ including the use of MPBG,^{25,26,31} our series showed enhanced rate of fracture union in 90.1% patients along with repair of AVN femoral head wherever present and also reduced the occurrence of fresh radiodensity after union of the fracture.

CONCLUSION

This technique is effective for satisfactory healing of ununited femoral neck fractures with or without the necrosis of femoral head improved function in majority.

Declaration of patient consent

The authors certify that they have obtained all appropriate patient consent forms. In the form the patient(s) has/have given his/her/their consent for his/her/their images and other clinical information to be reported in the journal. The patients understand that their names and initials will not be published and due efforts will be made to conceal their identity, but anonymity cannot be guaranteed.

Financial support and sponsorship

Nil.

Conflicts of interest

There are no conflicts of interest.

REFERENCES

1. Lambiase RE, Levine SM, Froehlich JA. Rapid osteolysis of the femoral neck after fracture. *AJR Am J Roentgenol* 1999;172:489-91.
2. Rogers LF. *Radiology of Skeletal Trauma*. 2nd ed., Vol. 11. New York: Churchill Livingstone; 1992. p. 39-40.

3. McMurray TP. Ununited fracture of the neck of femur. *J Bone Joint Surg* 1936;18:319-27.
4. Dickson JA. The unsolved fracture; a protest against defeatism. *J Bone Joint Surg Am* 1953;35-A:805-22.
5. Chowdhury AK, Chatterjee ND, Baksi DP. Different osteotomies and internal fixation combined with muscle pedicle bone grafting in the treatment of ununited femoral neck fractures – A comparative study. *Indian J Orthop* 1992;26:55-60.
6. Marti RK, Schüller HM, Raaymakers EL. Intertrochanteric osteotomy for nonunion of the femoral neck. *J Bone Joint Surg Br* 1989;71:782-7.
7. Garden RS. Malreduction and avascular necrosis in subcapital fractures of the femur. *J Bone Joint Surg Br* 1971;53:183-97.
8. Smith FB. Effects of rotatory and valgus malpositions on blood supply to the femoral head; observations at arthroplasty. *J Bone Joint Surg Am* 1959;41-A:800-15.
9. Calandruccio RA, Anderson WF 3rd. Post-fracture avascular necrosis of the femoral head: Correlation of experimental and clinical studies. *Clin Orthop Relat Res* 1980;152:49-84.
10. King T. The closed operation for a intracapsular fracture of the neck of the femur – Final results in recent and old cases. *Br J Surg* 1939;26:721-48.
11. Bonfiglio M, Bardenstein MB. Treatment by bone-grafting of aseptic necrosis of the femoral head and nonunion of the femoral neck (Phemister technique). *J Bone Joint Surg Am* 1958;40-A:1329-46.
12. Nagi ON, Dhillon MS, Goni VG. Open reduction, internal fixation and fibular autografting for neglected fracture of the femoral neck. *J Bone Joint Surg Br* 1998;80:798-804.
13. Sandhu HS, Sandhu PS, Kapoor A. Neglected fractured neck of the femur: A predictive classification and treatment by osteosynthesis. *Clin Orthop Relat Res* 2005;431:14-20.
14. Meyers MH, Harvey JP Jr., Moore TM. Treatment of displaced subcapital and transcervical fractures of the femoral neck by muscle-pedicle-bone graft and internal fixation. A preliminary report on one hundred and fifty cases. *J Bone Joint Surg Am* 1973;55:257-74.
15. Dickson JA. Treatment of ununited fractures of the neck of the femur by means of bone graft and Smith Petersen nail. *Surg Clin North Am* 1939;19:1235-41.
16. Leung PC, Shen WY. Fracture of the femoral neck in younger adults. A new method of treatment for delayed and nonunions. *Clin Orthop Relat Res* 1993;295:156-60.
17. LeCroy CM, Rizzo M, Gunneson EE, Urbaniak JR. Free vascularized fibular bone grafting in the management of femoral neck nonunion in patients younger than fifty years. *J Orthop Trauma* 2002;16:464-72.
18. Gupta A. The management of ununited fractures of the femoral neck using internal fixation and muscle pedicle periosteal grafting. *J Bone Joint Surg Br* 2007;89:1482-7.
19. Frankel CJ, Derian PS. The introduction of subcapital femoral circulation by means of an autogenous muscle pedicle. *Surg Gynecol Obstet* 1962;115:473-7.
20. Launois B, Judet R. Epaules Fractures du coll du femur. Paris, Masson et Cie 1963. [Cited by Meyers MH, Harvey JP Jr, Moore TM. Treatment of displaced subcapital and transcervical fractures of the femoral neck by muscle-pedicle-bone graft and internal fixation. A preliminary report on one hundred and fifty cases. *J Bone Joint Surg Am* 1973;55:257-74.
21. Medgyesi S. Investigation into the carrying ability of pedicled bone grafts during transplantation. *Acta Orthop Scand* 1968;39:1-7.
22. Judet R. Treatment of fractures of the femur neck by pedicled graft. *Acta Orthop Scand* 1962;32:421-7.
23. Johnson KD, Brock G. A review of reduction and internal fixation of adult femoral neck fractures in a county hospital. *J Orthop Trauma* 1989;3:83-96.
24. Meyers MH, Harvey JP Jr., Moore TM. Delayed treatment of subcapital and transcervical fractures of the neck of the femur with internal fixation and a muscle pedicle bone graft. *Orthop Clin North Am* 1974;5:743-56.
25. Baksi DP. Treatment of posttraumatic avascular necrosis of the femoral head by multiple drilling and muscle-pedicle bone grafting. Preliminary report. *J Bone Joint Surg Br* 1983;65:268-73.
26. Baksi DP. Internal fixation of ununited femoral neck fractures combined with muscle-pedicle bone grafting. *J Bone Joint Surg Br* 1986;68:239-45.
27. Harris WH. Traumatic arthritis of the hip after dislocation and acetabular fractures: Treatment by mold arthroplasty. An end-result study using a new method of result evaluation. *J Bone Joint Surg Am* 1969;51:737-55.
28. Henderson MS. Ununited fracture of the neck of the femur treated by the aid of the bone graft. *J Bone Joint Surg* 1940;22:97-106.
29. Patrick J. Intracapsular fractures of the femur treated with a combined Smith-Petersen nail and fibular graft. *J Bone Joint Surg Am* 1949;31A:67-80.
30. Bonfiglio M, Voke EM. Aseptic necrosis of the femoral head and nonunion of the femoral neck: Effect of treatment by drilling and bone-grafting (Phemister). *J Bone Joint Surg Am* 1968;50-A: 48-66.
31. Gupta AK, Rastogi S, Nath R. Internal fixation and muscle pedicle bone grafting in femoral neck fractures. *Indian J Orthop* 2008;42:39-42.
32. Nakamura F, Fujioka M, Takahashi KA, Ueshima K, Arai Y, Imahori Y, *et al.* Evaluation of the hemodynamics of the femoral head compared with the ilium, femoral neck and femoral intertrochanteric region in healthy adults: Measurement with positron emission tomography (PET). *Ann Nucl Med* 2005;19:549-55.