

Novel Port Placement and 5-mm Instrumentation for Robotic-Assisted Hysterectomy

Ceana H. Nezhat, MD, Adi Katz, MD, Erica C. Dun, MD, MPH, Kimberly A. Kho, MD, MPH, Friedrich A. Wieser, MD, PD

ABSTRACT

Background and Objectives: The value of robotic surgery for gynecologic procedures has been critically evaluated over the past few years. Its drawbacks have been noted as larger port size, location of port placement, limited instrumentation, and cost. In this study, we describe a novel technique for robotic-assisted laparoscopic hysterectomy (RALH) with 3 important improvements: (1) more aesthetic triangular laparoscopic port configuration, (2) use of 5-mm robotic cannulas and instruments, and (3) improved access around the robotic arms for the bedside assistant with the use of pediatric-length laparoscopic instruments.

Methods: We reviewed a series of 44 women who underwent a novel RALH technique and concomitant procedures for benign hysterectomy between January 2008 and September 2011.

Results: The novel RALH technique and concomitant procedures were completed in all of the cases without conversion to larger ports, laparotomy, or video-assisted laparoscopy. Mean age was 49.9 years (SD 8.8, range 33–70), mean body mass index was 26.1 (SD 5.1, range 18.9–40.3), mean uterine weight was 168.2 g (SD 212.7, range 60–1405), mean estimated blood loss was 69.7 mL

(SD 146.9, range 20–1000), and median length of stay was <1 day (SD 0.6, range 0–2.5). There were no major and 3 minor peri- and postoperative complications, including 2 urinary tract infections and 1 case of intravenous site thrombophlebitis. Mean follow-up time was 40.0 months (SD 13.6, range 15–59).

Conclusion: Use of the triangular gynecology laparoscopic port placement and 5-mm robotic instruments for RALH is safe and feasible and does not impede the surgeon's ability to perform the procedures or affect patient outcomes.

Key Words: Robotic-assisted laparoscopic hysterectomy, 5-mm Robotic ports, Short laparoscopic instruments, Aesthetics.

Atlanta Center for Reproductive Medicine, Minimally Invasive and Robotic Surgery, Atlanta, Georgia, USA (Drs. Nezhat, Dun).

Department of Obstetrics and Gynecology, Northshore–Long Island Jewish Health Systems, Manhasset, New York, USA (Dr. Katz).

Department of Obstetrics and Gynecology, University of Texas Southwestern Medical Center, Dallas, Texas, USA (Dr. Kho).

Department of Gynecology and Obstetrics, Emory University School of Medicine, Atlanta, Georgia, USA (Dr. Wieser).

Presented at the Society of Laparoendoscopic Surgeons, 19th SLS Annual Meeting and Endo Expo 2010, New York, New York, September 1–4, 2010. Oral presentation: Nezhat CH. Robotic-assisted laparoscopic hysterectomy utilizing the 5-mm da Vinci system.

Address correspondence to: Ceana H. Nezhat, MD, Adjunct Clinical Associate Professor of Gynecology & Obstetrics, Emory University School of Medicine, Atlanta Center for Reproductive Medicine, Minimally Invasive and Robotic Surgery, 5555 Peachtree Dunwoody Road, Suite 276, Atlanta, GA 30342, USA. Telephone: (404) 255-8778, Fax: (404) 255-5627, E-mail: ceana@nezhat.com

DOI: 10.4293/108680813X13693422518399

© 2014 by JSLS, *Journal of the Society of Laparoendoscopic Surgeons*. Published by the Society of Laparoendoscopic Surgeons, Inc.

INTRODUCTION

Robotic-assisted laparoscopic surgery is one of the fastest growing and widely adopted surgical innovations, with 373,000 procedures across all surgical subspecialties performed during 2012 in the United States, a 26% increase from the previous year.¹ In the field of gynecology, 222,000 robotic procedures were performed. Among these procedures were 176,000 robotic-assisted laparoscopic hysterectomies (RALHs); >80% of those were performed for benign indications.²

The RALH first reported by Diaz-Arrastia et al in 2002 has grown in popularity in the past decade.³ The da Vinci Surgical System (Intuitive Surgical, Inc., Sunnyvale, California) is an enabling technology that provides magnified, immersive, 3-dimensional visualization; greater dexterity and instrument articulation; decreased tremor; and seating during surgery to reduce surgeon fatigue. However, the value of the robot in gynecologic surgery has been critically evaluated in the past few years. Some shortcomings of robotic surgery are the larger 8-mm cannula, the un-aesthetic port configuration, and the high costs of owning and using the surgical system. When comparing robotic-assisted laparoscopy to conventional laparoscopy for benign, uncomplicated procedures such as a hysterectomy, patient outcomes and complication rates are similar.^{4,5} In

addition, a conventional laparoscopic hysterectomy can be executed with smaller 5-mm incisions and better cosmesis, and at lower costs.^{4,5}

In this case series, we describe an improved surgical technique for RALH combining a more aesthetic placement of laparoscopic incisions and smaller diameter ports. These improvements in robotic surgical technique are intended to decrease postoperative patient discomfort, decrease risk of wound complications, improve healing, and increase patient satisfaction. The objective was to evaluate first the safety and feasibility of this novel RALH technique that uses a triangular laparoscopic port configuration, smaller 5-mm robotic EndoWrist (Intuitive Surgical, Inc., Sunnyvale, California) instruments, and short laparoscopic instruments for the bedside assistant.

MATERIALS AND METHODS

The retrospective case series included consecutive patients who underwent the novel RALH technique as described in the next section. The female patients were >21 years of age, had been counseled about other treatment options for their respective conditions, and elected to undergo RALH, AAGL-type IVE hysterectomy⁶ and other indicated procedures between January 2008 and September 2011. The decision to perform robotic surgery versus conventional video-assisted laparoscopic surgery depended on the availability of the da Vinci Surgical System at the time of the procedure. Time conflicts owing to concurrent use within and between departments randomly and infrequently prevented the scheduled RALH from being performed. In these cases, the patient was not included in the study. All of the procedures were performed by a single surgeon, along with minimally invasive gynecology fellows and surgical assistants, at a private metropolitan hospital that is a tertiary referral center for minimally invasive gynecologic surgery and endometriosis. Demographic and clinical data were abstracted from medical records and included age, gravidity, parity, body mass index, prior surgery, and indication(s) for surgery. Data collected including primary and concomitant surgical procedures, estimated blood loss (EBL), uterine weight, operative time, intraoperative complications, postoperative complications, length of hospital stay (LOS), and follow-up time. This study, a retrospective case series, was exempt by the Institutional Review Board at Northside Hospital (Atlanta, Georgia).

Operative Technique

All patients received a perioperative dose of intravenous (IV) antibiotic per the surgical care improvement project protocol. After induction of general anesthesia, the patients were positioned on a nonslip pad in the dorsal lithotomy position with legs in Allen Pal Stirrups (Allen Medical Systems Inc., Acton, Massachusetts) and arms were tucked. The patients were sterilely prepped and draped, and an orogastric tube and Foley catheter were inserted. The procedure began with sounding the uterine cavity and then adjusting and inserting a RUMI uterine manipulator with a Koh colpotomy ring (Cooper Surgical, Trumbull, Connecticut) or VCare Uterine Manipulator/Elevator (ConMed Endosurgery, Utica, New York).

A pneumoperitoneum was established in the standard fashion with a Veress needle, and multipuncture operative laparoscopy⁷ was performed with the novel RALH technique, which is similar to the triangular gynecology laparoscopic port configuration (**Figure 1**). A 12- or 8.5-mm da Vinci robotic cannula was placed at or above the umbilicus depending on the uterine size; two lateral 5-mm

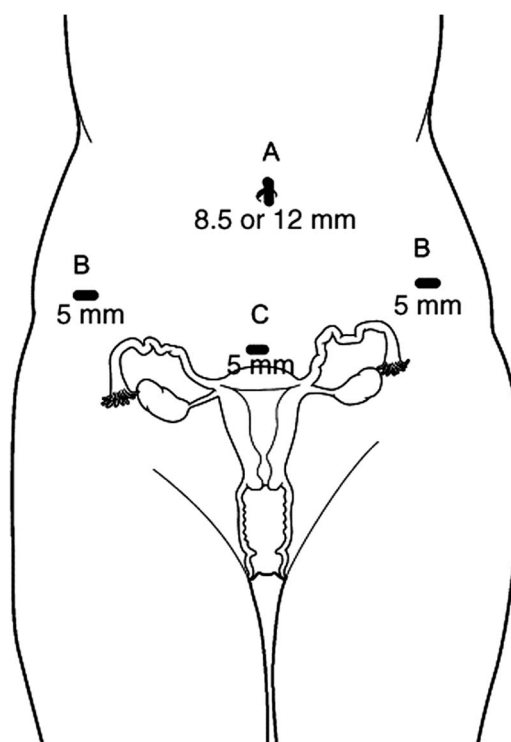


Figure 1. Novel RALH technique with triangular gynecology laparoscopic port configuration and smaller 5-mm robotic cannulas: (A) 8.5- or 12-mm cannula for the endoscope, (B) 5-mm robotic cannulas, (C) 5-mm midsuprapubic cannula.

robotic cannulas were placed 4 to 5 cm above the symphysis pubis at the lateral border of the rectus muscle and 3 to 4 cm below the iliac crest; and one disposable 5-mm cannula was placed 4 to 5 cm above the symphysis pubis in the midline. The 5-mm midsuprapubic port functioned as the primary assistant port. The triangular laparoscopic port configuration is more cosmetic than the original robotic port configuration that uses one 12-mm supraumbilical cannula, three 8-mm robotic cannulas, and one or two lateral 5- to 12-mm cannulas that function as assistant ports.^{3,8}

Patients were placed in the Trendelenburg position, and the patient-side robotic cart was side-docked as previously described.⁹ The procedures were performed with the 12-mm and later with the 8.5-mm endoscope, when it became available in August 2008, and 5-mm EndoWrist instruments. The instruments used in robot arm 1 (the right side of the operative field) were the 5-mm EndoWrist monopolar cautery hook or the 5-mm EndoWrist Harmonic Ace (Ethicon Endo-Surgery, Cincinnati, Ohio). The instrument inserted into robot arm 2 (the left side) was the 5-mm EndoWrist Maryland dissector or the 5-mm Schertel grasper. To facilitate suturing, 5-mm EndoWrist needle drivers were placed in both arms at the end of the procedure.

In place of the traditional RALH lateral assistant port, the 5-mm midsuprapubic port served as the primary assistant

port. Because of the bulky robotic arms and close proximity of the midsuprapubic port to the tissues in the pelvis, short, pediatric-length, 5-mm laparoscopic instruments (Karl Storz-Endoskope, Tuttlingen, Germany) were designed for the bedside assistant to use in the midsuprapubic port. The bedside assistant's instruments are 18 cm compared with the 33- to 36-cm standard adult-length laparoscopic instruments (**Figure 2**). Five instruments for varied gynecologic procedures were manufactured for use in the midsuprapubic port: a serrated grasper, a toothed biopsy forceps, a pair of Metzenbaum scissors, a pair of hooked scissors, and a single tooth tenaculum.

The RALH, AAGL-type IVE hysterectomy⁶ was performed in the standard fashion, with a few modifications. Briefly, the round ligaments were desiccated, followed by the development of the bladder flap anteriorly. The infundibulopelvic or uterine-ovarian ligaments and vessels were desiccated and transected. The uterine arteries and cardinal ligaments were skeletonized, desiccated, and transected. The colpotomy was created along the colpotomizer with the 5-mm monopolar cautery hook at a 75-W cutting current to minimize tissue devascularization. The uterus (and adnexa) was removed through the vagina. Larger uteri were vaginally morcellated. A sterile surgical glove with two folded 4 × 4-inch moist sponges¹⁰ was placed into the vagina as a colpo-pneumo occluder. Two 5-mm needle drivers were placed in the robotic arms, and

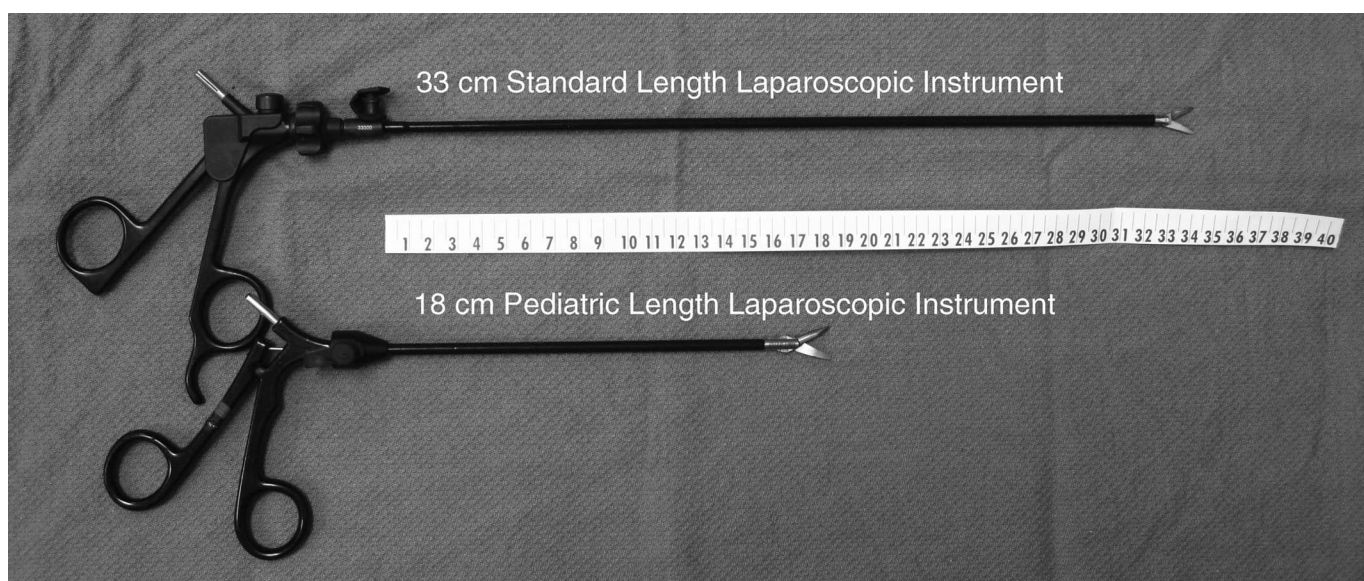


Figure 2. The bedside assistant laparoscopic instruments (Karl Storz Endoskope, Germany) are 18 cm in length, compared with 33 to 36 cm standard length laparoscopic instruments. The short, pediatric-length instruments are for use in the midsuprapubic port. They are nonarticulating and can be connected to monopolar energy.

0-vicryl sutures with CT-2 needles (Ethicon Endo-Surgery, Cincinnati, Ohio) were passed through the vaginal cuff. The vaginal cuff was closed with figure-of-eight sutures, incorporating the uterosacral ligament complexes on each side (**Figure 3**). The CT-2 needles were removed through the vagina, except the last one, which was used to complete the vaginal cuff closure. The last CT-2 needle was straightened and removed through the midsuprapubic port site. Cystoscopy was routinely performed after the RALH and cuff closure. Other indicated procedures were then performed, including natural orifice-assisted laparoscopic appendectomy.¹¹ The abdomen and pelvis were irrigated with saline and inspected for hemostasis, and the pneumoperitoneum was desufflated. The fascia of the 12- or 8.5-mm umbilical port was closed with an interrupted absorbable suture, and the skin incisions were closed with topical skin adhesive.

The patients were observed in a 23-hour outpatient unit with routine postoperative care. Voiding trials were initiated in the postanesthesia care unit or in the morning based on the time of day or the concomitant procedures. Patients were asked to refrain from vaginal intercourse for 6 to 8 weeks. After discharge from the hospital, the patients then returned to the office for postoperative evaluation at 2 weeks, 6 weeks, 6 months, 12 months, and then annually. Peri- and postoperative complications were collected during the hospital stay and during the office visits.

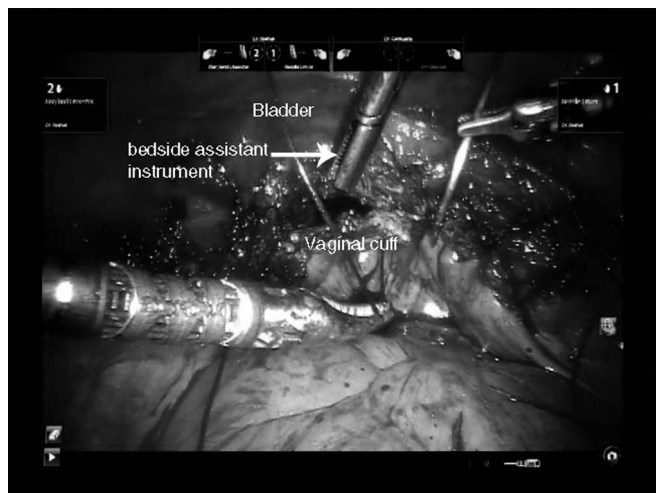


Figure 3. Laparoscopic view of the pelvis after the uterus and cervix were removed. The short 5-mm serrated grasper (arrow) placed through the midsuprapubic port holds the anterior vaginal cuff and assists with closure of the vaginal cuff.

Statistical Analysis

Descriptive statistics were used to analyze the data. Results were reported as mean, standard deviation (SD), and range of values; median (SD) and range of values; or number (N) and percent (%). Analyses were performed using the statistical software package SPSS 20.0 (IBM, Armonk, New York).

RESULTS

Between January 2008 and September 2011, 44 women underwent the novel RALH technique with the triangular gynecology laparoscopic port configuration and 5-mm robotic instruments. Patient demographics and preoperative characteristics are described in **Table 1**. The mean age was 49.9 years (SD 8.8, range 33–70), mean body mass index was 26.1 (SD 5.1, range 19–40), median gravidity was 3 (SD 1.6, range 0–6), and median parity was 1 (SD 1.2, range 0–4). Twenty patients had at least one prior laparoscopy (45.3%), and the median number was 1 (SD 1.8, range 1–7). Seventeen patients had at least one prior laparotomy (38.6%), and the median number was 1 (SD 0.9, range 1–4). The indications for the RALH included pelvic pain (n = 37), abnormal uterine bleeding (n = 29), endometriosis-related symptoms (n = 19), uterine myomas (n = 19), persistent adnexal mass (n = 6), and abnormal cervical cytology (n = 1). The patients often had more than one indication for the surgical procedures.

All of the RALHs were successfully completed with the triangular laparoscopic port configuration and 5-mm technique without conversion to larger ports, video-assisted laparoscopy, or laparotomy. No intraoperative complications occurred during the RALH or during concomitant procedures. All patients had at least one concomitant surgical procedure (**Table 1**). Concomitant procedures included culdoplasty (n = 32), treatment of endometriosis (n = 31), appendectomy (n = 31), enterolysis and lysis of adhesions (n = 27), ureteral stent placement (n = 2), ureteroneocystostomy (n = 1), cystoscopy (n = 44), and sigmoidoscopy (n = 7). The ureteral stent placements were performed because of the patients' endometriosis (n = 2) causing hydroureter; in one of these cases, a segment of the affected ureter required ureteroneocystostomy, and in the other case, extensive ureterolysis and stent placement were sufficient. The mean operative time was 197.1 minutes (SD 53.5, range 131–404). The operative time outlier of 404 minutes was a result of severe endometriosis in the case explained before and required ureteroneocystostomy. The mean EBL was 69.7 mL (SD 146.9, range 20–1000). Only one patient had an EBL of

Table 1.

Patient Demographics

Indications ^a for RALH (N = 44)	N (%)
Pelvic pain	37 (84.1)
Abnormal uterine bleeding	29 (65.9)
Endometriosis-related symptoms	19 (43.2)
Uterine myomas	19 (43.2)
Persistent adnexal mass	6 (13.6)
Abnormal cervical cytology	1 (2.3)
Operative time (min), mean (SD); range	197.1 (53.5); 131–404
Estimated blood loss (mL), mean (SD); range	69.7 (146.9); 20–1000
Concomitant surgeries	N (%)
Cystoscopy	44 (100)
Culdoplasty	32 (72.7)
Appendectomy	31 (70.5)
Treatment of endometriosis	31 (70.5)
Enterolysis and lysis of adhesions	27 (61.4)
Sigmoidoscopy	7 (15.9)
Ureteral stent placement	2 (4.5)
Ureteroneocystostomy	1 (2.3)
Uterine weight (g), mean (SD); range	168.2 (212.7); 50–1405
Length of hospital stay (d), median; range	1 (0.6); 0–2.5
Postoperative complications	N (%)
Urinary tract infection	2 (4.5)
Intravenous site thrombophlebitis	1 (2.3)
Follow-up time (mo), mean (SD); range	40.0 (13.6); 15–59

^aPatients may have more than one indication.

1000 mL, and this was attributed to the complexity of the case and the large size of the uterus (1405 g). The mean uterine weight was 168.2 g (SD 212.7, range 50–1405). The median length of hospital stay was <1 day (SD 0.6, range 0–2.5). No serious peri- or postoperative complications requiring blood transfusion or readmission to the hospital occurred. No patient developed a vaginal cuff dehiscence. Minor postoperative complications occurred in 3 patients and included 2 urinary tract infections and 1 case of intravenous site thrombophlebitis. There were no incidences of port site hernias during the follow-up period. Mean follow-up time was 40.0 months (SD 13.6, range 15–59).

DISCUSSION

The RALH has been performed in a standard manner with a 12-mm endoscope, 8-mm robotic cannulas, and 5- to 12-mm assistant ports since the procedure was first reported in 2002.³ In this case series, we describe a novel technique for RALH with 3 important improvements: (1) a more aesthetic triangular laparoscopic port configuration, (2) use of smaller 5-mm robotic cannulas and instruments, and (3) improved access around the robotic arms for the bedside assistant with the use of short, pediatric-length laparoscopic instruments.

Our experience with the triangular gynecology laparoscopic port configuration and smaller 5-mm robotic cannulas for RALH is comparable with traditional RALH using 8-mm robotic ports and total laparoscopic hysterectomy (TLH). In our previous study comparing traditional RALH and TLH, we found the mean operative time was 276 minutes and 206 minutes, respectively.¹² In the current study, in which we used smaller 5-mm cannulas, our average operative time was 197.1 minutes. The mean EBL (69.7 mL) in the current study was less compared with the mean EBL in the patients who had RALH and TLH (250 mL and 300 mL, respectively).¹² The decrease in the mean operative time and EBL in this study likely reflects the surgeon's and robotic team's increased experience since the first comparative study published in 2009. Perioperative complications were comparable; there were no conversions to laparotomy, and there were no complications requiring blood transfusion or readmission to the hospital. A more recent study by Woelk et al established similar operative times for robotic hysterectomy: 210 minutes when surgeons first started robotic surgery, which decreased to 160 minutes after 3 years.¹³ Studies by Pasic et al and Wright et al similarly reported low intraoperative, surgical site, and medical complication rates between conventional laparoscopic and robotic-assisted hysterectomy.^{4,5} Thus, the novel RALH technique described in this article with conventional laparoscopic configuration and short 5-mm robotic instruments is a viable, functional technique that does not increase operative time, EBL, early postoperative outcomes, or complications.

To maintain the aesthetic conventional laparoscopic configuration (**Figure 1**), the midsuprapubic port is used as the primary assistant port instead of a laterally placed assistant port. However, access to the midsuprapubic port is awkward for the bedside assistant, who needs to navigate around the bulky and constantly moving robotic arms during surgery. An innovation that we have used to facilitate working in the midsuprapubic port is short, pediatric-

length laparoscopic instruments described in this article. These 18-cm laparoscopic instruments overcome the bedside assistant's limited space and were designed to efficiently negotiate and comfortably perform the functions of conventional 33-cm-length laparoscopic instruments.

The importance of these improvements in the RALH technique described in this article is not only cosmetic but may also decrease pain and the risk of port site hernias (PSHs). In the original RALH port configuration,^{3,8} the lateral assistant ports have two disadvantages: pain caused by insertion through the oblique muscles and unaesthetic appearance. After robotic surgery using the original port locations, patients ubiquitously complain of pain at the site of the lateral accessory port. Chou et al compared 10-mm port transumbilical procedures versus transabdominal retrieval of benign adnexal masses, and found that postoperative pain was significantly more with retrieval through a lateral transabdominal location.¹⁴ This finding illustrates that the transabdominal lateral incisions are more painful than the midline incisions. By using a midsuprapubic 5-mm cannula as an accessory port, we eliminated the need for insertion through the lateral abdominal wall muscles. Decreasing musculoskeletal pain allows patients to ambulate with minimal discomfort almost immediately after surgery.

Whether there is a difference in the risk of PSHs between 8-mm versus 5-mm incisions is uncertain. PSH hernias are rare and occur in <1% of laparoscopic surgeries.^{15,16} From the laparoscopic literature, PSH is extremely unusual (0–0.09%) in laparoscopic incisions <10 mm.^{17–20} Only one PSH has been reported at the site of an 8-mm robotic incision.²¹ Robotic assistance theoretically decreases the manipulation of the ports by fixing the port's fulcrum. However, if there is prolonged operative time, multiple insertions of the cannula, and advanced surgical difficulty requiring increased force and torque on the fascia, we have noted that 5-mm ports can become stretched during operative laparoscopy.²⁰

In addition to important clinical outcomes such as pain, risk of PSH, and successful surgical treatment, patients are admittedly concerned about external surgical scars. A recent study of women polled regarding their preference of laparoscopic incisions made by conventional laparoscopy, single-site laparoscopy, and robotic-assisted laparoscopy showed that they significantly preferred the conventional (56.4%) and single-site laparoscopy (41.1%) over the robotic-assisted laparoscopic port placement (2.5%).²² This finding suggests that postoperative body image and patient satisfaction regarding their surgery is

affected to some degree by cosmesis. The novel RALH technique described in this article uses the same incisions as the cosmetically preferable laparoscopic incisions.

We present our modifications to performing the RALH with comparable surgical and patient outcomes. The strengths of this study are the relatively large number of cases for a series on surgical technique. We were able to collect and describe surgical feasibility and outcomes for 44 patients. The major limitation of the study was its descriptive and retrospective design, which limited our data collection and interpretation. Although it is unlikely, another limitation was the short mean follow-up period of 40 months, which may underestimate potential long-term postoperative complications.

The use of robotic assistance in laparoscopy has grown because the technology has enabled surgeons to overcome difficulties of conventional laparoscopy while allowing patients to benefit from minimally invasive surgery. Advances in both equipment and operative technique are optimizing robotic-assisted gynecologic surgery. In this article, we present a novel technique using the more aesthetic conventional laparoscopic port configuration and smaller 5-mm robotic instruments to perform RALH with concomitant procedures. It is safe and feasible and does not impede the surgeon's ability to perform the procedures or affect patient outcomes.

The authors thank Susan Kearney, MHSE, for her editorial assistance and invaluable support in preparing this manuscript.

References:

1. Herb G. Gynecologists urge caution on robotic hysterectomies. *CNBC*. March 14, 2013. Available at: <http://www.cnbc.com/id/100554849>. Accessed June 28, 2013.
2. Intuitive Surgical's CEO Discusses Q4 2012 Results-Earnings Call Transcript. *Seeking Alpha*. Jan 22, 2013. Available at: <http://seekingalpha.com/article/1125941-intuitive-surgical-ceo-discusses-q4-2012-results-earnings-call-transcript>. Accessed June 28, 2013.
3. Diaz-Arrastia C, Jurnalov C, Gomez G, Townsend C Jr. Laparoscopic hysterectomy using a computer-enhanced surgical robot. *Surg Endosc*. 2002;16(9):1271–1273.
4. Pasic RP, Rizzo JA, Fang H, Ross S, Moore M, Gunnarsson C. Comparing robot-assisted with conventional laparoscopic hysterectomy: impact on cost and clinical outcomes. *J Minim Invasive Gynecol*. 2010;17(6):730–738.
5. Wright JD, Ananth CV, Lewin SN, et al. Robotically assisted vs laparoscopic hysterectomy among women with benign gynecologic disease. *JAMA*. 2013;309(7):689–698.

6. Olive DL, Parker WH, Cooper JM, Levine RL. The AAGL classification system for laparoscopic hysterectomy. Classification committee of the American Association of Gynecologic Laparoscopists. *J Am Assoc Gynecol Laparosc*. 2000;7(1):9–15.
7. King LP, Nezhat CH, Nezhat F, Alkatout I, Mettler L, Ferland R, Nezhat CR. Laparoscopic access. In Nezhat's Video-Assisted and Robotic-Assisted Laparoscopy and Hysteroscopy, 4th ed. New York, NY: Cambridge University Press, 2013.
8. Reynolds RK, Advincula AP. Robot-assisted laparoscopic hysterectomy: technique and initial experience. *Am J Surg*. 2006;191(4):555–560.
9. Einarsson JI, Hibner M, Advincula AP. Side docking: an alternative docking method for gynecologic robotic surgery. *Rev Obstet Gynecol*. 2011;4(3–4):123–125.
10. Buescher E, Schipper E, Nezhat C. Laparoscopic equipment and operating room set up. In Nezhat's Video-Assisted and Robotic-Assisted Laparoscopy and Hysteroscopy, 4th ed. New York, NY: Cambridge University Press, 2013.
11. Nezhat C, Datta MS, Defazio A, Nezhat F, Nezhat C. Natural orifice-assisted laparoscopic appendectomy. *JLS*. 2009;13(1):14–18.
12. Nezhat C, Lavie O, Lemyre M, Gemer O, Bhagan L, Nezhat C. Laparoscopic hysterectomy with and without a robot: stanford experience. *JLS*. 2009;13(2):125–128.
13. Woelk JL, Casiano ER, Weaver AL, Gostout BS, Trabuco EC, Gebhart JB. The learning curve of robotic hysterectomy. *Obstet Gynecol*. 2013;121(1):87–95.
14. Chou LY, Sheu BC, Chang DY, et al. Comparison between transumbilical and transabdominal ports for the laparoscopic retrieval of benign adnexal masses: a randomized trial. *Eur J Obstet Gynecol Reprod Biol*. 2010;153(2):198–202.
15. Crist DW, Gadacz TR. Complications of laparoscopic surgery. *Surg Clin North Am*. 1993;73(2):265–289.
16. Boike GM, Miller CE, Spirtos NM, et al. Incisional bowel herniations after operative laparoscopy: a series of nineteen cases and review of the literature. *Am J Obstet Gynecol*. 1995;172(6):1726–1731.
17. Li TC, Saravelos H, Richmond M, Cooke ID. Complications of laparoscopic pelvic surgery: recognition, management and prevention. *Hum Reprod Update*. 1997;3(5):505–515.
18. Montz FJ, Holschneider CH, Munro MG. Incisional hernia following laparoscopy: a survey of the American Association of Gynecologic Laparoscopists. *Obstet Gynecol*. 1994;84(5):881–884.
19. Kadar N, Reich H, Liu CY, Manko GF, Gimpelson R. Incisional hernias after major laparoscopic gynecologic procedures. *Am J Obstet Gynecol* 1993;168(5):1493–1495.
20. Nezhat C, Nezhat F, Seidman DS, Nezhat C. Incisional hernias after operative laparoscopy. *J Laparoendosc Adv Surg Tech A*. 1997;7(2):111–115.
21. Seamon LG, Backes F, Resnick K, Cohn DE. Robotic trocar site small bowel evisceration after gynecologic cancer surgery. *Obstet Gynecol*. 2008;112(2 Pt 2):462–464.
22. Bush AJ, Morris SN, Millham FH, Isaacson KB. Women's preferences for minimally invasive incisions. *J Minim Invasive Gynecol*. 2011;18(5):640–643.