


CASE REPORT

Acute appendicitis in a patient immunised with COVID-19 vaccine: A case report with morphological analysis

Ettore Marconi¹ | Giada Crescioli^{2,3} | Roberto Bonaiuti² | Lavinia Pugliese⁴ |
Raffaella Santi⁵ | Gabriella Nesi⁵ | Elisabetta Cerbai² | Alfredo Vannacci^{2,3}  |
Niccolò Lombardi^{2,3}

¹Health Search, Italian College of General Practitioners and Primary Care, Florence, Italy

²Department of Neurosciences, Psychology, Drug Research and Child Health, Section of Pharmacology and Toxicology, University of Florence, Florence, Italy

³Tuscan Regional Centre of Pharmacovigilance, Florence, Italy

⁴Histopathology and Molecular Diagnostics, Careggi Teaching Hospital, Florence, Italy

⁵Pathology Section, Department of Health Sciences, University of Florence, Florence, Italy

Correspondence

Prof. Alfredo Vannacci, MD, PhD, Department of Neurosciences, Psychology, Drug Research and Child Health, Section of Pharmacology and Toxicology, University of Florence, Viale G. Pieraccini 6-50139 Florence, Italy.
Email: alfredo.vannacci@unifi.it

Although the benefit/risk profile for mRNA COVID-19 vaccines is recognised as extremely favourable, appendicitis is currently considered an adverse event (AE) of special interest. We describe the case of a 58-year-old female who presented with signs and symptoms of appendicitis approximately 48 hours after her first injection of the Pfizer-BioNTech vaccine. Abdominal ultrasound revealed fluid collection in the right iliac fossa and cecal wall thickening. Following the surgical visit, CT scan with contrast showed a distended appendix with thickened walls, suggestive of acute appendicitis. The patient tested negative to upper respiratory COVID-19 reverse transcription-polymerase chain reaction. Clinical trials and observational studies suggest a possible association between appendicitis and COVID-19 vaccines. Th-1 driven granulomatous inflammation reported in our case represents an infrequent nonspecific chronic inflammation of the appendix, especially in the setting of delayed or interval appendectomy. In view of the current paediatric vaccination campaign, we recommend monitoring the safety profile and potential gastrointestinal AEs associated with mRNA COVID-19 vaccines to swiftly manage subjects with gastrointestinal symptoms and prevent potential complications.

KEYWORDS

appendicitis, case report, COVID-19, histology, pharmacovigilance, vaccine

1 | INTRODUCTION

More than 2 years into the COVID-19 pandemic, an unprecedented number of mass vaccination programs are underway in several

countries. To date, over 10 billion doses of vaccine have been administered worldwide.¹

Approval studies have shown that both adenovirus-vectored and messenger RNA (mRNA) COVID-19 vaccines are efficacious and have a very good safety profile. No clinical trials have as yet reported any serious safety hazards, demonstrating a low incidence of serious adverse events (AEs), defined as any untoward medical occurrence which, at any dose, causes patient death, hospitalisation or its prolongation, or else persistent disability/incapacity. Nevertheless, serious AEs may not always emerge in phase 3 studies due to

Ettore Marconi, Giada Crescioli, Alfredo Vannacci and Niccolò Lombardi are the co-first and co-last authors.

The authors confirm that the principal investigator for this article is Niccolò Lombardi.

This is an open access article under the terms of the [Creative Commons Attribution-NonCommercial](https://creativecommons.org/licenses/by-nc/4.0/) License, which permits use, distribution and reproduction in any medium, provided the original work is properly cited and is not used for commercial purposes.

© 2022 The Authors. *British Journal of Clinical Pharmacology* published by John Wiley & Sons Ltd on behalf of British Pharmacological Society.

the small sample size, restrictive inclusion criteria, limited duration of follow-up and study participants at times differing from the general population.

Appendicitis is an acute gastrointestinal condition that is usually most frequent in younger people. Indeed, it commonly occurs between the ages of 10 and 30, with the highest incidence in children and adolescents.² Appendicitis is mentioned in the information fact sheet of the Pfizer-BioNTech vaccine approved by the FDA after an increase in cases in the vaccine arm of a large clinical trial.³ However, no causal relationship has been established nor is it labelled for the other vaccines.⁴ In view of the recent authorization for administering COVID-19 vaccines to the paediatric population, especially mRNA vaccines, more attention must be paid to avoid possible complications related to acute appendicitis in this subset.

2 | CASE DESCRIPTION

In mid-January 2021, a 58-year-old female academic healthcare professional presented to the emergency department (ED) of Careggi University Hospital (Florence, Italy) with pain in the right iliac fossa (RIF). She reported mild pain in the same site 2 weeks earlier, which had subsided with oral [scopolamine](#) and a bland diet. The patient referred to having fever, nausea and vomiting the day before ED admission and that her general practitioner prescribed a penicillin-based antibiotic (amoxicillin/clavulanate), with no improvement in symptoms. She denied diarrhoea, dyspnoea and dysuria. Furthermore, the patient has never tested positive for COVID-19 in the past. The patient stated she had received the 1 dose of Pfizer-BioNTech vaccine approximately 48 hours prior to ED admission (January 16, 2021).

Her past medical history included left quadrantectomy with radiotherapy for breast cancer and, at the time of ED admission, she was on perindopril/amlodipine therapy for arterial hypertension. The patient confirmed she was a nonsmoker, did not drink alcohol or use recreational drugs, nor was she allergic to any drugs.

At physical examination, the abdomen was flat and soft, but painful on deep palpation in RIF and hypogastrium. Blumberg, Murphy and Giordano signs were negative, and peristalsis was normal. ECG revealed normal heart rate, PR and ST-T intervals.

Laboratory tests showed normal haemoglobin levels (12.5 g/dL, range 12.0-16.0), significant leukocytosis ($12.1 \times 10^9/L$, range 4.0-10.0), neutrophilia (78.4%, range 37.0-75.0), high fibrinogen levels (636.0 mg/dL, range 200.0-400.0) and increased prothrombin time (13.3 seconds, range 9.5-12.0). Amylase, lipase, urine analysis, liver and renal function tests were normal. The RT-PCR test for COVID-19, following hospital protocol, was negative.

An abdominal ultrasound scan was requested for suspected appendicitis, which revealed fluid collection in the RIF and thickening of the cecal wall. CT scan with contrast disclosed a distended appendix (maximum thickness 12 mm) with thickened walls, typical of acute appendicitis. The patient was transferred to an inpatient ward and a video-laparoscopic appendectomy was performed under full COVID-19 precautions.

What is already known about this subject

- mRNA COVID-19 vaccines are recognised as extremely effective and safe.
- Post-marketing surveillance of adverse drug reactions is based more on spontaneous reporting and observational studies than on clinical trials.
- Serious adverse events have been suggested as signals in the post-marketing surveillance of COVID-19 vaccines.
- Appendicitis is currently considered a serious adverse event of special interest.

What this study adds

- COVID-19 vaccines induce strong Th1 immune responses.
- A relationship between an increased Th1-driven response and appendicitis has been suggested.
- As in our case, granulomatous inflammation is a common form of nonspecific chronic inflammation of the appendix.

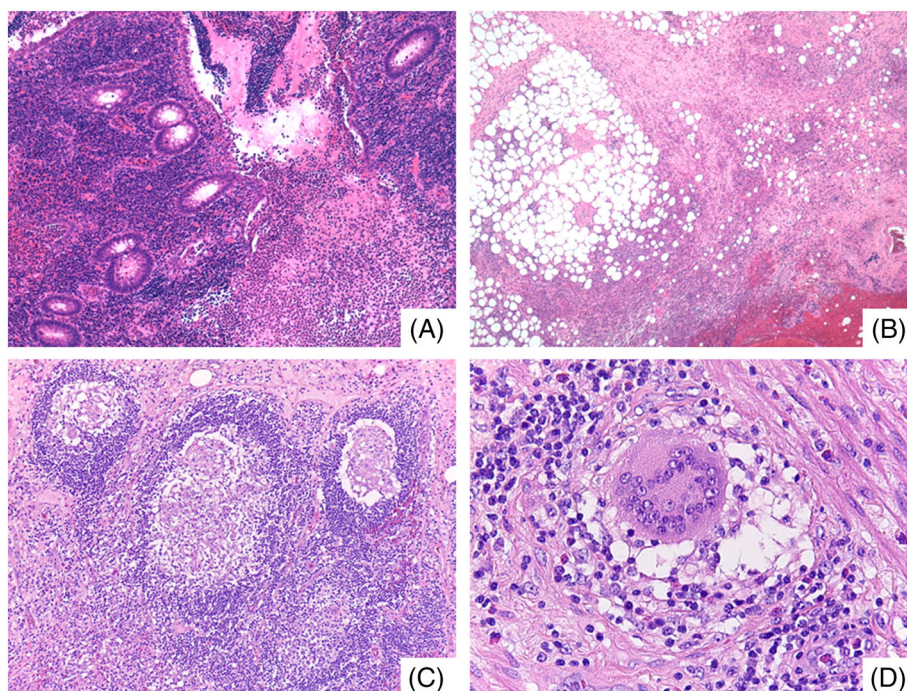
On gross examination, the appendix was swollen, measuring 8 cm in length and 2.5 cm in maximum diameter. Histology showed diffuse acute and chronic inflammatory infiltrates with scattered non-necrotizing granulomas throughout all layers of the appendiceal wall (Figure 1). Of note, numerous granulomas were identified within the germinal centres of lymphoid follicles. The presence of serosal giant cells surrounded by florid granulation tissue was suggestive of prior appendiceal rupture. No foreign bodies, obstructing lesions or infective microorganisms were detected.

The postoperative course was uneventful. After 4 days of hospitalisation (one in the ED and three on the ward), the patient was discharged and prescribed oral amoxicillin/clavulanate, subcutaneous low-molecular-weight heparin and oral acetaminophen/codeine as needed.

3 | FINAL DIAGNOSIS AND OUTCOME

Final diagnosis of the case was acute appendicitis. Applying the 2018 WHO algorithm to assess the causal relationship between mRNA COVID-19 vaccine and acute appendicitis,⁵ (B1 – Temporal relationship is consistent but there is insufficient definitive evidence that vaccine caused the event).

FIGURE 1 A, Prominent mucosal disease with cryptitis, crypt abscess and erosions. Collections of neutrophils were seen in the lumen (H&E, $\times 100$). B, Subserosal layer of the appendix with fibrosis and abundant acute and chronic inflammation (H&E, $\times 100$). C, Non-necrotizing epithelioid granulomas within germinal centres of lymphoid follicles (H&E, $\times 200$). D, Scattered foreign-body type giant cells were also present (H&E, $\times 400$)



3.1 | Follow-up

The patient was followed up at home by her general practitioner, with no clinical complications. The patient was administered with the II (February 6, 2021) and III doses (October 27, 2021) of mRNA COVID-19 vaccine without the occurrence of any other AEs.

4 | DISCUSSION

Clinical trials have shown that most COVID-19 vaccines are efficacious, with a satisfactory safety profile.⁶ Trials on the Pfizer-BioNTech vaccine have revealed a mild imbalance between vaccinated and placebo groups with respect to the number of cases of hypersensitivity reactions, acute myocardial infarction, cerebrovascular accidents and appendicitis.⁷ It is unclear, however, whether the risk of appendicitis is higher in the vaccinated than in the general population. Evidence from literature is scarce, with conflicting results, and global longitudinal studies are required to clarify any possible relationship.

Using data from the largest healthcare organisation in Israel, Barda et al⁷ noted that such a risk was higher in vaccinated than non-vaccinated patients (risk ratio 1.40, 95% confidence interval [CI] 1.02 to 2.01, risk difference 5.0 events per 100 000 persons, 95% CI 0.3 to 9.9). These authors also examined records from over 240 000 infected subjects to estimate the effects of documented SARS-CoV-2 infection on the incidence of the same AEs and found that SARS-CoV-2 infection was not associated with any meaningful events, including appendicitis.

Li et al⁸ performed a multinational network cohort study to quantify the background incidence rates of 15 pre-specified AEs that might need evaluation after COVID-19 vaccination. Based on electronic

health records and health claims data from eight countries (Australia, France, Germany, Japan, the Netherlands, Spain, the United Kingdom and the United States), they found that anaphylaxis, Bell's palsy, appendicitis and immune thrombocytopenia were essentially rare in all age groups. Notwithstanding the considerable variability of AE rates within age and sex subgroups, appendicitis was more common in younger populations.

From a pharmacovigilance perspective, Mitchell et al⁴ reviewed all cases of appendicitis following administration of COVID-19 vaccines reported to VigiBase (WHO). The authors observed an apparent increase of such cases within 4 days of vaccination and a possible dose-response relationship.

Globally, the incidence of appendicitis is approximately 11 cases per 10 000 life years,⁹ with the highest incidence in late childhood and early adulthood. The occurrence of appendicitis is low in the neonatal period but most frequent between ages 12 and 18, where it is the leading cause of abdominal surgical emergency.

The exact pathophysiology of appendicitis, as well as any potential causal association with COVID-19 vaccines, is still unclear. Appendicoliths, lymphoid hyperplasia and lymphadenopathy have been identified as relevant causes of appendicitis.⁴ Although lymphadenopathy is listed among AEs of COVID-19 vaccines, abdominal lymphadenopathies are greatly underreported since they are usually diagnosed only after abdominal imaging. Immune response could also contribute to the onset of appendicitis. COVID-19 status should also be considered, as a previous infection may enhance immune response to vaccination.¹⁰ Interestingly, COVID-19 vaccines induce strong Th1 immune responses and a possible relationship has been suggested between an increased Th1-driven response and appendicitis. In particular, Th1 responses and cytotoxic cells may provide the background for the development of gangrenous and perforated appendicitis, in

contrast to the Th2 immune response observed in phlegmonous appendicitis.¹¹

Granulomatous appendicitis is seen in less than 2% of appendectomy specimens. However, granulomatous inflammation represents a common form of nonspecific chronic inflammation of the appendix, especially in the setting of delayed or interval appendectomy, as in our case.¹² Pathologists should be aware of this inflammatory pattern, and not to misinterpret findings as Crohn's disease, infectious disorders, sarcoidosis or foreign-body reactions without relevant clinical history.¹³

Recently, an observational study aimed to describe US surveillance data collected both through the Vaccine Adverse Event Reporting System (VAERS) and through v-safe during the first 6 months of the US COVID-19 vaccination program found a total of 383 cases of appendicitis associated with mRNA vaccines, accounting for 1.3 reports per million doses administered. Based on available real-world data, appendicitis is currently considered an AE of special interest.¹⁴

At the end of March 2022, Kildegaard et al in Denmark performed a nationwide cohort study to assess the risk of appendicitis after receiving an mRNA COVID-19 vaccine compared with the risk of appendicitis in unvaccinated individuals.¹⁵ Although authors reported several limitations, they found no association between immunisation with mRNA-based COVID-19 vaccines and appendicitis, and they stated that further studies from different settings are needed to clarify this association.

While clinical trials on the efficacy and safety of COVID-19 vaccines have not yet involved the paediatric population, the European Medicines Agency has recommended extending the use of the Pfizer-BioNTech vaccine to children aged 5 to 11.¹⁶ Since limited information is available on acute appendicitis following immunisation, especially in children, healthcare providers and national health services should be aware of the potential relationship between COVID-19 vaccines and acute appendicitis.

5 | CONCLUSIONS

The present case highlights the risk of acute appendicitis as an event potentially associated with COVID-19 vaccines. Considering the ongoing COVID-19 vaccination campaign aimed at younger individuals, we recommend monitoring safety profiles and potential AEs especially in children so that any gastrointestinal symptoms following immunisation can be rapidly diagnosed and managed.

ACKNOWLEDGMENTS

The authors declare that this research was conducted in the absence of any commercial or financial relationship that could be construed as a potential conflict of interest. This research did not receive any specific grant from funding agencies in the public, commercial or not-for-profit sectors. Open Access Funding provided by Università degli Studi di Firenze within the CRUI-CARE Agreement.

COMPETING INTERESTS

All authors have no competing interests to disclose.

CONTRIBUTORS

N.L. conceived the original idea. E.M., G.C. and N.L. wrote the manuscript. L.P., R.S. and G.N. performed the morphological analyses. R.B., E.C. and A.V. contributed to the analyses of the results and revised the manuscript for critical content. All authors revised and approved the manuscript.

DATA AVAILABILITY STATEMENT

Data are available upon reasonable request to the corresponding author.

ORCID

Alfredo Vannacci  <https://orcid.org/0000-0001-5259-2026>

REFERENCES

1. Our World In Data. Coronavirus (COVID-19) Vaccinations. Published 2022. Accessed March 21, 2022. https://ourworldindata.org/covid-vaccinations?country=OWID_WRL
2. di Saverio S, Podda M, de Simone B, et al. Diagnosis and treatment of acute appendicitis: 2020 update of the WSES Jerusalem guidelines. *World J Emerg Surg.* 2020;15(1):27. doi:10.1186/S13017-020-00306-3
3. FDA. Comirnaty and Pfizer-BioNTech COVID-19 Vaccine. Published 2022. Accessed March 21, 2022. <https://www.fda.gov/emergency-preparedness-and-response/coronavirus-disease-2019-covid-19/comirnaty-and-pfizer-biontech-covid-19-vaccine#additional>
4. Mitchell J, Yue QY. Appendicitis as a possible safety signal for the COVID-19 vaccines. *Vaccine X.* 2021;9:100122. doi:10.1016/j.jvaxc.2021.100122
5. WHO World Health Organization. *Causality Assessment of an Adverse Event Following Immunization (AEFI): User Manual for the Revised WHO Classification.* Second Edition.; 2018. Accessed March 22, 2022. chrome-extension://efaidnbmninnibpcapjcgclcfndmkaj/viewer.html?pdfurl=https%3A%2F%2Fwww.who.int%2Fvaccine_safety%2Fpublications%2Faeifi_manual.pdf&clen=1956918&chunk=true.
6. Polack FP, Thomas SJ, Kitchin N, et al. Safety and efficacy of the BNT162b2 mRNA Covid-19 vaccine. *N Engl J Med.* 2020;383(27):2603-2615. doi:10.1056/NEJMoa2034577
7. Barda N, Dagan N, Ben-Shlomo Y, et al. Safety of the BNT162b2 mRNA Covid-19 vaccine in a nationwide setting. *N Engl J Med.* 2021;385(12):1078-1090. doi:10.1056/NEJMoa2110475
8. Li X, Ostroplets A, Makadia R, et al. Characterising the background incidence rates of adverse events of special interest for covid-19 vaccines in eight countries: multinational network cohort study. *BMJ.* Published online June 14, 2021;n1435. doi:10.1136/bmj.n1435
9. Ferris M, Quan S, Kaplan BS, et al. The global incidence of appendicitis. *Ann Surg.* 2017;266(2):237-241. doi:10.1097/SLA.0000000000002188
10. Manisty C, Otter AD, Treibel TA, et al. Antibody response to first BNT162b2 dose in previously SARS-CoV-2-infected individuals. *Lancet.* 2021;397(10279):1057-1058. doi:10.1016/S0140-6736(21)00501-8
11. Rubér M, Berg A, Ekerfelt C, Olaison G, Andersson RE. Different cytokine profiles in patients with a history of gangrenous or phlegmonous

- appendicitis. *Clin Exp Immunol*. 2005;143(1):117-124. doi:[10.1111/j.1365-2249.2005.02957.x](https://doi.org/10.1111/j.1365-2249.2005.02957.x)
12. Guo G, Greenson JK. Histopathology of interval (delayed) appendectomy specimens. *Am J Surg Pathol*. 2003;27(8):1147-1151. doi:[10.1097/00000478-200308000-00013](https://doi.org/10.1097/00000478-200308000-00013)
 13. Tucker ON, Healy V, Jeffers M, Keane FBV. Granulomatous appendicitis. *Surgeon*. 2003;1(5):286-289. doi:[10.1016/S1479-666X\(03\)80047-1](https://doi.org/10.1016/S1479-666X(03)80047-1)
 14. Rosenblum HG, Gee J, Liu R, et al. Safety of mRNA vaccines administered during the initial 6 months of the US COVID-19 vaccination programme: an observational study of reports to the Vaccine Adverse Event Reporting System and v-safe. *Lancet Infect Dis*. 2022;22(6):802-812. doi:[10.1016/S1473-3099\(22\)00054-8](https://doi.org/10.1016/S1473-3099(22)00054-8)
 15. Kildegaard H, Ladebo L, Andersen JH, et al. Risk of appendicitis after mRNA COVID-19 vaccination in a Danish population. *JAMA Intern Med*. 2022 Apr 25;e221222. doi:[10.1001/jamainternmed.2022.1222](https://doi.org/10.1001/jamainternmed.2022.1222)
 16. EMA. Comirnaty COVID-19 vaccine: EMA recommends approval for children aged 5 to 11. Published 2022. Accessed March 21, 2022. [https://www.ema.europa.eu/en/news/comirnaty-covid-19-vaccine-ema-recommends-approval-children-aged-5-11#:~:text=EMA's%20human%20medicines%20committee%20\(CHMP,children%20aged%2012%20and%20above](https://www.ema.europa.eu/en/news/comirnaty-covid-19-vaccine-ema-recommends-approval-children-aged-5-11#:~:text=EMA's%20human%20medicines%20committee%20(CHMP,children%20aged%2012%20and%20above)

How to cite this article: Marconi E, Crescioli G, Bonaiuti R, et al. Acute appendicitis in a patient immunised with COVID-19 vaccine: A case report with morphological analysis. *Br J Clin Pharmacol*. 2022;1-5. doi:[10.1111/bcp.15421](https://doi.org/10.1111/bcp.15421)