

# Safety and Efficacy of Percutaneous Pedicle Screw Placement Using a Power Tool

Atsushi Kojima<sup>1,3)</sup>, Atsushi Fujii<sup>2)</sup>, Shigeta Morioka<sup>2)</sup>, Yoshiaki Torii<sup>2)</sup>, Kenichiro Arai<sup>3)</sup> and Yutaka Sasao<sup>4)</sup>

1) Spine Center, Funabashi Orthopaedic Hospital, Chiba, Japan

2) Department of Orthopaedic Surgery, St. Marianna University, School of Medicine, Kanagawa, Japan

3) Department of Orthopaedic Surgery, Saint Joseph's Hospital, Kanagawa, Japan

4) Department of Orthopaedic Surgery, International University of Health and Welfare Shioya Hospital, Tochigi, Japan

## Abstract:

**Introduction:** This study compared traditional manual methods and power tool use with regard to the speed and accuracy of percutaneous pedicle screw (PPS) placement and determined the advantages associated with the use of power tools.

Although the indication of PPS placement in minimally invasive spine stabilization (MIS<sub>t</sub>) procedures has been recently expanded, there are no reports on PPS insertion using a power tool.

**Methods:** We evaluated 35 patients who underwent PPS insertion using a power tool during MIS<sub>t</sub> procedures. On one side, PPS insertion was performed using the manual (M) method, whereas on the contralateral side, insertion was performed using the power tool (P) method. We assessed the number of implanted PPSs, time taken to implant PPSs after guidewire insertion, and accuracy of PPS placement as ranked postoperatively using computed tomography images.

**Results:** A total of 294 PPSs were inserted (147 using the M method and 147 using the P method). The mean PPS insertion time was 10.5 s using the P method and 27.4 s using the M method. The time required for inserting a screw using the P method remained consistent in the range of 10-15 s, whereas the time using the M method tended to increase from the second screw onward, with a range of 25-30 s. With regard to PPS insertion accuracy, a 2 mm or more pedicle breach was noted in 2 (1.4%) case after the P method and in 2 (1.4%) case after the M method.

**Conclusions:** PPS placement using power tools has the potential to save the surgical time during MIS<sub>t</sub> procedures.

## Keywords:

Minimally invasive spine stabilization: MIS<sub>t</sub>, Percutaneous Pedicle Screw: PPS, Power tool

Spine Surg Relat Res 2018; 2(1): 60-64  
dx.doi.org/10.22603/ssrr.2017-0029

## Introduction

A number of recent reports on the effectiveness and safety of pedicle screws (PSs) have been published, and all of these have involved manual screw insertion<sup>1-8)</sup>. In addition, many reports have investigated the effectiveness of percutaneous pedicle screws (PPSs)<sup>9-12)</sup>. Power tools are being used in the field of orthopedic surgery for screw insertion into fractured bones or for joint surgeries involving the extremities. However, power tools are not commonly used in spinal surgery.

Seehausen et al. suggested that the use of power tools to place pedicle screws can provide shorter fluoroscopy times and lower revision rates than the use of manual tools and

that both techniques had similar low risks of injury to patients<sup>13)</sup>. We have used power tools in many cases involving open surgeries or minimally invasive spine stabilization (MIS<sub>t</sub>) procedures. We immediately noticed stress reductions in the surgeon's neck and shoulder region during and following surgery. However, some surgeons may be hesitant to use power tools for PS placement because of various safety concerns. To our knowledge, there has been no published clinical report on the effectiveness of PPS placement using power tools.

Therefore, this study compared traditional manual methods and power tool use with regard to the speed and accuracy of PPS placement and assessed the advantages associated with the use of power tools.

Corresponding author: Atsushi Kojima, akojima@fff.or.jp

Received: April 11, 2017, Accepted: July 4, 2017

Copyright © 2018 The Japanese Society for Spine Surgery and Related Research

## Materials and Methods

This study received an exemption by the institutional review board of our institute. Among the MIST procedures performed between September 2014 and April 2016, we used power tools for PPS placement in 35 patients (12 men and 23 women). The mean age of the patients was 75.6 years (range, 39-90 years). There was pyogenic spondylitis in 5 cases, degenerative spinal disease in 4 cases, traumatic burst fracture in 1 case, and osteoporotic vertebral fracture (OVF) in 25 cases. The average of bone mineral density (BMD) at lateral lumbar spine for 25 OVF cases is 64% of young adult mean (YAM). In addition, the same surgeon (AK) performed all of the procedures.

After making a 20-mm long vertical incision and opening the myofascia, PPS placement points were determined via finger navigation. The lateral side of facet joint, the intersection of lateral side of superior vertebral notch, and base point of transverse process were identified by the surgeon's fingertip; then, the probe was out on the point after checking its shape. If the tip of probe was located at the lateral side of pedicle by checking with AP view of fluoroscopy, the probe could be inserted into the pedicle. Next, a Stryker MANTIS cannulated probe (Stryker Instruments, Kalamazoo, MI) was used to make a screw hole for guidewire insertion<sup>14</sup>.

The procedure was the same for all PPS insertions to the stage of guidewire insertion. However, after guidewire insertion, the manual (M) method was used to implant a PPS on one side of the vertebra and the power tool (P) method was used on the other side (Fig. 1). We used a system that consisted of a Stryker ES2 for the PS and a RemB Universal Driver Corded Hand Piece (Stryker Instruments) as the power tool, which was set to operate at 300 rpm using a CORE unit controller (Stryker Instruments) to insert the PPS at low revolution via the guidewire.

The following variables were examined in this study: (1) number of implanted PPSs; (2) time taken to implant a PPS

after guidewire insertion; (3) accuracy of PPS placement as determined postoperatively with computed tomography (CT) images using the grade classification described by Ravi et al.<sup>15</sup>

Student's t-test was used to compare the methods. A P-value of <0.05 was considered to indicate a significant difference. All statistical analyses of recorded data were performed using the Excel Statistical Software Package (Ekuseru-Toukei 2012; Social Survey Research Information Co., Ltd., Tokyo, Japan).

## Results

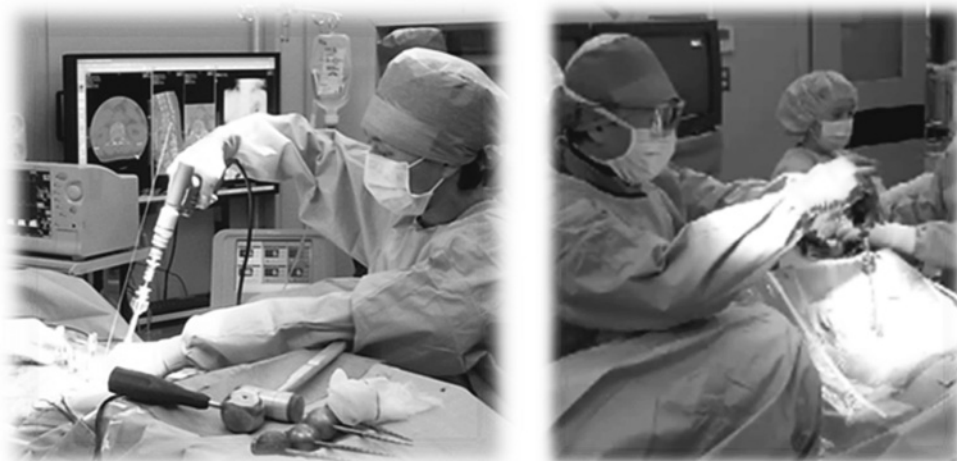We implanted a total of 294 PPSs. Of the 294 PPSs, 147 were implanted using the P method and 147 were implanted using the M method (Table 1). The time taken to implant a PPS after the installation of the guidewire was  $10.5 \pm 2.92$  s using the P method and  $27.4 \pm 7.31$  s using the M method; the time taken using the P method was significantly shorter than that using the M method ( $P < 0.01$ ) (Fig. 2).

With regard to moving from one screw to the next during a particular surgery, the time required for inserting a screw using the P method remained consistent in the range of 10-15 s, whereas the time using the M method tended to increase from the second screw onward, with a range of 25-30 s (Fig. 3).

In addition, the P and M methods each had four inaccurately placed screws according to the Ravi grades of pedicle breaches<sup>15</sup>. Breaches of  $\geq 2$  mm (Ravi grade 3 or 4) were observed 2 patients (1.4%) using both methods. Thus, there were no significant differences between the two methods in terms of screw placement accuracy (Table 1).

## Discussion

Elliott et al. performed a study on the use of power tools versus hand tools for the bones of the extremities and found that power tools reduced the time required to insert cortical



**Figure 1.** Using a power tool (left) and a manual driver (right).

bone screws without altering thread patterns or diminishing the surgeon's control of penetration<sup>16</sup>. In addition, Ansell and Scales<sup>17</sup> demonstrated that a lower total torque was required by continuous rotation produced from a power drill than by intermittent rotation produced from hand tools. Our findings indicate that PPS placement using the P method is 2.5x faster than PPS placement using the M method. In addition, placement accuracy determined by postoperative CT assessment does not differ between the two methods. We also found that the time taken to implant PPSs in multiple vertebrae tended to be longer for the M method than for the P method because the number of screws to be implanted increased.

According to a survey of the Scoliosis Research Society, spine surgeons appear to be at increased risk of overuse injuries of the hand, wrist, shoulder, and cervical spine com-

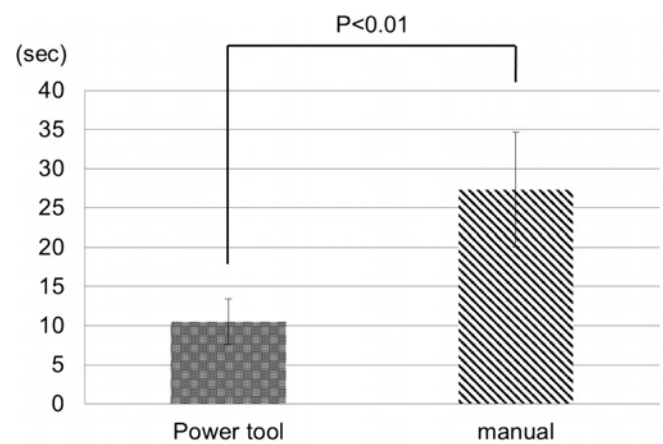
pared to the risk in the general population<sup>18</sup>.

In addition, cadaveric testing for PS placement with and without power tools found that placement with power tools required 95% less surgeon effort, was 55% faster, and was associated with 38% less wobbling during insertion than placement using manual method<sup>19</sup>. The P method allows safe PPS placement at a low rotary speed and is expected to decrease occupational health problems among spinal surgeons, as the use of power tools reduces fatigue at the upper extremities during sequential placement.

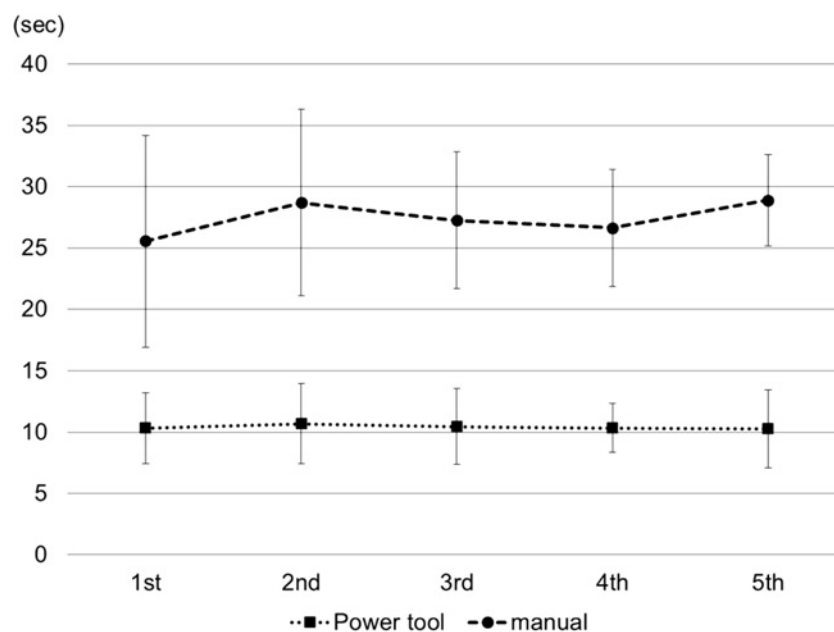
A previous report revealed that PS placement using power tools was as accurate in the hands of surgeons with <15 years of experience as in those with ≥15 years of experience<sup>20</sup>. The extent of the surgeon's experience is not an issue for safe and proper placement of PPSs using power tools because power tools can operate at a low rotary speed

**Table 1.** The Number of Percutaneous Pedicle Screws (PPSs) Placed and the Placement Accuracy Using the Power Tool and Manual Methods.

|                              | Power tool                             | Manual                               |
|------------------------------|--|--------------------------------------|
| Number of PPSs               | 147                                    | 147                                  |
| Grade 1<br>(No breach)       | 141                                    | 142                                  |
| Grade 2<br>(<2-mm breach)    | 4<br>(3 lateral and 1 caudal breaches) | 3<br>(2 lateral and 1 caudal breach) |
| Grade 3<br>(2-4-mm breach)   | 1<br>(1 lateral breach)                | 2<br>(2 lateral breaches)            |
| Grade 4<br>(>4-mm breach)    | 1<br>(1 lateral breach)                | 0                                    |
| Frequency of<br>≥2-mm breach | 1.4%                                   | 1.4%                                 |



**Figure 2.** Time taken to place a percutaneous pedicle screw using the power tool and manual methods.



**Figure 3.** Time required for to place each screw placement during percutaneous pedicle screw placement using the power tool and manual methods with multiple screws.

of 300 rpm without veering from the direction of the guidewire. However, the guidewire should be inserted correctly.

During the MIST procedure, the guidewire can bend when the screw is being manually inserted, deforming the screw tip; however, this is rare. This can occur because of malalignment between the axis of the guidewire and the axis of the screwdriver or because of involuntary movement of the wrist or forearm during manual placement. If the problem is due to axis malalignment, the PPS can be implanted properly by strictly following the guidewire, regardless of whether placement is performed manually or using a power tool. However, if the problem is because of the slight slip of the wrist or forearm when manually inserting the PPS, surgeons should try to hold the arm steady. This becomes progressively difficult when the procedure is repeated for each new screw during the surgery. In this regard, power tools can be advantageous, as the surgeon needs only to follow the guidewire while firmly holding the power tool, reducing the probability of veering from the axis or slipping during screw insertion.

These preventive techniques might also favorably influence the postoperative issue of screw loosening because of unwitting enlargement of the screw hole at the original screw insertion. Seehausen et al. conducted a study on open posterior spinal fixation involving comparisons between 4,542 PSs implanted using power tools (283 patients) and 1,870 PSs implanted manually (159 patients). The authors found that the number of PSs implanted using power tools requiring removal or revision was only one-sixth of that implanted manually requiring removal or revision and that the fluoroscopy time using power tools was two-third of that using a manual method<sup>16</sup>.

By simultaneously maintaining placement accuracy and avoiding radiological exposure, the use of power tools for PPS placement appears to be beneficial to patients, surgeons, and surgical staff. Therefore, this approach will further contribute to the development of MIST procedures.

## Conclusion

The PPS insertion accuracy is similar between the use of power tools and manual methods. However, the insertion time is much lower and the effort required for multiple insertions tends to be lower with power tools than with manual methods. PPS placement using power tools has the potential to save the surgical time of MIST procedures.

## Disclosure

We have no disclosure and financial support.

Acknowledgments: I would like to express my deepest gratitude to Prof. David L. Skaggs whose comments and suggestions were of inestimable value for my study.

Conflicts of Interest: The authors declare that there is no conflict of interest.

## References

1. Brown CA, Lenke LG, Bridwell KH, et al. Complications of pediatric thoracolumbar and lumbar pedicle screws. *Spine*. 1998; 23(14): 1566-71.
2. Kim YJ, Lenke LG, Bridwell KH, et al. Free hand pedicle screw placement in the thoracic spine: is it safe? *Spine*. 2004; 29(3): 333-42.
3. Esses SI, Sachs BL, Dreyzin V. Complications associated with the technique of pedicle screw fixation: a selected survey of ABS members. *Spine*. 1993; 18(15): 2231-38.
4. Kim YJ, Lenke LG, Cho SK, et al. Comparative analysis of pedicle screw versus hook instrumentation in posterior spinal fusion of adolescent idiopathic scoliosis. *Spine*. 2004; 29(18): 2040-48.
5. Liljenqvist UR, Halm HF, Link TM. Pedicle screw instrumentation of the thoracic spine in idiopathic scoliosis. *Spine*. 1997; 22(19): 2239-45.
6. Lonstein JE, Denis F, Perra JH, et al. Complications associated with pedicle screws. *J Bone Joint Surg Am*. 1999; 81(11): 1519-28.
7. Suk SI, Kim WJ, Lee SM, et al. Thoracic pedicle screw fixation in spinal deformities: are they really safe? *Spine*. 2001; 26(18): 2049-57.
8. Suk SL, Lee CK, Kim WJ, et al. Segmental pedicle screw fixation in the treatment of thoracic idiopathic scoliosis. *Spine*. 1995; 20: 1399-1405.
9. Heintel TM, Berglehner A, Meffert R. Accuracy of percutaneous pedicle screws for thoracic and lumbar spine fractures: a prospective trial. *Eur Spine J*. 2013; 22(3): 495-502.
10. Nakashima H, Sato K, Ando T, et al. Comparison of the percutaneous screw placement precision of isocentric C-arm 3-dimensional fluoroscopy-navigated pedicle screw implantation and conventional fluoroscopy method with minimally invasive surgery. *J Spinal Disord Tech*. 2009; 22(7): 468-72.
11. Raley DA, Mobbs RJ. Retrospective computed tomography scan analysis of percutaneously inserted pedicle screws for posterior transpedicular stabilization of the thoracic and lumbar spine: accuracy and complication rates. *Spine*. 2012; 37(12): 1092-1100.
12. Spitz SM, Sandhu FA, Voyadzis JM. Percutaneous "K-wireless" pedicle screw fixation technique: an evaluation of the initial experience of 100 screws with assessment of accuracy, radiation exposure, and procedure time. *J Neurosurg Spine*. 2015; 22(4): 422-431.
13. Seehausen D, Skaggs D, Andras L, et al. Safety and efficacy of power-assisted pedicle tract preparation and screw placement. *Spine Deform*. 2015; 3(2): 159-65.
14. Ishii K, Kaneko Y, Funao H, et al. A novel percutaneous guide wire (S-Wire) for percutaneous pedicle screw insertion: its development, efficacy, and safety. *Surg Innov*. 2015; 22(5): 469-73.
15. Ravi B, Zahrai A, Rampersaud R. Clinical accuracy of computer-assisted two-dimensional fluoroscopy for the percutaneous placement of lumbar pedicle screws. *Spine*. 2011; 36(1): 84-91.
16. Elliott D. The use of power tools in the insertion of cortical bone screws. *Injury*. 1992; 23(7): 451-2.
17. Ansell RH, Scales JT. A study of some factors which affect the strength of screws and their insertion and holding power in bone. *J Biomech*. 1968; 1(4): 279-302.
18. Auerbach JD, Weidner ZD, Milby AH, et al. Musculoskeletal disorders among spine surgeons: results of a survey of the Scoliosis Research Society membership. *Spine*. 2011; 36(26): E1715-21.

19. Mahajan A, Vadapalli S, Steele B. Biomechanical evaluation of the POWEREASE™ taper/driver system. Medtronic Internal White Paper. 2012; PMD0007528-1.0: 1-4.
20. Strain J. Stryker power tools for pedicle screw insertion: results of testing. Stryker Spine White Paper. 2012; 1-11.

Spine Surgery and Related Research is an Open Access article distributed under the Creative Commons Attribution - NonCommercial - NoDerivatives 4.0 International License. To view the details of this license, please visit (<https://creativecommons.org/licenses/by-nc-nd/4.0/>).