

Clinical Experience with a Hybrid Procedure Using the Adherent Clot Catheter for Salvage of Thrombosed Hemodialysis Access: A Comparison with the Standard Fogarty Balloon Catheter

Yu Sung Yang¹, Kyu Dam Han¹, Eun Hye Choi¹, Young Sam Park¹, Yeon Ho Seo², and Cheol Seung Kim¹

¹Division of Vascular and Endovascular Surgery, Department of Surgery, ²Department of Chest Surgery, Presbyterian Medical Center, University of Seonam College of Medicine, Jeonju, Korea

Purpose: This study aimed to compare the efficacy of two different catheters in hybrid surgery for salvage of thrombosed hemodialysis accesses.

Materials and Methods: The hybrid salvage procedure (surgical thrombectomy followed by endovascular angioplasty) of the thrombosed hemodialysis access, was performed using adherent clot (AC) catheter in 140 cases and Fogarty balloon catheter in 68 cases. Procedure-related outcomes such as the clot removal status, clinical success, complications, and primary patency rates were analyzed retrospectively.

Results: The proportion of cases with good clot removal scores in the AC catheter and Fogarty balloon catheter groups was 77.9% and 91.2%, respectively ($P=0.018$). Clinical success was achieved in 90.7% of the cases in the AC catheter group and in 98.5% of the cases in the balloon catheter group ($P=0.035$). The mean patency rates of the two groups were 50.7% and 63.2% at 3 months, 40.7% and 47.1% at 6 months, and 17.9% and 19.1% at 12 months. The complication rates (12.1% and 5.9%) and primary patency rates between the two catheters were not statistically different ($P=0.328$). On the analysis of the patency rate on access type of autologous ($P=0.169$) and prosthetic graft ($P=0.423$), there was no significant difference between the two catheter groups.

Conclusion: In terms of clot removal and clinical success, the AC catheter did not demonstrate better outcomes than the Fogarty balloon catheter. However, primary patency was not related to the type of catheter. Adherent clot catheter can be a useful alternative to Fogarty balloon catheter for thrombosed hemodialysis access.

Key Words: Fogarty balloon, Thrombosis, Vascular access, Thrombectomy

Received October 9, 2014

Revised (1st) November 16, 2014

(2nd) December 15, 2014

Accepted December 26, 2014

Corresponding author: Cheol Seung Kim
Division of Vascular and Endovascular Surgery, Department of Surgery, Presbyterian Medical Center, University of Seonam College of Medicine, 365 Seowon-ro, Wansan-gu, Jeonju 560-750, Korea
Tel: 82-63-230-1408
Fax: 82-63-230-1409
E-mail: cskimmd@hotmail.com
Conflict of interest: None.

Copyright © 2015, The Korean Society for Vascular Surgery

This is an Open Access article distributed under the terms of the Creative Commons Attribution Non-Commercial License (<http://creativecommons.org/licenses/by-nc/3.0>) which permits unrestricted non-commercial use, distribution, and reproduction in any medium, provided the original work is properly cited.

Vasc Spec Int 2015;31(1):25-31 • <http://dx.doi.org/10.5758/vsi.2015.31.1.25>

INTRODUCTION

Vascular access thrombosis, the most common complication in hemodialysis patients, leads to morbidity, hospi-

talization, salvage procedures, and increased costs [1,2]. A thrombosed access can be managed surgically or with an endovascular technique, or a combination of the two [3,4]. In our hospital, we performed a hybrid salvage procedure,

which combined surgical thrombectomy with endovascular treatment. A Fogarty balloon catheter is traditionally used for surgical thrombectomy. We tried a different clot removal catheter (adherent clot [AC] catheter) for our hybrid salvage procedures because the catheter is designed for adherent clot removal in the peripheral vasculature and is also radiopaque, thus applicable to the hybrid operation setting. To date, no studies have been published regarding the differences in type of catheter used for salvage of thrombosed hemodialysis access.

This study aimed to compare the efficacy of the AC catheter for clot removal in thrombosed hemodialysis access with that of the standard Fogarty balloon catheter and to determine their post-procedural patencies.

MATERIALS AND METHODS

1) Patients and design

A total of 116 consecutive patients who underwent a hybrid salvage procedure for thrombosed vascular access at Jesus Hospital, Jeonju, Korea from August 2012 to February 2014 were enrolled. This study is a retrospective study from prospectively collected data. The patients' demographic data, types of vascular access, hemodialysis duration, clot removal status, clinical success, and procedure-related

complications were collected. We reviewed radiologic image records to identify the location and number of vascular stenoses in each case. All of the procedures that were performed were by hybrid means.

The surgical procedure was performed in the hybrid operating suite with a fixed digital angiography equipment (AlluraXper FD20/20; Philips, Heide, Netherlands). The surgical technique consisted of thrombectomy with either a AC catheter (ACC 4/6; Edwards Lifesciences, Irvine, CA, USA) or a Fogarty balloon catheter, which was selected randomly for each procedure. The size of the AC catheter was 4 Frx6 mmx80 cm. An intraoperative fistulography was performed to confirm the completion of thrombectomy and to find the cause of access failure. Stenoses were treated with a one-stage endovascular procedure. Failed thrombectomies led to access abandonment and placement of a short-term dialysis catheter or surgical revision. The treating nephrologist and the vascular surgeon both monitored the access during the follow-up. In our practice, vascular surgeons performed a fistulography or Doppler ultrasound imaging if stenosis or thrombosis was suspected. The institutional review board of Presbyterian Medical Center approved the study protocol (PMCI RB-020-003).

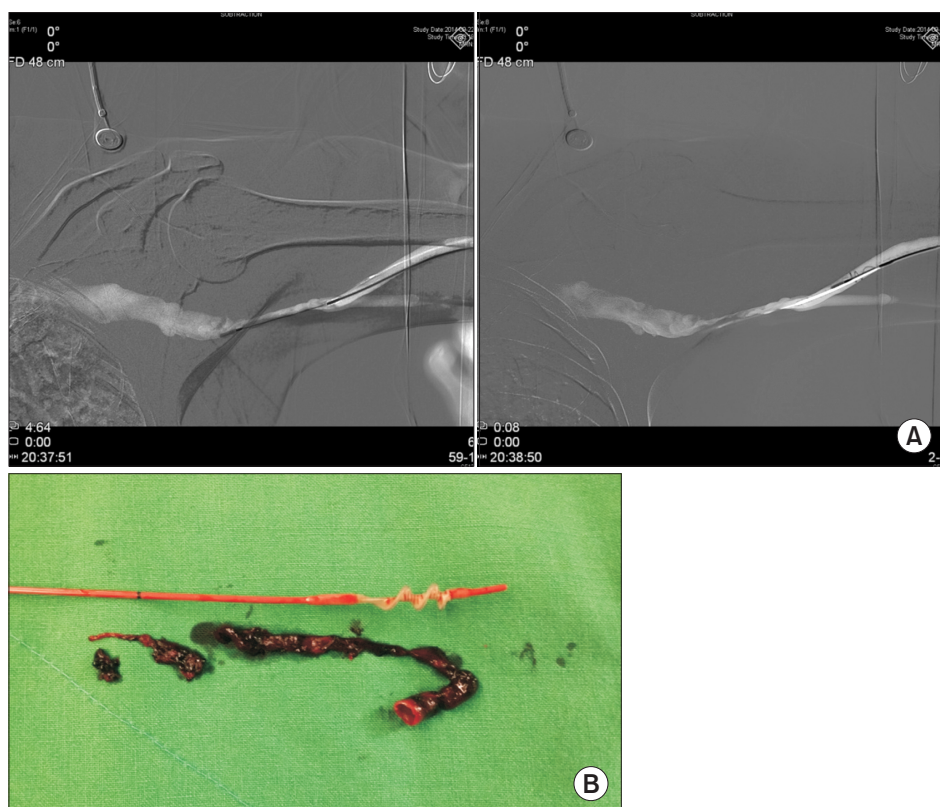


Fig. 1. Hybrid surgery using adherent clot catheter for thrombosed prosthetic brachio-axillary access. (A) Under fluoroscopy, the adherent clot catheter is passed along the graft and into the stenotic venous anastomosis. The knob on the catheter's handle is retracted until the spiral shape assumes the desired size; the corkscrew adherent clot catheter is then retracted, (B) thereby engaging the material within the interstices of the spiral.

2) Surgical thrombectomy with AC catheter

Surgical thrombectomy with the AC catheter is similar to the procedure performed using the Fogarty balloon catheter except for the manner in which the equipment is handled. The AC catheter is collapsed to its low-profile configuration and passed along the fistula or graft into the region of obstruction. The sliding knob on the handle is then retracted to expand the corkscrew wire to the desired diameter, engaging the thrombus within the spiral sections of the catheter. Under fluoroscopy, the AC catheter is slowly drawn back along the fistula or graft until the thrombus is removed through venotomy or graftomy. The diameter of the spiral wire may be continuously adjusted in response to the resistance within the vessel as the catheter is slowly withdrawn (Fig. 1A, B).

3) Definition

Clinical success was defined as at least one successful hemodialysis session using the graft after mechanical thrombectomy. The clot removal status was assessed by intraoperative angiography after thrombectomy and classified based on the clot removal score (CRS) as complete clot removal (non-circumferential wall adherent thrombus attached to only a small portion [one-fifth or less] of the access, CRS=1) and incomplete clot removal (adherent thrombus involving much more than one-fifth, CRS=0) [5]. Complications were classified as vascular rupture and arterial embolization necessitating an additional procedure.

The primary patency rate was defined as the percentage of grafts that functioned well without any additional intervention for graft failure. The follow-up time was censored for patient death, transplant, and change of dialysis modality. Primary patency was studied using the Kaplan-Meier survival analysis, and the differences in the patency rates were tested using the log-rank test. All calculations were conducted using SPSS ver. 14.0 (SPSS Inc., Chicago, IL, USA).

RESULTS

Demographic data of those who underwent the hybrid procedure using the AC and Fogarty balloon catheters are

Table 1. Demographic data of the study population

Patients' characteristic	Catheter		P-value
	AC (n=140)	Balloon (n=68)	
Age (y)	65 (30-88)	67 (31-84)	0.430
Sex (male:female)	76:64	50:18	0.008
Hypertension	114 (81.4)	51 (75.0)	0.283
Diabetes	95 (67.9)	41 (60.3)	0.282
Anti-platelets	106 (75.7)	43 (63.2)	0.061
AVG vs. AVF			0.015
Polytetrafluoroethylene	111 (79.3)	63 (92.6)	
Autologous	29 (26.7)	5 (7.4)	

Values are presented as median (range) or number (%). AC, adherent clot; AVG, arteriovenous graft; AVF arteriovenous fistula.

Table 2. Number, type and location of grafts with distribution per catheter

	Total	Catheter				
		Adherent clot		Balloon		
Number of thrombectomies	208	140		68		
Access age (y)		3.69		3.34		
Hemodialysis duration (y)						
0-3		39 (27.9)		22 (32.3)		
4-5		47 (33.6)		25 (36.8)		
6-10		54 (38.5)		21 (30.9)		
Type of access		Autogenous	Prosthetic	Autogenous	Prosthetic	
Number of graft	37	171	32	108	5	63
Location of grafts						
Autogenous radio-cephalic			15		3	
Autogenous brachio-cephalic			17		2	
Prosthetic brachio-axillary				92		56
Prosthetic brachio-antecubital (forearm U loop)				8		6
Unclassified				8		1

Values are presented as number only or number (%).

compared in Tables 1 and 2. Of the compared variables, no significant difference was found in age, hypertension, diabetes status, and anti-platelet use between the groups. In view of gender ratio, the balloon group was significantly shifted towards male predominance (P=0.008). The access age of the AC and balloon catheter groups was 3.7±1.5 years and 3.3±1.6 years, respectively (P=0.132). The types of conduit in the AC group were autogenous radio-cephalic (RC) direct wrist access in 15 cases, autogenous brachio-cephalic (BC) upper arm direct access in 17, prosthetic brachio-axillary (BA) access in 92, prosthetic brachio-antecubital forearm loop (U) access in 8, and unclassified in 8. In the balloon group, RC was performed in 3 cases, BC in 2, BA in 56, U in 6 and unclassified in 1 (P=0.030) [6]. A total of 208 hybrid procedures (AC catheter in 140 cases and Fogarty balloon catheter in 68 cases) were performed in 116 patients. Sixty patients (51.7%) underwent more than 2 procedures due to rethrombosed access during the follow-up period. The catheter selection during the reoperation was also random without influence of access conditions. All 208 simultaneous endovascular treatments were successful. Two hundred and six of these procedures were only balloon angioplasty and the remaining 2 were balloon angioplasty with cutting balloons.

The CRS and clinical success of the two groups are shown in Table 3. In terms of CRS, the balloon catheter was superior to the AC catheter (P=0.018). Clinical success was achieved in 90.7% of the cases in the AC catheter group and in 98.5% of the cases in the balloon catheter group (P=0.035). A total of 336 stenoses were encountered among all cases. The mean number of stenoses was 1.56 in the AC catheter group and 1.72 in the balloon catheter group (P=0.267). All stenoses were treated by percutaneous

angioplasty after surgical thrombectomy. A total of 21 complications occurred (Table 4); 17 (12.1%) cases in the AC catheter group and 4 (5.9%) cases in the balloon catheter group (P=0.160). All of them are caused by surgical thrombectomy, not by balloon angioplasty. The mean age of the accesses in the complication group compared to the non-complication group was 3.9±2.3 years and 4.4±3.1 years, respectively (P=0.336).

Fig. 2 shows the Kaplan-Meier survival curves for each catheter. The patency rates between the two catheters were not significantly different (P=0.328). Primary patency rates are shown in Table 3. The primary patency rates of the AC catheter group and balloon catheter group were 50.7%

Table 3. Surgical thrombectomy results according to the type of catheter

	Catheter		P-value
	Adherent clot	Balloon	
Clot removal score			0.018
1	109 (77.9)	62 (91.2)	
0	31 (22.1)	6 (8.8)	
Clinical success	127 (90.7)	67 (98.5)	0.035
Patency (%)			
At 3 mo	50.7	63.2	
At 6 mo	40.7	47.1	
At 12 mo	17.9	19.1	
Complications	17 (12.1)	4 (5.9)	0.160
Rupture	13 (9.3)	3 (4.4)	
Distal embolization	2 (1.4)	1 (1.5)	
Obstruction	2 (1.4)		
Mean numbers of stenoses per access	1.56	1.72	0.267

Values are presented as number (%) or number only.

Table 4. Number and type of complications and additional procedures

Catheter	Type	No.	Complications	No.	Additional procedure	No.
Adherent clot (n=17)	Prosthetic brachio-axillary	7	Venous outlet rupture	3	Balloon angioplasty	3
			Graft rupture	3	Primary closure	3
			Distal embolization	1	Heparinization	1
	Prosthetic brachio-antecubital (forearm U loop)	1	Distal embolization	1	Thrombolysis	1
	Autogenous radio-cephalic	6	Fistula rupture	4	Swing	3
			Obstruction	2	PTA	1
Autogenous brachio-cephalic	3	Fistula rupture	2	Short term catheter	1	
		Obstruction	1	Proximal swing	1	
			2	Patchy angioplasty	1	
Balloon (n=4)	Prosthetic brachio-axillary	2	Venous outlet rupture	2	PTA	1
			Obstruction	2	Jump graft	1
	Autogenous radio-cephalic	2		2	Balloon angioplasty	2
				2	Short term catheter	1
				2	Proximal swing	1

PTA, percutaneous transluminal angioplasty.

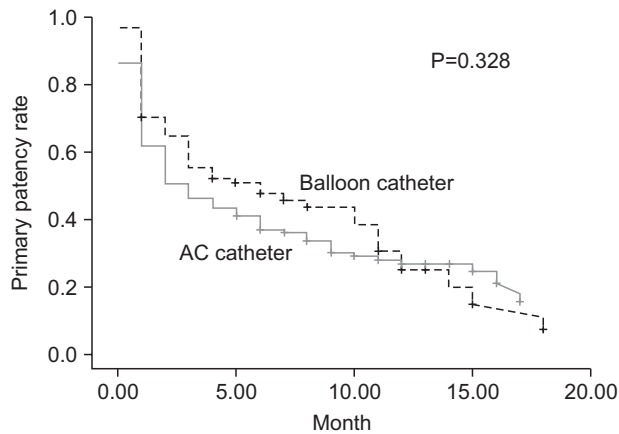


Fig. 2. Primary patency rate of adherent clot (AC) catheter and Fogarty balloon catheter after hybrid salvage surgery.

vs. 63.2% at 3 months, 40.7% vs. 47.1% at 6 months, and 17.9% vs. 19.1% at 12 months, respectively. The Kaplan-Meier survival analysis in the AC catheter group for autogenous fistula versus prosthetic graft did not show significant differences in patency ($P=0.764$). Analysis of patency rate based on access type, as in autogenous ($P=0.169$) and prosthetic graft ($P=0.423$), showed no significant difference between the two catheter groups.

The mean follow-up duration of the two groups were 19 months in AC group and 13.7 ± 5.9 months in balloon group ($P=0.00$). During the follow-up period, 2 patients died with functioning access and 1 was successfully transplanted.

DISCUSSION

Traditionally, thrombosed vascular access has been treated with surgical thrombectomy followed by local revision or endovascular treatment of the access. Recently, hybrid surgery performed by vascular surgeons has gained popularity in the salvage of failed hemodialysis access [7,8]. Complete removal of thrombi adjacent to an anastomosis of the graft and aneurysms within the fistula is often difficult, as this can prevent the passing of the thrombectomy catheter. Therefore, adoption of an effective method for surgical thrombectomy of thrombosed hemodialysis access is essential. Newer or more refined procedures to salvage thrombosed accesses could potentially play a major role in the clinical success and long-term patency of this approach.

To date, no studies have been published on the use of the AC catheter for salvage of failed hemodialysis access. The AC catheter is designed to effectively remove clot material from the peripheral vasculature. It is also indicated for the removal of emboli and thrombi from native arteries or synthetic grafts [9]. The catheter features an adjustable (3–10 mm), spiral-shaped, latex-covered stainless steel

cable that assumes a corkscrew shape when retracted by a control handle, greatly expanding the surface area to entrap material. Moreover, it is radiopaque, which aids visualization [10,11].

We were interested in whether a catheter with these features would be suitable for application in hybrid salvage of hemodialysis vascular access. Therefore, we used this catheter to determine whether it improved clinical success and primary patency rates. This study demonstrated our clinical experience and outcomes of the corkscrew AC catheter compared to those of the standard Fogarty balloon catheter in a salvage procedure for thrombosed hemodialysis accesses.

Our overall clinical success rate in the AC catheter group and balloon catheter group was 90.7% and 98.5%, respectively, which is in the same range as that of previously published data on surgical thrombectomies for autologous and prosthetic accesses [12]. In terms of clinical success, the AC catheter did not demonstrate better outcomes compared to the balloon catheter. The clot removal outcomes with the Fogarty balloon catheter were also better compared to those with the AC catheter. However, there was no statistically significant difference in the primary patency rate between the two groups ($P=0.328$, log-rank test). The presence of small amounts of residual thrombi seemed insignificant because these were likely to be cleared by the bloodstream [5]. Additionally, it is important to note that thrombectomy alone may not influence the patency because of the presence of variable etiologies of the thrombosis [4]. Although we analyzed that the CRS were different between two groups, we believe that the patency rate between the two groups were not significantly different because all combined endovascular treatments were successfully performed in the hybrid setting.

In our clinical experience, we found the use of the AC catheter to have both advantages and shortcomings. Its use is advantageous in that the catheter has a good curettage effect on autogenous access and prosthetic grafts. It can effectively remove the acute and chronic adherent clots and aggressively excoriate the neointimal hyperplasia layer of the graft. Moreover, the catheter is useful in the hybrid operative setting because it is radiopaque in the procedure with intraoperative fluoroscopy. Although we could not identify the exact number of aneurysmal fistula due to a limitation of the medical records, the clots were retained frequently in multiple areas of aneurysmal dilatation in some of our cases, and the major causes of technical failure included incomplete thrombectomy after percutaneous procedures. During hybrid surgery, removal of clots, including large pieces of thrombi contained in an aneurysm, was feasible by manual squeezing and multiple

passes of the AC catheter for curettage. With regards to its shortcomings, the catheter is somewhat stiff, so it cannot pass through angled lesions. When passing through an angled anastomotic lesion or venous valve area, the stiff catheter could cause rupture. Moreover, the thrombus can be pushed into the distal artery flow by the stiff catheter, thereby causing distal embolization and hand ischemia. The corkscrew catheter may also be responsible for intimal injury, venous wall injury, and inflammation, which could elevate the risk for rethrombosis.

On the basis of our experience with the AC catheter for hemodialysis access, we do not advocate its use to salvage a thrombosed tortuous or luminal narrowing autogenous access that is sclerotic or with long-segment stenosis because rupture or occlusion of access can occur easily. The AC catheter could be an effective tool for surgical thrombectomy of the thrombosed hemodialysis prosthetic grafts. However, it cannot be used on aged and fragile prosthetic grafts due to the possibility of graft rupture.

The limitations of this study should be acknowledged. First, this was a retrospective study based on previously data and catheter selection bias may be present. Second, this study was not designed to prove the efficiency of endovascular treatment after surgical thrombectomy, even

though all cases were treated with a hybrid procedure. We did not analyze parameters such as residual stenosis and recoil after angioplasty, which could be another important factor influencing the patency of access. The time to performance of the surgical thrombectomy can influence access salvage [3,13], and the ingraft to systemic systolic blood pressure ratio can also predict recurrent stenosis [14]. The patency rate should be determined based on the success of the endovascular angioplasty of the various underlying causes including residual stenosis and recoil in addition to the clot removal status.

CONCLUSION

The balloon catheter removed clots more effectively than the AC catheter. However the patency rates were not significantly different between the two types of catheters for hybrid salvage of thrombosed hemodialysis access. The AC catheter can be a useful alternative to the standard Fogarty balloon catheter in hybrid salvage procedure for thrombosed hemodialysis access. However when using the AC catheter, the potential complications such as fistula or graft rupture and distal embolization should be considered.

REFERENCES

- 1) Brenner L, Singh AK, Campbell D, Frei F, Winkelmayr WC. Associations between demographic factors and provider structures on cost and length of stay for hemodialysis patients with vascular access failure. *Clin J Am Soc Nephrol* 2006;1:455-461.
- 2) Sawant A, Mills PK, Dhingra H. Increased length of stay and costs associated with inpatient management of vascular access failures. *Semin Dial* 2013;26:106-110.
- 3) National Kidney Foundation. KDOQI clinical practice guideline for diabetes and CKD: 2012 update. *Am J Kidney Dis* 2012;60:850-886.
- 4) Sidawy AN, Spergel LM, Besarab A, Allon M, Jennings WC, Padberg FT Jr, et al; Society for Vascular Surgery. The Society for Vascular Surgery: clinical practice guidelines for the surgical placement and maintenance of arteriovenous hemodialysis access. *J Vasc Surg* 2008;48(5 Suppl):25-25S.
- 5) Smits HF, Smits JH, Wüst AF, Buskens E, Blankestijn PJ. Percutaneous thrombolysis of thrombosed haemodialysis access grafts: comparison of three mechanical devices. *Nephrol Dial Transplant* 2002;17:467-473.
- 6) Sidawy AN, Gray R, Besarab A, Henry M, Ascher E, Silva M Jr, et al. Recommended standards for reports dealing with arteriovenous hemodialysis accesses. *J Vasc Surg* 2002;35:603-610.
- 7) Kang HS, Han KD, Choi EH, Park YS, Seo YH, Kim CS. The comparative analysis between surgical thrombectomy and hybrid treatment in salvage operation. *Korean J Vasc Endovasc Surg* 2012;28:207-211.
- 8) Hyun JH, Lee JH, Park SI. Hybrid surgery versus percutaneous mechanical thrombectomy for the thrombosed hemodialysis autogenous arteriovenous fistulas. *J Korean Surg Soc* 2011;81:43-49.
- 9) Trerotola SO, Harris VJ, Snidow JJ, Johnson MS. Percutaneous use of the Fogarty adherent clot catheter. *J Vasc Interv Radiol* 1995;6:578-580.
- 10) Hill B, Fogarty TJ. The use of the Fogarty catheter in 1998. *Cardiovasc Surg* 1999;7:273-278.
- 11) Fogarty TJ, George D. New techniques for clot extraction and managing acute thrombotic limb ischemia. *Curr Crit Probl Vasc Surg* 1993;3:197-203.
- 12) Cull DL, Washer JD, Carsten CG, Keahey G, Johnson B. Description and outcomes of a simple surgical technique to treat thrombosed autogenous accesses. *J Vasc Surg* 2012;56:861-865.
- 13) Sadaghianloo N, Jean-Baptiste E, Gaid

H, Islam MS, Robino C, Declemy S, et al. Early surgical thrombectomy improves salvage of thrombosed vascular accesses. *J Vasc Surg* 2014;59:1377-

1384.

14) Lilly RZ, Carlton D, Barker J, Saddekni S, Hamrick K, Oser R, et al. Predictors of arteriovenous graft patency after

radiologic intervention in hemodialysis patients. *Am J Kidney Dis* 2001; 37:945-953.