



Contents lists available at ScienceDirect

Indian Pacing and Electrophysiology Journal

journal homepage: www.elsevier.com/locate/IPEJ

Atrial flutter presenting as broad complex tachycardia in a patient with right sided pneumonectomy

Thomas Beiert, MD^{*}, Georg Nickenig, MD, Jan Wilko Schrickel, MD, Markus Linhart, MD

Department of Internal Medicine II, University Hospital Bonn, Rheinische Friedrich-Wilhelms University, Bonn, Germany

ARTICLE INFO

Article history:

Received 2 December 2016
Received in revised form
16 February 2017
Accepted 3 May 2017
Available online 4 May 2017

Keywords:

Broad complex tachycardia
Ventricular tachycardia
Supraventricular tachycardia
Atrial flutter

ABSTRACT

A 71-year-old man with no history of coronary artery disease presented with palpitations to the emergency department. The 12-lead ECG showed a regular tachycardia with wide QRS complexes (220 bpm) suggestive of ventricular tachycardia. Instead invasive electrophysiological investigation revealed typical atrial flutter as underlying arrhythmia. The altered QRS morphology resulted from displacement of the heart into the right hemithorax due to right-sided pneumonectomy in combination with bundle branch block.

Copyright © 2017, Indian Heart Rhythm Society. Production and hosting by Elsevier B.V. This is an open access article under the CC BY-NC-ND license (<http://creativecommons.org/licenses/by-nc-nd/4.0/>).

1. Introduction

Despite the evolution of various ECG-criteria patients presenting to the Emergency Department with broad QRS complex tachycardia still remain challenging. There are several algorithms for differential diagnosis of regular tachycardia with wide QRS complex, of which the most widely used has been developed by Brugada et al. [1]. This approach improved discrimination between supraventricular and ventricular tachycardia (SVT and VT) compared to the sole application of morphological features [2].

2. Case report

A 71-year old man presented to his general practitioner with palpitations. He was then transferred to our Emergency Department with diagnosis of VT. His medical history included chronic obstructive pulmonary disease and right-sided pneumonectomy due to non-small cell lung cancer, but no history of prior myocardial infarction or coronary artery disease.

The 12-lead ECG on admission (Fig. 1A) showed a regular broad complex tachycardia with 220 bpm (QRS width 154 ms).

Differential diagnosis included VT or SVT with 1:1 aberrant conduction. The ECG was analyzed using an algorithm based on Brugada et al. [1]: There were no RS-complexes in any precordial lead favoring right away the diagnosis of VT. Neither capture/fusion beats nor atrio-ventricular dissociation, that would further support VT, could be detected. The initial R-wave upstroke in lead aVR was positive (“north-west axis”, “no man’s land vector”) indicating propagation of electrical activity from the apex to the heart base thus in favor of VT [3]. With regards to morphology, QRS complexes showed a right bundle branch block (RBBB)-like pattern with two classical Wellens criteria positive for VT: namely a R-complex with “rabbit ear” in V1 and a QS-complex in V6 [2]. In contrast, initial up- or down-stroke of QRS was rapid compared to the terminal portion, resulting in a Vi/Vt ratio > 1, which would favor SVT [3].

An acute myocardial infarction could be excluded by negative troponin levels. We decided to treat the tachycardia as VT by intravenous administration of 300 mg amiodarone which was ineffective.

The patient, who was hemodynamically stable throughout, was taken to the catheterization lab for invasive electrophysiological investigation. Intracardiac ECG tracings showed a supraventricular tachycardia with a total cycle length of 282 ms and intermittent 2:1 or 1:1 atrio-ventricular conduction (Fig. 2A). Entrainment from the proximal coronary sinus catheter showed a post-pacing interval of 288 ms. These findings were consistent with typical atrial flutter. Radiofrequency ablation of the cavotricuspid isthmus resulted in slowing of the tachycardia with transition to 1:1 conduction and

^{*} Corresponding author. Department of Internal Medicine II, University Hospital Bonn, Sigmund Freud Str. 25, 53127 Bonn, Germany.

E-mail address: thomas.beiert@ukbonn.de (T. Beiert).

Peer review under responsibility of Indian Heart Rhythm Society.

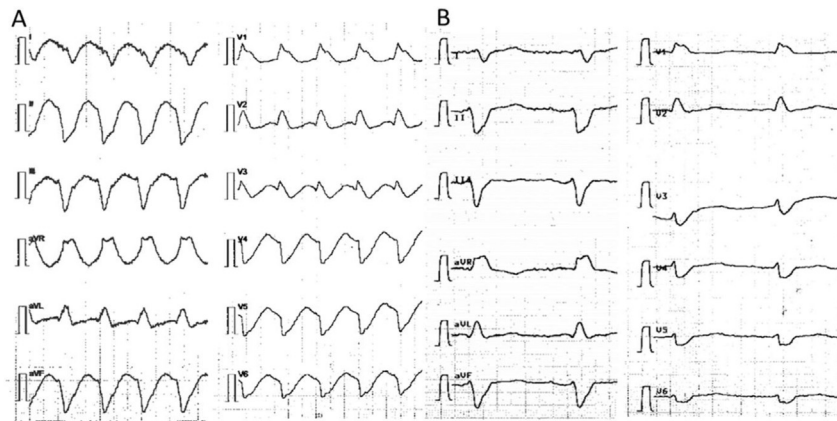


Fig. 1. (A) 12-lead ECG recorded during tachycardia (50 mm/s). Note the absence of RS-complexes in all precordial leads and the positive initial R-wave in lead aVR (“north-west axis”). (B) 12-lead ECG recorded during sinus rhythm after ablation (50 mm/s).

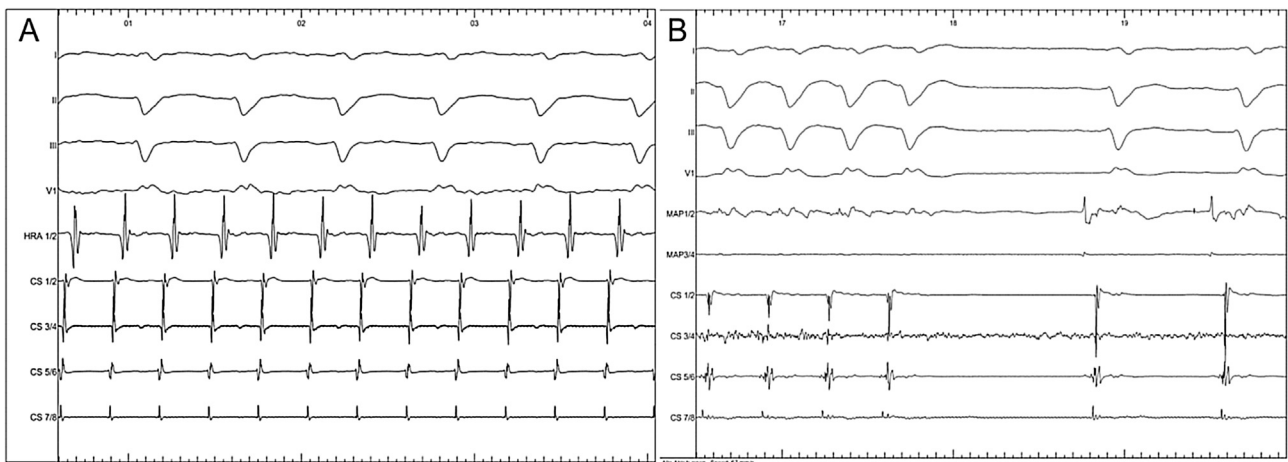


Fig. 2. (A) Intracardiac ECG demonstrates atrial flutter with 2:1 conduction (67 mm/s). (B) Termination of atrial flutter with 1:1 conduction and onset of sinus rhythm (67 mm/s). HRA: high right atrium catheter. MAP: ablation catheter. CS: coronary sinus catheter.

finally termination of tachycardia (Fig. 2B). Note that there is no atrial signal following the last QRS complex of the tachycardia which would have been expected after cessation of a VT with VA conduction.

Former chest CT images revealed a grossly displaced heart shifted to the right hemithorax after right-sided pneumonectomy (Fig. 3).

3. Discussion

This case illustrates the complexity of differential diagnosis between SVT and VT. Several approaches [1–3] have been developed to help differentiating between these two forms.

The applied algorithm indicated the diagnosis of VT, whereas the definite diagnosis after invasive electrophysiological investigation was SVT (atrial flutter with 2:1 and 1:1 conduction). The proposed algorithm from Vereckei et al. includes the V_i/V_t criterion that relates initial versus terminal activation/deactivation velocities of the QRS complex [3]. The algorithm claims to be more sensitive and specific for VT. In our case, the V_i/V_t criterion was >1 and thus indicating SVT. However, this algorithm would already have pointed towards VT two steps earlier because of initial R-wave in aVR.

This false diagnosis (SVT treated as VT) is always less life

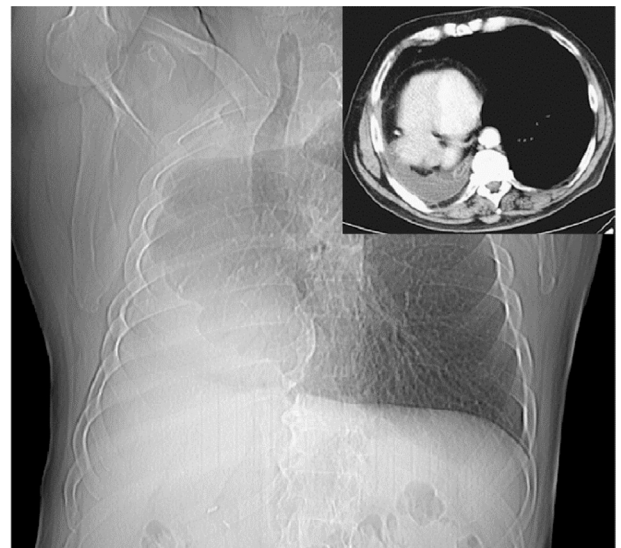

Fig. 3. CT topogram and axial view (inlay) show the heart displaced to the right hemithorax.

threatening than vice versa [4]. In stable patients, without the need for urgent cardioversion, vagal maneuvers or application of adenosine should be considered for differentiation. In our case atrial flutter waves might have been unmasked helping to find the definitive diagnosis. Other SVTs, like atrio-ventricular reentry tachycardia, might terminate but VT would not be affected. As our case clearly demonstrates, it must always be taken into account that diagnostic ECG algorithms rely on a typical macroscopic anatomy of the heart and thorax. In our case, anatomical displacement alone cannot explain this QRS morphology. The width of the QRS complex and the axis deviation towards aVR require additional presence of some degree of blockage in the specific conduction system. QRS morphology most likely indicates presence of RBBB, but again it must be taken into account that ECG definitions of bundle branch block morphology are based on normal gross cardiac anatomy. The ECG findings are compatible with a bifascicular block, most likely RBBB and left anterior hemiblock. In “normal” anatomic position, the resulting main QRS axis would be $\leq -30^\circ$ in the frontal plane and thus positive in leads I and aVR. Due to displacement of the heart completely into the right hemithorax and a slightly reduced tilt angle of the anatomical heart axis, main QRS axis points towards aVR and this ECG can be

explained.

Funding

None.

Conflicts of interest

None declared.

References

- [1] Brugada P, Brugada J, Mont L, Smeets J, Andries EWI. A new approach to the differential diagnosis of a regular tachycardia with a wide QRS complex. *Circulation* 1991;83:1649.
- [2] Wellens HJJ, Bar FW, Lie KL. The value of the electrocardiogram in the differential diagnosis of a tachycardia with a widened QRS complex. *Am J Med* 1978;64:27–33.
- [3] Vereckei A, Duray G, Szénási G, Altemose GT, Miller JM. Application of a new algorithm in the differential diagnosis of wide QRS complex tachycardia. *Eur Heart J* 2007;28:589–600.
- [4] Blomström-Lundqvist C, Scheinman MM, Aliot EM, Alpert JS, Calkins H, Camm AJ, et al. ACC/AHA/ESC guidelines for the management of patients with supraventricular arrhythmias-executive summary. *J Am Coll Cardiol* 2003;42(8):1493–531.