

Mazabraud syndrome associated with McCune-Albright syndrome

Alessio Biazzo¹, Andrea Di Bernardo², Antonina Parafioriti², Norberto Confalonieri¹

¹Orthopaedic Department, Gaetano Pini-CTO, Milano; ²Pathology Department, Gaetano Pini-CTO, Milano

Dear Editor, we report the case of a 28-year-old girl with the association of Mazabraud syndrome (MS) and McCune-Albright syndrome (MAS). Since birth she had café-au-lait spot on the right buttock and thigh (figure 1). When she was 4-year-old she developed precocious puberty and fibrous dysplasia (FD) at the right upper limb and left chest wall. Hypothyroidism, polycystic ovary and breast fibroadenomatosis accompanied the extraskeletal manifestations. She was admitted at our Institute because of an intramuscular myxoma on the right leg (figure 2) that was biopsied and later excised.

MS is a rare benign condition characterized by the association of one or multiple myxomas with FD, which can be monostotic or polyostotic. The syndrome was first described by Henschen in 1926 (1) and later by Mazabraud in 1957 (2) and 1967 (3). Today, approximately 80 cases of MS have been reported in the English literature. According one of the most recent reviews (4), MS is characterized by female prevalence with odds-ratio female/male of 2:1. The average age of diagnosis is 32 years, with FD usually diagnosed 12 years before myxomas. FD is polyostotic in 80%, myxomas are multiple in 70%. Only four cases of malignant transformation of FD in MS are reported in the literature. Conversely, no malignant transformation has been described for myxomas.

MAS was originally described by McCune and Albright in 1936 (5) and 1937 (6) as the association of polyostotic FD, café-au-lait skin pigmentation and precocious puberty. It was later recognized that oth-

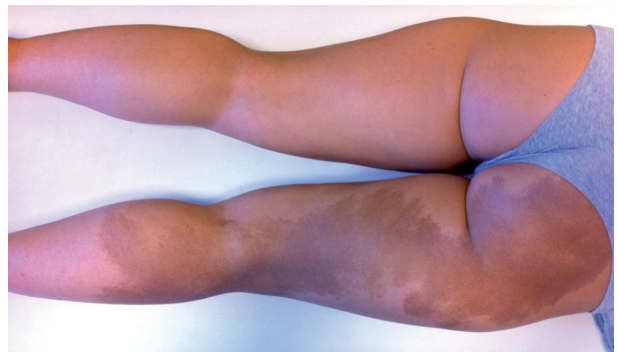

Figure 1. A typical café-au-lait lesion on the right buttock and thigh which demonstrates jagged “coast of Maine” borders and the tendency to respect the midline

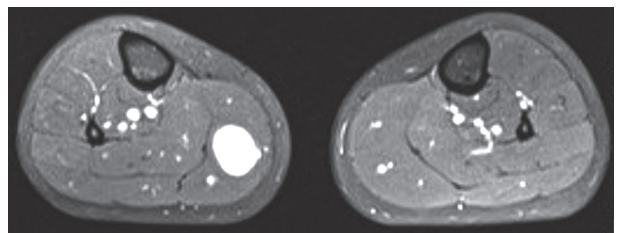


Figure 2. Non-contrast axial STIR-weighted image displaying an intramuscular mass within the medial gastrocnemius which is homogeneous and higher signal intensity compared to the muscle.

er endocrinopathies, including hyperparathyroidism, growth hormone excess, renal phosphate wasting, Cushing syndrome, polycystic ovary and breast fibroadenomatosis could be found in association with the original triad (7). Malignant transformation of FD

Table 1. Ten cases (except the current case) showed the association of Mazabraud syndrome with the typical triad of McCune-Albright syndrome (polyostotic fibrous dysplasia, café-au-lait skin pigmentation and endocrine dysfunction)

Authors	Sex	FD onset	Myxoma onset	Fibrous dysplasia	Myxoma	Endocrine dysfunction	Malignancy
Heinemann and Worth (11)	f	18	82	poly	mul	goiter	no
Laporte (12)	f	12	24	poly	single	p.p. hyperthyroidism	no
Mazabraud (3)	f	infant	n.r.	poly	mul	p.p.	osteo
Roze (13)	f	20	38	poly	mul	p.p.	no
Logel (14)	f	child	41	poly	mul	p.p., diabetes mellitus, goiter	no
Lopez-Ben (15)	f	5	40	poly	mul	p.p.	osteo
Faivre (16)	f	35	35	poly	mul	goiter	no
Tsitouridis (17)	f	5	28	poly	single	p.p.	no
Fertikh (18)	f	59	59	poly	mul	p.p. hyperthyroidism	no
Kitagawa (19)	f	35	30	poly	mul	p.p., goiter, adrenal adenoma	no
Current case	f	5	28	poly	single	p.p., hypothyroidism, polycystic ovary	no

Abbreviations f: female, poly: polyostotic, mul: multiple, p.p.: precocious puberty, osteo: osteosarcoma, n.r.: not reported

into osteosarcoma is the most common and best described malignancy that occurs in MAS (8). The frequency of malignant transformation of FD in MS is higher than that in isolated FD or MAS; we found 4 cases reported by Zoccali et al. (4) in a cohort of 67 MS, and a recent case reported by Crawford et al. (9). A greater tendency for malignant transformation in patients who have concomitant growth-hormone excess has been described (10).

The association of MS and MAS in the same patient is a very rare event, with few reports in the English literature. Only 26 cases have been reported of which only 10 with the typical triad of MAS, such as polyostotic FD, café-au-lait spots and endocrine dysfunction (Table 1). All these patients were female with an average age of 18 years at the FD diagnosis and 40 years at the myxoma diagnosis, confirming the later onset of myxomas respect to FD reported by Zoccali et al. (4). Myxomas were multiple in 8 cases. Precocious puberty was the most common endocrine dysfunction, present in 9 cases. Our review shows a higher risk of malignant transformation of FD in patients with MS associated with the classical triad of MAS (2 cases out of 10). Probably the percentage is overestimated because a malignant transformation is more probably object of publication rather than the association of two

syndromes that are often misdiagnosed because of the lack of symptoms.

Our case report represents probably the 11th case of MS associated with the classical triad of MAS. Our review shows that in MS associated with MAS there is a higher risk of malignant transformation of FD into osteosarcoma, confirming previous reports. Conversely, no malignant transformation has been reported for myxomas in MS or in the association with MAS. We conclude that these patients, especially female, should be scheduled to a close and long-term follow-up.

References

1. Henschen F. Fall von ostitis fibrosa mit multiplen tumoren in der umgebenden muskulatur. Verh Dtsch Ges Pathol 1926; 21: 93-7.
2. Mazabraud A, Girard J. A peculiar case of fibrous dysplasia with osseous and tendinous localizations. Rev Rhum Mal Osteoartic 1957 Sep-Oct; 24(9-10): 652-9.
3. Mazabraud A, Semat P, Roze R. Apropos of the association of fibromyxomas of the soft tissues with fibrous dysplasia of the bones. Presse Med 1967 Oct 25; 75(44): 2223-8.
4. Zoccali C, Teori G, Prencipe U, Erba F. Mazabraud's syndrome: a new case and review of the literature. Int Orthop 2009 Jun; 33(3): 605-10.
5. McCune DJ: Osteitis fibrosa cystica: the case of a nine-year-old girl who also exhibits precocious puberty, multiple pig-

- mentation of the skin and hyperthyroidism. *Am J Dis Child* 1936; 52: 743-744.
6. Albright F, Butler AM, Hampton AO, Smith P: Syndrome characterized by osteitis fibrosa disseminata, areas of pigmentation, and endocrine dysfunction, with precocious puberty in females: report of 5 cases. *N Engl J Med* 1937; 216: 727-46.
 7. Dumitrescu CE, Collins MT. McCune-Albright syndrome. *Orphanet J Rare Dis* 2008 May 19; 3: 12.
 8. Ruggieri P, Sim FH, Bond JR, Unni KK. Malignancies in fibrous dysplasia. *Cancer*. 1994 Mar 1; 73(5): 1411-24.
 9. Crawford EA, Brooks JS, Ogilvie CM. Osteosarcoma of the proximal part of the radius in Mazabraud syndrome. A case report. *J Bone Joint Surg Am* 2009 Apr; 91(4): 955-60.
 10. Blanco P, Schaeferbeke T, Baillet L, Lequen L, Bannwarth B, Dehais J. Chondrosarcoma in a patient with McCune-Albright syndrome. Report of a case. *Rev Rhum Engl Ed* 1999 Mar; 66(3): 177-9.
 11. Heinemann G, Worth D. Zur Osteofibrosis deformans juvenilis. *Bruns Beitr Klin Chir* 1958; 197(3): 327-36.
 12. Laporte F, Leger H, Malchair G. Albright's syndrome. *J Chir (Paris)* 1961 Nov; 82: 457-75.
 13. Roze R, Mazabraud A, Semat P. Fibrous dysplasia of bone and myxomas of the soft tissues. Localized sarcomatous degeneration. *J Radiol Electrol Med Nucl* 1967 Oct; 48(10): 527-36.
 14. Logel RJ. Recurrent intramuscular myxoma associated with Albright's syndrome. *J Bone Joint Surg Am* 1976 Jun; 58(4): 565-8.
 15. Lopez-Ben R, Pitt MJ, Jaffe KA, Siegal GP. Osteosarcoma in a patient with McCune-Albright syndrome and Mazabraud's syndrome. *Skeletal Radiol* 1999 Sep; 28(9): 522-6.
 16. Faivre L, Nivelon-Chevallier A, Kottler ML, Robinet C, Khau Van Kien P, Lorcerie B et al. Mazabraud syndrome in two patients: clinical overlap with McCune-Albright syndrome. *Am J Med Genet* 2001 Mar 1; 99(2): 132-6.
 17. Tsitouridis I, Sayegh FE, Natsis K, Goutsaridou F, Melidis D, Emmanouilidou M. Mazabraud's syndrome: MRI evaluation. 2003 *Eur J Radiol Extra* 45(2):83-87(5).
 18. Fertikh D. Fibrous Dysplasia and Intramuscular Myxomas: Mazabraud's Syndrome. *Appl Radiol* 2003; 32(1).
 19. Kitagawa Y, Ishihara Y, Hayashi M, Kim Y, Fujii N, Ito H. Mazabraud syndrome associated with McCune-Albright syndrome. *J Orthop Sci* 2011 Jan; 16(1): 129-32.
-
- Received: 1 March 2016
Accepted: 29 March 2016
Correspondance:
Alessio Biazzo
via Bignami 1, Milano
Tel. 0039 3476234772
E-mail: ale.biazzo@yahoo.it