

Contents lists available at [ScienceDirect](http://www.sciencedirect.com)

## International Journal of Surgery Case Reports

journal homepage: [www.casereports.com](http://www.casereports.com)

# Neurophysiological monitoring of lumbar spinal nerve roots: A case report of postoperative deficit and literature review



Yuguang Chen<sup>a</sup>, Baoqing P. Wang<sup>b,\*</sup>, Junlin Yang<sup>a</sup>, Yaolong Deng<sup>a</sup>

<sup>a</sup> Department of Spinal Surgery, The First Affiliated Hospital of Sun Yat-sen University, Guangzhou, China

<sup>b</sup> Neurological Monitoring Services, West Reading, PA, USA

## ARTICLE INFO

### Article history:

Received 8 September 2016

Received in revised form

17 November 2016

Accepted 17 November 2016

Available online 19 November 2016

### Keywords:

Spinal nerve root

Postoperative deficit

Neuromonitoring

Electromyography

Evoked potential

Case report

## ABSTRACT

**INTRODUCTION:** Intraoperative neurophysiological monitoring (IONM) has proven to help reduce the probability of postoperative neurological deficit for spinal deformity correctional surgeries. However, in rare cases new deficits may still happen. We report a surgical case in which the patient had postoperative paralysis. We would like to call for more case reports with postoperative neurological deficits as they present difficult clinical cases.

**PRESENTATION OF CASE:** A 61-year-old male patient with severe thoracolumbar kyphoscoliosis underwent posterior spinal correction and fusion with segmental T10–L5 pedicle screws and rods instrumentation with IONM. The only intraoperative event was a pedicle breach at left L3 which was detected by triggered electromyography (EMG) testing, and the pedicle screw was repositioned. Left lower extremity paralysis was observed upon patient awakening. He received rehabilitation treatment and had limited recovery of muscle strength. Partial lumbar nerve root injury was likely the cause of the paralysis.

**DISCUSSION:** This is a case with new lumbar nerve root deficit, with positive EMG signal change, but negative somatosensory evoked potential (SSEP) and motor evoked potential (MEP) findings. We discuss the different neurophysiological modalities for monitoring lumbar spinal nerve root function. We review journal articles from the past two decades which reported lumbar root deficits, and list neuromonitoring events during the surgeries.

**CONCLUSION:** Multimodality monitoring with spontaneous and electrically triggered EMG combined with SSEP and MEP may provide the best chance to detect lumbar nerve root injuries.

© 2016 The Author(s). Published by Elsevier Ltd on behalf of IJS Publishing Group Ltd. This is an open access article under the CC BY-NC-ND license (<http://creativecommons.org/licenses/by-nc-nd/4.0/>).

## 1. Introduction

Clinical data has demonstrated that new neurological deficits are inherent potential complications of spine surgery especially deformity correctional surgery even among skilled surgeons, and intraoperative neurophysiological monitoring (IONM) provides early detection to reduce postoperative sensory and motor deficits [1–5].

The ideal goal of IONM is to prevent new postoperative neurological deficits from happening, but in rare cases new deficits may still happen despite IONM. Those cases should be of great interest to us for discussion. We should review what happened during the surgery, what kind of signal changes occurred, and what surgical alterations were made in response to the neurophysiological alerts. The possibilities are: 1) IONM identified positive signal changes, but too late to avoid or reduce the injury; or 2) false-negative, that IONM failed to detect the injury.

\* Corresponding author at: Neurological Monitoring Services, 601 Spruce Street, West Reading, PA, 19611, USA.

E-mail addresses: [bpw@neuromoninc.com](mailto:bpw@neuromoninc.com), [bqw@yahoo.com](mailto:bqw@yahoo.com) (B.P. Wang).

<http://dx.doi.org/10.1016/j.ijscr.2016.11.027>

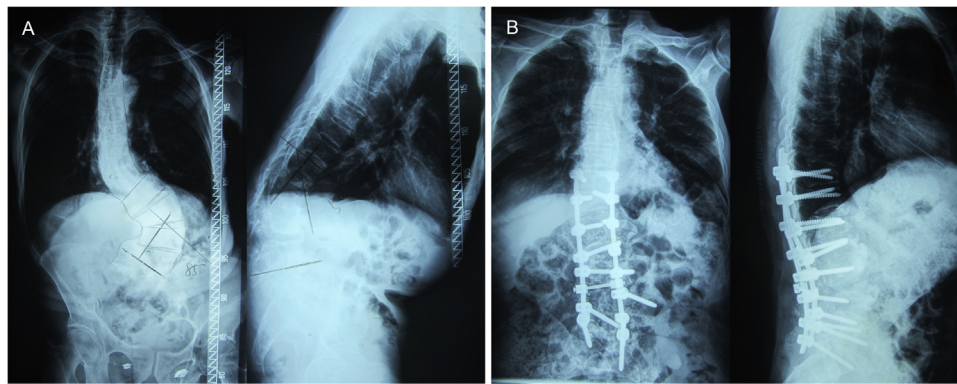
2210–2612/© 2016 The Author(s). Published by Elsevier Ltd on behalf of IJS Publishing Group Ltd. This is an open access article under the CC BY-NC-ND license (<http://creativecommons.org/licenses/by-nc-nd/4.0/>).

There were few journal articles describing new deficits associated with specific neurophysiological findings in detail, especially case reports. We believe more study and discussion of such tough cases should help the surgical team and intraoperative neurophysiologists prepare for challenging surgeries and serve our patients better. We would like to call for more such case reports with new neurological deficits from surgical and neuromonitoring colleagues.

We report a case of postoperative paralysis after thoracolumbar kyphoscoliosis correction surgery. With this case, we focus on lumbar nerve root deficits, discuss the possible cause of the deficit, and discuss the different neurophysiological modalities of lumbar nerve root monitoring.

## 2. Presentation of case

A 61-year-old male patient had progressive spinal deformity for 10 years, back pain for 5 years, and subjective weakness and fatigue in the lower extremities over a year. Physical examination revealed normal sensation to touch and strength of 5/5 for all major muscle groups in the lower extremities. Radiographs demonstrated severe thoracolumbar scoliosis with 85° Cobb angle and 50°



**Fig. 1.** Anteroposterior and lateral radiography of a 61-year-old male patient's thoracolumbar spine. A: Preoperative images showing thoracolumbar scoliosis with 85° Cobb angle and 50° kyphosis. B: Postoperative images demonstrating pedicle screws and rods fixation with excellent correction of the spinal deformity.

kyphosis (Fig. 1A). Magnetic resonance imaging and myelogram excluded any intraspinal abnormalities.

He underwent a Smith-Peterson osteotomy at L2/3 and L3/4, fusion with pedicle screws and rods instrumentation T10-L5 (Fig. 1B) under total intravenous general anesthesia. IONM was carried out with an Endeavor CR system from Nicolet. Baseline posterior tibial nerve somatosensory evoked potentials (SSEPs) were within normal limits for latency and amplitude; transcranial motor evoked potentials (MEPs) recorded from lower extremity muscle groups were present. Triggered electromyography was recorded to electrical stimulation of pedicle screws. A compound muscle action potential was recorded from adductors and quadriceps when the left L3 pedicle screw was stimulated at 5 mA. The screw was repositioned and subsequent stimulation showed a stimulus threshold of 27 mA. The remaining pedicle screws all had a stimulus threshold of 24 mA or above. There was no remarkable change in SSEPs and MEPs during the surgical procedure, especially following osteotomy at L2/3 and L3/4, correction of kyphoscoliosis, and internal fixation with rods at T10-L5. A wake-up test was performed after the correction and the patient moved his feet.

Upon patient awakening after completion of the surgery and returning to supine position, muscle strength was found to be 0/5 for left iliopsoas, adductors, and quadriceps. Muscle strength was normal with the remaining muscle groups, sensation was intact, and Babinski sign was negative. Postoperative X-ray and CT scan demonstrated that all pedicle screws were in satisfactory positions, and there was no spinal cord compression. Transcranial MEPs were performed and the responses were absent from left quadriceps, present with prolonged latency and reduced amplitude from left adductors.

Six days after surgery, there was no recovery of the paralyzed muscles. One month after the surgery, there was still no change. He received rehabilitation treatment and had limited recovery. One year after surgery, he could walk with a limp with a cane; muscle strength was 4/5 for left adductor and quadriceps.

### 3. Discussion

This was a difficult surgical case with the advanced age of the patient and severe and complex curvature of the thoracolumbar spine. There was a high risk of neurological deficit with factors such as high degree of Cobb angle, osteotomy, deformity correction, pedicle screw placement, consistent with other published reports [6]. Lieberman et al. [7] reported 10 out of 35 patients had postoperative neurological deficit after posterior-based osteotomies for the correction of fixed sagittal plane deformity. It was a challeng-

ing case for IONM to monitor both spinal cord and spinal nerve root function with limited recording channels and computing power.

Spinal cord function remains the major concern for spinal surgeries, which can be monitored effectively with combined SSEP and MEP recording to minimize the risk of spinal cord injury and permanent deficit. The rate of spinal nerve root deficit is reportedly higher than that of spinal cord deficit associated with spine surgeries [1,4]. Nerve root injury can be more common, but less devastating, with symptoms such as localized pain, numbness, and weakness.

In this case the muscle paralysis may have been caused by nerve root damage when the left L3 pedicle screw was inserted initially, or nerve root stretch when the spinal curvature was corrected, or both. Pedicle screw testing with triggered electromyographic recording successfully detected the pedicle breach, leading to repositioning of the pedicle screw. It was unfortunate that the patient suffered new paralysis, but it should be pointed out that the timely detection and removal of the breaching screw most likely prevented more severe and permanent nerve root damage, avoided bringing the patient back for additional surgery to correct the problem with associated cost, and created a better chance of recovery from the incomplete nerve root injury.

Despite many available neurophysiological techniques, there is still no entirely satisfactory way to monitor spinal nerve root function [8]. Free-run and triggered electromyography (EMG) is standard with limitations; MEP and mixed nerve SSEP may provide useful information; dermatomal SSEP, F waves, reflexes (H or bulbocavernosus reflex) are also optional techniques [9]. We listed journal articles of new lumbar nerve root deficits with description of neurophysiological monitoring status in Table 1. Cervical nerve root deficits have similar characteristics but are not included here.

Electrically triggered EMG (tEMG, also known as stimulated EMG, or evoked EMG) has become a standard technique for prediction of malpositioned pedicle screws. A positive result with a stimulus threshold of 4–5 mA has a specificity of nearly 100% for pedicle wall defect [10,11]. There were some reports of new nerve root deficits with true positive triggered EMG finding [12–14], and rare false-negatives [12,15]. Immediate removal of malpositioned pedicle screws may greatly reduced the possibility of postoperative nerve root deficits. Triggered EMG may also be recorded to direct nerve roots stimulation, to identify individual nerve roots and to check their integrity.

Spontaneous EMG (sEMG, or free-run EMG) is standard for spinal nerve root monitoring, which should be recorded from myotomes innervated by the nerve roots involved in the specific surgery. Neurotonic discharges indicate nerve root irritation, which can be minor and reversible and surgical action can be taken to relieve the irritation, or can be severe with nerve root dam-

**Table 1**  
Reported lumbar nerve roots deficits associated with neurophysiological signal changes following surgical procedures.

Authors	Year	Deficits	Total Cases	sEMG	tEMG	SSEP	MEP
Darden et al. [12]	1996	3	132		2 (+) 1 (-)		
Welch et al. [14]	1997	1	32	1 (+)	1 (+)		
Balzer et al. [16]	1998	2	44	2 (+)			
Bose et al. [17]	2001	1	61	1 (+)			
Iwasaki et al. [20]	2003	2	817				2 (-)
MacDonald et al. [8]	2007	3	206				1 (+) 2 (-)
Santiago-Perez et al. [15]	2007	1	54	1 (-)	1 (-)		
Sutter et al. [13]	2007	20	409	5 (+)	2 (+)	5 (+)	17 (+) 3 (-)
Lieberman et al. [7]	2008	10	35	6 (+) 4 (-)			10 (+)
Alemo et al. [18]	2010	3	86	3 (-)			
Duncan et al. [19]	2012	2	115	2 (-)		2 (+)	
Raynor et al. [10]	2013	4	12,375			4 (+)	

(+): Positive signal changes; (-): Negative signal changes.

sEMG: Spontaneous EMG; tEMG: Triggered EMG; SSEP: Somatosensory evoked potential; MEP: Motor evoked potential.

age. There were reports that sEMG activity were associated with new nerve root deficit [7,13,14,16,17]. However it should be cautious that false-negatives may happen; new nerve root deficit were reported without remarkable sEMG activities [7,15,18,19].

Mixed nerve SSEPs are generally considered insensitive to nerve root injury, because of radicular overlap. In this case, there was no remarkable change in posterior tibial nerve SSEP, which was not a surprise because it does not represent L3 nerve root function. However, there were published reports that decrease in amplitude of SSEPs were associated with new nerve root deficits in surgical cases of interbody fusion cage placement, deformity correction, or tumor resection [2,13,19].

Motor evoked potentials have similar limitations for nerve root monitoring. Each nerve root supplies a myotome of multiple muscles, and each muscle receives overlapping innervation from several adjacent nerve roots. Transcranial electrical stimulation activates the pyramidal tracts including the descending corticospinal track, activates spinal lower motor neurons to all myotomes, and only a portion of the motor units fire to generate the recorded MEPs. There were reports of nerve root deficits with associated intraoperative MEP changes [7,8,13]; but there were also reports of root deficits without remarkable MEP changes [8,13,20]. It is interesting that in our case, there was no remarkable intraoperative MEP changes, but postoperative MEP testing showed responses were absent from left quadriceps. It is rare yet possible that nerve root damage developed or worsened after the neurophysiological monitoring ended, during either closure or postoperative patient positioning, with inflammatory changes to the nerve roots. There was a report that paraparesis developed 13 h after a scoliosis surgery [21].

**4. Conclusion**

Together with SSEP and MEP, electromyography (sEMG and tEMG) should be a necessary part of multimodality protocol for monitoring lumbar spinal nerve roots. Knowledge and experience of the strength and limitations of each modality helps to optimize and further improve the value of IONM.

**Author contribution**

Yuguang Chen: study concept, data collection and analysis, data interpretation. Baoqing Wang: study concept, writing the manuscript, literature review. Junlin Yang: study concept, data interpretation. Yaolong Deng: data collection and analysis.

**Conflicts of interest**

The authors report no conflict of interest.

**Funding**

No funding was received for this study.

**Ethical approval**

Not applicable; this is a case report and literature review. All patient identifying details are omitted.

**Consent**

Written informed consent was obtained from the patient for publication of this case report and accompanying images. All patient identifying details are omitted.

**Guarantor**

Baoqing Wang and Yuguang Chen.

**Acknowledgments**

This work was reported in line with the SCARE criteria [22] and the corresponding checklist was completed by the authors.

The authors did not receive any funding from any organizations for this study, and there is no conflicts of interest.

The authors wish to thank Raymond C. Truex Jr, MD, Stephen P. Banco, MD, Stanley L. Grabias, MD, and Lawrence R. Wierzbowski, AuD, DABNM for their critical review of the manuscript, and Christina C. Wang, BS, for her editorial efforts.

**References**

- [1] D.K. Hamilton, J.S. Smith, C.A. Sansur, S.D. Glassman, C.P. Ames, S.H. Berven, et al., Rates of new neurological deficit associated with spine surgery based on 108,419 procedures: a report of the scoliosis research society morbidity and mortality committee, *Spine* 36 (15) (2011) 1218–1228.
- [2] B.L. Raynor, J.D. Bright, L.G. Lenke, R.K. Rahman, K.H. Bridwell, K.D. Riew, et al., Significant change or loss of intraoperative monitoring data: a 25-year experience in 12,375 spinal surgeries, *Spine* 38 (2) (2013) E101–E108.
- [3] F. Pastorelli, M. Di Silvestre, R. Plasmati, R. Michelucci, T. Greggi, A. Morigi, et al., The prevention of neural complications in the surgical treatment of scoliosis: the role of the neurophysiological intraoperative monitoring, *Eur. Spine J.* 20 (Suppl. 1) (2011) S105–S114.
- [4] E.D. Thuet, J.C. Winscher, A.M. Padberg, K.H. Bridwell, L.G. Lenke, M.B. Dobbs, et al., Validity and reliability of intraoperative monitoring in pediatric spinal deformity surgery: a 23-year experience of 3436 surgical cases, *Spine* 35 (20) (2010) 1880–1886.
- [5] J.R. Kamerlink, T. Errico, S. Xavier, A. Patel, A. Patel, A. Cohen, et al., Major intraoperative neurologic monitoring deficits in consecutive pediatric and adult spinal deformity patients at one institution, *Spine* 35 (2) (2010) 240–245.
- [6] B. Feng, G. Qiu, J. Shen, J. Zhang, Y. Tian, S. Li, et al., Impact of multimodal intraoperative monitoring during surgery for spine deformity and potential

- risk factors for neurological monitoring changes, *J. Spinal Disord. Tech.* 25 (4) (2012) E108–E114.
- [7] J.A. Lieberman, R. Lyon, J. Feiner, S.S. Hu, S.H. Berven, The efficacy of motor evoked potentials in fixed sagittal imbalance deformity correction surgery, *Spine* 33 (13) (2008) E414–E424.
- [8] D.B. Macdonald, B. Stigsby, I. Al Homoud, T. Abalkhail, A. Mokeem, Utility of motor evoked potentials for intraoperative nerve root monitoring, *J. Clin. Neurophysiol.* 29 (2) (2012) 118–125.
- [9] R.E. Leppanen, Intraoperative monitoring of segmental spinal nerve root function with free-run and electrically-triggered electromyography and spinal cord function with reflexes and F-responses. A position statement by the American Society of Neurophysiological Monitoring, *J. Clin. Monit. Comput.* 19 (6) (2005) 437–461.
- [10] B.L. Raynor, L.G. Lenke, K.H. Bridwell, B.A. Taylor, A.M. Padberg, Correlation between low triggered electromyographic thresholds and lumbar pedicle screw malposition: analysis of 4857 screws, *Spine* 32 (24) (2007) 2673–2678.
- [11] S.L. Parker, A.G. Amin, S.H. Farber, M.J. McGirt, D.M. Sciubba, J.P. Wolinsky, et al., Ability of electromyographic monitoring to determine the presence of malpositioned pedicle screws in the lumbosacral spine: analysis of 2450 consecutively placed screws, *J. Neurosurg. Spine* 15 (2) (2011) 130–135.
- [12] B.V. Darden 2nd, K.E. Wood, M.K. Hatley, J.H. Owen, J. Kostuik, Evaluation of pedicle screw insertion monitored by intraoperative evoked electromyography, *J. Spinal Disord.* 9 (1) (1996) 8–16.
- [13] M.A. Sutter, A. Eggspuehler, D. Grob, F. Porchet, D. Jeszenszky, J. Dvorak, Multimodal intraoperative monitoring (MIOM) during 409 lumbosacral surgical procedures in 409 patients, *Eur. Spine J.* 16 (Suppl. 2) (2007) S221–S228.
- [14] W.C. Welch, R.D. Rose, J.R. Balzer, G.B. Jacobs, Evaluation with evoked and spontaneous electromyography during lumbar instrumentation: a prospective study, *J. Neurosurg.* 87 (3) (1997) 397–402.
- [15] S. Santiago-Pérez, R. Nevado-Estévez, J. Aguirre-Arribas, M.C. Pérez-Conde, Neurophysiological monitoring of lumbosacral spinal roots during spinal surgery: continuous intraoperative electromyography (EMG), *Electromyogr. Clin. Neurophysiol.* 47 (7–8) (2007) 361–367.
- [16] J.R. Balzer, R.D. Rose, W.C. Welch, R.J. Scلابassi, Simultaneous somatosensory evoked potential and electromyographic recordings during lumbosacral decompression and instrumentation, *Neurosurgery* 42 (6) (1998) 1318–1324.
- [17] B. Bose, L.R. Wierzbowski, A.K. Sestokas, Neurophysiologic monitoring of spinal nerve root function during instrumented posterior lumbar spine surgery, *Spine* 27 (13) (2002) 1444–1450.
- [18] S. Alemo, A. Sayadipour, Role of intraoperative neurophysiologic monitoring in lumbosacral spine fusion and instrumentation: a retrospective study, *World Neurosurg.* 73 (1) (2010) 72–76.
- [19] J.W. Duncan, R.A. Bailey, R. Baena, Intraoperative decrease in amplitude of somatosensory-evoked potentials of the lower extremities with interbody fusion cage placement during lumbar fusion surgery, *Spine* 37 (20) (2012) E1290–E1295.
- [20] H. Iwasaki, T. Tamaki, M. Yoshida, M. Ando, H. Yamada, S. Tsutsui, et al., Efficacy and limitations of current methods of intraoperative spinal cord monitoring, *J. Orthop. Sci.* 8 (5) (2003) 635–642.
- [21] J. Mineiro, S.L. Weinstein, Delayed postoperative paraparesis in scoliosis surgery. A case report, *Spine* 22 (14) (1997) 1668–1672.
- [22] R.A. Agha, A.J. Fowler, A. Saeta, I. Barai, S. Rajmohan, D.P. Orgill, for the SCARE group, The SCARE statement: consensus-based surgical case report guidelines, *Int. J. Surg.* 34 (2016) 180–186.

#### Open Access

This article is published Open Access at [sciencedirect.com](https://www.sciencedirect.com). It is distributed under the [IJSCR Supplemental terms and conditions](#), which permits unrestricted non commercial use, distribution, and reproduction in any medium, provided the original authors and source are credited.