



# Defatting Vestibuloplasty for Functional and Esthetic Reconstruction of Tongue

Si-Yeok Park, Min-Keun Kim, Seong-Gon Kim, Kwang-Jun Kwon, Jin-Soo Byun<sup>1</sup>,  
Chan-Jin Park<sup>1</sup>, Young-Wook Park

Departments of Oral and Maxillofacial Surgery, <sup>1</sup>Prosthodontics, College of Dentistry, Gangneung-Wonju National University

## Abstract

The radial forearm free flap (RFFF) is a thin and pliable tissue with many advantages for tongue reconstruction. However, tongues reconstructed with RFFF occasionally need revision surgery because inadequate defect measurement at primary surgery can lead to bulkiness and limited movement of reconstructed tongue. In this case, the patient underwent partial glossectomy and RFFF reconstruction for treatment of tongue cancer five years prior. We could not make a lower denture for the patient, because the alveolo-lingual sulcus of tongue was almost lost. So we performed vestibuloplasty with a modified Kazanjian method on the lingual vestibule of the mandibular right posterior area, and defatting surgery to debulk the flap. After surgery, we observed that the color and texture of the revised tongue changed to become similar with adjacent tissue. The patient obtained a more functional and esthetic outcome. Accordingly, we present a case report with a review of relevant literature.

**Key words:** Radial forearm free flap, Defatting vestibuloplasty, Transition of skin flap

## Introduction

The tongue is crucial in pronunciation and the manipulation of the food bolus for mastication, and is critical in prevention of aspiration[1,2]. Small defects after ablative surgery usually are closed primarily without significant functional deficiency[3]. However, the larger the defect after resection surgery, the greater the morbidity in terms of function[4]. Therefore, microvascular free flap reconstruction usually is required if more than 50% of the tongue is resected[5,6]. Adequate reconstruction of tongue with a protuberant shape and sufficient volume is important for postoperative function[7].

The radial forearm free flap (RFFF) can be applied to any defect of the oral cavity because of its flexibility, thinness, and good vascularization[8]. However, tongues reconstructed with RFFF sometimes need revision surgery because inadequate defect measurement at primary surgery can lead to bulkiness and limited movement of the reconstructed tongue. Another limitation of the RFFF for tongue reconstruction is a non-esthetic color that does not match adjacent tissues[9].

In this case report, we present a patient who was treated by defatting vestibuloplasty five years after partial glossectomy and RFFF reconstruction. The skin flap of the patient's tongue over the past five years maintained the original

RECEIVED August 28, 2014, REVISED September 16, 2014, ACCEPTED October 15, 2014

Correspondence to Min-Keun Kim

Department of Oral and Maxillofacial Surgery, College of Dentistry, Gangneung-Wonju National University  
7 Jukheon-gil, Gangneung 210-702, Korea  
Tel: 82-33-640-2753, Fax: 82-33-642-6410, E-mail: omfsmk@gwnu.ac.kr

Copyright © 2014 by The Korean Association of Maxillofacial Plastic and Reconstructive Surgeons. All rights reserved.

© This is an open access article distributed under the terms of the Creative Commons Attribution Non-Commercial License (<http://creativecommons.org/licenses/by-nc/3.0>) which permits unrestricted non-commercial use, distribution, and reproduction in any medium, provided the original work is properly cited.

color and texture of the forearm skin, but after defatting the RFFF, the color and texture of the skin flap changed gradually to become similar to adjacent tissues. This interesting phenomenon may helpful for more esthetic reconstruction of the tongue. Accordingly, we present a case report with a review of literature.

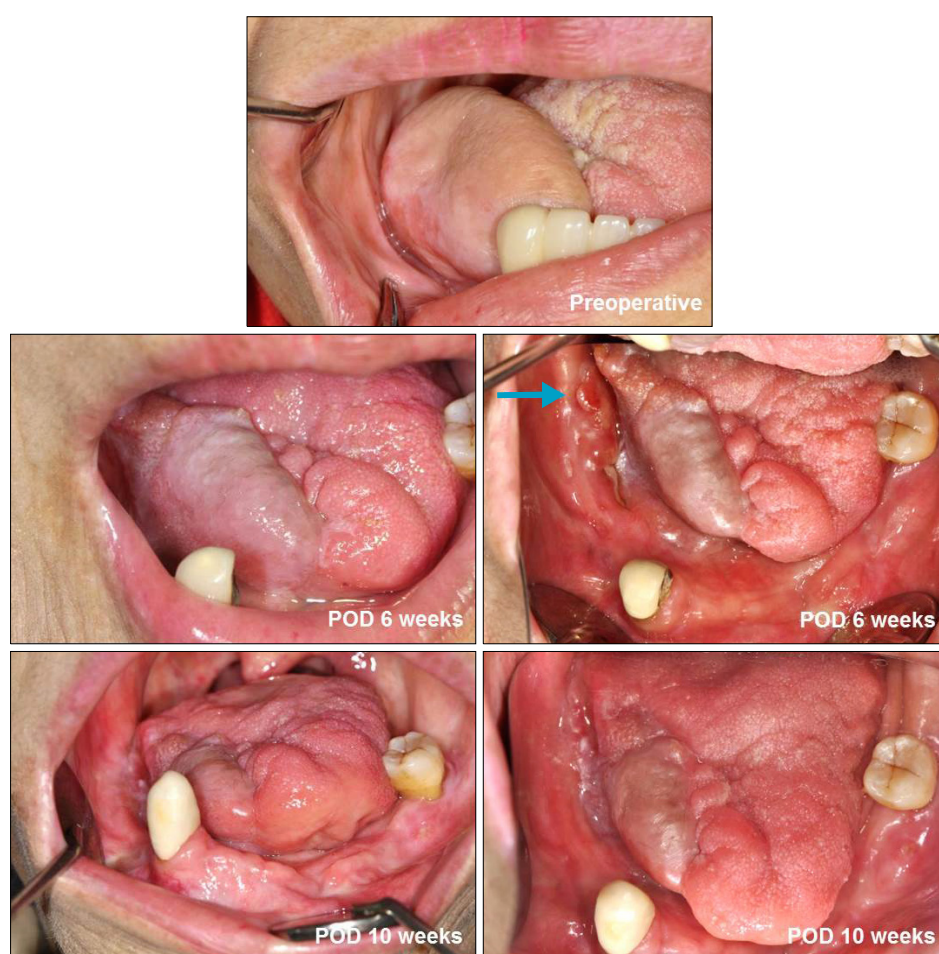
## Case Report

A 70-year-old female patient was referred to the Department of Oral and Maxillofacial Surgery of the Gangneung-Wonju National University Dental Hospital to receive vestibuloplasty to fit a mandibular denture. The patient underwent partial glossectomy and RFFF reconstruction for treatment of tongue cancer five years prior. Routine dental examination showed that the alveolo-lingual sulcus of the reconstructed area was almost lost, and the reconstructed portion of the tongue was overcontoured (Fig. 1). Therefore we could not prepare a lower denture

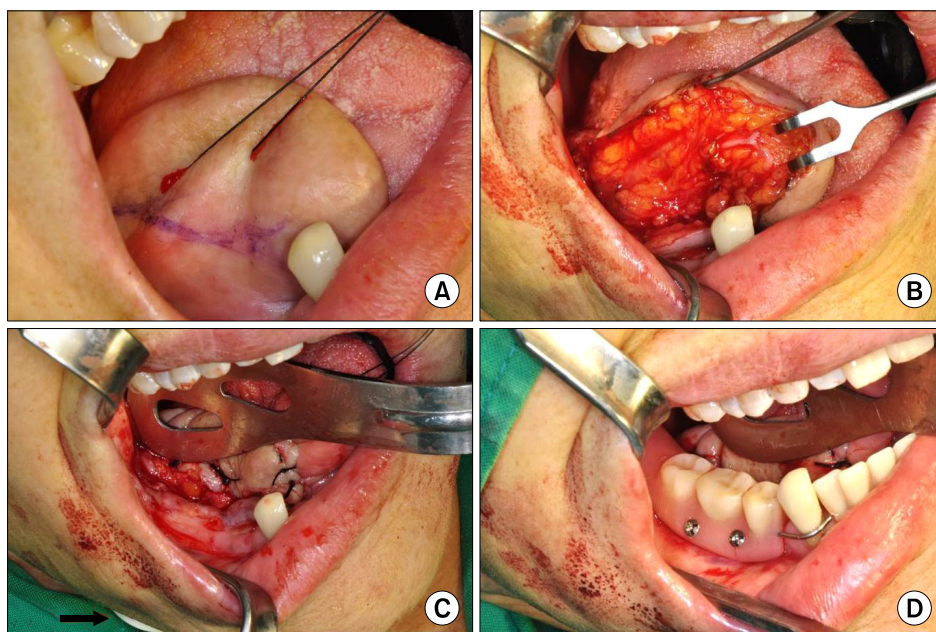
for the patient. An additional complaint was that her pronunciation was unclear because of the limitation in tongue movement.

We determined to perform the defatting of RFFF with vestibuloplasty by a modified Kazanjian method[10]. Mucosal incision was performed on the lower lateral side of RFFF (Fig. 2A), and the fat tissue was removed for debulking (Fig. 2B). The flap was repositioned inferiorly and buttons placed percutaneously to secure the flap downward (Fig. 2C). Immediately after surgery, to maintain the denture space, a temporary denture was fixed with micro screws for two weeks (Fig. 2D). During the follow-up period, additional laserplasty was performed using CO<sub>2</sub> laser because there were some irregular surfaces under the removable partial denture (Fig. 1, arrow).

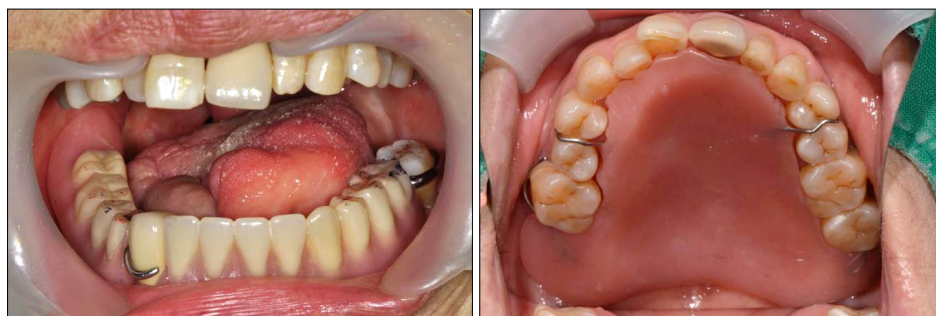At three months after surgery, a removable partial mandible denture was fabricated in Department of Prosthodontics. During the follow-up, we observed that the texture and color of the reconstructed portion of tongue



**Fig. 1.** The skin of the forearm flap changed gradually, showing similar architecture with adjacent tissue after revised surgery. Some irregular surfaces were observed under the removable partial denture (arrow). POD, postoperative day.



**Fig. 2.** (A) Incision line for the de-fatting vestibuloplasty. (B) Fat tissues were removed for de-bulking of the radial forearm free flap to make enough space for the removable partial denture. (C) The flap was repositioned inferiorly and a button (arrow) placed percutaneously to secure downward the flap. (D) Temporary removable partial denture was fixed with microscrews for maintaining the flap in a stable position.



**Fig. 3.** A palatal augmentation prosthesis was made to improve the pronunciation of patient.

was gradually becoming similar to adjacent tissues (Fig. 1). In addition, a palatal augmentation prosthesis (Fig. 3) was made to improve the pronunciation of patient. After wearing the prosthesis, the patient's pronunciation noticeably improved.

## Discussion

The treatment goal of tongue reconstruction should be the preservation of function such as swallowing, pronunciation and esthetic blending with adjacent tissues. The RFFF can be used in any part of the oral cavity for more functional and esthetic reconstruction[11]. It creates a neo-tongue with good form and increased bulk posteriorly at the base[12]. In addition, if the medial and/or lateral antebrachial cutaneous nerves of the flap are coapted to the lingual nerve, sensory return is possible[12]. The folding

techniques used in reconstruction of the tongue with microvascular free flaps is useful with recovery of adequate speech and swallowing in most patients[13].

While RFFF reconstruction of tongue has many advantages, it cannot fully recover function and esthetics of the tongue. The non-esthetic color of the skin flap is one limitation of RFFF. Tongue mobility is an important component in maintaining tongue function[3]. If reconstruction is performed with insufficient flap size, tongue mobility may be compromised. Therefore, tongue reconstruction should be performed with sufficient flap volume and size[14]. If surgery is performed with excessive flap volume, revision surgery will be required[6]. In this case, the patient's chief complaint was excessive volume of the reconstructed tongue. So we performed vestibuloplasty with defatting to make space for a denture.

There are reports about clinical changes of the skin of

the RFFF. It often takes on an appearance similar to oral mucosa following transfer to the oral cavity[15]. These changes are thought to be due to inflammation resulting from the oral environmental factors such as saliva, oral microflora, mechanical and chemical stimuli associated with food ingestion, and *Candida* infection[16]. The rich blood supply for the skin of the forearm[17] enables the skin to undergo these changes[15]. Histologically, mucosa-like change of RFFF does not represent true metaplasia, permanent change in epithelial type[18]. In many cases these changes are reversible, and seem to be directly related to the degree of inflammation in the dermis[18]. In split thickness skin graft, the skin maintains the epidermal phenotype and does not assume the histologic characteristics of mucosa[19].

In this case, the mechanism of the color change was unclear. It might be a little different from the mechanism of the above cases, because the skin of the RFFF was unchanged during the previous five years (Fig. 1). The color change of the RFFF did not start until the defatting surgery. During the observation after the defatting surgery, we saw that the color and texture of the revised tongue changed gradually to become similar with the adjacent tissue (Fig. 1). There are few publications about this change after revision surgery. In our opinion, this change might be due to the original healing nature of the transplanted RFFF as a response to the severe injury within the flaps from the defatting surgery. Also, because the stem cells in fat tissue can differentiate into many type of cells[20], the flap might be affected by stem cells within the subcutaneous fat of the RFFF. After reconstructive surgery for oral cancer, usually we have an opportunity of secondary surgery for implant or bone graft. In that time, defatting surgery may be contribute to make the skin match better.

Pronunciation is also very important for the reconstruction of tongue. In this case, there was distinct improvement of pronunciation after using the palatal augmentation prosthesis (Fig. 3). From this valuable experience, we recommend this palatal augmentation prosthesis for the patients whose tongue length is not sufficient for adequate palatal contact.

In conclusion, defatting vestibuloplasty may be a useful reconstructive technique for more functional and esthetic reconstruction of the tongue. We urge cautious inter-

pretation, as the presented case is only a single case and the evidence is limited. Therefore, a well-controlled prospective study is required to examine this phenomenon closely.

## Acknowledgements

This study was supported by a grant from the Next-Generation BioGreen21 Program (No. PJ009013), Rural Development Administration, Republic of Korea.

## References

1. Haughey BH. Tongue reconstruction: concepts and practice. *Laryngoscope* 1993;103:1132-41.
2. Miller AJ. Oral and pharyngeal reflexes in the mammalian nervous system: their diverse range in complexity and the pivotal role of the tongue. *Crit Rev Oral Biol Med* 2002;13:409-25.
3. McConnel FM, Pauloski BR, Logemann JA, *et al.* Functional results of primary closure vs flaps in oropharyngeal reconstruction: a prospective study of speech and swallowing. *Arch Otolaryngol Head Neck Surg* 1998;124:625-30.
4. Freedlander E, Espie CA, Campsie LM, Soutar DS, Robertson AG. Functional implications of major surgery for intraoral cancer. *Br J Plast Surg* 1989;42:266-9.
5. Michiwaki Y, Ohno K, Imai S, *et al.* Functional effects of intraoral reconstruction with a free radial forearm flap. *J Craniomaxillofac Surg* 1990;18:164-8.
6. Hsiao HT, Leu YS, Chang SH, Lee JT. Swallowing function in patients who underwent hemiglossectomy: comparison of primary closure and free radial forearm flap reconstruction with videofluoroscopy. *Ann Plast Surg* 2003;50:450-5.
7. Kimata Y, Sakuraba M, Hishinuma S, *et al.* Analysis of the relations between the shape of the reconstructed tongue and postoperative functions after subtotal or total glossectomy. *Laryngoscope* 2003;113:905-9.
8. Seikaly H, Rieger J, O'Connell D, Ansari K, Alqahtani K, Harris J. Beavertail modification of the radial forearm free flap in base of tongue reconstruction: technique and functional outcomes. *Head Neck* 2009;31:213-9.
9. Swartz WM, Banis JC, Newton ED, Ramasastry SS, Jones NF, Acland R. The osteocutaneous scapular flap for mandibular and maxillary reconstruction. *Plast Reconstr Surg* 1986;77:530-45.
10. Al-Mahdy Al-Belasy F. Mandibular anterior ridge extension: a modification of the Kazanjian vestibuloplasty technique. *J Oral Maxillofac Surg* 1997;55:1057-9.
11. Urken ML, Moscoso JF, Lawson W, Biller HF. A systematic approach to functional reconstruction of the oral cavity following partial and total glossectomy. *Arch Otolaryngol Head Neck Surg* 1994;120:589-601.
12. Sanger JR, Campbell BH, Ye Z, Yousif NJ, Matloub HS. Tongue reconstruction with a combined brachioradialis-radial forearm flap. *J Reconstr Microsurg* 2000;16:7-13.

13. Haughey BH, Taylor SM, Fuller D. Fasciocutaneous flap reconstruction of the tongue and floor of mouth: outcomes and techniques. *Arch Otolaryngol Head Neck Surg* 2002;128:1388-95.
14. Miloro M, Ghali GE, Larsen PE, Waite PD, editors. *Peterson's principles of oral and maxillofacial surgery*. 2nd ed. Hamilton, (ON), London: B.C Decker Inc; 2004.
15. Shibahara T, Mohammed AF, Katakura A, Nomura T. Long-term results of free radial forearm flap used for oral reconstruction: functional and histological evaluation. *J Oral Maxillofac Surg* 2006;64:1255-60.
16. Wei WI, Lam KH, Lau WF. Fate of skin element of pectoralis major flap in intraoral reconstruction. *Arch Otolaryngol Head Neck Surg* 1989;115:360-3.
17. Lamberty BG, Cormack GC. The forearm angiotomes. *Br J Plast Surg* 1982;35:420-9.
18. Badran D, Soutar DS, Robertson AG, *et al*. Behavior of radial forearm skin flaps transplanted into the oral cavity. *Clin Anat* 1998;11:379-89.
19. Petruzzelli GJ, Johnson JT, Myers EN, Kline JM. Histomorphometric analysis of intraoral split-thickness skin grafts. *Head Neck* 1992;14:119-24.
20. Samman N, Cheung LK, Tideman H. The buccal fat pad in oral reconstruction. *Int J Oral Maxillofac Surg* 1993;22:2-6.