



Contents lists available at [ScienceDirect](http://www.sciencedirect.com)

Trauma Case Reports

journal homepage: <http://www.journals.elsevier.com/trauma-case-reports/>



Case Report

Transcarotid balloon occlusion of the brachiocephalic artery to control bleeding due to sharp injuries of the right subclavian artery☆

Denis A. Skrypnik*, Roman A. Vinogradov, Victoria P. Magamet, Alexey L. Kovalenko

*Department of Vascular Surgery, State Budget Institution of Public Health Department, Research Institute Regional Clinical Hospital №1 after prof. S.V. Ochapovsky, Krasnodar, Russian Federation
St. 1 May 167, 350086 Krasnodar, Russian Federation*

ARTICLE INFO

Article history:

Accepted 20 July 2015

Available online 29 August 2015

Keywords:

Sharp subclavian artery injury

Transcarotid balloon occlusion

Balloon bleeding control

Balloon occlusion of the brachiocephalic artery

ABSTRACT

We present a new manoeuvre of transcarotid balloon occlusion of the brachiocephalic artery to control bleeding due to sharp injuries of the right subclavian artery.

To control the bleeding, we employed a temporary balloon occlusion of the brachiocephalic artery with a 6.0 Fogarty balloon catheter, which was introduced through ECA retrogradely into the aorta, inflated and pulled back.

Described manoeuvre is simple, rapid performed, relatively safe and it is capable of decreasing the morbidity and mortality rates of patients with sharp injuries to the right subclavian artery.

© 2015 The Authors. Published by Elsevier Ltd. This is an open access article under the CC BY-NC-ND license

(<http://creativecommons.org/licenses/by-nc-nd/4.0/>).

Introduction

Military or civilian subclavian artery injuries are frequently life-threatening entities that are accompanied by high morbidity and mortality. Syntopic peculiarities can result in huge losses of blood and difficulty in the control of bleeding. Here, we present a new manoeuvre involving transcarotid balloon occlusion of the brachiocephalic artery to control bleeding due to sharp injuries of the right subclavian artery.

☆ This manoeuvre and case report were reported as the e-poster on Controversies and Updates in Vascular Surgery January 22–24 2015 in Paris, France!!!

* Corresponding author. Tel.: +7 918 383 36 90.

E-mail address: skrypnik.denis@mail.ru (D.A. Skrypnik).

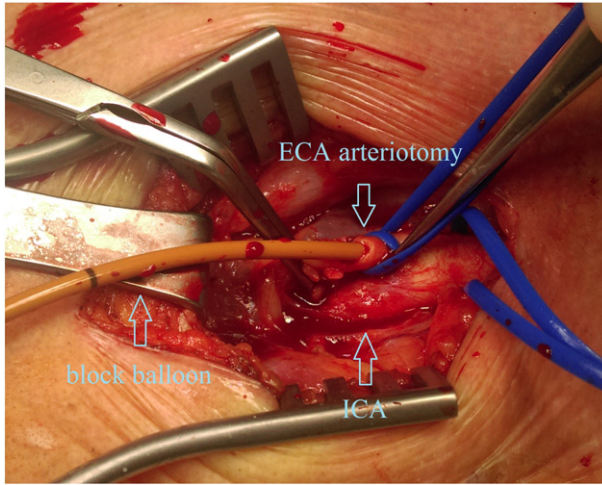


Fig. 1. Retrogradely insertion 6.0 Fogarty balloon catheter through the arteriotomy of the a.carotis externa.

Surgical technique

A 25 year-old male was admitted to a general surgery hospital 40 minutes after suffering knife trauma to the right supraclavicular region and profuse bleeding from a linear wound above the middle third of the clavicle. The patient was in severe haemorrhagic shock, unconsciousness, and without a pulse in the right arm; however, he did not exhibit X-ray signs of haemothorax. He was immediately intubated and transported to an operation room.

To control the bleeding, we employed a temporary transcarotid balloon occlusion of the brachiocephalic artery. The CCA, ICA, and ECA were exposed using standard techniques, and tourniquets were applied. After a 2500 EU bolus of heparin was delivered, a transverse ECA transverse arteriotomy was made (Fig. 1.) and a 6.0 Fogarty balloon catheter was introduced retrogradely into the aorta, inflated and pulled back (Fig. 2). Next, the wound compression was removed, and the deep narrow wound canal was revised to reveal the

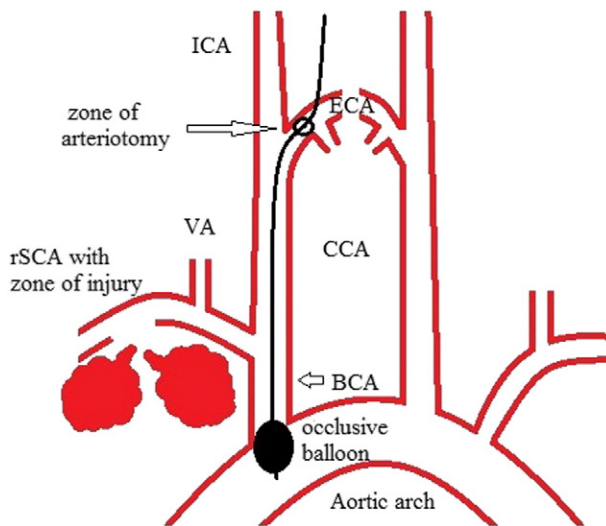


Fig. 2. Principal scheme of transcarotid balloon occlusion of the brachiocephalic artery.

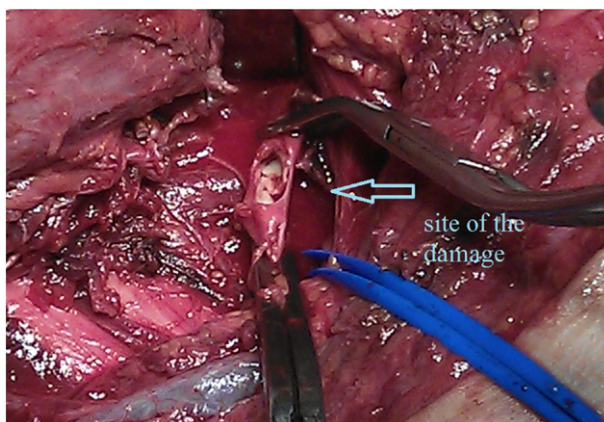


Fig. 3. Damaged area of a.subclavia after separation and clamping.

full right subclavian artery transection in the interscalene zone. Transected fragments were selectively clamped (Fig. 3) and the balloon in the brachiocephalic artery was deflated. The occlusion time was 4 minutes, which was sufficient to reach and selectively cross-clamp the artery fragments. The right subclavian artery was restored in an end-to-end fashion with a 6.0 Prolene suture, and the ECA arteriotomy was closed with a 6.0 Prolene suture using standard techniques. Postoperatively, the patient exhibited no central neurological deficits, but signs of right-sided plexitis due to the prolonged compression of the supraclavicular region were present. This plexitis completely resolved within 3 weeks. The patient was discharged on the 14th day.

Discussion

Sharp subclavian artery injuries are associated with high mortality and morbidity rates [1, 2]. The complex syntopy of this type of injury makes the control of bleeding with simple wound compression difficult. Balloon-assisted endovascular bleeding control and endovascular repair [1–3] are a well-known techniques, but this techniques may be impossible to apply in military circumstances, in unspecialised general surgery hospitals or in situations in which an endovascular specialist is not immediately available.

The use of Foley catheters for the control of bleeding [4] is commonly problematic; on the one hand, there is no concrete channel or cavity after tissue interposition, and on the other hand, the Foley balloon itself can be an obstacle to wound revision. Despite these limitations, endovascular control of bleeding is preferable because all compression materials must be removed from the wound prior to revision, which consequently leads to repeated bleeding and patient deterioration in the absence of a proximal control.

The anatomy of the right subclavian artery, which arises from the brachiocephalic artery in 74% of patients [5], allows for the use of the ECA as a relatively safe access point for balloon occlusion of the brachiocephalic artery. As discussed above, transcarotid balloon occlusion of the brachiocephalic artery can be quickly implemented, can be performed even by general surgeons without X-ray control and, importantly, this manoeuvre allows the control of bleeding to be achieved during wound revision. Additionally, as demonstrated in the present case, intraoperative stroke can be avoided in patients in haemorrhagic shock. Further reports are needed, but we believe that the simple, relatively safe manoeuvre of transcarotid balloon occlusion of the brachiocephalic artery, which can be performed under ultrasound control in some circumstances, is capable of decreasing the morbidity and mortality rates of patients with sharp injuries to the right subclavian artery.

Ethical approval for publication of this case report was obtained from local ethic committee.

Conflict of interest

There is no conflict of interest to declare.

References

- [1] Chatt A. Johnson, M.D., F.A.C.S, Endovascular management of peripheral vascular trauma, *Semin. Interv. Radiol.* 27 (2010) 38–43.
- [2] Jack L. Cronenwett, K. Wayne Johnston, *Rutherford's Vascular Surgery*, 7th edition Vol. 2, 2010 2327–2329.
- [3] S. Chakraverty, K. Flood, D. Kassel, et al., CIRSE guidelines: quality improvement guidelines for endovascular treatment of traumatic hemorrhage, *Cardiovasc. Intervent. Radiol.* 35 (2012) 427–482.
- [4] P. Navsaria, M. Thoma, A. Nicol, Foley catheter balloon tamponade for life-threatening hemorrhage in penetrating neck trauma, *World J. Surg.* 30 (7) (Jul. 2006) 1265–1268.
- [5] G.C. Jakanany, W. Adair, Frequency of variations in aortic arch anatomy depicted on multidetector CT, *Clin. Radiol.* 65 (2010) 481–487.