



Original Article

Outcome analysis of antibiotic-loaded poly methyl methacrylate (PMMA) beads in musculoskeletal infections

Krunal H. Patel, MS^a, Shyamasunder N. Bhat, MS^{a,*} and Mamatha H, MD^b

^a Department of Orthopaedics, Kasturba Medical College, Manipal Academy of Higher Education, Manipal, India

^b Department of Anatomy, Kasturba Medical College, Manipal Academy of Higher Education, Manipal, India

Received 5 September 2020; revised 20 October 2020; accepted 26 October 2020; Available online 19 November 2020



المخلص

أهداف البحث: على الرغم من توافر مجموعة واسعة من المضادات الحيوية، لا يتم الشفاء من العدوى العظمية الهيكلية بنجاح. إن إزالة الأوشطة، والأنسجة النخرية المصابة والغرسات ضرورية. وقد أجريت هذه الدراسة لتقييم فعالية خرز البوليمر ميثيل ميثاكريلات، ولتحديد المتغيرات التي تؤثر على علاج وتكرار الالتهابات العظمية الهيكلية.

طرق البحث: ضمت هذه الدراسة 82 مريضاً يعانون من التهاب العظم والنقي المزمن، الذين عولجوا على مدى ست سنوات في مستشفى الرعاية الثالثة. تابعنا 71 مريضاً لمدة عام. وتم تقييم البيانات السريرية الدوائية لمكافحة العدوى وشفاء العظام في زيارة المتابعة الأخيرة. تم تقييم العلاقة بين حساسية المضادات الحيوية والمقاومة وتكرار العدوى لتراكيب جينتاميسين + سيفروكسيم، وجينتاميسين + فانكوميسين.

النتائج: كان لدى 53 (62.4%) من المرضى طريق خارجي للعدوى، بينما قُدم 26 (31.7%) من المرضى مع إفرازات جيبية وقت المراجعة. تم التحقق عند 42 (51%) من المرضى من التشخيص مع مزرعة بكتيرية إيجابية. بالإضافة إلى ذلك، استخدمنا خزعات المضادات الحيوية من الجينتاميسين + السيفوروكسيم في 74 (90%) من المرضى، في حين أن في 8 (10%) من المرضى استخدمنا الجينتاميسين + الفانكوميسين على أساس المزرعة ونتائج الحساسية. وتم العثور على عودة العدوى عند خمس حالات من الجينتاميسين + السيفوروكسيم واثنين من حالات الجينتاميسين + الفانكوميسين.

الاستنتاجات: المضادات الحيوية التي تحتوي على خرز البوليمر ميثيل ميثاكريلات فاعلة في علاج التهاب العظم والنقي المزمن وفي منع تكرار العدوى.

ومن الضروري تحديد العوامل المختلفة المسؤولة عن تكرار الإصابة. وهذا قد يساعد الأطباء في التنبؤ بتكهن المرض وتقليل خطر النتائج السلبية.

الكلمات المفتاحية: خرز محمل بالمضادات الحيوية؛ إصابة تثبيث العظام بالعدوى؛ عدوى العضلات والعظام؛ التهاب العظم والنقي؛ بولي ميثيل ميثاكريلات

Abstract

Objective: Despite the availability of an extensive array of antibiotics, musculoskeletal infections are not cured successfully. It is necessary to remove sequestra, infected necrotic tissue, and implants. This study was undertaken to assess the efficacy of poly methyl methacrylate (PMMA) beads and identify the variables that influence eradication and recurrence in the treatment of musculoskeletal infections.

Methods: This study was conducted on 82 patients with chronic osteomyelitis who were treated over a period of 6 years at our tertiary care hospital. We followed up with 71 patients for one year. Clinicoradiological data for the control of infection and bone healing were assessed at the final follow up visit. The correlation between antibiotic sensitivity/resistance and infection was evaluated for Gentamicin + Cefuroxime and Gentamicin + Vancomycin combinations. Chi-squared testing, using SPSS version 16.0, was used for statistical analysis, and a *p*-value < 0.05 was considered significant.

Results: Fifty-three patients (65.4%) had an exogenous route of infection. Fifty-six patients (68.51%) presented with a discharging sinus on first presentation. In 42 patients (59%), the diagnosis was verified with a positive bacterial culture. In addition, we used antibiotic beads of Gentamicin + Cefuroxime in 74 patients (90%), while in

* Corresponding address: Department of Orthopaedics, Kasturba Medical College, Manipal Academy of Higher Education, Manipal, 576104, India.

E-mail: shyambhat.n@manipal.edu (S.N. Bhat)

Peer review under responsibility of Taibah University.



8 patients (10%), we used Gentamicin + Vancomycin, based on culture and sensitivity results. Recurrence was found in five cases of Gentamicin + Cefuroxime and two cases of Gentamicin + Vancomycin ($p = 0.065$).

Conclusion: Antibiotics containing PMMA beads are effective in the treatment of chronic osteomyelitis and in preventing the recurrence of infection. It is imperative to identify various factors responsible for the recurrence of infection. This may help clinicians predict the prognosis of the disease and minimise the risk of adverse outcomes.

Keywords: Antibiotic-loaded bead; Infected osteosynthesis; Musculoskeletal infection; Osteomyelitis; Poly methyl methacrylate

© 2020 The Authors.

Production and hosting by Elsevier Ltd on behalf of Taibah University. This is an open access article under the CC BY-NC-ND license (<http://creativecommons.org/licenses/by-nc-nd/4.0/>).

Introduction

Osteomyelitis, unlike some other infections, is not consistently treated successfully despite the extensive array of antibiotics available in the present era. Though such drugs have improved the prognosis for acute osteomyelitis, there is little literature about their effectiveness in the treatment of osteomyelitis.¹ A persistent draining sinus from the focus of bone infection and the sequestration of devitalised bone are the main features of chronic osteomyelitis. It is necessary to remove foreign material and sequestra, excise all infected and necrotic tissue, and remove alloplastic implants. Meticulous surgical debridement is the most effective treatment for chronic osteomyelitis. Any procedure that falls short of achieving this will not eradicate the infection, irrespective of the method of antibiotic application.^{2,3}

Buchholz and Elson⁴ proposed the local delivery of antibiotics to prevent infection associated with replacement arthroplasty. Klemm later utilised this concept in the treatment of chronic osteomyelitis.⁵ It was said that the outcome of chronic osteomyelitis is infection-free bone and optimum bone strength with later remodelling into normal bone. A large proportion of patients who are treated with surgical debridement adjunct with antibiotic beads will end up with near normal, strong, healthy bone. Hence, this study was undertaken to assess the efficacy and limitations of poly methyl methacrylate (PMMA) beads in the treatment of musculoskeletal infections of variable aetiology.

This study was undertaken (i) to determine the efficacy of PMMA beads in musculoskeletal infections and evaluate their efficacy in sensitive and resistant organisms, as well as (ii) to identify the variables that influence the eradication and recurrence of infection in patients with chronic osteomyelitis.

Materials and Methods

Study participants

This study targeted 82 patients with chronic osteomyelitis and various aetiologies. The patients were treated at our university teaching hospital over a period of 6 years. We made the diagnosis of chronic osteomyelitis based on the presence of clinical and radiological features for more than 6 weeks.

The patients are divided into three groups, as follows, depending on the primary cause:

Group 1: Patients with haematogenous osteomyelitis

Group 2: Infection following open fractures

Group 3: Patients with infected osteosynthesis

Exclusion criterion: Patients who could not be found for follow-up were excluded.

In this study, 82 patients were treated for chronic osteomyelitis from June 2007 to June 2013 using handmade antibiotic-loaded PMMA beads. Ten patients could not be located for follow up, and one patient expired. Hence, final analysis was done on 71 patients.

Each patient was categorised as a type of physiological host, as follows, using the classification by Cierney et al.⁶:

Type A: Normal immune status

Type B: A host with systemic compromise, local compromise, or both

Type C: A host for whom the morbidity of treatment is worse than that imposed by the disease itself

All cases were planned for elective surgery. Discharge from the sinus was taken for culture, and sensitivity and empirical broad-spectrum antibiotics were started. Radiographic assessment was done to identify sequestra and early signs of implant loosening.

Preparation of beads

Indigenously-made antibiotic-loaded bone cement beads were used in all cases. These beads were prepared just before commencing surgery in the operating room in a sterile environment. Cefuroxime powder (from three 1.5 g vials) or Vancomycin (1 g vial) was mixed homogeneously with polymer powder (20 g) in a sterile bowl. Monomer liquid (10 ml) was then added and mixed. When the mixture was in a non-sticky, doughy state, small beads (5 mm–8 mm) were hand rolled. The beads were threaded on a stainless steel wire, and the ends of the wire were twisted into a knot.¹

Interventions

We performed two-staged surgery in all cases. In the first stage, the sinus was excised, and the underlying bone was explored via the old scar (Figure 1a). Sequestra and implants, whenever present, were removed in view of being nidus

conducive to persistent infection. Unhealthy granulation tissue was removed and sent for histopathology, and culture and sensitivity. The bone cavities were thoroughly curetted and washed with povidone iodine (5%), hydrogen peroxide, and saline. To prevent any entanglement of the PMMA chain, the bony edges were rounded off. The antibiotic bead chain(s) was/were implanted inside the cavity, whenever possible (Figure 1b). The number of beads and the size of the chain were determined by the size of the cavity. All wounds were closed, primarily with an overflow drain without negative suction.

Systemic antibiotics, depending upon the sensitivity of the organisms, were given for seven days. Broad-spectrum antibiotics were administered if the organisms were found to be resistant to all antibiotics. Drains were removed after 24–48 h. Suture removal was done after ten days.

The second-stage procedure was done after three weeks. The PMMA beads were removed, a limb reconstruction system (LRS) was applied, and autologous bone grafting was done whenever needed. Erythrocyte sedimentation rate (ESR) reduction was recorded for each patient at the time of bead removal. An operation theatre culture sensitivity report was produced as follow up for all patients. Persistence and recurrence of infection were recorded.

All patients were followed up with at an interval of six weeks during the initial three months, then every three months for at least one year. The clinical and radiological parameters of infection and bony healing were assessed at the final follow up (Figure 2a–c).

Statistical analysis

The correlation for recurrence of infection was evaluated between Gentamicin + Cefuroxime and Gentamicin + Vancomycin. Chi-squared testing using the Statistical Package for Social Sciences (SPSS) version 16.0 was done for statistical analysis, and $p < 0.05$ was considered significant.

Results

The average age in our study group was 30.05 years (Figure 3). The male to female ratio was 4:1. Among long bones, the femur was the most common site of infection in 34 patients (41.5%), followed by the spine in 21 patients (25.6%). Infection in the remaining patients was scattered among other bones (Figure 4). The associated comorbidities in 37 patients are shown in Table 1.

Fifty-four patients (65.9%) had an exogenous route of infection, while 28 (34.1%) had a hematogenous route. The most commonly found host was Type B [48 (58.5%)]. In our study, 6 patients (7.3%) had a normal ESR value at the time of presentation, while 76 (92.7%) presented with a higher than normal ESR. Among the patients with whom follow up was done, 36 (50.70%) showed a more than 50% reduction in ESR at three weeks, compared to the preoperative value.

In our study, 56 patients (68.3%) had a discharging sinus at the time of presentation. In 74 patients (90.2%),

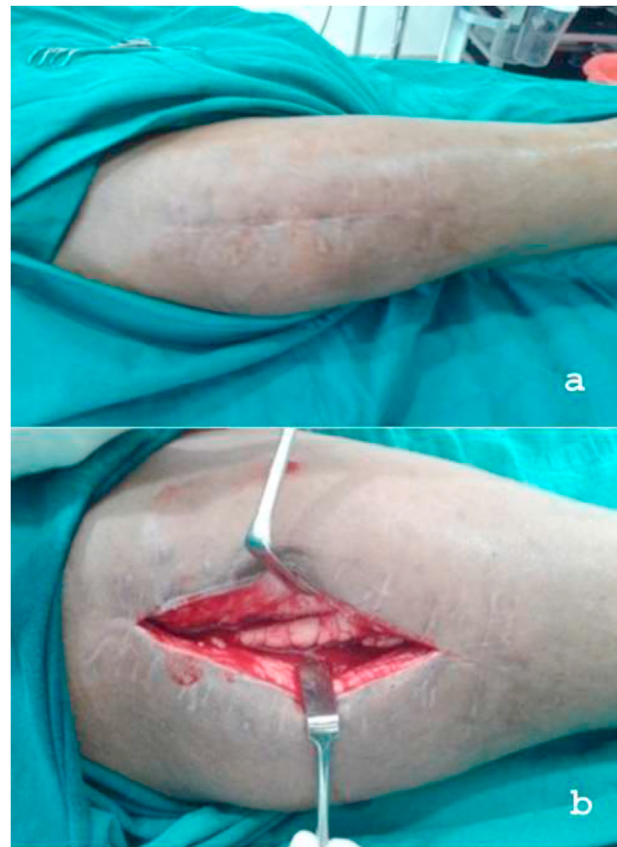

Figure 1: Intraoperative photographs of a case treated for chronic osteomyelitis of the femur (**a**: before skin incision, **b**: after curettage application of chain of PMMA beads).

Gentamicin + Cefuroxime antibiotic beads were used, while Gentamicin + Vancomycin beads were used in 8 patients (9.8%), depending on sensitivity.

Eleven patients (13.4%) in the first group could not be found for follow up. Out of the remaining 63 patients in whom Gentamicin + Cefuroxime was used, 58 (92.1% efficacy) were cured of the infection. Out of the 8 patients in whom Gentamicin + Vancomycin was used, 6 were free of infection at the time of the final follow up.

In 42 (59.2%) out of the 71 patients with whom follow up was done, the diagnosis could be verified with a positive bacterial culture. Recurrence occurred in 5 patients (7.9%) patients in whom Gentamicin + Cefuroxime was used and in the patients in whom Gentamicin + Vancomycin was used ($p = 0.065$). The majority of recurrence was found with the methicillin-resistant *Staphylococcus aureus* (MRSA) microbe in 5 out of 20 patients, followed by methicillin-sensitive *S. aureus* (MSSA) in 1 out of 12 patients. One patient with *Proteus mirabilis* growth also experienced infection recurrence.

Infection recurrence was more common in Gentamicin-resistant patients (5 out of 27) than in Gentamicin-sensitive patients (2 out of 16) ($p = 0.132$). The remaining 22 (out of 27) patients who showed Gentamicin resistance did not develop infection recurrence.

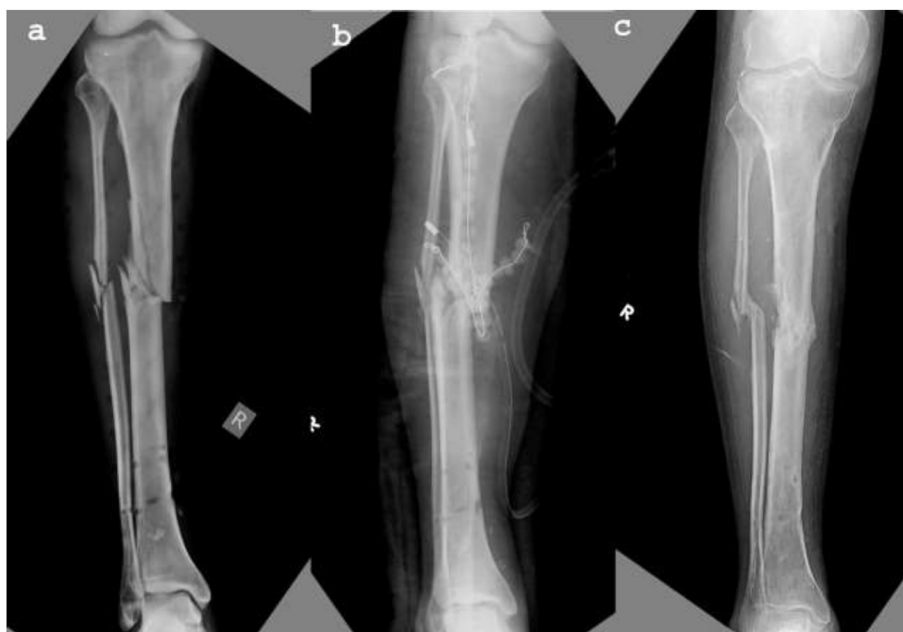


Figure 2: Anteroposterior radiographs of a case treated for infected open fracture of the tibia (a: preoperative, b: postoperative, and c: follow-up at 1 year).

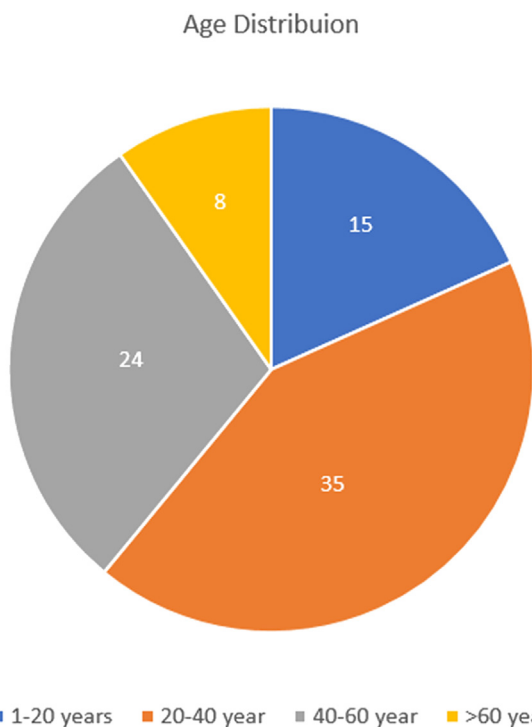


Figure 3: Age distribution: 1–20 years, 20–40 years, 40–60 years and > 60 years ($N = 82$).

We found 4 out of 43 recurrences in the Type B physiological host and 3 out of 28 in the Type A physiological host ($p < 0.001$) (Table 2). Infection recurrence was found the most frequently in the tibia (35.71%), followed by the femur (6.29%) (Table 3).

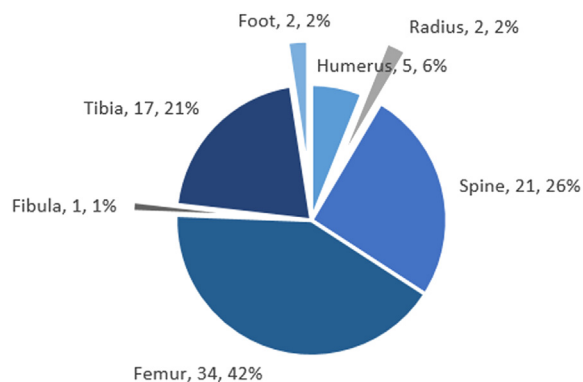


Figure 4: Site of bone involvement ($N = 82$).

Table 1: Analysis of Comorbidity Among Patients ($N = 71$).

Comorbidity	Follow up relapse/ recurrence of infection		Total
	No	Yes	
Hepatitis B	10	1	11
Anaemia	12	1	13
Diabetes mellitus	13	1	14
Nil	28	5	33
Total	63	8	71

$p = 0.643$.

Table 2: Recurrence of Infection With Respect to Type of Physiological Host (N = 71).

Type of physiological host	Follow up relapse/recurrence of infection		Total
	No	Yes	
Type A	25	3	28
Type B	39	4	43
Type C	0	0	0
Total	64	7	71

$p < 0.001^*$.

*Statistically significant.

Table 3: Relapse/recurrence of Bone Involvement (N = 71).

Site of bone involvement		Follow up relapse/recurrence of infection		Total
		No	Yes	
Site of bone involvement	Femur	30	2	32
	Spine	17	0	17
	Tibia	9	5	14
	Humerus	5	0	5
	Fibula	1	0	1
	Foot	1	0	1
	Radius	1	0	1
Total		64	7	71

$p = 0.220$.

Discussion

Local antibiotic delivery using antibiotic-loaded acrylic bone cement has been extensively attempted in the management of chronic osteomyelitis and implant-related infections. It is considered to be the gold standard in the treatment of osteomyelitis.⁷⁻⁹ The beads are typically inserted to fill anatomic defects secondary to surgical debridement. Locally-made antibiotic-loaded bone cement beads can be antibiotic-specific, cheaper, and readily available.¹⁰

Many studies have been conducted to assess the efficacy of antibiotic beads.^{1-3,11-15} Inspired by these studies, the present study was conducted to assess their efficacy in musculoskeletal infections and identify the various influencing factors on infection recurrence. Several authors^{15,16} have opined that Cefuroxime and Vancomycin can be used because of their safety, broad spectrum of action, heat stability, and low systemic side effects when used locally. Mohapatra and Jain¹⁷ treated 32 patients with debridement and implant removal, filling the dead space with antibiotic-laden bone cement or cement-coated nail. Infection was controlled in 28 patients at the time of cement removal.

In our study, the most common type of chronic osteomyelitis was infected osteosynthesis, followed by open fractures at the time of presentation, with the remainder due to

haematogenous infection. Hedstorm et al.¹⁸ found incidence of chronic osteomyelitis in 77% patients in post-operative infections, 17% in hematogenous infection, and 12% in infection following open fractures. However, Majid et al. identified haematogenous osteomyelitis as the most common aetiological factor. Mohanty et al.¹ found infected osteosynthesis to be a cause of infection in 49% patients, open fracture in 29%, and haematogenous infection in 22% patients.

Cierney et al.⁶ have shown that Types B and C physiological hosts are more prone to infection. Our study is in accordance with theirs in terms of the type of host and the recurrence of infection.

In our study, infection recurrence was found to be more common in the Type B physiological host (11.90%) and less common in Type A (6.89%). This was statistically significant. Walenkamp et al.¹⁹ showed that all relapses occurred at the 1- to 2-year mark in the long term, while there was no recurrence in the short term follow up. Klemm et al.,⁵ in their study of 405 patients, found that 9.6% recurrence occurred in patients with the temporary placement of antibiotic beads, while in 46 patients with the permanent placement of beads, the recurrence rate was 13%. Mohanty et al.¹ found infection recurrence in 6 out of 45 patients with chronic osteomyelitis who had been treated with antibiotic beads. They found that the majority of cases had an infected implant in situ.

Samuel et al.⁹ showed that the addition of adjuvant antibiotics to Gentamicin-impregnated bone cement has been shown to increase the escape of the antibiotic and broaden the spectrum of antibiotic coverage. Hence, in our study, we used Cefuroxime and Vancomycin as adjuvant antibiotics.

In our study, in 59.2% of the patients, the diagnosis could be verified with a positive bacterial culture. However, others had a sterile culture report. This was explained by the fact that pre-operative empirical antibiotic treatment could have reduced the bacteria significantly, so that the culture technique was not sensitive enough to identify low-grade infection or the specimens were not taken from an active part of the lesion. A study conducted by various authors^{9,12,18,20} concluded that there is a positive correlation between intraoperative cultures and subsequent wound infection. They also found *S. aureus* to be the most common pathogen.^{1,13,18,20}

In our study, infection recurrence was more common in Gentamicin-resistant patients than in Gentamicin-sensitive patients. The majority of infection recurrence was found with the MRSA microbe, followed by the MSSA microbe. Infection recurrence was more common in the Cefuroxime-resistant group than in the Cefuroxime-sensitive group. However, in the majority of patients, a Vancomycin culture sensitivity report was unavailable, so a correlation between sensitivity/resistance and infection recurrence could not be confirmed. Mohanty et al.¹ found 42% Gentamicin resistance among microorganisms, but in 19 patients who were resistant, only one showed infection recurrence. This is probably due to a high localised concentration of antibiotics. Other reasons for the difference in the infection cure rate are variations in host type and in patient's health status and aetiology of infection. Von Eiff et al.²¹ suggested that small colony variants (SCVs) may be

responsible for more recurrences of infection because they are more resistant to Gentamicin due to decreased uptake and reduced membrane potential.

Failure in some patients can be explained by the retention of the initial implant in 5 out of 7 patients, rather than to the presence of Gentamicin-resistant organisms. The implants were not removed in view of stability at the fracture site. This is comparable to Mohanty et al.¹

One of the inherent problems in interpreting this study's results is that the overall infection rate was very low (10%). With such a small number of infections, differences in the infection frequency rate between the two drug combinations may not be evident because of the lack of statistical power; consequently, one needs to interpret the results with caution. The PMMA antibiotic beads must be removed because they are non-biodegradable.

Conclusion

Antibiotics containing PMMA beads are very effective in the treatment of chronic osteomyelitis and in preventing infection recurrence. They are effective in both sensitive and resistant organisms. This effect is probably due to a high local minimum inhibitory concentration (MIC) for bacteria.

Recommendations

It is imperative to identify various factors responsible for the recurrence of infection to help clinicians predict the disease prognosis and minimise the risk of an unsatisfactory outcome. Antibiotic-loaded PMMA beads have a definite role in musculoskeletal infections.

Source of funding

This research did not receive any specific grant from funding agencies in the public, commercial, or not-for-profit sectors.

Conflict of interest

The authors have no conflict of interest to declare.

Ethical approval

Institutional Ethics Committee approval was obtained for this study (IEC 481/2012 dated November 14, 2012), and the study was conducted in accordance with the Declaration of Helsinki (revised in 2013).

Authors' contributions

KHP contributed to the acquisition, analysis, and interpretation of data. SNB was involved in the conception and design of the study and in drafting the article and revising it critically for important intellectual content. MH revised the article and approved the final version. All authors have critically reviewed and approved the final draft and are responsible for the manuscript's content and similarity index.

References

- Mohanty SP, Kumar MN, Murthy NS. Use of antibiotic-loaded polymethyl methacrylate beads in the management of musculoskeletal sepsis - a retrospective study. *J Orthop Surg* 2003; 11(1): 73–79. <https://doi.org/10.1177/230949900301100115>.
- Klemm K. The use of antibiotic-containing bead chains in the treatment of chronic bone infections. *Clin Microbiol Infect* 2000; 7(1): 28–31. <https://doi.org/10.1046/j.1469-0691.2001.00186.x>.
- Majid SA, Lindberg LT, Gunterberg B, Siddiki MS. Gentamicin-PMMA beads in the treatment of chronic osteomyelitis. *Acta Orthop Scand* 1985; 56(3): 265–268. <https://doi.org/10.3109/17453678508993010>.
- Buchholz HW, Elson RA, Heinert K. Antibiotic-loaded acrylic cement: current concepts. *Clin Orthop Relat Res* 1984; 190: 96–108. <https://doi.org/10.1097/00003086-198411000-00014>.
- Klemm KW. Antibiotic bead chains. *Clin Orthop Relat Res* 1993; (295): 63–76. <https://doi.org/10.1097/00003086-199310000-00011>.
- Cierny G, Mader JT, Penninck JJ. The classic: a clinical staging system for adult osteomyelitis. *Clin Orthop Relat Res* 2003; 414: 7–24. <https://doi.org/10.1097/01.blo.0000088564.81746.62>.
- Hanssen AD. Local antibiotic delivery vehicles in the treatment of musculoskeletal infection. *Clin Orthop Relat Res* 2005; 437: 91–96. <https://doi.org/10.1097/01.blo.0000175713.30506.77>.
- Nelson CL. The current status of material used for depot delivery of drugs. *Clin Orthop Relat Res* 2004; 427: 72–78. <https://doi.org/10.1097/01.blo.0000143741.92384.18>.
- Samuel S, Ismavel R, Boopalan PRJVC, Matthai T. Practical considerations in the making and use of high-dose antibiotic-loaded bone cement. *Acta Orthop Belg* 2010; 76(4): 543–545.
- Barth RE, Vogely HC, Hoepelman AIM, Peters EJG. “To bead or not to bead?” Treatment of osteomyelitis and prosthetic joint-associated infections with gentamicin bead chains. *Int J Antimicrob Agents* 2011; 38(5): 371–375. <https://doi.org/10.1016/j.ijantimicag.2011.03.008>.
- Agrawal M, Yuvarajan P, Maini L, Gautam VK. Management of infected non-union in long bones: our experience with bone cement. *J Clin Orthop Trauma* 2010; 1(1): 41–46. [https://doi.org/10.1016/S0976-5662\(11\)60009-X](https://doi.org/10.1016/S0976-5662(11)60009-X).
- Bayston R, Milner RDG. The sustained release of antimicrobial drugs from bone cement. An appraisal of laboratory investigations and their significance. *J Bone Jt Surg Br* 1982; 64(4): 460–464. <https://doi.org/10.1302/0301-620x.64b4.7096423>.
- Ostermann PAW, Seligson D, Henry SL. Local antibiotic therapy for severe open fractures. A review of 1085 consecutive cases. *J Bone Jt Surg Br* 1995; 77(1): 93–97. <https://doi.org/10.1302/0301-620x.77b1.7822405>.
- Sørensen TS, Sørensen LI, Merser S. Rapid release of gentamicin from collagen sponge: in vitro comparison with plastic beads. *Acta Orthop Scand* 1990; 61(4): 353–356. <https://doi.org/10.3109/17453679008993535>.
- Wahlig H, Dingeldein E, Bergmann R, Reuss K. The release of gentamicin from polymethylmethacrylate beads. An experimental and pharmacokinetic study. *J Bone Jt Surg Br* 1978; 60(2): 270–275. <https://doi.org/10.1302/0301-620x.60b2.659478>.
- Salvati EA, Callaghan JJ, Brause BD, Klein RF, Small RD. Reimplantation in infection. Elution of gentamicin from cement and beads. *Clin Orthop Relat Res* 1986; 207: 83–93. <https://doi.org/10.1097/00003086-198606000-00015>.
- Mohapatra N, Jain S. Antibiotic laden bone cement in chronic osteomyelitis. *J Orthop Traumatol Rehabil* 2017; 9(2): 74. https://doi.org/10.4103/jotr.jotr_18_17.
- Hedstrom SA, Lidgren L, Törholm C, Önnertfalt R. Antibiotic containing bone cement beads in the treatment of deep muscle

- and skeletal infections. *Acta Orthop Scand* 1980; 51(1–6): 863–869. <https://doi.org/10.3109/17453678008990886>.
19. Walenkamp GHIM. Chronic osteomyelitis. *Acta Orthop Scand* 1997; 68(5): 497–506. <https://doi.org/10.3109/17453679708996270>.
20. Mackowiak PA, Smith JW, Jones SR. Diagnostic value of sinus-tract cultures in chronic osteomyelitis. *J Am Med Assoc* 1978; 239(26): 2772–2775. <https://doi.org/10.1001/jama.239.26.2772>.
21. Von Eiff C, Bettin D, Proctor RA, Rolauffs B, Lindner N, Winkelmann W, et al. Recovery of small colony variants of

Staphylococcus aureus following gentamicin bead placement for osteomyelitis. *Clin Infect Dis* 1997; 25(5): 1250–1251. <https://doi.org/10.1086/516962>.

How to cite this article: Patel KH, Bhat SN, H M. Outcome analysis of antibiotic-loaded poly methyl methacrylate (PMMA) beads in musculoskeletal infections. *J Taibah Univ Med Sc* 2021;16(2):177–183.