

ORIGINAL ARTICLE

A new micro-forceps for endoscopic ultrasound-guided through-the-needle biopsy in the diagnosis of pancreatic cystic lesions: Single center experience

Serena Stigliano,^{*,†}  Francesco Covotta* and Francesco M Di Matteo*

*Operative Endoscopy Department, Campus Bio-Medico University Hospital and [†]Department of Translational and Precision Medicine, Sapienza University, Rome, Italy

Key words

endoscopic ultrasound, increased diagnosis, micro-forceps, new device, pancreatic cystic neoplasm.

Accepted for publication 15 June 2021.

Correspondence

Dr Serena Stigliano, Endoscopy Department, Campus Bio-Medico University Hospital, Via Alvaro del Portillo 200, 00128 Rome, Italy.
Email: s.stigliano@unicampus.it

Declaration of conflict of interest: All the authors declare no conflict of interest.

Author contribution: Serena Stigliano and Francesco Covotta collected and analyzed the data. Serena Stigliano and Francesco M Di Matteo wrote the manuscript. All the authors carefully reviewed the manuscript.

Introduction

Pancreatic cystic neoplasms (PCNs) are being diagnosed with increasing frequency because of the widespread use of cross-sectional imaging and are estimated to be present in 2–45% of the general population. PCN comprises a clinically challenging entity as their biological behavior ranges from benign to malignant disease.¹

On one hand, some PCNs have the potential for malignant transformation to adenocarcinoma, but on the other hand, this rate is low and it is estimated approximately 0.24% per year.² Consequently, correct management of PCN may prevent progression to pancreatic cancer as well as minimizing the need for life-long follow-up surveillance.

At present, there is no single diagnostic test that reliably can help in distinguishing and stratifying the malignancy risk of PCNs. Hence, the current clinical practice relies on a

Abstract

Background and Aim: Endoscopic ultrasound (EUS)-guided through-the-needle biopsy (TTNB) has improved the diagnostic algorithm of pancreatic cystic neoplasms (PCNs). Recently, a new through-the-needle micro-forceps device (Micro Bite, MTW Endoskopie Manufaktur) has been introduced. The primary aim was to assess the safety and technical success of this new type of micro-forceps. The secondary aim was to evaluate the diagnostic role of EUS-TTNB.

Methods: Retrospective study of consecutive patients receiving EUS-TTNB for the diagnosis of PCNs. Two micro-forceps were used: Moray Micro-forceps and Micro-Bite. Cystic fluid was collected for cytological analysis. Categorical variables were analyzed by Fisher's exact test, and continuous variables were analyzed by Student's *t*-test. $P < 0.05$ was considered significant.

Results: Forty-nine patients enrolled in the study (24% male; mean age 63 ± 14 years). TTNB was successfully performed in all patients. A diagnostic sample was obtained in 67.3% PCNs with TTNB compared with 36.7% with cyst fluid cytology ($P = 0.01$). Adverse events rate was 10.2% and occurred in older patients (76.6 ± 5.4 vs 61.3 ± 13.7 $P = 0.02$). The 51% underwent EUS-TTNB with Micro Bite. A diagnostic sample was obtained in 52% PCNs with Micro Bite compared with 24% obtained with cyst fluid cytology ($P = 0.07$). Comparing the two devices, the rate of diagnostic sample obtained with the micro-forceps Moray was higher than that obtained with the Micro Bite (20/24 [83.3%] vs 13/25 [52%] $P = 0.03$).

Conclusions: EUS-TTNB increases the diagnostic yield of PCNs. The new Micro-Bite could represent a valid alternative to the currently used Moray Micro-forceps, but its diagnostic rate is still suboptimal and further studies are needed.

combination of clinical history, cross-sectional imaging, endoscopic ultrasound (EUS) with fine needle aspiration (FNA), cyst fluid analysis, and cytology.^{1–5}

A recent study showed that EUS-FNA-based cytology had 42% sensitivity and 99% specificity to differentiate mucinous from non-mucinous PCN.⁶

Targeted cyst wall sampling using FNA can provide adequate specimen for cytologic or histologic evaluation in 65–81% but the diagnostic yield remains low (29%) due to the relatively small tissue sample that can be obtained using conventional FNA.^{7,8}

To improve the diagnostic yield, a through-the-needle micro-forceps device (Moray Microforceps, US Endoscopy, Mentor, OH, USA) was introduced for EUS-guided tissue sampling in PCNs. This single-use micro-forceps can be passed through the lumen of a standard 19-gauge EUS-FNA needle, allowing through-the-needle tissue biopsy (TTNB) for histologic sampling of PCNs.



Figure 1 Micro Bite: MTW Endoskopie Manufaktur.

Several case-reports and observational studies^{9–19} have been published. However, these studies were affected by a high heterogeneity and by the small number of included patients that have limited the possibility to assess the real clinical impact.

Recently, a new through-the-needle micro-forceps device (Micro Bite, MTW Endoskopie Manufaktur) has been introduced. The shape of the forceps is oval, spoon-shaped mouth, toothed, with diameter of 0.8 mm (Fig. 1). This single-use micro-forceps can be passed through the lumen of a standard 19-gauge EUS-FNA needle.

There are no data in the literature about the diagnostic role of this new through-the-needle micro-forceps in the management of PCNs. The primary aim of this study was to assess the safety and technical success of this new through-the-needle micro-forceps. The secondary aims were to evaluate the overall diagnostic role of EUS-TTNB in the management of PCN when compared with FNA cyst fluid cytology.

Methods

It is a retrospective study of consecutive patients who underwent EUS-FNA and TTNB for PCNs at the Operative Endoscopy department of Campus Bio-Medico University Hospital of Rome. In accordance with the international guidelines,¹ the pancreatic cysts enrolled in the study were those with features suspected for malignancy: Growth-rate ≥ 5 mm/year; increased levels of serum carbohydrate antigen 19.9 (CA 19.9) (>37 U/mL); main pancreatic duct dilatation between 5 and 9.9 mm; cyst diameter ≥ 40 mm; enhancing mural nodule (<5 mm).

The EUS exam was performed using a linear Ecoendoscope Fujifilm (EG-580UT), with patients in deep sedation. The cyst's size and location, the presence of mural nodule, solid mass or wall thickness and the main pancreatic duct dilation were recorded. EUS-FNA was performed using the 19-gauge EUS-FNA needle (Boston scientific Slimline).

Before puncturing PCNs, the stylet was removed and the micro-forceps was preloaded in the FNA needle in order to reduce fluid aspiration and cystic walls collapse due to the stylet removal before the sampling. The needle was inserted into the PCN under EUS guidance and with the use of Doppler to avoid interposed vessels. After puncturing PCNs, the micro-forceps was inserted through the FNA needle till it was seen inside the cyst

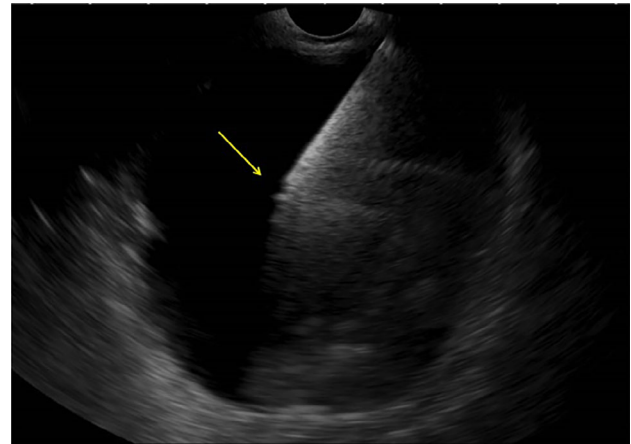


Figure 2 EUS-TTNB of pancreatic cyst. The hyperechogenic needle is inside the cyst. The arrow indicates the small jaws of the opened micro-forceps. EUS, endoscopic ultrasound; TTNB, through-the-needle biopsy.

(Fig. 2). The micro-forceps open was then advanced and gently pushed against the opposite walls, then closed and pulled back until the “tent sign” was seen. In case of the presence of mural nodules, the biopsy was directed on them.

The specimen obtained was placed directly in formalin. The number of passes was guided by the obtaining of macroscopic visible fragment of tissue. Cystic fluid was also collected for intra-cystic markers dosage (carcinoembryonic antigen [CEA], amylase, lipase) and for cytological analysis. For the cytological analysis, cystic fluid was either smeared onto a glass slide or placed into a CytoLyt container for liquid-based cytology. Cytological and histological samples were evaluated by a pathologist specialized in pancreatic cytology and were graded according to the guidelines of the Papanicolaou Society of Cytopathology.²⁰ A prophylactic antibiotic (Fluoroquinolones) was administered. Technical success was defined as the successful acquisition of at least one macroscopically visible biopsy sample.

An adequate sample was defined when there was sufficient material for the histological analysis. A diagnostic sample was defined if the material obtained allows distinguishing the type of pancreatic cysts. A cyst was determined to be mucinous on cytology if there was identifiable epithelium with characteristics consistent with mucinous pancreatic cystic epithelium. On histology with TTNB, a cyst was categorized as mucinous if there was mucinous epithelium with cytoplasmic mucin seen.

The final diagnosis was obtained by surgical histopathology when available. In the absence of surgery, the diagnosis was based on a combination of imaging features, value of CEA, history of acute/chronic pancreatitis, and stable appearance on follow-up imaging at 12 months or later.

Safety was defined by the rate of occurrence of post-procedure adverse events. Adverse events were defined according to the American Society for Gastrointestinal Endoscopy (ASGE)'s lexicon on adverse events in endoscopy.²¹

Two different TTNB micro-forceps were used: The Moray Microforceps, US Endoscopy, Mentor, OH and the Micro Bite;

Table 1 General features of pancreatic cystic neoplasm

Pancreatic cyst's features	n (%)
Cyst size (mean; SD)	38.2 ± 16
Location	
Head	21 (43)
Body	13 (27)
Tail	15 (30)
Multifocal	14 (28.5)
Main PD dilated	8 (16.3)
Mural nodule	13 (26.5)
Atrophic parenchyma	4 (8.2)
Feasibility of TTNB	49 (100)
Adequate samples	40/49 (81.6)
Diagnostic samples	33/49 (67.4)
Number of passes (median; range)	3.5 (1–6)
Adverse events	5 (10.2)

PD, pancreatic duct; TTNB, through-the-needle biopsy.

MTW Endoskopie Manufaktur. The choice was made according to the hospital's availability of the device.

Statistical analysis. Quantitative variables were presented as mean with corresponding SD or median with range. Categorical variables were presented as percentages. In the univariate analysis, numerical outcomes were compared using a Student's *t* test, while for categorical data Fischer's exact test was used. A logistic regression analysis was performed to assess the association between the abovementioned variables and the TTNB diagnostic samples. *P* < 0.05 was considered statistically significant.

Results

Overall, from December 2017 to November 2020, 49 patients who underwent EUS-TTNB were included (24.5% male; mean age 63 ± 14 years old). In 13 (26.5%) PCNs, mural nodules were observed. Pathological dilatation of pancreatic duct (5–9 mm) was detected in eight (2%) patients (Table 1). In 18 PCNs (36.7%), the size was bigger than 40 mm. Six patients showed an increase of cyst's size of more than 5 mm from the previous follow-up image and four patients had increased serum CA 19.9 value.

The mean size of PCNs was 38 ± 16 mm and was mostly localized in pancreatic head and tail (42.8%). Exactly 28.6% of patients had multifocal disease. A unilocular cyst was observed in 65% of the patients. In 25 patients (51%), EUS-TTNB has been performed with the new device Micro Bite, MTW Endoskopie Manufaktur. EUS-TTNB with Micro Bite was successfully performed in 25 of 25 (100%) patients. An adequate sample was obtained in 17 of 25 (68%) patients. A diagnostic sample was obtained in 13 of 25 (52%) PCNs with TTNB compared with 6 of 25 (24%) obtained with FNA cyst fluid cytology (*P* 0.07). Only one patient had an adverse event represented by the occurrence of fever after the procedure.

Considering all patients independently from the type of device, a diagnostic sample was obtained in 33 of 49 (67.3%) PCNs with TTNB compared with 18 of 49 (36.7%) obtained with FNA cyst fluid cytology (*P* 0.01).

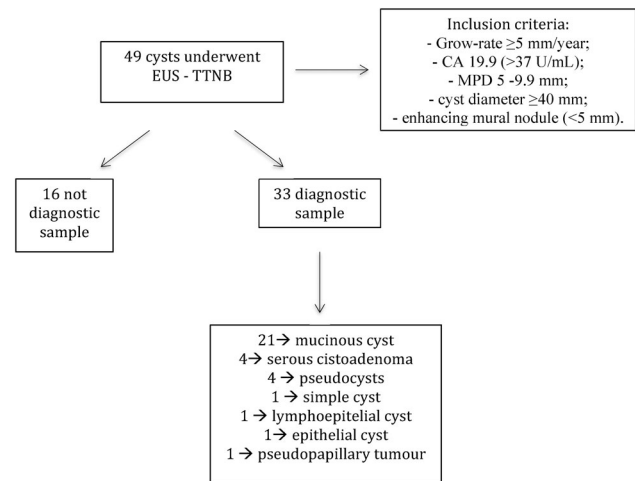


Figure 3 Flowchart of the management of pancreatic cysts: From the inclusion criteria to the diagnosis.

Mucinous PCNs were diagnosed in 21 of 49 patients (42.8%). Sixteen of 49 samples were classified as not diagnostic; 4 of 49 were serous cistoadenoma; 1 of 49 were lymphoepithelial cyst; 1 of 49 solid pseudopapillary tumor; 4 of 49 pseudocysts; 1 of 49 simple cyst; 1 of 49 epithelial cyst with low-grade dysplasia (Fig. 3).

We evaluated the possible association between cystic features and the diagnosis with TTNB. There was no difference in terms of cyst size (38.1 ± 17 vs 38.4 ± 15 *P* 0.41), cyst location in pancreatic head *versus* other sites (12/21 57.1% vs 9/21 42.8% *P* 0.25), presence of mural nodule (9/13 69.2% vs 4/13 30.7% *P* 1), and the rate of diagnosis with TTNB. In the logistic regression analysis, neither the presence of mural nodule nor the presence of pathologic Wirsung dilation was associated with a higher rate of TTNB diagnostic sample (odds ratio [OR] 0.89 95% confidence interval [CI] 0.22–3.48 *P* 0.86; OR 1.5 95% CI 0.27–8.73 *P* 0.62). The localization of the cyst in the pancreatic head was not associated with a higher rate of TTNB diagnostic sample (OR 0.45 95% CI 0.13–1.49 *P* 0.91). The mean value of CEA in mucinous cyst was 1792.3 ± 3533.7 ng/mL.

Regarding the safety of the EUS-TTNB, post-procedure adverse events were observed in 5 of 49 (10.2%) cases. Two (40%) of these were mild acute pancreatitis managed with fasting and fluid resuscitation. One (20%) patient experienced moderate–severe acute pancreatitis with infected fluid collections that were drained with EUS stent position. Two (40%) patients had fever after the procedure, which was managed with antibiotic therapy and paracetamol.

There was no association between the cystic size and the risk of adverse events (48.2 ± 19 vs 37.8 ± 15 *P* 0.15). The mean age was higher in patients who developed adverse events compared with those who did not (76.6 ± 5.4 vs 61.3 ± 13.7 *P* 0.02). About the mean number of passes performed with the micro-forceps, data were available only for 23 patients. The median value was 3 (range of 1–6 passes). The mean number of passes in patients in whom the EUS-TTNB was diagnostic was similarly compared with the others (3.2 ± 1 vs 3.7 ± 1 *P* 0.28).

Table 2 Differences between micro-forceps Moray and Micro Bite

	Moray (n 24)	Micro Bite (n 25)	P
Cyst's size (mean; SD)	38.6 ± 17	37.8 ± 16	0.86
Feasibility of through-the-needle biopsy	24/24 (100%)	25/25 (100%)	1
Adequate sample	23/24 (95.8%)	17/25 (68%)	0.02
Diagnostic sample	20/24 (83.3%)	13/25 (52%)	0.03
Adverse events	4/24 (16.7%)	1/25 (4%)	0.18

Overall, four patients underwent surgery, and in three cases, the diagnosis was confirmed. Only in one patient, while the histological diagnosis obtained with TTNB was intraductal mucinous papillary neoplasm (IPMN) with low-grade dysplasia, the definitive histological diagnosis in the surgical specimen was mucinous adenocarcinoma.

Comparing the two devices, the rate of diagnostic sample obtained with the micro-forceps Moray was higher than that obtained with the Micro Bite (20/24 [83.3%] vs 13/25 [52%] P 0.03) (Table 2).

There was no difference in terms of mean age (62 ± 14 vs 63.1 ± 14 P 0.91), male sex (6/24 vs 6/25 P 1), and cyst's size (37.8 ± 15 vs 38.6 ± 17 P 0.86) between the two groups of patients.

No difference in terms of adverse events rate was observed between the two micro-forceps (4/5 [80%] vs 1/5 [20%] P 0.18).

Discussion

The present retrospective study investigates, for the first time, the safety and technical success of a new micro-forceps, the Micro Bite, MTW Endoskopie Manufaktur, for the diagnosis of pancreatic cystic lesions. Of the 49 patients with PCNs included in the study, this new device was used in 25 patients, and it was successfully performed in all cases, obtaining an adequate sample for the histological analysis in 68% of the patients. Mild adverse event occurred in one patient.

Considering the overall EUS-TTNB, independently from the type of micro-forceps, a histological adequate sample and a histological diagnostic sample were obtained irrespectively in 67.3% and 81.6% of PCN. The high technical success and tissue acquisition yield with TTNB in the current study are in line with prior series and so it supports the reproducibility of these findings.

A recent meta-analysis conducted on nine studies aimed to assess the clinical impact of EUS-TTNB in terms of technical success, histological accuracy, and diagnostic yield.²²

The overall histologic adequacy of EUS-TTNB was around 87% and the diagnostic yield was 69.5% (95% CI 59.2–79.7) with high heterogeneity among studies ($I^2 = 84.7%$; $P < 0.001$). This suboptimal diagnostic yield was possibly related to the heterogeneity of cyst wall. In fact, a large portion of the cyst may undergo epithelial denudation, and TTNB samples can result in inconclusive fibrotic tissue. The fact that TTNB does not provide information on the whole cyst but only on focal pieces is probably the greatest limitation of this technique. This aspect was experienced even in our study where in one patient the histological diagnosis obtained with TTNB showed low-

grade dysplasia while the definitive histological diagnosis in the surgical specimen presented foci of adenocarcinoma.

In another meta-analysis conducted on 11 studies, *Facciorusso and colleagues* showed that the overall sample adequacy rate with TTNB was 85.3%, with diagnostic accuracy and sensitivity of 78.8% and 82.2%, respectively.²³

About the number of passes that should be performed, the method is still not standardized. In the literature, the average number of micro-forceps passes is three and it seems to be associated with the histological adequacy and diagnostic yield. On the other hand, it is necessary to define the minimum number of passes necessary to reach an adequate diagnosis because the traumatism of each pass could increase the risk of adverse events and the time of the procedure.

In their study, *Crinò et al* showed that the obtainment of two TTNB macroscopically visible specimens reached 100% histologic adequacy and a specific diagnosis in 74% of patients. The collection of a third specimen did not add any additional information and should be avoided to possibly decrease the risk of adverse events.²⁴

In the present study, the number of passes was available only for 23 patients, and the mean number was similar between diagnostic and non-diagnostic sample obtained. Of course these results must be taken with caution because of the small number of the patients but it could be correlated with the fact that the most important aspect is the attainment of macroscopically visible specimens independently from the number of passes.

Regarding the risk of post-procedure adverse events, data from the literature show that the pooled estimate for the overall adverse events rate of EUS-TTNB was 8.6% (95% CI 4.0–13.1). In the present study, adverse events were observed in 10.2% of cases, and it is concordant with previous results. However, we experienced major adverse events (necrotizing acute pancreatitis) only in one case.

The present study has some limitations related to its retrospective design. Indeed, only a small percentage of PCN underwent surgery and so only for those we have a definite diagnosis. However, the other lesions were followed up according with the European guidelines,¹ and in no case the diagnosis was changed. Ultimately, the aspiration of cystic fluid was performed after the TTNB sampling and it could cause cyst's wall bleeding, which may interfere with the cytological evaluation.

In conclusion, for the best of our knowledge, this is the first study evaluating the safety and technical success of the Micro Bite forceps in the diagnosis of PCN. This new device—Micro Bite: MTW Endoskopie Manufaktur—represents a valid alternative to the currently used Moray Microforceps, given the

high adequate sample rate. However, other studies conducted on wider sample of patients are necessary to confirm it.

The present study confirms the high diagnostic yield of EUS-TTNB in PCN. This technique seems to be safe but not absolutely free from adverse events, so it should be performed in well-selected patients.

References

- 1 The European Study Group on Cystic Tumours of the Pancreas. European evidence-based guidelines on pancreatic cystic neoplasms. *Gut*. 2018; **67**: 789–804.
- 2 Scheiman JM, Hwang JH, Moayyedi P. American gastroenterological association technical review on the diagnosis and management of asymptomatic neoplastic pancreatic cysts. *Gastroenterology*. 2015; **148**: 824–48.e22.
- 3 Park WG, Mascarenhas R, Palaez-Luna M *et al.* Diagnostic performance of cyst fluid carcinoembryonic antigen and amylase in histologically confirmed pancreatic cysts. *Pancreas*. 2011; **40**: 42–5.
- 4 Cizginer S, Turner BG, Bilge AR, Karaca C, Pitman MB, Brugge WR. Cyst fluid carcinoembryonic antigen is an accurate diagnostic marker of pancreatic mucinous cysts. *Pancreas*. 2011; **40**: 1024–8.
- 5 Gaddam S, Ge PS, Keach JW *et al.* Suboptimal accuracy of carcinoembryonic antigen in differentiation of mucinous and non-mucinous pancreatic cysts: results of a large multicenter study. *Gastrointest. Endosc.* 2015; **82**: 1060–9.
- 6 Gillis A, Cipollone I, Cousins G, Conlon K. Does EUS-FNA molecular analysis carry additional value when compared to cytology in the diagnosis of pancreatic cystic neoplasm? A systematic review. *HPB*. 2015; **17**: 377–86.
- 7 Barresi L, Tarantino I, Traina M *et al.* Endoscopic ultrasound-guided fine needle aspiration and biopsy using a 22-gauge needle with side fenestration in pancreatic cystic lesions. *Dig. Liver Dis.* 2014; **46**: 45–50.
- 8 Hong SK, Loren DE, Rogart JN *et al.* Targeted cyst wall puncture and aspiration during EUS-FNA increases the diagnostic yield of premalignant and malignant pancreatic cysts. *Gastrointest. Endosc.* 2012; **75**: 775–82.
- 9 Hashimoto R, Lee JG, Chang KJ, Chehade NEH, Samarasena JB. Endoscopic ultrasound-through-the-needle biopsy in pancreatic cystic lesions: a large single center experience. *World J Gastrointest Endosc.* 2019; **11**: 531–40.
- 10 Yang D, Trindade AJ, Yachimski P *et al.* Histologic analysis of endoscopic ultrasound-guided through the needle microforceps biopsies accurately identifies mucinous pancreas cysts. *Clin. Gastroenterol. Hepatol.* 2019; **17**: 1587–96.
- 11 Yang D, Samarasena JB, Jamil LH *et al.* Endoscopic ultrasound-guided through-the-needle microforceps biopsy in the evaluation of pancreatic cystic lesions: a multicenter study. *Endosc Int Open.* 2018 Dec; **6**: E1423–30.
- 12 Samarasena JB, Nakai Y, Shinoura S, Lee JG, Chang KJ. EUS-guided, through-the-needle forceps biopsy: a novel tissue acquisition technique. *Gastrointest. Endosc.* 2015; **81**: 225–6.
- 13 Barresi L, Tarantino I, Ligresti D, Curcio G, Granata A, Traina M. A new tissue acquisition technique in pancreatic cystic neoplasm: endoscopic ultrasound-guided through-the-needle forceps biopsy. *Endoscopy*. 2015; **47**(S 01): E297–2015, 8.
- 14 Pham KD-C, Engjom T, Gjelberg Kollesete H, Helgeland L. Diagnosis of a mucinous pancreatic cyst and resection of an intracystic nodule using a novel through-the-needle micro forceps. *Endoscopy*. 2016; **48**(S 01): E125–6.
- 15 Shakhathreh M, Naini S, Brijbassie A, Grider D, Shen P, Yeaton P. Use of a novel through-the-needle biopsy forceps in endoscopic ultrasound. *Endosc Int Open.* 2016; **04**: E439–42.
- 16 Attili F, Pagliari D, Rimbaş M *et al.* Endoscopic ultrasound-guided histological diagnosis of a mucinous non-neoplastic pancreatic cyst using a specially designed through-the-needle microforceps. *Endoscopy*. 2016; **48**(S 01): E188–9.
- 17 Huelsen A, Cooper C, Saad N, Gupta S. Endoscopic ultrasound-guided, through-the-needle forceps biopsy in the assessment of an incidental large pancreatic cystic lesion with prior inconclusive fine-needle aspiration. *Endoscopy*. 2017; **49**(S 01): E109–10.
- 18 Crinò SF, Bernardoni L, Gabbrielli A *et al.* Beyond pancreatic cyst epithelium: evidence of ovarian-like stroma in EUS-guided through-the-needle micro-forceps biopsy specimens. *Am. J. Gastroenterol.* 2018; **113**: 1059–60.
- 19 Barresi L, Tacelli M, Chiarello G, Tarantino I, Traina M. Mucinous cystic neoplasia with denuded epithelium: EUS through-the-needle biopsy diagnosis. *Gastrointest. Endosc.* 2018; **88**: 771–4.
- 20 Pitman MB, Centeno BA, Ali SZ *et al.* Standardized terminology and nomenclature for pancreatobiliary cytology: the Papanicolaou Society of Cytopathology guidelines. *Diagn. Cytopathol.* 2014; **42**: 338–50.
- 21 Cotton PB, Eisen GM, Aabakken L *et al.* A lexicon for endoscopic adverse events: report of an ASGE workshop. *Gastrointest. Endosc.* 2010; **71**: 446–54.
- 22 Tacelli M, Celsa C, Magro B *et al.* Diagnostic performance of endoscopic ultrasound through-the-needle microforceps biopsy (EUS-TTNB) of pancreatic cystic lesions: a systematic review with meta-analysis. *Dig. Endosc.* 2020; **32**:1018–1030.
- 23 Facciorusso A, Del Prete V, Antonino M, Buccino VR, Wani S. Diagnostic yield of EUS-guided through-the-needle biopsy in pancreatic cysts: a meta-analysis. *Gastrointest. Endosc.* 2020; **92**:1–8.
- 24 Crinò SF, Bernardoni L, Brozzi L *et al.* Association between macroscopically visible tissue samples and diagnostic accuracy of EUS-guided through-the-needle microforceps biopsy sampling of pancreatic cystic lesions. *Gastrointest. Endosc.* 2019; **90**: 933–43.