

# Zoster Brachial Plexopathy as a Presenting Manifestation of Human Immunodeficiency Virus Infection

Rajesh Verma, Soumik Sarkar, Chetan Shettigar

Department of Neurology, King George's Medical University, Lucknow, Uttar Pradesh, India

## Abstract

Brachial plexopathy is an uncommon neurologic complication of varicella-zoster virus (VZV) infection. VZV is not an acquired immunodeficiency syndrome-defining illness, but human immunodeficiency virus (HIV) infection is a risk factor for atypical and severe complications of VZV reactivation. Here, we present a 70-year-old male, who presented with left upper-limb weakness, preceded by painful dermatomal vesicular eruption, and was diagnosed to have zoster brachial plexopathy. This severe and atypical manifestation of VZV prompted HIV infection testing, leading to a new diagnosis of HIV infection.

**Keywords:** Brachial plexopathy, human immunodeficiency virus, shingles, varicella-zoster virus

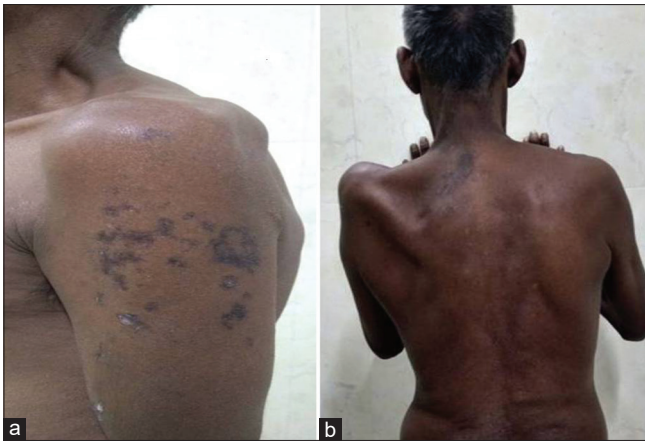## INTRODUCTION

Varicella-zoster commonly presents with painful, vesicular skin lesions in a restricted dermatomal distribution due to shingles in the dorsal root ganglia.<sup>[1]</sup> Although varicella zoster predominantly involves sensory system, it may rarely result in weakness due to the involvement of motor system.<sup>[2]</sup> Brachial plexopathy is an uncommon neurologic complication of varicella-zoster virus (VZV) infection.<sup>[3,4]</sup> Zoster brachial plexopathy has not been described as a complication of VZV reactivation in the setting of human immunodeficiency virus (HIV) infection.<sup>[5,6]</sup> The neurological complications

of VZV vary, with the most common being postherpetic neuralgia; others reported in the literature are meningitis, vasculopathy, myelitis, Ramsay Hunt syndrome, Horner syndrome, and, rarely, encephalitis.<sup>[7]</sup> We report a patient who had vesicular skin eruption due to shingles and developed brachial plexopathy.

## CASE REPORT

A 70-year-old male complained of inability to raise the right upper limb for 20 days. Initially, the disease started with pain in the left side of neck, right shoulder, and outer aspect



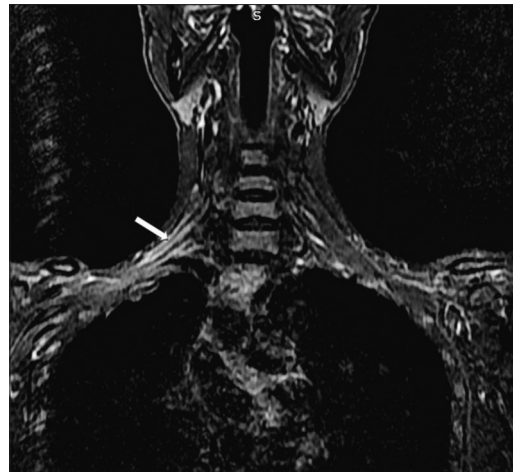
**Figure 1:** (a) The arm demonstrated typical zoster rash in dermatomal distribution (C5 over the regiment badge area). (b) The shoulder region revealed atrophy of left deltoid, supraspinatus, and infraspinatus muscles

of left upper limb. The pain was radiating in nature. It was followed 4 days later by vesicular eruptions over the same area [Figure 1a]. Pain increased during these eruptions. The eruptions subsided 7 days later, but pain persisted. After the vesicles subsided, he noticed that he was unable to lift the upper limb. His weakness progressed over a week and then became static. There were marks of healed eruptions over the left limb. The patient was staying away from his family for the past many years due to occupation. He reported no clear occupational injury to explain his symptoms.

There was a positive history of high-risk sexual exposure. The patient returned back to his village and helped in farming on a minor scale. The history was negative for varicella vaccination and chicken pox. On physical examination, the patient was conscious and oriented with normal bedside observations. Motor system examination revealed atrophy of left deltoid, supraspinatus, and infraspinatus [Figure 1b]. As per the Medical Research Council grading, power around left shoulder flexor, extensor, abductor, and adductor was 2/5, while it was 5/5 at elbow flexor/extensor and wrist joint flexor/extensor. Left biceps and supinator reflex were absent, while triceps reflex was normally elicitable on both sides. Sensory examination revealed reduced pinprick and fine touch sensation over C5 and C6 distribution in the left upper limb. The rest of the general and neurological examination did not reveal abnormality.

Biochemistry and full blood count blood testing were within normal range. The full blood count revealed Hb14 g/dl, total leucocytes count (TLC) 7400 cells/mm<sup>3</sup>, N<sub>70</sub> L<sub>27</sub> E<sub>03</sub>, and platelet count of 2.21 lac cells/mm<sup>3</sup>. The serum biochemistry showed serum creatinine – 1.1 mg/dl, liver function test showed serum bilirubin – 0.8 mg/dl, Serum glutamic pyruvic transaminase (SGPT) – 32 IU/dl, serum electrolytes were sodium – 138 meq/l, and potassium – 4.2 mmol/l.

Nerve conduction studies were done for both the upper limbs. Brachial plexus was stimulated at Erb's point, the musculocutaneous nerve, axillary nerve, and radial nerve, and



**Figure 2:** Magnetic resonance imaging and coronal short tau inversion recovery sequence showing hyperintensity in brachial plexus on the left side (white arrow)

motor response was recorded from biceps, deltoid, and triceps, respectively. Absent left supraspinatus and infraspinatus compound motor action potentials (CMAPs), reduced left deltoid CMAP, and absent left lateral antebrachial cutaneous sensory nerve action potentials were suggestive of left upper trunk brachial plexopathy. Motor and sensory responses on the right side were normal [Table 1]. Electromyography showed denervation changes in the same muscles on the left side [Table 2]. The needle electromyography of paraspinal muscles did not demonstrate denervation pattern negating the possibility of associated radiculopathy.

HIV-1 antibody testing was positive. The patient's CD4+ T-cell count was 256 cells/mm<sup>3</sup>. The direct fluorescent immunoglobulin G antibody was elevated in significant titers for varicella-zoster infection. Serological markers for Japanese encephalitis virus, Epstein–Barr virus, West Nile virus, dengue, and chikungunya virus revealed negative results.

Magnetic resonance imaging (MRI) of the left brachial plexus was studied. T2-weighted and coronal short tau inversion recovery sequences revealed hyperintensity of the upper trunk [Figure 2]. On T1 contrast, it was showing enhancement of the upper trunk. T1-weighted image did not reveal any significant abnormality. MRI cervical spine showed no evidence of compressive myelopathy or radiculopathy.

**Address for correspondence:** Prof. Rajesh Verma,  
Department of Neurology, King George's Medical University,  
Lucknow - 226 003, Uttar Pradesh, India.  
E-mail: drrajeshverma32@yahoo.com

**Submitted:** 19-Mar-2019 **Revised:** 15-Apr-2019 **Accepted:** 18-Apr-2019  
**Published:** 21-May-2019

This is an open access journal, and articles are distributed under the terms of the Creative Commons Attribution-NonCommercial-ShareAlike 4.0 License, which allows others to remix, tweak, and build upon the work non-commercially, as long as appropriate credit is given and the new creations are licensed under the identical terms.

**For reprints contact:** reprints@medknow.com

**DOI:** 10.4103/aian.AIAN\_158\_19

**Table 1: Nerve conduction velocity parameters in our patient**

Motor NCS			
Nerve/sites	Muscle	Latency (ms)	Amplitude (mV)
Left suprascapular (Erb's point)	Supraspinatus	-	-
	Infraspinatus	-	-
Right suprascapular (Erb's point)	Supraspinatus	2.19	10.2
	Infraspinatus	2.1	9.7
Left musculocutaneous (Erb's point)	Biceps	-	-
Right musculocutaneous (Erb's point)	Biceps	3.82	10.7
Left axillary (Erb's point)	Deltoid	3.59	1.2
Right axillary (Erb's point)	Deltoid	3.2	12.5
Right radial (Erb's point)	Triceps	2.6	13.9
Left radial (Erb's point)	Triceps	2.81	18.1
Sensory NCS			
Nerve/sites	Peak latency (ms)	Amplitude (mV)	Velocity (m/s)
Left lateral antebrachial nerve	-	-	-
Right lateral antebrachial nerve	2.14	12.4	49

Stimulation at the Erb's point showed that CMAPs of the left suprascapular nerve and left musculocutaneous nerve were not recordable, left axillary nerve stimulation at the Erb's point recorded reduced CMAPs. The stimulation of the above-mentioned nerves on the right side showed normal CMAPs and latency. On sensory study, SNAPs of left lateral antebrachial nerve were not recordable and SNAPs of right lateral antebrachial nerve were normal. NCS=Nerve conduction study, CMAPs=Compound motor action potentials, SNAPs=Sensory nerve action potential

**Table 2: Electromyography**

Muscle	Insertional activity	Fibrillations	Fasciculations	Recruitment	Duration	Amplitude
Left supraspinatus	↑	-	++	↓↓↓	N	N
Left infraspinatus	-	-	+	↓	N	N
Left deltoid	↑	+	+++	↓↓↓	N	N
Right supraspinatus	N	-	-	N	N	N
Right infraspinatus	N	-	-	N	N	N
Right deltoid	N	-	-	N	N	N

Electromyography demonstrated denervation pattern in left supraspinatus, infraspinatus, and deltoid as compared to the right side.

EMG=Electromyography. Upward single arrow: Increased, Downward single arrow: Reduced, Triple downward arrows: Markedly reduced, one plus: Noted occasionally, Two Plus: Noted regularly

He was started on antiretroviral treatment in addition to gabapentin and analgesics for pain. He also received physical therapy and was enrolled in a rehabilitation program. Acyclovir therapy was not used as the patient presented when vesicular eruptions subsided.<sup>[8]</sup> The antiretroviral therapy has been started according to the World Health Organization guidelines. The drugs prescribed were tenofovir (300 mg), lamivudine (300 mg), and efavirenz (600 mg) in daily fixed-dosage combination therapy.

Three months later, he reported complete subsidence of pain and modest improvement in strength. He regained a power of 4+/5 Medical Research Council scale at the left shoulder joint and was able to perform all his routine activities.

## DISCUSSION

The reactivation of the latent VZV infection in the dorsal root ganglia results in shingles. It commonly presents with painful vesicular rash in dermatomal distribution.<sup>[1]</sup> The various neurologic complications secondary to VZV infection

reported in literature include postherpetic neuralgia, meningitis, meningoencephalitis, myelitis, Brown–Sequard syndrome, brachial plexopathy, and polyradiculitis.<sup>[3-7]</sup> Brachial plexopathies can occur due to inflammatory disorders, tumors, post trauma, and radiation exposure. The differential conditions to be considered can be divided into two parts. Nonneurogenic disorders include rotator cuff abnormalities, injury, hematomas, calcified tendinitis, and adhesive capsulitis. The neurological conditions are radiculopathies, neuronomas, and inflammatory plexopathy related to infectious or immune-mediated conditions<sup>[9,10]</sup>

The segmental zoster paresis is reported in 3%–5% of patients with cutaneous herpes zoster. Elderly patients are usually affected.<sup>[11]</sup>

This study exhibited involvement of the upper trunk of the brachial plexus. The diagnosis of a brachial plexitis associated with VZV was established, based on the development of upper-limb weakness, herpetic skin lesions, MRI changes of brachial plexus study, and demonstration of the abnormal brachial plexus findings on neurophysiological evaluation.

The various immunosuppressive conditions such as HIV infection, Hodgkin's disease, non-Hodgkin's lymphomas, leukemias, bone marrow and other organ transplants, systemic lupus erythematosus, and intake of immunomodulators are predisposing factors for shingles.<sup>[12]</sup>

The immunodeficient states should be ruled out before attributing zoster to the age-related decline in specific cell-mediated immune responses to VZV so that treatment of the underlying disease can be instituted in addition to the treatment of shingles.<sup>[13]</sup> The association of shingles and HIV has been established in various studies. It can occur anytime during the course of HIV infection.<sup>[14]</sup>

Zoster may be the first clinical clue to an underlying otherwise asymptomatic HIV infection.<sup>[15]</sup> However, zoster-associated brachial plexopathy as a presenting manifestation of HIV has not been reported in the literature. Physicians should be aware of the fact that it may be a presenting manifestation of otherwise asymptomatic HIV infection. This is important because specific treatments are available for these infections.

#### Declaration of patient consent

The authors certify that they have obtained all appropriate patient consent forms. In the form the patient(s) has/have given his/her/their consent for his/her/their images and other clinical information to be reported in the journal. The patients understand that their names and initials will not be published and due efforts will be made to conceal their identity, but anonymity cannot be guaranteed.

#### Financial support and sponsorship

Nil.

#### Conflicts of interest

There are no conflicts of interest.

## REFERENCES

1. Arvin AM. Varicella-zoster virus. *Clin Microbiol Rev* 1996;9:361-81.
2. Martín del Pozo M, Benito-León J, Rodríguez J, Molina JA, Díaz-Guzmán J, Bermejo FP, *et al.* Uncommon neurologic complications related to varicella-zoster virus. *Neurologia* 1998;13:94-7.
3. Gilden DH, Kleinschmidt-DeMasters BK, LaGuardia JJ, Mahalingam R, Cohrs RJ. Neurologic complications of the reactivation of varicella-zoster virus. *N Engl J Med* 2000;342:635-45.
4. Kawajiri S, Tani M, Noda K, Fujishima K, Hattori N, Okuma Y, *et al.* Segmental zoster paresis of limbs: Report of three cases and review of literature. *Neurologist* 2007;13:313-7.
5. Fabian VA, Wood B, Crowley P, Kakulas BA. Herpes zoster brachial plexus neuritis. *Clin Neuropathol* 1997;16:61-4.
6. Brawerman DL, Ku A, Nagler W. Herpes zoster polyradiculopathy. *Arch Phys Med Rehabil* 1997;78:880-2.
7. Mueller NH, Gilden DH, Cohrs RJ, Mahalingam R, Nagel MA. Varicella zoster virus infection: Clinical features, molecular pathogenesis of disease, and latency. *Neurol Clin* 2008;26:675-97, viii.
8. Saguil A, Kane S, Mercado M, Lauters R. Herpes zoster and postherpetic neuralgia: Prevention and management. *Am Fam Physician* 2017;96:656-63.
9. Verma R, Sharma P, Khurana N, Sharma LN. Neuralgic amyotrophy associated with dengue fever: Case series of three patients. *J Postgrad Med* 2011;57:329-31.
10. Khadilkar SV, Khade SS. Brachial plexopathy. *Ann Indian Acad Neurol* 2013;16:12-8.
11. Ismail A, Rao DG, Sharrack B. Pure motor herpes zoster induced brachial plexopathy. *J Neurol* 2009;256:1343-5.
12. Jones LK Jr., Reda H, Watson JC. Clinical, electrophysiologic, and imaging features of zoster-associated limb paresis. *Muscle Nerve* 2014;50:177-85.
13. Yoshikawa TT, Schmader K. Herpes zoster in older adults. *Clin Infect Dis* 2001;32:1481-6.
14. Buchbinder SP, Katz MH, Hessol NA, Liu JY, O'Malley PM, Underwood R, *et al.* Herpes zoster and human immunodeficiency virus infection. *J Infect Dis* 1992;166:1153-6.
15. Colebunders R, Mann JM, Francis H, Bila K, Izaley L, Ilwaya M, *et al.* Herpes zoster in African patients: A clinical predictor of human immunodeficiency virus infection. *J Infect Dis* 1988;157:314-8.