



CORRESPONDENCE OPEN

Pathological and molecular examinations of postmortem testis biopsies reveal SARS-CoV-2 infection in the testis and spermatogenesis damage in COVID-19 patients

Xixiang Ma¹, Chuhuai Guan², Rong Chen³, Yunyun Wang², Shenglei Feng¹, Rongshuai Wang⁴, Guoqiang Qu⁴, Sijia Zhao¹, Fengli Wang¹, Xiaoli Wang¹, Dingyu Zhang^{5,6}, Liang Liu², Aihua Liao¹ and Shuiqiao Yuan¹

Cellular & Molecular Immunology (2021) 18:487–489; <https://doi.org/10.1038/s41423-020-00604-5>

In late December 2019, the novel severe acute respiratory syndrome coronavirus 2 (SARS-CoV-2), which causes coronavirus disease 2019 (COVID-19), was identified in Wuhan, China, and the ensuing pandemic has led to more than 50 million infected individuals and more than one million deaths by November 10, 2020 (<https://covid19.who.int/>). Pathologic investigations of autopsy tissue have focused primarily on the lung, heart, and kidney, whereas morphologic data on testis injury and the effects of SARS-CoV-2 infection on spermatogenesis are limited. Although two groups did not detect SARS-CoV-2 in the semen or testes of recovered COVID-19 patients,^{1,2} another group confirmed SARS-CoV-2 in the semen of patients.³ Therefore, it is currently unknown whether SARS-CoV-2 infection impacts spermatogenesis and male fertility. In the present study, we evaluated the effects of SARS-CoV-2 infection on spermatogenesis by examining the pathophysiology and molecular features of testes obtained from five male COVID-19 patients at autopsy.

First, the histological morphology of the testes from five COVID-19 patients and three uninfected controls was examined by periodic acid-Schiff (PAS) staining. The COVID-19 patients were aged 51, 62, 70, 78, and 83 years, and the control patients were aged 71, 78, and 80 years (Supplementary Table S1). In all five COVID-19 patients, numerous degenerated germ cells (GCs) had sloughed into the lumen of seminiferous tubules (Fig. 1a). In contrast, in the age-matched control tissues, GCs at various stages were well aligned around the whole seminiferous tubules (Fig. 1a). Strikingly, in four of the five cases, GC loss was massive, with only a few GCs left attached to the seminiferous tubules. In particular, many seminiferous tubules in the testes of patients 4 and 5 showed almost no intact GCs, similar to Sertoli cell-only syndrome. Consistent with this morphological observation, the number of DDX4 (a germ cell marker)-positive cells was dramatically reduced in all testicular specimens from the COVID-19 group (Supplementary Fig. S1a, b). Interestingly, the number of Sertoli cells in the testes of SARS-CoV-2-infected patients and uninfected controls was comparable (Supplementary Fig. S1c, d), suggesting that SARS-CoV-2 infection may not impair Sertoli cells. These morphological changes in the testes of COVID-19 patients

indicate that SARS-CoV-2 infection may impair male GC development and eventually lead to GC loss.

SARS-CoV-2 can induce cellular and humoral immune changes and destroy antiviral immunity at an early stage in COVID-19 patients.^{4,5} To ascertain how male GC loss occurs in patients with COVID-19, we investigated the presence of apoptosis and inflammatory reactions in the testicular cells. TUNEL assays revealed that the number of apoptotic cells in COVID-19 testes was significantly higher than that in control testes (Supplementary Fig. S1e, f), raising the possibility that SARS-CoV-2 damages the immune privilege and innate immune homeostasis of the testis. Indeed, immunohistochemical (IHC) staining for various immune cells revealed scattered infiltration of CD3⁺ T lymphocytes, CD20⁺ B lymphocytes, and CD68⁺ macrophages in the interstitial compartments of patients with COVID-19, whereas such infiltration was rarely detected in controls (Fig. 1b–d). In addition, we found CD38⁺ (activated B cells) and CD138⁺ (plasma cells) cells in the interstitial compartments of COVID-19 patient testes (Supplementary Fig. S2a, b). Correspondingly, extensive IgG precipitation was observed mainly in the seminiferous epithelium, interstitium, and some degenerated GCs, similar to the findings in SARS-infected testes (Fig. 1e).⁶ These data suggest that SARS-CoV-2 might trigger a secondary autoimmune response and contribute to the primary pathogenesis of viral orchitis and consequent testicular damage.

To further determine whether SARS-CoV-2 can directly attack testicular cells, we first detected the nucleic acid sequence of SARS-CoV-2 in the testes of COVID-19 patients. Through RT-qPCR-based virus nucleic acid detection, we found two testis samples (patients 1 and 3) to be positive for SARS-CoV-2 nucleic acid (Supplementary Table S2). To further confirm the presence of the virus, we examined the testes from COVID-19 patients by immunohistochemistry using an anti-SARS-CoV spike S1 antibody. As shown in Fig. 1f, the testicular sections from patients stained positively, indicating infection of testicular cells by SARS-CoV-2. (Fig. 1f) and suggesting that SARS-CoV-2 indeed infects testicular cells through the spike glycoprotein binding mechanism. Further transmission electron microscopy (TEM) analyses revealed coronavirus-like particles in the interstitial compartment of the

¹Institute of Reproductive Health, Tongji Medical College, Huazhong University of Science and Technology, Wuhan, Hubei 430030, China; ²Department of Forensic Medicine, Tongji Medical College, Huazhong University of Science and Technology, Wuhan, Hubei 430030, China; ³Department of Pathology, Wuhan Jinyintan Hospital, Wuhan, Hubei 430023, China; ⁴Hubei Chongxin Judicial Expertise Center, Wuhan, Hubei 430415, China; ⁵Research Center for Translational Medicine, Wuhan Jinyintan Hospital, Wuhan, Hubei 430023, China and ⁶Joint Laboratory of Infectious Diseases and Health, Wuhan Institute of Virology and Wuhan Jinyintan Hospital, Chinese Academy of Sciences, Wuhan, Hubei 430023, China

Correspondence: Liang Liu (907505@qq.com) or Aihua Liao (aihua_liao@sina.com) or Shuiqiao Yuan (shuiqiaoyuan@hust.edu.cn)

These authors contributed equally: Xixiang Ma, Chuhuai Guan, Rong Chen

Received: 11 November 2020 Accepted: 20 November 2020

Published online: 14 December 2020

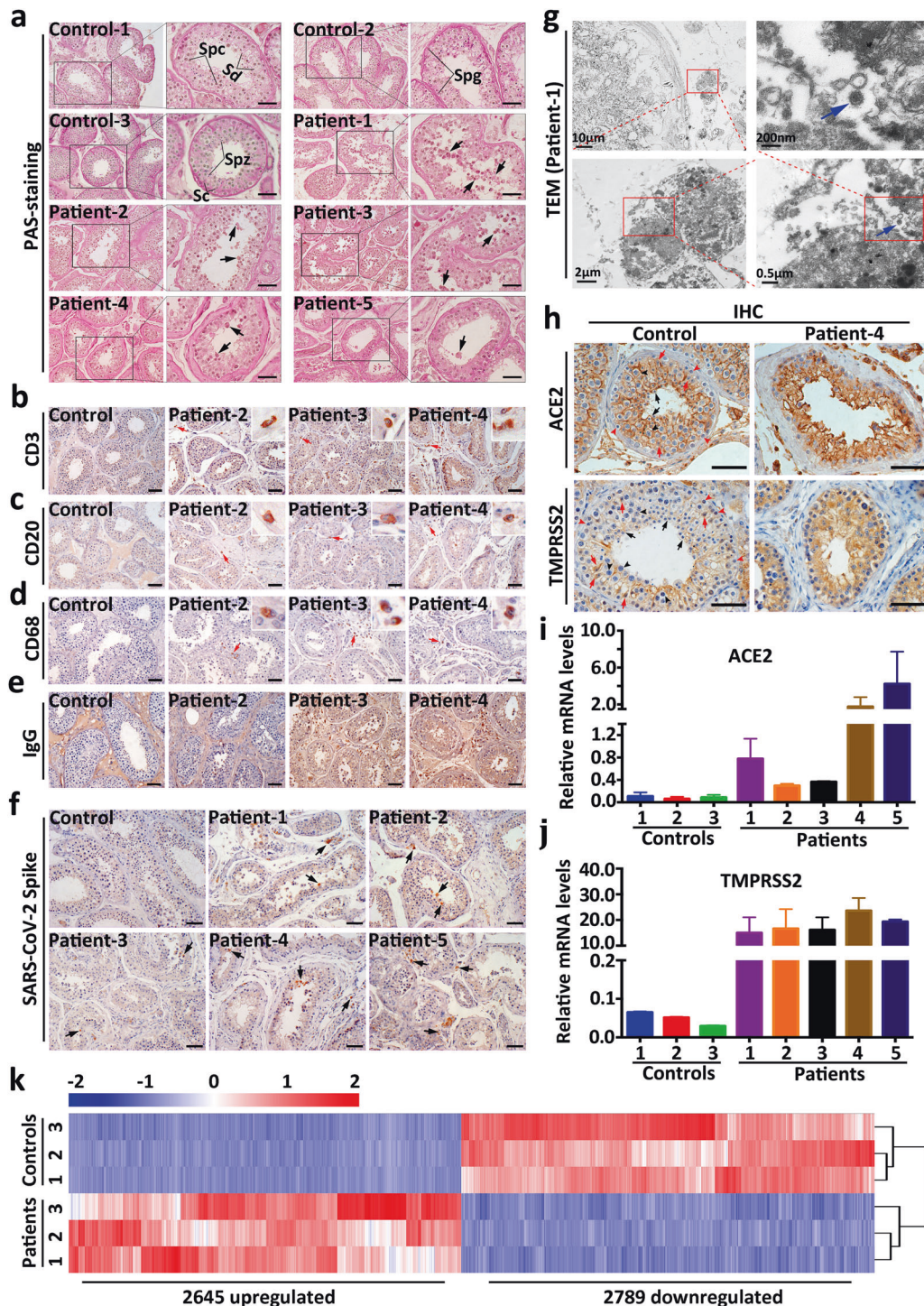


Fig. 1 Spermatogenesis damage was observed in COVID-19 patients. **(a)** Histological analyses of testicular sections from COVID-19 patients (patients 1, 2, 3, 4, and 5) and uninfected controls (controls 1, 2, and 3) showing numerous degenerated germ cells sloughing into the lumen of the seminiferous tubules of all five COVID-19 patients; normal spermatogenesis was observed in control patients. Spg spermatogonia, Spc spermatocytes, Sd spermatids, Spz spermatozoa, Sc Sertoli cells. Arrows indicate degenerated germ cells. Scale bar = 100 µm. Representative PAS-stained testicular sections of control and COVID-19 patients (patients 2, 3, and 4) are shown. Scale bar = 100 µm. The right upper image represents a magnified inset for each positive cell stain. **(b)** Representative SARS-CoV-2 spike protein immunohistochemical staining images in the testicular sections of control and COVID-19 patients (patients 1, 2, 3, 4, and 5) are shown. Black arrows indicate SARS-CoV-2 spike S1-positive cells. Scale bar = 100 µm. **(c)** Representative CD3 (b), CD20 (c), C68 (d), and human IgG (e) immunohistochemical staining images in the testicular sections of control and COVID-19 patients (patients 2, 3, and 4) are shown. Scale bar = 100 µm. **(d)** Representative SARS-CoV-2 spike protein immunohistochemical staining images in the testicular sections of control and COVID-19 patients (patients 1, 2, 3, 4, and 5) are shown. Black arrows indicate SARS-CoV-2 spike S1-positive cells. Scale bar = 100 µm. **(e)** Representative SARS-CoV-2 spike protein immunohistochemical staining images in the testicular sections of control and COVID-19 patients (patients 1, 2, 3, 4, and 5) are shown. Black arrows indicate SARS-CoV-2 spike S1-positive cells. Scale bar = 100 µm. **(f)** Representative SARS-CoV-2 spike protein immunohistochemical staining images in the testicular sections of control and COVID-19 patients (patients 1, 2, 3, 4, and 5) are shown. Black arrows indicate SARS-CoV-2 spike S1-positive cells. Scale bar = 100 µm. **(g)** Electron microscopy of the testis from COVID-19 patient 1, showing coronavirus-like particles suggestive of viral infection (viral particles are highlighted by blue arrows). **(h)** Representative ACE2 (upper panel) and TMPRSS2 (lower panel) immunohistochemical staining images in the testicular sections of a control and COVID-19 patient (patient 4) are shown. Black arrows indicate round spermatids; black arrowheads indicate pachytene spermatocytes; red arrows indicate Sertoli cells; red arrowheads indicate spermatogonia. Scale bar = 100 µm. **(i)** RT-qPCR analyses of relative ACE2 **(j)** mRNA levels in controls (controls 1, 2, and 3) and COVID-19 patients (patients 1, 2, 3, 4, and 5). Each color bar represents one sample. **(k)** Heat map of genes significantly deregulated in the testes of COVID-19 patients compared to those in the testes of controls.

testes of COVID-19 patients (Fig. 1g and Supplementary Fig. S2c), providing direct evidence that SARS-CoV-2 enters and attacks human testicular tissues.

The SARS-CoV-2 spike protein binds to the angiotensin-converting enzyme 2 (ACE2) receptor through its receptor-binding domain. In turn, ACE2 employs the serine protease TMPRSS2 to activate the S protein, allowing its HR1 and HR2 domains to interact with each other and form a six-helical bundle (6-HB) to mediate membrane fusion between the virus and a target cell.^{7–9} Therefore, we next examined the protein and mRNA levels of ACE2 and TMPRSS2 in the testes. Although both ACE2 and TMPRSS2 proteins were predominantly expressed in the cytoplasm and membrane of spermatocytes, spermatids, and Sertoli cells in control testes, elevated ACE2 and TMPRSS2 levels were observed in the seminiferous tubules of all patients with COVID-19 (Fig. 1h and Supplementary Fig. S3a, b). Consistent with the immunohistochemistry results, RT-qPCR showed significantly increased mRNA levels of ACE2 and TMPRSS2 in the testes of all COVID-19 patient compared to control patient testes (Fig. 1i, j). Together, these results indicate that the signal intensity of ACE2- and TMPRSS2-positive cells in the testes of patients with COVID-19 is higher than that in the testes of uninfected controls, which further supports the hypothesis that SARS-CoV-2 is able to attack testicular cells. However, it is not clear how SARS-CoV-2 interferes with ACE2 and TMPRSS2 expression and/or their regulation. Some common diseases (COVID-19 comorbidities) are reported to be related to ACE2 expression,¹⁰ and it is possible that higher levels of ACE2 and TMPRSS2 are observed in COVID-19 patient testes because patients with severe COVID-19 are more susceptible to SARS-CoV-2 due to underlying disease or individual differences in ACE2 and TMPRSS2 expression.

To investigate the molecular changes associated with SARS-CoV-2 infection in testes, we extracted total RNA from control (controls 1, 2, and 3) and COVID-19 patient (patients 1, 2, and 3) testes and performed RNA-seq to analyze transcriptome changes. The analysis revealed 28,801 expressed coding RNAs and lncRNAs in control and COVID-19 patient testes (Supplementary Table S3), of which 2645 were upregulated and 2789 were downregulated in COVID-19 patients compared with controls (fold change > 2, FDR < 0.001) (Fig. 1k, Supplementary Fig. S4a and Table S4). These results suggest that SARS-CoV-2 infection triggers dynamic transcriptome alterations at the molecular level in testes during specific biological processes.

To further characterize changes in the transcriptome upon SARS-CoV-2 infection in the testes, we performed Gene Ontology term analysis of the differentially regulated genes. Consistent with our virus RNA detection and IHC results, the upregulated transcripts were significantly enriched in terms related to virus invasion, such as “viral gene expression” and “viral life cycle” (Supplementary Fig. S4b). Importantly, some inflammation-related processes were activated, including the “interleukin-6-mediated signaling pathway” and “regulation of B-cell proliferation”. Consistent with our histological results (Fig. 1a), the downregulated genes were significantly enriched in “spermatogenesis” and “reproduction” (Supplementary Fig. S4c), further illustrating the impact of SARS-CoV-2 infection on male fertility. Moreover, we found 32 inflammatory cytokines to be considerably upregulated, with a *P* value < 0.05 and fold change > 2, in COVID-19 patient testes, and 10 of these cytokines (CMTM6, FAM3C, INHBA, IL33, TNFSF10, NAMPT, CMTM4, CCL28, IL2, and TIMP1) were significantly upregulated with an FDR < 0.001 (Supplementary Fig. S4d). These bioinformatics data suggest that SARS-CoV-2 infection may lead to dysfunction of the genes that regulate spermatogenesis and inflammation-related pathways, thereby causing inflammatory immune attack in the testes and defects in spermatogenesis.

Collectively, our findings provide direct evidence that SARS-CoV-2 can infect the testis and GCs, indicating the potential

impact of the COVID-19 pandemic on spermatogenesis and male fertility. Nevertheless, further study is essential to reveal the underlying mechanism of SARS-CoV-2 infection of testicular cells and the correlation of testis infection with the clinical course of COVID-19.

ACCESSION CODES

The RNA-seq data have been submitted to the NCBI GEO database (PRJNA661970).

ACKNOWLEDGEMENTS

We thank the patients and their families for their dedication to help others understand this disease. We are also grateful for the support of the clinical staff and technicians for performing the autopsy work. This work was supported by the Strategic Collaborative Research Program of the Ferring Institute of Reproductive Medicine, Ferring Pharmaceuticals and Chinese Academy of Sciences (FIRMSCO02), the Cultivation Plan of International Joint Research Platform of Huazhong University of Science and Technology (5001519009), and Emergency Research Funds of Ministry of Science and Technology of P.R. China (2020YFC0844700).

ADDITIONAL INFORMATION

The online version of this article (<https://doi.org/10.1038/s41423-020-00604-5>) contains supplementary material.

Competing interests: The authors declare no competing interests.

REFERENCES

1. Pan, F. et al. No evidence of severe acute respiratory syndrome-coronavirus 2 in semen of males recovering from coronavirus disease 2019. *Fertil. Steril.* **113**, 1135–1139 (2020).
2. Song, C. et al. Absence of 2019 novel coronavirus in semen and testes of COVID-19 patients. *Biol. Reprod.* **103**, 4–6 (2020).
3. Li, D., Jin, M., Bao, P., Zhao, W. & Zhang, S. Clinical characteristics and results of semen tests among men with coronavirus disease 2019. *JAMA Netw. Open* **3**, e208292 (2020).
4. Zheng, H. Y. et al. Elevated exhaustion levels and reduced functional diversity of T cells in peripheral blood may predict severe progression in COVID-19 patients. *Cell Mol. Immunol.* **17**, 541–543 (2020).
5. Zheng, M. et al. Functional exhaustion of antiviral lymphocytes in COVID-19 patients. *Cell Mol. Immunol.* **17**, 533–535 (2020).
6. Xu, J. et al. Orchitis: a complication of severe acute respiratory syndrome (SARS). *Biol. Reprod.* **74**, 410–416 (2006).
7. Tai, W. et al. Characterization of the receptor-binding domain (RBD) of 2019 novel coronavirus: implication for development of RBD protein as a viral attachment inhibitor and vaccine. *Cell Mol. Immunol.* **17**, 613–620 (2020).
8. Xia, S. et al. Fusion mechanism of 2019-nCoV and fusion inhibitors targeting HR1 domain in spike protein. *Cell Mol. Immunol.* **17**, 765–767 (2020).
9. Hoffmann, M. et al. SARS-CoV-2 cell entry depends on ACE2 and TMPRSS2 and is blocked by a clinically proven protease inhibitor. *Cell* **181**, 271 (2020).
10. Breidenbach, J. D. et al. Impact of comorbidities on SARS-CoV-2 viral entry-related genes. *J. Pers. Med.* **10**, E146 (2020).



Open Access This article is licensed under a Creative Commons Attribution 4.0 International License, which permits use, sharing, adaptation, distribution and reproduction in any medium or format, as long as you give appropriate credit to the original author(s) and the source, provide a link to the Creative Commons license, and indicate if changes were made. The images or other third party material in this article are included in the article's Creative Commons license, unless indicated otherwise in a credit line to the material. If material is not included in the article's Creative Commons license and your intended use is not permitted by statutory regulation or exceeds the permitted use, you will need to obtain permission directly from the copyright holder. To view a copy of this license, visit <http://creativecommons.org/licenses/by/4.0/>.

© The Author(s) 2020