

## Subcutaneous Achilles tendon rupture in an eighty-year-old female with an absence of risk factors

Motoki Sonohata,<sup>1</sup> Tsutomu Okamoto,<sup>2</sup> Kazuyoshi Uchihashi,<sup>3</sup> Tsutomu Motooka,<sup>1</sup> Hirofumi Tanaka,<sup>1</sup> Masaru Kitajima,<sup>1</sup> Masaaki Mawatari,<sup>1</sup> Takao Hotokebuchi<sup>1</sup>

<sup>1</sup>Department of Orthopaedic Surgery, Faculty of Medicine, Saga University, Nabeshima, Saga, Japan;

<sup>2</sup>Department of Orthopaedic Surgery, Omuta Memorial Hospital, Kunugi, Fukuoka, Japan;

<sup>3</sup>Department of Pathology and Biodefense, Faculty of Medicine, Saga University, Nabeshima, Saga, Japan

### Abstract

Achilles tendon ruptures rarely occur in patients over 80 years of age. However, it is unclear what treatment, surgical or conservative, is suitable for such an Achilles tendon rupture in the elderly. In addition, the clinical results of an Achilles tendon rupture in the elderly are disappointing. We report here the case of a subcutaneous Achilles tendon rupture in an eighty-year-old, healthy female, who returned to her previous level of activity following surgical treatment. Additional case reports of other instances of successful treatment are needed to help establish the optimal treatment protocol for an Achilles tendon rupture in the elderly.

### Introduction

The Achilles tendon is the most frequently ruptured tendon in the lower limb and it accounts for approximately 20% of all large tendon injuries.<sup>1</sup> Epidemiological data from Malmö, Sweden have shown an incidence curve with two peaks, one in young, middle-aged subjects and one in those in their 70s.<sup>2</sup> The treatment for a ruptured Achilles tendon is controversial still, and the outcome and complications are well documented in studies mainly involving patients active in sports.<sup>3,5</sup> However, it is difficult for elderly patients with a ruptured Achilles tendon to return to their previous levels of activity, and there are few reports on treating ruptured Achilles tendons in the elderly.<sup>6</sup>

Achilles tendon rupture rarely occurs in

patients over 80 years of age.<sup>6,8</sup> However, in this report we describe a case of a subcutaneous Achilles tendon rupture in an eighty-year-old, healthy female, who returned to her previous level of activity following surgical treatment. The patient was informed that this case study would be submitted for publication, and she gave her written informed consent.

### Case Report

An 80-year-old female (height, 148 cm; weight, 55 kg) was referred to the hospital because of sudden pain in her left calf after falling approximately 30 cm. She was diagnosed to have hypertension only, which had been treated with nifedipine and candesartan cilexetil. However, she was otherwise normal and did not take either corticosteroids or newquinolone antibiotics, such as fluoroquinolone, ciprofloxacin, or levofloxacin. She had experienced no pain in her Achilles tendon, such as achillobygia, before the injury.

A physical examination revealed moderate swelling of the left distal calf, with maximal tenderness about 4 cm proximal to the insertion of the Achilles tendon. She was unable to bear weight or dorsiflex her ankle. A Simmonds-Tompson calf-squeeze test was positive. Radiographic studies revealed that there was no osteoarthritis at the talocrural or talocalcaneal joints, calcium deposition on the Achilles tendon, or bony spurs. The sharp contour of the fat pad in Kager's triangle was absent and the margins became serrated and indistinct (Figure 1A). A magnetic resonance image demonstrated a rupture of the Achilles tendon, and there was no space-occupying lesion (Figure 1B). The laboratory test results including the white blood cell count, hemoglobin, blood urine nitrogen, and creatinine were within normal limits.

Surgical treatment was performed six days after the injury. An exploratory examination confirmed the physical findings of a rupture of the tendon. The Achilles tendon was completely ruptured at its midportion. The color of the paratenon suggested healthy tissue; however, there were definite degenerative changes at the end of the Achilles tendon that could be observed macroscopically (Figure 2). The Achilles tendon was sutured end-to-end according to the Kessler method. The proximal frayed end of the ruptured Achilles tendon was resected. The specimens showed a mixture of normal tendon tissue and degenerative tissue. Fibrosis and hyalinization with angiogenesis extended into normal tendon near the ruptured lesion. The histology findings did not show either Achilles tendinopathy or a neoplastic lesion (Figure 3).

The patient's leg was placed in a short-leg

Correspondence: Motoki Sonohata, Department of Orthopaedic Surgery, Faculty of Medicine, Saga University, Nabeshima 5-1-1, Saga 849-8501, Japan. E-mail: epc9719@yahoo.co.jp

Key words: Achilles tendon, elderly, surgical treatment.

Contributions: TO was in charge of the patient. KU contributed to the description of the histology finding; TM, HT, MK, MM, TH participated in the initial conceptualization and design of the intervention, and advised on most aspects of the study. All authors contributed to the drafting of this manuscript and approved the final version. This research was carried out at the Department of Orthopaedic Surgery, Faculty of Medicine, Saga University.

Conflict of interest: the authors report no conflicts of interest.

Received for publication: 1 February 2010.

Revision received: 24 March 2010.

Accepted for publication: 24 March 2010.

This work is licensed under a Creative Commons Attribution 3.0 License (by-nc 3.0).

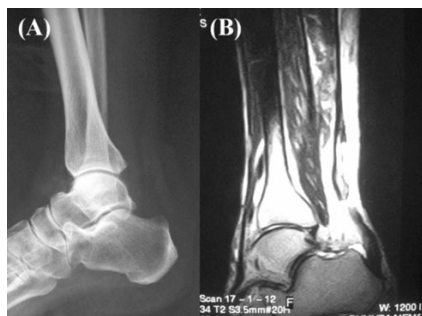©Copyright M. Sonohata et al., 2010  
Licensee PAGEPress, Italy  
Orthopedic Reviews 2010; 2:e11  
doi:10.4081/or.2010.e11

cast in minimal plantar flexion for one week. She then gradually started weight-bearing with a brace, and six weeks after the operation she regained full range of motion in her ankle and was able to walk on her own. The patient was examined one year after the rupture and was found to be completely asymptomatic. At the last follow-up two years after the operation, she remained asymptomatic. In addition, radiographic studies and magnetic resonance imaging were performed. The radiographic studies showed calcification of the Achilles tendon around the suture site, and the Kager's triangle appeared (Figure 4A). Magnetic resonance imaging showed a healed Achilles tendon (Figure 4B).

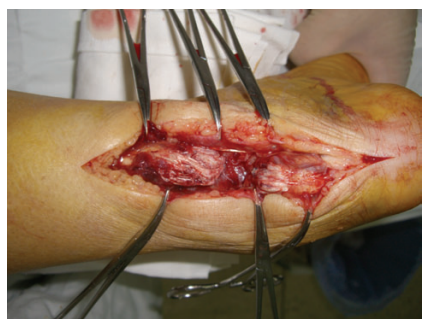### Discussion

Epidemiological studies showed that the incidence of Achilles tendon rupture ranges from 4.2 to 37.3 in 100,000 people. In addition, there is a trend of increased incidence over time.<sup>7-10</sup> The number of elderly patients with Achilles tendon rupture is increasing, because the mean age of the population is increasing.<sup>6</sup>

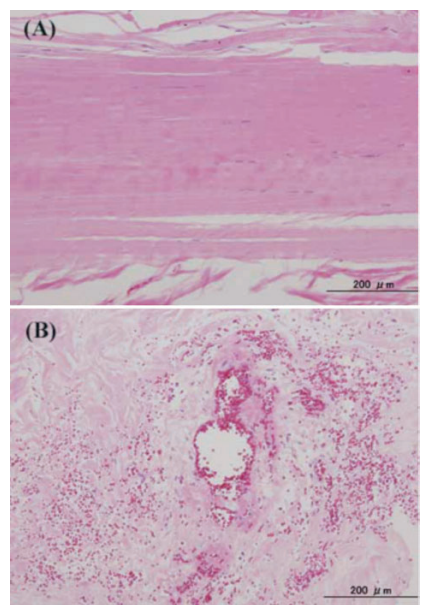
The risk factors associated with the Achilles tendon include the use of corticosteroids or newquinolone antibiotics; renal failure; sys-



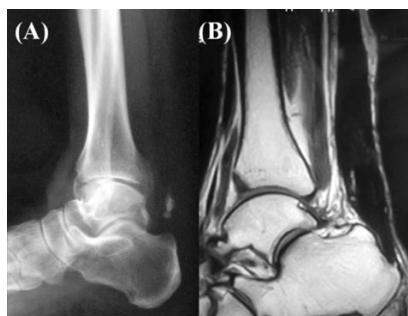
**Figure 1.** (A) Lateral radiograph demonstrating a negative Kager's sign. There is no abnormality in the bone and joint construction. (B) Magnetic resonance image showing a common tear of the Achilles tendon.



**Figure 2.** Macroscopic findings during the operation. The Achilles tendon was ruptured at the midportion. There were definite degenerative changes.



**Figure 3.** Histology of the ruptured Achilles tendon (hematoxylin and eosin stain). (A) Normal Achilles tendon demonstrating parallel, slightly wavy collagen bundles, and slender, elongated, fibroblast cell nuclei. (B) Part of the Achilles tendon tissue included degenerative changes with fibrosis and hyalinization around a neovascular vessel. It does not show findings consistent with Achilles tendinopathy and a neoplastic lesion.



**Figure 4.** (A) Lateral radiograph two years after the operation, demonstrating a positive Kager's sign and calcium deposits on the Achilles tendon. (B) Magnetic resonance image taken two years after the operation showed the continuous Achilles tendon.

temic disease such as diabetes, gout, hyperparathyroidism; connective tissue disorders; neurological disorders; sports activities; a male gender; and the elderly (>60 years of age).<sup>8,11</sup> Several lines of evidence indicate that the blood supply decreases,<sup>12,13</sup> the tendon collagen volume increases, and glycosaminoglycans and water content decrease in the aging Achilles tendon.<sup>14</sup> Therefore, age significantly affects the ultimate tensile strength and the tangent of the modulus of elasticity in the tendon.<sup>15</sup> Furthermore, there has been an increase in the use of new quinolone antibiotics in elderly inpatients and outpatients, which is a risk factor for an Achilles tendon rupture.<sup>16</sup>

The use of surgical or conservative treatment for an Achilles tendon rupture still remains controversial. The optimal treatment of Achilles tendon rupture is unknown. Both types of treatment have a good outcome; however, many reports included only young and middle-aged subjects in the clinical analysis.<sup>3,10</sup> The case reports of Achilles tendon ruptures in the elderly mainly targeted the cases with complications associated with the risk factors of Achilles tendon rupture.<sup>14</sup> There are few reports involving healthy elderly people. Therefore, the treatment for Achilles tendon rupture in the elderly has rarely been addressed.

The clinical results of Achilles tendon rupture in the elderly are disappointing,<sup>6</sup> and it is necessary to determine whether treatments that are effective for young and middle-aged patients can be used for elderly patients. The increased life expectancy has increased not only the number of healthy elderly people but also the number of elderly athletes.<sup>17</sup> Therefore, it is important to establish a therapeutic strategy for Achilles tendon rupture in the elderly.

Although our patient was 80 years old, her condition following the surgical treatment improved considerably. However, calcification of the Achilles tendon was observed two years after the operation. Achilles tendon calcifica-

tion can result in posterior heel pain,<sup>18</sup> and there is a case report of rupture of the calcified Achilles tendon.<sup>19</sup> Therefore, a close clinical follow-up of this patient is necessary. Unfortunately, there is no way to determine whether the surgical treatment really had a favorable influence on the clinical results. Nevertheless, surgical treatment of an Achilles tendon rupture in our healthy 80-year-old female patient showed good clinical results. Therefore, aggressive surgical treatment for elderly patients with a ruptured Achilles tendon is feasible. Additional case reports of other successful treatments are needed in the future to help reach a consensus for the optimal treatment of such patients.

## References

- Haines JF. Bilateral rupture of the Achilles tendon in patients on steroid therapy. *Ann Rheum Dis* 1983;42:652-4.
- Möller A, Åstrom M, Westlin N. Increasing incidence of Achilles tendon rupture. *Acta Orthop Scand* 1996;67:479-81.
- Nistor L. Surgical and non-surgical treatment of Achilles tendon rupture. A prospective randomized study. *J Bone Joint Surg Am* 1981;63:349-99.
- Cetti R, Christensen SE, Ejsted R, et al. Operative versus nonoperative treatment of Achilles tendon rupture. A prospective randomized study and review of the literature. *Am J Sports Med* 1993;21:791-9.
- Lo IK, Kirkley A, Nonweiler B, et al. Operative versus nonoperative treatment of acute Achilles tendon ruptures: a quantitative review. *Clin J Sport Med* 1997;7:207-11.
- Nestorson J, Movin T, Möller M, et al. Function after Achilles tendon rupture in the elderly: 25 patients older than 65 years followed for 3 years. *Acta Orthop Scand* 2000;71:64-8.
- Houshian S, Tscherning T, Riegels-Nielsen P. The epidemiology of Achilles tendon rupture in a Danish county. *Injury* 1998;29:651-4.
- Pajala A, Kangas J, Ohtonen P, et al. Rupture and deep infection following treatment of total Achilles tendon rupture. *J Bone Joint Surg Am* 2002;84:2016-21.
- Maffulli N, Waterston SW, Squair J, et al. Changing incidence of Achilles tendon rupture in Scotland: a 15-year study. *Clin J Sport Med* 1999;9:157-60.
- Nyyssönen T, Lüthje P. Achilles tendon ruptures in South-East Finland between 1986-1996, with special reference to epidemiology, complications of surgery and hospital costs. *Ann Chir Gynaecol* 2000;89:53-7.
- Akali AU, Niranjana NS. Management of

- bilateral Achilles tendon rupture associated with ciprofloxacin: a review and case presentation. *J Plast Reconstr Aesthet Surg* 2008;61:830-83.
12. Håstad K, Larsson LG, Lindholm Å. Clearance of radiosodium after local deposit in the Achilles tendon. *Acta Chir Scand* 1958/59;116:251-5.
  13. Åström M, Westlin N. Blood flow in the human Achilles tendon assessed by laser Doppler flowmetry. *J Orthop Res* 1994;12: 246-52.
  14. Ippolito E, Natali PG, Postacchini F, et al. Morphological, immunochemical, and biochemical study of rabbit Achilles tendon at various ages. *J Bone Joint Surg Am* 1980; 62:583-98.
  15. Lewis G, Shaw KM. Tensile properties of human tendon Achilles: effect of donor age and strain rate. *J Foot Ankle Surg* 1997; 36:435-45.
  16. Corrao G, Zambon A, Bertù L, et al. Evidence of tendinitis provoked by fluoroquinolone treatment: a case-control study. *Drug Saf* 2006;29:889-96.
  17. Pigozzi F, Spataro A, Alabiso A, et al. Role of exercise stress test in master athletes. *Br J Sports Med* 2005;39:527-31.
  18. Fiamengo SA, Warren RF, Marshall JL, et al. Posterior heel pain associated with a calcaneal step and Achilles tendon calcification. *Clin Orthop Relat Res* 1982;167: 203-11.
  19. Wick MC, Rieger M. Images in clinical medicine. Rupture of a calcified Achilles' tendon. *N Engl J Med* 2008;358:2618.