

Panniculitis caused by *Mycobacterium monacense* mimicking erythema induratum: a case in Ecuador

J. J. Romero^{1,3}, P. Herrera¹, M. Cartelle², P. Barba², S. Tello⁴ and J. Zurita^{1,2,3}

1) Hospital Vozandes, 2) Unidad de Investigaciones en Biomedicina, Zurita & Zurita Laboratorios, 3) Facultad de Medicina, Pontificia Universidad Católica del Ecuador and 4) Laboratorio de Patología, Hospital AXXIS, Quito, Ecuador

Abstract

We report the first case of recently characterized species *M. monacense* associated with chronic nodular vasculitis, infecting a young woman. This case represents the first isolation of *M. monacense* from Ecuador. The isolate was identified by conventional and molecular techniques.

New Microbes and New Infections © 2016 The Authors. Published by Elsevier Ltd on behalf of European Society of Clinical Microbiology and Infectious Diseases.

Keywords: Ecuador, erythema induratum, *Mycobacterium monacense*, Non-tuberculous mycobacteria

Original Submission: 12 October 2015; **Revised Submission:** 2 January 2016; **Accepted:** 14 January 2016

Article published online: 22 January 2016

Corresponding author: J. Zurita, Hospital Vozandes, Villalengua Oe2-37, Quito, Ecuador
E-mail: jzurita@zuritalaboratorios.com

Introduction

Continued improvement of techniques for identification of mycobacteria has produced a resurgence of interest in diseases caused by species other than *Mycobacterium tuberculosis*. Currently there are more than 150 species of nontuberculous mycobacteria, and more than half are considered definite or potential pathogens in humans [1].

Mycobacterium monacense is rapidly growing nontuberculous mycobacteria, first described in 2006 by Reischl *et al.* [2]. The name *monacense* come from Monacum, the Latin name of the German city of Munich, where the first strain was isolated. Subsequently five additional reports [3–7] have been published that describe infection by this new species. Here we report the first case of *M. monacense* associated with chronic nodular vasculitis infecting a woman in Ecuador.

Erythema induratum was previously described in association with tuberculosis in the middle of the 19th century. The clinical picture is characterized by tender violaceous nodules and plaques most commonly affecting the posterior lower legs (usually calves), with the shins involved less often. The nodules are tender and erythematous (those may ulcerate with bluish borders), and cold weather may be a precipitating factor. About half of the patients have a past or present history of tuberculosis. This is most often pulmonary tuberculosis, with cervical lymphadenopathy second. Erythema induratum often remains undiagnosed or misdiagnosed because it is often mistaken for other types of chronic nodules of the lower extremities.

Case Report

A 29-year-old woman with a previous clinical diagnosis of erythema nodosum 4 months before was admitted to hospital with chronic recurrent nodular lesions in both legs associated with moderate pain and erythema. She had previously received topical steroid injections in the lesions, with partial improvement. Four days before admission, she noted a new nodular lesion on the anterior aspect of her left knee.

The skin lesions were tender erythematous nodules approximately 3 cm in diameter located on the anterior and posterior aspects both legs (Fig. 1). An ulcerated nodule with an abscess was present on the medial aspect of her left knee. At admission, here complete blood count was 8580 leucocytes with 50.8% neutrophils, hemoglobin 12.4 g/dL and C-reactive protein 68.99 mg/dL. Because of the possibility of erythema induratum, a chest X-ray was conducted, which revealed no pathologic lesions on the lungs. Serology for hepatitis B and C virus was negative.

A deep biopsy of the nodular lesion was performed; the biopsy sample was sent for histopathologic, bacteriologic and mycobacteriologic diagnosis. Results revealed lobular panniculitis consistent with nodular vasculitis (Fig. 1). Ziehl-Neelsen staining, performed on a direct biopsy sample, was negative for acid-fast bacilli.

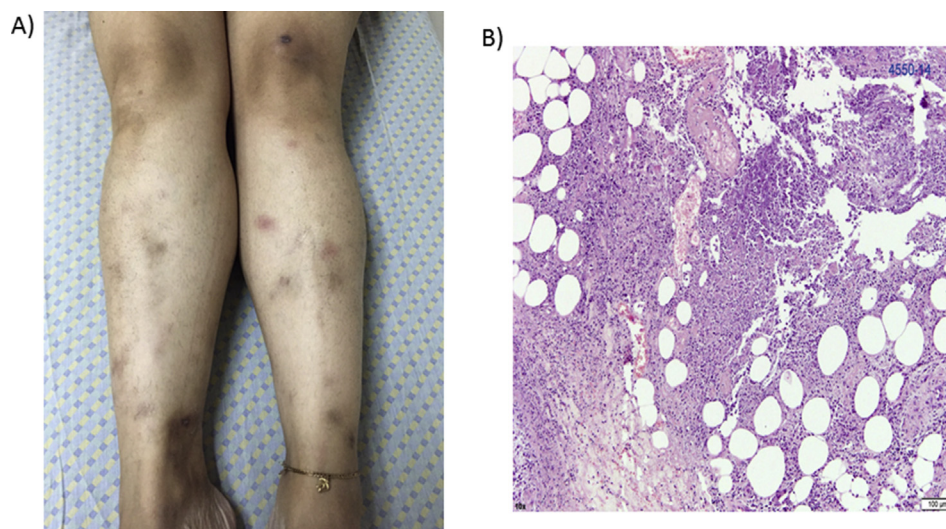


FIG. 1. (A) Tender nodular lesions present on anterior aspects of legs. (B) Biopsy sample of nodular lesion revealing lobular panniculitis and lymphocytic vasculitis.

The biopsy sample was cultured on chocolate agar, blood agar, MacConkey agar, Lowenstein-Jensen media and Mycobacteria Growth Indicator Tube (MGIT). After 5 days' growth in MGIT and after 7 days evidence of growth was observed on agar plates as well on Lowenstein-Jensen media but not on MacConkey agar; a rapid test for SD Bioline TB Ag MPT64 was

performed, with negative results (Standard Diagnostics, Gyeonggi-do, Korea). Cultures performed using solid media revealed yellow-pigmented colonies. Identification by matrix-assisted laser desorption/ionization time-of-flight mass spectrometry (MALDI-TOF; Bruker Daltonics, Leipzig, Germany) was performed identifying the colonies as *Mycobacterium*

TABLE 1. Review of *Mycobacterium monacense*

Year of isolation	Age (years)	Country	Clinical or underlying condition	Sample	HIV status	Acid-fast smear	Treatment	Follow-up	Reference
1998	80	Germany	Multifocal lung carcinoma and insulin-dependent diabetes mellitus	Bronchial lavage	Unknown	Unknown	Unknown	Unknown	[2]
2000–2005	11	Italy	Fistula on his right thigh from accidental deep penetration of screwdriver	Fistula	Unknown	Unknown	Unknown	Unknown	[2]
2000–2005	31	Italy	Bronchopneumonitis	Sputum	Unknown	Unknown	Unknown	Unknown	[2]
2000–2005	82	Italy	Suspected lung cancer	Sputum	Unknown	Unknown	Unknown	Unknown	[2]
2001–2006	26	Brazil	Meningitis	Cerebrospinal fluid	Positive	Unknown	Unknown	Unknown	[3]
2007	36	China	Car accident in Germany. During initial examination of broken clavicle and radius, received thoracic computed tomographic scan revealing large tumor in upper lobe of his lung highly suspicious for tuberculosis	Bronchoalveolar lavage sample and sputum	Negative	Negative	Unknown	Lost to follow-up	[4]
2007	59	USA	Non-insulin dependent Diabetes mellitus presented with pain, swelling and recurrent pustules of left thumb	Tissue biopsy	Unknown	Unknown	Clarithromycin + levofloxacin ^a	At 14-month follow-up, complete resolution had occurred and hand function was normal	[5]
2011	43	India	Diabetes	Sputum	Negative	Negative	Unknown	Lost to follow-up	[6]
2012	57	Iran	Chronic pulmonary disease	Sputum	Unknown	Positive	Antituberculosis first, amikacin + ciprofloxacin ^b	24 months later, patient did not experience relapse	[7]

^aClarithromycin 500 mg twice a day and levofloxacin 500 mg twice a day were initiated 2 months after symptoms were first noted and 1 month after the patient was first seen in the emergency room. Clinical response was discernible within 2 weeks; pain began to resolve, and erythema and swelling decreased. By 6 weeks of therapy, the patient was asymptomatic, with minimal swelling and fading erythema.

^bAfter the initial 45 days of antituberculosis therapy and the following 45 days of antimicrobial therapy of nontuberculous pulmonary infection (amikacin plus ciprofloxacin), the patient's general condition improved.

monacense. The acquired mass spectra were compared to Mycobacteria Library 2.0 reference spectra using MALDI Biotyper 3.1 software (Bruker). PCR restriction enzyme analysis (PRA)-*hsp65* was performed as described elsewhere [8]. The PRA-*hsp65* assay also identified the isolate as *M. monacense*. The sequencing of *hsp65* and *rpoB* genes confirmed the identity of the *M. monacense* isolate. The analysis of the nucleotide sequences were performed with MEGA 6 6.06 and National Center for Biotechnology Information BLAST (Basic Local Alignment Search Tool; <http://blast.ncbi.nlm.nih.gov/>). The *hsp65* and *rpoB* nucleotide sequences were deposited into GenBank with the following accession numbers: *hsp65*, KU361326I and *rpoB*, KU361327.

Susceptibility testing was performed using the rapid growing mycobacteria plate (Sensititre RAPMYCOI; Thermo Scientific, Waltham, MA, USA), showing the following breakpoints (mg/L): trimethoprim/sulfamethoxazole $\leq 0.25/4.75$, linezolid ≤ 1 , ciprofloxacin 1, imipenem 4, moxifloxacin ≤ 0.25 , cefepime 8, cefoxitin 64, amoxicillin/clavulanic acid $\leq 2/1$, amikacin ≤ 1 , ceftriaxone ≤ 4 , doxycycline ≤ 0.12 , minocycline ≤ 1 , tigecycline 0.030, tobramycin 16 and clarithromycin 8. No interpretation of the breakpoints was performed because there are no breakpoints available for *M. monacense* in the international guidelines. In this case, we also performed an Etest, which obtained the same results as RAPMYCOI, which indicates that the Etest may be helpful when access to microdilution is not possible.

The patient received a short course of oral steroids pending the microbiologic and pathologic results, with partial relief of her symptoms. The patient was informed of the diagnosis of *Mycobacterium monacense* by phone, with the recommendation that she go to hospital for the treatment to be adjusted, but the patient did not return for a follow-up consultation.

Discussion

The first description of the species *M. monacense* was made in 2006 in three nonrelated respiratory samples and one tissue biopsy sample from a posttraumatic wound infection [2]. To our knowledge, there are five additional reports on the isolation of *M. monacense* in clinical samples after the initial description (Table 1). In six respiratory samples [2,4,6,7], the clinical significance of the isolation could not be proved in three. In the two soft tissue infections, the clinical relevance was clarified in one of the cases [5].

Rapidly growing nontuberculous mycobacteria are an increasingly recognized cause of skin and soft tissue infections, with *M. abscessus*, *M. fortuitum* and *M. chelonae* being the most

common species involved. According to the clinical history, the nodular lesions preceded the topical steroid injections on the legs, suggesting that *M. monacense* caused a secondary infection of the lesions, with the port of entry being the steroid injections. Because the patient was lost to follow-up we were unable to perform further evaluation.

Nowadays, MALDI-TOF is a good tool for the diagnosis of rapid growing mycobacteria as long as the bacteria is included in the software database. Further, PCR restriction enzyme analysis has limitations, as sometimes it is not possible to distinguish among species. For these reasons, we consider that sequencing is a must when identifying rapidly growing mycobacteria [9]. In this study, the three techniques we used verified the first identification, confirming the results, but this is not always the case for noncommon rapidly growing mycobacteria or those not previously described.

Acknowledgements

We thank J. Gurr for English-language review. We also thank the staff at the Hospital Vozandes for their assistance and their authorization for the publication of this study.

Conflict of Interest

None declared.

References

- [1] Brown-Elliott B, Wallace R. Infections caused by nontuberculous mycobacteria other than *Mycobacterium avium* complex. In: Mandell, Douglas, and Bennett's principles and practice of infectious diseases. 8th ed. Philadelphia: Elsevier Saunders; 2015. p. 2844–52.
- [2] Reischl U, Melzl U, Kroppenstedt RM, Miethke T, Naumann L, Mariottini A, et al. *Mycobacterium monacense* sp. nov. Int J Syst Evol Microbiol 2006;56:2575–8.
- [3] Senna GS, Marsico AG, Vieira GB, Sobral L, Suffys PN, Fonseca L de S. Identification of nontuberculous mycobacteria isolated from clinical sterile sites in patients at a university hospital in the city of Rio de Janeiro, Brazil. J Bras Pneumol 2011;37:521–6.
- [4] Hogardt M, Schreff A, Naumann L, Reischl U, Sing A. *Mycobacterium monacense* in a patient with a pulmonary tumor. Jpn J Infect Dis 2008;61:77–8.
- [5] Taieb A, Ikeguchi R, Yu VL, Rihs JD, Sharma M, Wolfe J, et al. *Mycobacterium monacense*: a mycobacterial pathogen that causes infection of the hand. J Hand Surg 2008;33A:94–6.
- [6] Therese KL, Gayathri R, Thirupathi K, Madhavan H. First report on isolation of *Mycobacterium monacense* from sputum specimen in India. Lung India 2011;2:124–6.
- [7] Shojaei H, Hashemi A, Heidarieh P, Hosseini N, Daei Naser A. Chronic pulmonary disease due to *Mycobacterium monacense* infection: the first case from Iran. Ann Lab Med 2012;32:87–90.

- [8] Chimara E, Ferrazoli L, Ueky SY, Martins MC, Durham AM, Arbeit RD, et al. Reliable identification of mycobacterial species by PCR-restriction enzyme analysis (PRA)-*hsp65* in a reference laboratory and elaboration of a sequence-based extended algorithm of PRA-*hsp65* patterns. *BMC Microbiol* 2008;8:48.
- [9] Zurita J, Ortega-Paredes D, Mora M, Espinel N, Parra H, Febres L, et al. Characterization of the first report of *Mycobacterium timonense* infecting an HIV patient in an Ecuadorian hospital. *Clin Microbiol Infect* 2014;20: 1113–6.