



Characteristic features of newly established specific pathogen-free albino large rabbit (JW-AKT): Comparison with Japanese White and New Zealand White rabbits

Yukihisa MATSUDA¹⁾, Yoshiko SHIBATA¹⁾, Keita BASAKI¹⁾, Yasuyoshi FUKUDA¹⁾, Naofumi TAKAKI²⁾, Tatsuhiro MAEDA²⁾, Masao HIRAO²⁾, Megumi YANO¹⁾, Misako HIGASHIYA¹⁾, Takahiro OBATA¹⁾, Shinsuke SEKI¹⁾ and Kazutoshi NISHIJIMA¹⁾*

¹⁾Animal Research Laboratory, Bioscience Education-Research Support Center, Akita University, 1-1-1 Hondo, Akita 010-8543 Japan

²⁾Kitayama Labes Co., Ltd., 8046-1 Nishiminowa, Ina, Nagano 399-4501 Japan

ABSTRACT. The present study was conducted to reveal characteristic features of albino large rabbit (JW-AKT) which we formerly established a specific pathogen-free (SPF) colony. Body weights of JW-AKT rabbit at 52 weeks old was 5.7 ± 0.4 kg in males and 6.4 ± 0.4 kg in females. Weight of body, heart, lung and kidney in JW-AKT rabbit was significantly higher than in Japanese white and New Zealand white rabbits in both sexes. Though the body weight (BW) was rather lower in males, body length and brain weights tended to be higher in males than in females. Since body fat was significantly higher in females, what affects difference in BW is body fat, rather than the physical constitution of female JW-AKT rabbit. No critical sex difference was found in hematological parameters in JW-AKT rabbit. The results indicated that JW-AKT were about 1.5 times larger than the general laboratory rabbits with common properties in hematology. Thus, JW-AKT rabbit could be used as a novel SPF experimental animal model with some advantages in surgical experiments or collection of large amount of biological specimen.

KEY WORDS: alternative to dog, body size, JW-AKT, novel rabbit model

J. Vet. Med. Sci.

81(5): 739–743, 2019

doi: 10.1292/jvms.18-0758

Received: 24 December 2018

Accepted: 16 March 2019

Published online in J-STAGE:
27 March 2019

The rabbit has been used as an animal model in experiments to elucidate physiological and pathological mechanisms and in hazardous tests of toxic pyrogenic and teratogenic agents [18]. The rabbit also provides an important model animal for the study of atherosclerosis. This is because the characteristics of lipid metabolism in rabbits is more similar to that in humans compared with other animal models such as laboratory rodents like mice and rats [28]. The Watanabe heritable hyperlipidemic (WHHL) rabbit is considered a valuable model for research on hyperlipidemia and has contributed to elucidating mechanisms of lipid metabolism [25]. The rabbit has also been used in experiments that involve surgical operations in cardiology, orthopedics, and so on because of its body size, which is larger than laboratory rodents [10].

The Japanese White (JW) rabbit is a widely employed laboratory albino rabbit, along with the New Zealand White (NZW) rabbit [21]. The JW rabbit originated from the species *Oryctolagus cuniculus* from the Iberian Peninsula of Europe [6] and is documented to have been introduced to Japan at the beginning of the Meiji era (1868–1912) [11]. The JW rabbit was bred around the city of Daisen in the Akita prefecture for more than 100 years to yield more meat and fur. A large rabbit breed was established by introducing foreign rabbits such as the Flemish giant rabbit [7, 11]. The resulting rabbit breed was registered at the Ministry of Agriculture, Forestry and Fisheries of Japan as Akita Kairyō (meaning “improved” in Japanese) rabbit (Fig. 1).

Larger rabbit (including Flemish giant) models have been employed for medical research, especially in those that involved surgical treatment including vascular [2, 9, 17] and orthopedic [3–5, 12, 13, 23] surgery due to its body size. Because of recent greater animal welfare advocacy for the ethical treatment, it is getting harder to use dogs as an experimental animal [19]. Thus, there is increasing demand for the use of the larger rabbit as an animal model to replace the dog in experiments with the surgical treatment. Akita Kairyō rabbit which is albino has an advantage for laboratory use compared to colored Flemish giant.

However, since Akita Kairyō rabbits were bred as livestock animals in open field conditions, their microbiological status was

*Correspondence to: Nishijima, K.: kanish@gipc.akita-u.ac.jp

©2019 The Japanese Society of Veterinary Science



This is an open-access article distributed under the terms of the Creative Commons Attribution Non-Commercial No Derivatives (by-nc-nd) License. (CC-BY-NC-ND 4.0: <https://creativecommons.org/licenses/by-nc-nd/4.0/>)

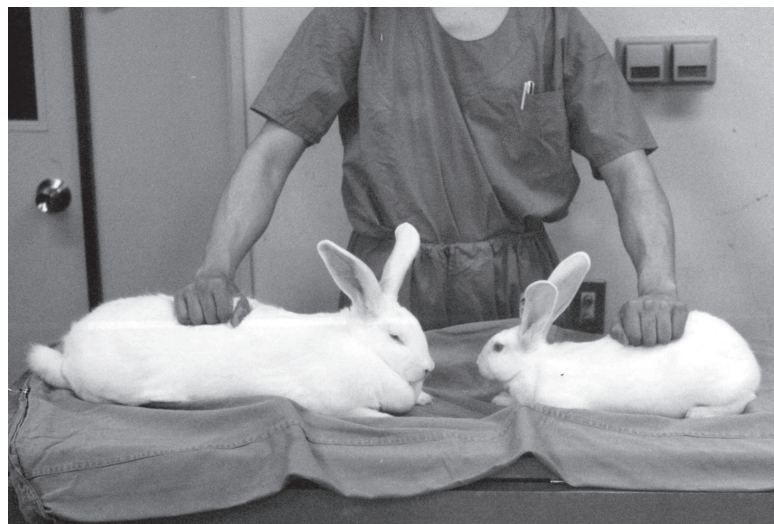

Fig. 1. Comparison of body size of JW-AKT (left) and JW (right) rabbit.

not controlled. As a result, Akita Kairyō rabbits often exhibit infectious diseases like snuffles which can interfere with the results of experiments. Thus we have established a specific pathogen free (SPF) colony of Akita Kairyō rabbits housed in microbiologically controlled facilities for animal experiments, and named JW-AKT [20].

The present study was conducted to clarify the anatomical and hematological characteristics of JW-AKT rabbit by comparing to JW and NZW rabbits for presenting its utility value in medical research.

MATERIALS AND METHODS

The protocols for animal experimentation performed in this study were approved by the Animal Committee of Akita University. The university's "Regulation for Animal Experimentation" was completely adhered to in all subsequent animal experiments.

Breeding of SPF rabbits

The JW-AKT rabbits were bred in the animal room, part of the animal facilities at Akita University. The animal room was under a barrier system and regulated in temperature ($23 \pm 2^\circ\text{C}$), humidity ($50 \pm 10\%$) and illumination (lighting, 7:00–19:00). The rabbits were housed in 653 (wide) \times 653 (depth) \times 450 (height)-mm cages (Tecniplast Japan Co., Ltd., Tokyo, Japan) and given Lab Stock R (Nihon Nosan Co., Ltd., Yokohama, Japan) and sterilized water *ad libitum*.

The colony was maintained by artificial inseminations with semen from Akita Kairyō rabbits bred out of the SPF colony. Sperm collected from male Akita Kairyō rabbits bred under conventional conditions was rinsed with Tris-Citrate-Glucose buffer (313.8 mM tris, 103.1 mM citric acid, and 33.3 mM glucose) containing kanamycin ($180 \mu\text{g/ml}$) and sperm concentration was adjusted with the same buffer to 20×10^6 sperms/ml. SPF females were inseminated with 0.5 ml of the sperm solution using a glass pipette and concurrently injected with hCG.

Body and organ size

Body weight (BW) of JW-AKT and control JW (SPF, Kbl:JW, Kitayama Labes, Ina, Japan) rabbits in each sex were monitored until 52 weeks of age (W).

The matured JW-AKT (between 21–35 months of age), JW and NZW (over 12 months of age, SPF, Kbl:NZW, Kitayama Labes) rabbits were sacrificed with overdose of anesthetics (ketamine + medetomidine). Organs including brain, heart, lung, liver, spleen, kidney, testis/ovary were dissected and weighed. Diameters of carotid artery and abdominal aorta, and femur head were measured.

Body length (distance between roots of auricle and tail) and body fat (weights of mesenterium fat and abdominal subcutaneous fat) was compared between sexes in JW-AKT rabbit.

Hematological examination

JW-AKT rabbit were fasted for 15 hr and blood samples were collected via the ear vein using a heparinized syringe. Red blood cell (RBC), white blood cell (WBC), hemoglobin (Hb), hematocrit value (Ht), and platelet (PLT) were measured by an automatic hematology analyzer (Celltac MEK-5258, Nihon Kohden, Tokyo, Japan). Total protein (TP), total cholesterol (T-cho), high density lipoprotein cholesterol (HDL-c), glucose (GLU), aspartate aminotransferase (AST), alanine aminotransferase (ALT), blood urea nitrogen (BUN), and creatinine (CRE) in plasma were measured by an automatic chemical analyzer (Fuji Dri-chem 3000V, Fujifilm Corp., Tokyo, Japan). Triglyceride (TG) and non-esterified fatty acid (NEFA) were measured using Triglyceride E-test Wako and NEFA C-test Wako respectively (Wako Pure Chemical industries, Osaka, Japan).

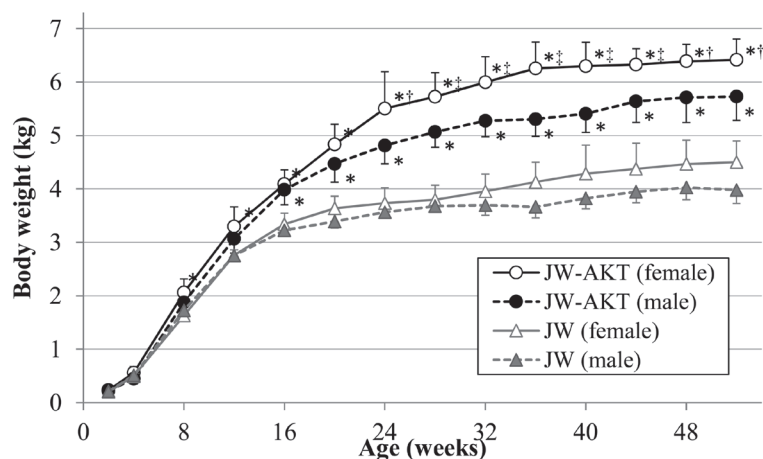


Fig. 2. Change of body weight with age in the JW-AKT and JW rabbit. ‡ $P < 0.01$; † $P < 0.05$, significantly different from male within the same strain. * $P < 0.01$, significantly different from JW in the same sex.

Statistical analysis

Significant differences ($P < 0.05$) in BW were tested at each age with a two-way factorial ANOVA using SPSS Statistics 24.0 (IBM, Armonk, NY, U.S.A.). This was followed by Bonferroni correction applied to the four groups formed by the combinations of JW-AKT and JW rabbits in each sex. The same analysis was employed to test the differences of organ weight among the three strains within the same sex. Sex differences in organ weight and hematological values were examined with Student's t -test using Excel 2010 (Microsoft).

For the statistical accuracy, 7 rabbits per each group in monitoring of body weight growth and 5 rabbit per each group were used in other experiments.

RESULTS

The BW of the rabbits increased rapidly until Week 16 (16 W) and moderately thereafter (Fig. 2). Although there was no difference in BW among the groups until 8 W, the difference between the JW-AKT and the JW rabbit became clearer with aging in both sexes (Fig. 2). Additionally, BW in females was significantly higher than in males after 24 W in the JW-AKT rabbit. At 52 W, the BW of male JW-AKT rabbit was 5.7 ± 0.4 kg, which was significantly higher than the JW rabbit (4.0 ± 0.3) kg (Fig. 2). In females, the BW of the JW-AKT rabbit was 6.4 ± 0.4 kg at 52 W, which was significantly higher than the JW rabbit (4.5 ± 0.4) kg and the male JW-AKT rabbit (Fig. 2).

Body length of JW-AKT rabbit was 51.2 ± 2.6 cm in males and 50.6 ± 3.8 cm in females, which showed no sex difference. Weight of visceral fat of female (178.8 ± 32.7 g) was significantly higher ($P < 0.01$) than that of male (77.0 ± 25.4 g) in JW-AKT rabbit. The weight of heart, lung and kidney in JW-AKT rabbit was significantly higher than in JW and NZW rabbits in both sexes (Table 1). The liver weight of JW-AKT rabbit was significantly higher than others only in female, and testis weight of male JW-AKT rabbit was significantly higher than others (Table 1).

The diameter of femur head in JW-AKT rabbit was significantly larger than others in both sexes, and that of abdominal aorta in male JW-AKT rabbit was significantly larger than in male NZW rabbit (Table 2).

The hematological examination showed a few sex differences in JW-AKT rabbit. RBC, Hb and PLT were significantly higher in male than female.

Table 1. Weight of body and organs

		BW (kg)	Brain (g)	Heart (g)	Lung (g)	Liver (g)	Spleen (g)	Kidney (right, g)	Testis/Ovary (right, g)
Male	JW-AKT	5.9 ± 0.4^a	11.1 ± 1.0	14.8 ± 3.7^a	16.3 ± 1.7^a	88.3 ± 8.8	1.4 ± 0.3	13.4 ± 1.5^a	5.3 ± 1.0^a
	JW	3.7 ± 0.2^b	10.8 ± 0.7	9.5 ± 0.7^b	10.0 ± 0.6^b	67.0 ± 14.5	1.3 ± 0.4	9.1 ± 1.0^b	2.5 ± 1.2^b
	NZW	4.2 ± 0.3^b	10.5 ± 0.3	8.4 ± 0.8^b	9.9 ± 0.7^b	67.3 ± 13.5	1.3 ± 0.5	8.1 ± 1.3^b	3.5 ± 0.4^b
Female	JW-AKT	6.4 ± 0.4^a	9.7 ± 1.0	13.3 ± 1.8^a	25.5 ± 10.9^a	91.8 ± 17.9^a	1.7 ± 0.2	12.8 ± 1.2^a	0.4 ± 0.2
	JW	4.2 ± 0.3^b *	10.4 ± 0.4	9.3 ± 0.7^b	9.8 ± 0.4^b	63.2 ± 11.1^b	1.4 ± 0.5	10.3 ± 1.7^b	0.5 ± 0.1
	NZW	4.3 ± 0.4^b	10.3 ± 0.4	7.9 ± 0.7^b	10.0 ± 0.7^b	58.9 ± 8.0^b	1.6 ± 0.1	7.4 ± 0.6^c	0.2 ± 0.1

Different superscript letters: Significant difference ($P < 0.05$) within the same sex; *Significantly different from male of the same strain ($P < 0.05$).

Table 2. Diameters of arteries and femur head

		Carotid artery (mm)	Abdominal aorta (mm)	Femur head (mm)
Male	JW-AKT	2.4 ± 0.4	3.1 ± 0.5 ^{a)}	11.2 ± 0.7 ^{a)}
	JW	2.9 ± 0.4	2.5 ± 0.3	8.7 ± 0.4 ^{b)}
	NZW	2.3 ± 0.3	2.3 ± 0.4 ^{b)}	9.0 ± 0.4 ^{b)}
Female	JW-AKT	2.5 ± 0.2	3.0 ± 0.3	10.8 ± 0.4 ^{a)}
	JW	2.6 ± 0.4	2.6 ± 0.5	8.9 ± 0.5 ^{b)}
	NZW	2.4 ± 0.4	2.7 ± 0.5	8.8 ± 0.4 ^{b)}

Different superscript letters: Significant difference ($P < 0.05$) within the same sex.

Table 3. Hematological properties of JW-AKT rabbit

	Unit	Male	Female
RBC	$\times 10^4/\mu\text{l}$	608.0 ± 45.9	519.6 ± 59.7 ^{a)}
WBC	$\times 10^2/\mu\text{l}$	43.8 ± 22.3	41.4 ± 20.9
Hb	g/dl	13.0 ± 1.1	10.7 ± 0.4 ^{b)}
Ht	%	39.0 ± 2.8	34.8 ± 3.5
MCV	fl	64.2 ± 3.0	67.1 ± 1.7
MCH	pg	21.4 ± 0.2	20.7 ± 2.0
MCHC	%	33.4 ± 1.7	30.9 ± 2.8
PLT	$\times 10^4/\mu\text{l}$	28.4 ± 4.9	19.0 ± 6.7 ^{a)}
T-cho	mg/dl	26.6 ± 4.6	33.4 ± 11.0
HDL-C	mg/dl	20.0 ± 6.2	26.4 ± 11.6
TG	mg/dl	51.5 ± 9.3	56.3 ± 25.2
NEFA	$\mu\text{Eq/l}$	590.1 ± 255.3	457.3 ± 318.3
GLU	mg/dl	145.0 ± 60.8	177.6 ± 63.3
BUN	mg/dl	23.5 ± 3.0	26.6 ± 6.6
CRE	mg/dl	1.2 ± 0.4	1.1 ± 0.2
AST	IU/l	18.2 ± 8.2	20.0 ± 10.2
ALT	IU/l	17.6 ± 11.9	15.2 ± 6.6
TP	g/dl	6.3 ± 0.2	6.4 ± 0.5

a) $P < 0.05$, b) $P < 0.01$; significantly different from male.

DISCUSSION

The present study revealed that BW, weights of heart, lung, liver (in female only), kidney and testis (in male), and the diameters of femur head and abdominal aorta were larger in JW-AKT than JW and NZW rabbits. On the other hand, the weight of brain and diameter of carotid artery was almost same among the 3 rabbit breeds. Therefore, JW-AKT rabbit is larger than general laboratory rabbits in physical constitution with same head size. In general, JW-AKT rabbit showed normal hematological characteristics (Table 3) similar to other laboratory rabbits [8, 26]. Though blood glucose level could be higher in JW-AKT than other rabbits, it is necessary to perform further examination like glucose tolerance test to diagnose glucose metabolism disorders. These would show that the origin and basic properties of JW-AKT is common to those of JW and NZW rabbits.

In comparison between sexes in JW-AKT rabbit, even though BW was rather lower in males, body length and brain weights tended to be higher in males than in females (Table 1). Additionally, body fat was significantly higher in females, and therefore what affects difference in BW is body fat, rather than the physical constitution of female JW-AKT rabbit. Though RBC, Hb and PLT were significantly higher in males, no critical sex difference was found in hematological parameters in JW-AKT rabbit.

Rabbits have been employed as an animal model especially in experiments accompanying surgical operations due to their physiological characteristics and moderate body size compared with small laboratory rodents [10]. Recently, the perspective of animal welfare has required an animal model to replace dogs. Although (mini) pigs are a prime candidate for an animal model to replace dogs in surgical experiments [27], their care and microbiological control is difficult. Thus, JW-AKT rabbits could serve as an alternative candidate for an animal model to replace dogs because of their body size and easiness in handle. The larger rabbit (including Flemish giant) models have been employed for medical research with surgical treatments especially in vascular [2, 9, 17] and orthopedic [3–5, 12, 13, 23] experiments. Additionally, large body size is advantageous in collection of a large amount of biological specimen. Rabbits have been frequently used for yielding specific anti-serum. The larger rabbit provide larger amount of serum since it is known that blood volume is proportional to BW, and concurrently, required number of animals will be reduced. Not like colored Flemish giant rabbit, JW-AKT is albino, and thus can be a prime candidate in laboratory use [15, 16, 22].

JW-AKT rabbit bred in SPF condition has the advantage over conventional large rabbit models in health control. Rabbits are known to show severe inbreeding depression [1, 24], and thus a considerable number of animals is needed to maintain a rabbit colony. Since breeding a large number of rabbits under SPF conditions requires considerable space and cost, we designed the livestock resource such that a SPF colony could be maintained within a minimum number of rabbits. It is advantageous that artificial insemination can be used in rabbits, and the sperm from livestock rabbits did not serve as an infectious source of the specific pathogen when rinsed with Tris-Citrate-Glucose buffer containing antibiotics [14].

In conclusion, the novel albino rabbit breed JW-AKT rabbits are more than 1.5 times larger than general laboratory rabbits with basic properties common to JW and NZW rabbits so can be a valuable animal model.

ACKNOWLEDGMENT. Authors wish to express their sincere thanks to Dr. Shuji Kitajima (Saga University) for his critical advice in the completion of the present study.

REFERENCES

1. Casellas, J., Vidal-Roqueta, D., Flores, E., Casellas-Vidal, D., Llach-Vila, M., Salgas-Fina, R. and Casellas-Molas, P. 2011. Epistasis for founder-specific inbreeding depression in rabbits. *J. Hered.* **102**: 157–164. [Medline] [CrossRef]
2. Centeno, R. S., Hackney, D. B. and Rothrock, J. R. 1985. Streptokinase clot lysis in acute occlusions of the cranial circulation: study in rabbits. *AJNR Am. J. Neuroradiol.* **6**: 589–594. [Medline]
3. Ewers, B. J. and Haut, R. C. 2000. Polysulphated glycosaminoglycan treatments can mitigate decreases in stiffness of articular cartilage in a traumatized animal joint. *J. Orthop. Res.* **18**: 756–761. [Medline] [CrossRef]
4. Fischenich, K. M., Button, K. D., DeCamp, C., Haut, R. C. and Donahue, T. L. 2017. Comparison of two models of post-traumatic osteoarthritis; temporal degradation of articular cartilage and menisci. *J. Orthop. Res.* **35**: 486–495. [Medline] [CrossRef]
5. Fischenich, K. M., Pauly, H. M., Button, K. D., Fajardo, R. S., DeCamp, C. E., Haut, R. C. and Haut Donahue, T. L. 2017. A study of acute and chronic tissue changes in surgical and traumatically-induced experimental models of knee joint injury using magnetic resonance imaging and micro-computed tomography. *Osteoarthritis Cartilage* **25**: 561–569. [Medline] [CrossRef]
6. Flux, J. E. C. 1994. World distribution. pp. 8–21. In: *The European Rabbit: The History and Biology of a Successful Colonizer* (Thompson, H. V. and King, C. M. eds.), Oxford University Press, Oxford.
7. Fujimoto, G. and Shindo, K. 1996. [Oogatausagi–Akita kairyoushu]. *Animal-husbandry* **50**: 703–708 (in Japanese).
8. Haneda, R., Mizoguchi, Y., Matsuoka, T., Mizuguchi, H., Endoh, T., Fukuda, K. and Asano, Y. 2010. Changes in blood parameters in pregnant Japanese White rabbits. *J. Toxicol. Sci.* **35**: 773–778. [Medline] [CrossRef]
9. Hong, M. K., Vossoughi, J., Haudenschild, C. C., Wong, S. C., Zuckerman, B. D. and Leon, M. B. 1995. Vascular effects of diet-induced hypercalcemia after balloon artery injury in giant Flemish rabbits. *Am. Heart J.* **130**: 758–764. [Medline] [CrossRef]
10. Houdebine, L. M. and Fan, J. 2009. Introduction. pp. 1–2. In: *Rabbit Biotechnology–Rabbit Genomics, Transgenesis, Cloning and Models* (Houdebine, L. M. and Fan, J. eds.), Springer, New York.
11. Inayoshi, D. 1952. [Nihon no Kato ni Tsuite]. *Bull. Exp. Anim.* **1**: 34–35 (in Japanese).
12. Kamps, B. S., Linder, L. H., DeCamp, C. E. and Haut, R. C. 1994. The influence of immobilization versus exercise on scar formation in the rabbit patellar tendon after excision of the central third. *Am. J. Sports Med.* **22**: 803–811. [Medline] [CrossRef]
13. Killian, M. L., Isaac, D. I., Haut, R. C., Déjardin, L. M., Leetun, D. and Donahue, T. L. 2010. Traumatic anterior cruciate ligament tear and its implications on meniscal degradation: a preliminary novel lapine osteoarthritis model. *J. Surg. Res.* **164**: 234–241. [Medline] [CrossRef]
14. Kitajima, S. 2009. Improvement of rabbit production. pp. 3–12. In: *Rabbit Biotechnology–Rabbit Genomics, Transgenesis, Cloning and Models* (Houdebine, L. M. and Fan, J. eds.), Springer, New York.
15. Kuroda, T. 1995. [Bone formation and mechanical properties of the cancellous bone defect site filled with hydroxyapatite granules]. *Nippon Seikeigeka Gakkai Zasshi* **69**: 1037–1049 (in Japanese with English abstract). [Medline]
16. Kuroda, T. and Sato, K. 1995. Mechanical properties of hydroxyapatite granules implanted in the cancellous bone defect in rabbits. *Jpn. J. Clin. Biomech.* **16**: 479–482 (in Japanese with English abstract).
17. LeVeen, R. F., Wolf, G. L. and Villanueva, T. G. 1982. New rabbit atherosclerosis model for the investigation of transluminal angioplasty. *Invest. Radiol.* **17**: 470–475. [Medline] [CrossRef]
18. Lidfors, L. and Edström, T. 2010. The laboratory rabbit. pp. 399–417. In: *The UFAW Handbook on the Care and Management of Laboratory and Other Research Animals*, 8th ed. (Hubrecht, R. and Kirkwood, J. eds.), Blackwell Publishing, Oxford.
19. Matsuda, Y. 2004. Recent trends in the number of laboratory animals used in Japan. *Altern. Lab. Anim.* **32** Suppl 1A: 299–301. [Medline]
20. Matsuda, Y., Shibata, Y., Basaki, K., Fukuda, Y., Yano, M., Obata, T., Seki, S. and Nishijima, K. 2018. Establishment of a specific pathogen-free colony of albino large rabbit. *Kyushu J. Exp. Anim.* **34**: 23–27 [Article in Japanese with English abstract].
21. Naff, K. A. and Craig, S. 2012. The domestic rabbit, *Oryctolagus cuniculus*: origins and history. pp. 157–163. In: *The Laboratory Rabbit, Guinea Pig, Hamster, and Other Rodents* (Suckow, M. A., Stevens, K. A. and Wilson, R.P. eds.), Academic Press, London.
22. Nitta, N., Sonoda, A., Nitta-Seko, A., Ohta, S., Tsuchiya, K., Tanaka, T., Kanasaki, S., Mukaisho, K., Takahashi, M. and Murata, K. 2009. Basic investigation of vascular interventional radiology (IR) using large rabbits. *Exp. Anim.* **58**: 557–561. [Medline] [CrossRef]
23. Ogay, V., Karzhauov, M., Mukhambetova, A., Raimagambetov, E. and Batpenov, N. 2014. Intra-articular injection of synovium-derived mesenchymal stem cells and hyaluronic acid promote regeneration of massive cartilage defects in rabbits. *Cent. Asian J. Glob. Health* **2** Suppl: 97. [Medline]
24. Ragab, M., Sánchez, J. P. and Baselga, M. 2015. Effective population size and inbreeding depression on litter size in rabbits. A case study. *J. Anim. Breed. Genet.* **132**: 68–73. [Medline] [CrossRef]
25. Shiomi, M. and Ito, T. 2009. The Watanabe heritable hyperlipidemic (WHHL) rabbit, its characteristics and history of development: a tribute to the late Dr. Yoshio Watanabe. *Atherosclerosis* **207**: 1–7. [Medline] [CrossRef]
26. Suckow, M. A., Schroeder, V. and Douglas, F. A., editors. 2010. *The Laboratory Rabbit*, 2nd ed. CRC Press, Boca Raton.
27. Swindle, M. M., Makin, A., Herron, A. J., Clubb, F. J. Jr. and Frazier, K. S. 2012. Swine as models in biomedical research and toxicology testing. *Vet. Pathol.* **49**: 344–356. [Medline] [CrossRef]
28. Yanni, A. E. 2004. The laboratory rabbit: an animal model of atherosclerosis research. *Lab. Anim.* **38**: 246–256. [Medline] [CrossRef]