

Eosinophilia in a patient with cyclical vomiting: a case report

Billy H Copeland*, Omolola O Aramide, Salim A Wehbe, S
Matthew Fitzgerald and Guha Krishnaswamy

Address: P.O. Box 70622, Department of Internal Medicine, Division of Allergy and Immunology, East Tennessee State University, Johnson City, TN 37614, USA

Email: Billy H Copeland* - bhcopelandII@aol.com; Omolola O Aramide - aramidelola@aol.com; Salim A Wehbe - selimw@hotmail.com; S Matthew Fitzgerald - fitzgers@etsu.edu; Guha Krishnaswamy - krishnas@etsu.edu

* Corresponding author

Published: 14 May 2004

Received: 19 November 2003

Clinical and Molecular Allergy 2004, **2**:7

Accepted: 14 May 2004

This article is available from: <http://www.clinicalmolecularallergy.com/content/2/1/7>

© 2004 Copeland et al; licensee BioMed Central Ltd. This is an Open Access article: verbatim copying and redistribution of this article are permitted in all media for any purpose, provided this notice is preserved along with the article's original URL.

Abstract

Background: Eosinophilic gastritis is related to eosinophilic gastroenteritis, varying only in regards to the extent of disease and small bowel involvement. Common symptoms reported are similar to our patient's including: abdominal pain, epigastric pain, anorexia, bloating, weight loss, diarrhea, ankle edema, dysphagia, melaena and postprandial nausea and vomiting. Microscopic features of eosinophilic infiltration usually occur in the lamina propria or submucosa with perivascular aggregates. The disease is likely mediated by eosinophils activated by various cytokines and chemokines. Therapy centers around the use of immunosuppressive agents and dietary therapy if food allergy is a factor.

Case presentation: The patient is a 31 year old Caucasian female with a past medical history significant for ulcerative colitis. She presented with recurrent bouts of vomiting, abdominal pain and chest discomfort of 11 months duration. The bouts of vomiting had been reoccurring every 7–10 days, with each episode lasting for 1–3 days. This was associated with extreme weakness and cachexia. Gastric biopsies revealed intense eosinophilic infiltration. The patient responded to glucocorticoids and azathioprine. The differential diagnosis and molecular pathogenesis of eosinophilic gastritis as well as the molecular effects of glucocorticoids in eosinophilic disorders are discussed.

Conclusions: The patient responded to a combination of glucocorticosteroids and azathioprine with decreased eosinophilia and symptoms. It is likely that eosinophil-active cytokines such as interleukin-3 (IL-3), granulocyte macrophage colony stimulating factor (GM-CSF) and IL-5 play pivotal roles in this disease. Chemokines such as eotaxin may be involved in eosinophil recruitment. These mediators are downregulated or inhibited by the use of immunosuppressive medications.

Background

Eosinophilic gastritis is a serious disease manifesting with eosinophilia of the blood and stomach with vomiting, diarrhea, melena, weight loss and/or cachexia. Although the cause is mostly unknown, food hypersensitivity has been blamed in several cases. The disease causes edema

and thickening of the bowel which may cause stenosis of the lumen in some cases. Ascites and local lymphadenopathy may be present. Microscopic examination reveals lamina propria and submucosal infiltration of eosinophils. Treatment usually consist of glucocorticoid therapy although leukotriene modifier drugs are showing

effectiveness at preventing eosinophil chemotaxis. This report describes a patient with eosinophilic gastritis and discusses the disease and the differential diagnosis along with treatment options.

Case presentation

The patient is a 31 year old Caucasian female with a past medical history significant for ulcerative colitis. She presented with recurrent bouts of vomiting, abdominal pain and chest discomfort. For the past 11 months, bouts of vomiting had been reoccurring every 7–10 days, with each episode lasting 1 to 3 days. This was associated with extreme weakness and cachexia. The patient had kept a food diary and was unable to associate the symptoms with any particular food. The episodes were not related to activity and occurred both at work and home. At the time of presentation the patient reported considerable social stress.

The patient also had a history of ulcerative colitis, which was originally diagnosed 3 years prior to presentation. She had previously been prescribed 6-mercaptopurine (50 mg daily) and at time of evaluation was using mesalamine (400 mg thrice daily). She however continued to experience diarrhea with occasional blood streaking. Since diagnosis there had been a 6.8 kg (15 lbs) weight loss, night sweats, swelling of her hands and feet, hyperventilation, generalized weakness, and chest discomfort. In the months leading up to presentation she was treated with Doxycycline (100 mg po BID) for facial acne. The doxycycline was soon discontinued due to worsening diarrhea with no improvement of her symptoms. Though the patient was under some stress, it was felt that this did not contribute to her symptoms. She had no history of drug or alcohol abuse and hence a toxicology screen was not performed.

On examination, the patient had a height of 165 cm (5' 6"), a weight of 52.7 kg (116 lbs), and a blood pressure of 110/70 mm Hg. She was a thin built young woman. The head and neck exam was essentially unremarkable with a fundoscopic exam that showed no evidence of retinitis. Tympanic membranes were clear bilaterally, turbinates

non-swollen without polyps or discharge. Oral pharynx was clear. Lymphadenopathy or thyroidmegaly could not be appreciated. Lung examination was clear to auscultation. Abdomen was soft with positive bowel sounds, no hepatosplenomegaly, masses or tenderness noted. Extremities did not display clubbing, cyanosis, edema, or joint deformity or tenderness. No eruption was present and neurological exam was grossly intact. The patient gave written consent for publication of this report. Her stool hemocult test was negative for blood.

Laboratory evaluation

At the time of presentation a complete blood count showed hemoglobin of 12.6 g/dl, hematocrit of 37.5%, and WBC of 8,300 cells/mm³ with 16% eosinophils on peripheral smear. Electrolytes and liver and renal functions were all normal. With further investigation diminished levels of immunoglobulin G, total protein and albumin were noted. The total IgG was 341 mg/dl (normal 613–1295 mg/dl), total protein was 5.0 g/dl (normal 6–8 g/dl) and albumin 3.1 g/dl (normal 3.2–5.0 g/dl). Pneumococcal vaccination responses were normal suggesting that the IgG deficiency did not result in a functional antibody defect as would be seen in common variable immune deficiency. The serum C3, C4, CH-50, and C-1 esterase were within normal limits. Serum amylase and lipase levels were in the normal ranges. Urine analysis showed no proteinuria or active sediment. The following tests were either negative or normal: ESR, ANA, anti-Ro, anti-La, SCL-70, rheumatoid factor, p-ANCA, and anti-myeloperoxidase antibodies. Stool studies and serum serology are listed in Table 1. Allergy skin testing was negative for a panel of commonly eaten foods. Given the gastrointestinal symptoms, an upper GI series was also carried out. It showed evidence of a small hiatal hernia and reflux. Echocardiogram showed no evidence of systolic dysfunction or restrictive cardiomyopathy, a feature of some hypereosinophilic syndromes. Pulmonary function tests displayed a minimal obstructive lung defect with normal diffusion capacity. Computerized tomography of the head (carried out because of the vomiting) was negative for space occupying lesions.

Table 1: Patient laboratory results

TEST	RESULT
<i>Strongyloides</i> antibody	negative
<i>Toxocara</i> antibody	negative
<i>Trichinella</i> antibody	negative
<i>Giardia</i> antibody	negative
HIV test	negative
Pneumococcal vaccine response	normal
Stool ova and parasites	negative

Question 1

Based on the initial history, physical examination and laboratory results, what would be the differential diagnosis in this 31 year old white female with cyclical vomiting, weight loss, and peripheral eosinophilia?

- a. Parasitic infection
- b. Food allergy and atopy
- c. Connective tissue disease with vasculitis
- d. Idiopathic hypereosinophilic syndrome
- e. Adrenal insufficiency
- f. Eosinophilic gastritis

Differential diagnosis**Parasitic infestation**

Infection with helminthic parasites elicits eosinophilia by stimulation of Th2 cytokines, especially IL-5. Common intestinal parasites include *Strongyloides stercoralis*, hookworm, and *Toxocara* species [1-5]. Of these parasites, strongyloidiasis is seen endemically in East Tennessee [2]. *S. stercoralis* adult worms reproduce parthogenetically in the gastrointestinal tract. Rhabditiform larvae may develop into infective filarial forms in the gastrointestinal tract and also after passage in the feces. Strongyloides can persist for decades without causing major symptoms. In many cases, larval and worm penetration of the small bowel can cause an enteritis associated with eosinophilic and mononuclear infiltration of the mucosa. Pathologically, edema, ulceration, and hemorrhage can be seen in these patients. Clinically, abdominal bloating, epigastric pain, and diarrhea can be presenting features in these individuals. Hematochezia and/or melena occurs in the minority of these patients (<20%). Filariform larvae can penetrate the gut and disseminate, especially in patients who are immunosuppressed or treated with glucocorticoids. This condition, referred to as strongyloides hyperinfection, is heralded by dyspnea, cough, wheezing, and hemoptysis [2]. Fever, tachypnea, hypoxemia, and gram negative meningitis may develop in the sicker patients. Serology can be used to detect strongyloides if fecal or sputum examination does not demonstrate the parasite [2]. In our patient, the absence of parasites in stool and the lack of serological evidence of strongyloidiasis mitigated against this diagnosis.

Food allergy and atopy

Food allergic reactions can present with eosinophilia, vomiting, and diarrhea [6-9]. Usually, when severe, food allergy is accompanied by urticaria, angioedema, and/or symptoms of systemic anaphylaxis. Food allergy must be

differentiated from food intolerance (such as lactose intolerance) where bloating and diarrhea may occur but no demonstrable IgE antibody to food protein is discovered. In many cases, foods can induce allergic gastroenteritis with findings identical to that seen in our patient [10]. Some infants may also demonstrate hypersensitivity to food protein resulting in an enterocolitis [11,12]. Food allergy may occur in as many as 6% of young children and up to 2% of the adult population. Common foods known to elicit reactions in such individuals include milk, wheat, egg, soy, fish, shrimp, and nuts [9]. The diagnosis is established either by skin or by RAST testing [7,9]. Confirmation sometimes requires a double blinded, placebo controlled challenge. In our patient, the normal IgE levels and absence of significant sensitivity to foods on skin testing mitigated against the possibility of food allergy. There have been cases of allergic gastroenteritis where elimination of suspected foods in the patient leads to disease amelioration. In our patient, a food elimination diet (that she had pursued herself) did not alter her clinical course. The patient refused to attempt an elemental amino acid diet due to presumed intolerance and costs associated with these preparations, although this was discussed with her as a therapeutic option.

Eosinophilic vasculitides (Churg-Strauss syndrome)

Churg-Strauss syndrome (CSS) is a small and medium sized artery inflammation [2,13]. It frequently involves the skin, peripheral nerves and lungs with associated peripheral eosinophilia. The syndrome is characterized by a triad of 1) asthma, 2) hypereosinophilia, and 3) necrotizing vasculitis. There may be three phases of the disease process. It is possible to have a prodromal period which may last for years. Normally it consists of allergic rhinitis, polyposis and asthma. The second phase includes peripheral blood and tissue eosinophilia with multisystem involvement. The third phase is systemic vasculitis with neuropathy, cardiac disease, and renal disease manifesting. All three phases may present simultaneously. It is important to note that weight loss and fever may herald the onset of systemic disease [13]. In some cases, CSS has been associated with the use of leukotriene modifier drugs but a causal relationship has not been proven. Chest radiograph is abnormal in approximately half the cases. Changes range from patchy shifting infiltrates (Loffler's syndrome) to massive bilateral nodular infiltrates without cavitations and diffuse interstitial lung disease. Cutaneous lesions occur over pressure areas, petechiae, purpura, and peripheral neuropathy is found in the majority of patients. Cardiac involvement may result in congestive heart failure. Gastrointestinal involvement may sometimes present as bloody diarrhea or simulating ulcerative colitis and is caused by bowel ischemia. The patients with CSS often have pulmonary infiltration, neuropathy,

hematuria, and elevated ESR with a restrictive cardiomyopathy, none of which were features seen in our patient.

Idiopathic hypereosinophilic syndrome

IHES is an idiopathic condition which belongs to the myeloproliferative disorders group and is associated with marked peripheral eosinophilia and involvement of multiple organs such as the heart, gastrointestinal tract, lungs, brain, and kidneys [14,15]. There are no specific tests diagnostic of hypereosinophilic syndrome and it remains a clinical diagnosis and essentially a diagnosis of exclusion. A definition of the syndrome has been proposed with 3 defining features:

- 1) blood eosinophilia >1500 eosinophils/ mm^3 present for more than 6 months
- 2) no other apparent etiologies for eosinophilia such as parasitic infection, malignancy, vasculitis, drug hypersensitivity or atopic disease
- 3) signs and symptoms of end organ dysfunction including cardiac disease, neuropathy, and hepatic dysfunction

Hypereosinophilic syndrome occurs predominantly in males between the ages of 20–50. Onset is usually insidious and eosinophilia is detected incidentally [14-16]. Hematological, cardiac, cutaneous, neurological, pulmonary, hepatic, or gastrointestinal symptoms may predominate presentation. Myalgia, diarrhea, psychiatric disturbances, and ocular disease have also been described. Elevated serum IgE, elevated levels of tumor necrosis factor (TNF- α) and interleukin-5 (IL-5) [17], polyclonal hyperglobulinemia, and good response to steroids are additional diagnostic features of this disease. Our patient had no evidence of multiple organ involvement and no evidence of cardiac, hepatic or renal disease excluding this diagnosis.

Adrenal insufficiency

The loss of endogenous glucocorticoids, regardless of the cause, results in eosinophilia. The etiology could include a primary failure due to autoimmune adrenalitis, or secondary failure arising from many conditions such as infection, neoplasia, and granulomatous/infiltrative disorders [18]. Though the disease itself is rare, its presentation may be cryptic and the diagnosis missed. It is also important to realize that patients who have been treated with exogenous courses of glucocorticoids for various inflammatory conditions may be more prone to developing adrenal failure, especially in stressful conditions such as surgery. Laboratory evaluation is likely to demonstrate hyperkalemia and hypoglycemia. Clinically, weight loss, anorexia, and vomiting with eosinophilia may be seen [18]. It has been suggested that the presence of relative eosinophilia in crit-

ically ill patients is associated with clinical signs of relative adrenal insufficiency [19,20]. Our patient had no obvious evidence of adrenal insufficiency and the tests for her cortisol axis were within normal limits, excluding this diagnosis.

Eosinophilic gastritis

This is a pathological diagnosis characterized by peripheral eosinophilia, eosinophilic infiltration of the bowel wall, and gastrointestinal symptoms. It affects all age groups, predominately in the second to sixth decades of life. The disease affects both sexes with a slightly increased prevalence in males. The cause is largely unknown. An allergic or immunological reaction to food antigen seems likely in 20–50% of cases. In the case of eosinophilic gastritis, there is mainly invasion of the gastric mucosa while in eosinophilic gastroenteritis, both the stomach and small intestine may be involved. These disorders are further reviewed in the sections below.

Question 2

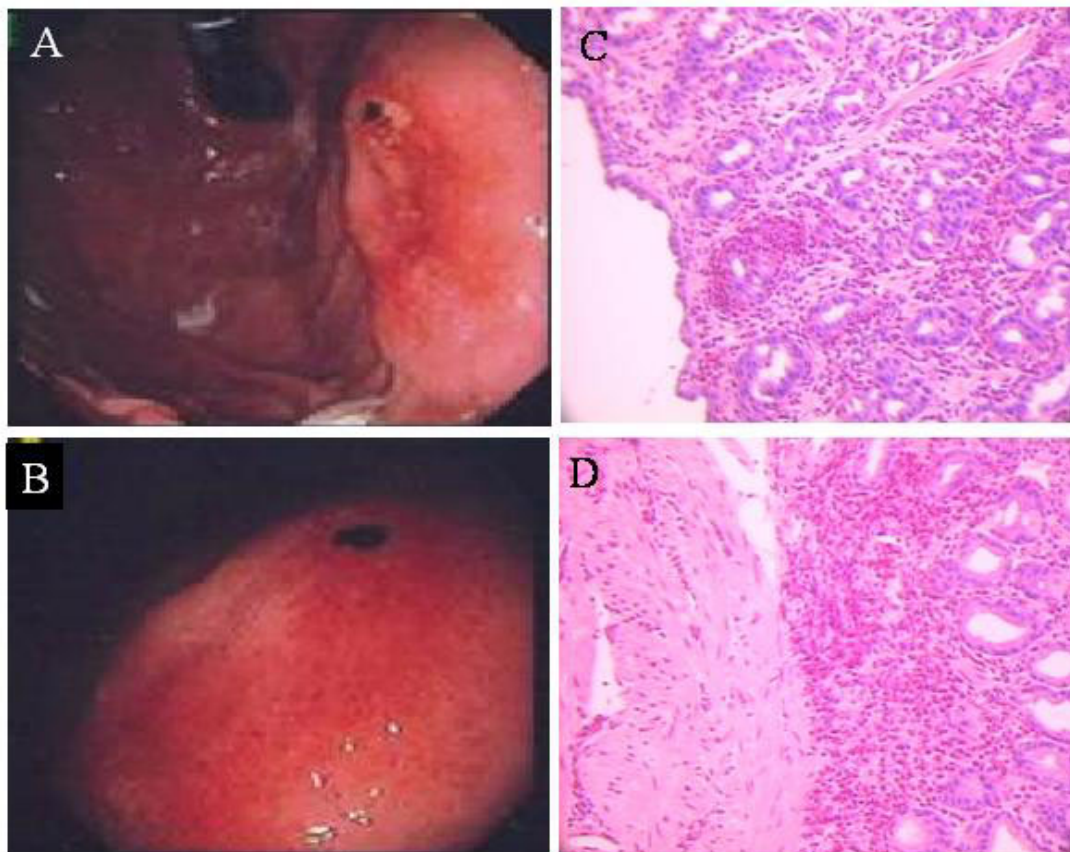
What diagnostic test will you perform in this patient to confirm the diagnosis?

- a. blood culture
- b. gastric biopsy
- c. stool alpha 1 antitrypsin
- d. ESR
- e. Bone marrow biopsy

The patient underwent esophagogastroduodenoscopy (EGD) and had multiple gastric biopsies taken by a consultant gastroenterologist. Images revealed multiple erosions in the gastric and duodenal mucosa and Barrett's esophagitis (Figure 1A and 1B). Gastric biopsy showed eosinophilic infiltration of the mucosa in clusters, a diagnostic feature of eosinophilic gastritis (Figure 1C and 1D). Duodenal and ileal biopsies demonstrated no eosinophilic infiltration. Viral inclusions were absent on biopsy tissue and no evidence of celiac disease was present. Follow up colonoscopy revealed some colitis involving the rectosigmoid colon, with neutrophilic infiltration but no crypt abscesses. Cecal, right colon and ileal biopsies were normal and these findings were improved from prior studies.

Diagnosis: Eosinophilic gastritis with protein losing enteropathy

The diagnosis of eosinophilic gastritis was most compatible with the presentation of our patient. Her history of nausea and vomiting associated with weight loss and lower extremity edema are recognized features of the

**Figure 1**

Esophagogastroduodenoscopy showing gastric erosion (A) and esophagitis (B). Panels C and D show eosinophil infiltration of gastric biopsy samples.

disease. Although cyclical vomiting has not been described as a typical feature of eosinophilic gastritis, this was the presenting feature in our patient. Initially some of these symptoms could have been contributed to her ulcerative colitis which can also be associated with eosinophilic infiltration but not to the degree and severity seen in this patient. The peripheral edema was most likely secondary to the protein losing enteropathy, hypoalbuminemia, and cachexia (Figure 2).

Eosinophilic gastritis is a disease that affects both sexes with a slightly increased prevalence in males. Eosinophilic gastritis is a rare disease with less than 300 cases previously reported. The disease has been predominantly described in Caucasians [21,22] with some reported cases

in Asians [23,24]. Eosinophilic gastritis is related to eosinophilic gastroenteritis, varying only in regards to the extent of disease and small bowel involvement. Common symptoms reported are similar to our patient's and include: abdominal pain, epigastric pain, anorexia, bloating, weight loss, diarrhea, ankle edema, dysphagia, melena, and postprandial nausea and vomiting. Given a somewhat non-specific presentation, a high index of suspicion must be maintained once peripheral eosinophilia is noted. If a patient has concomitant ascites the ascitic fluid will have a high eosinophilia count. In some cases, presentations have been diverse and cryptic such as patients who present with a solitary gastric ulcer or pyloric outlet obstruction and those who present like gastric malignancy [23-26]. In some cases, parasitic diseases such

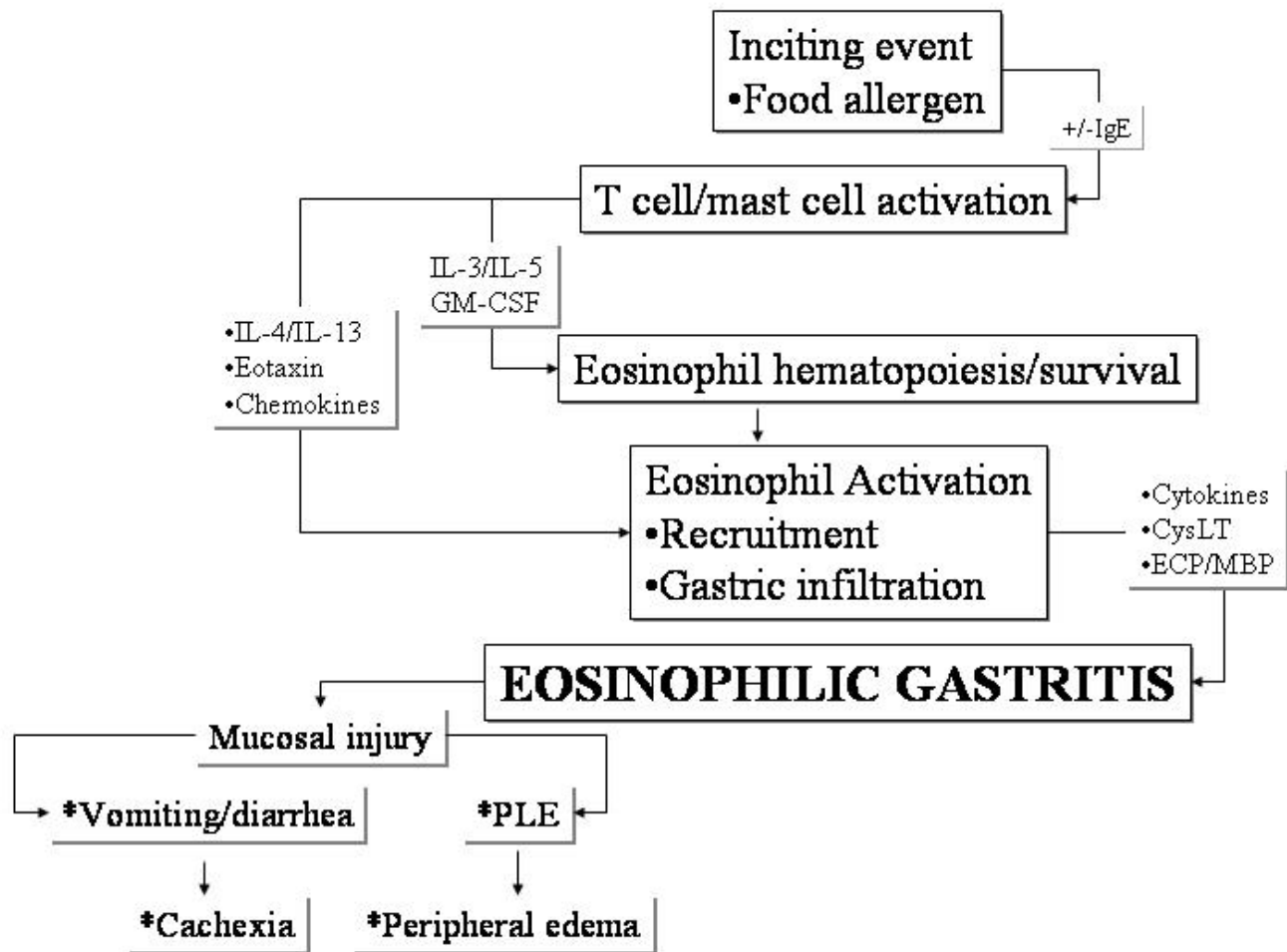


Figure 2

Pathology of eosinophilic gastritis. In the presence of an inciting event, inflammatory cells like T-cells and mast cells are activated to produce a host of eosinophilic cytokines that regulate eosinophil biology, activation, recruitment, and survival. Once in the gastric mucosa, eosinophils can orchestrate tissue damage by releasing toxic proteins like eosinophil cationic protein, major basic protein, eosinophil peroxidase, and eosinophil derived neurotoxin. With mucosal injury, vomiting, diarrhea, cachexia, and peripheral edema ensue.

as anisakiasis have mimicked eosinophilic gastritis [27]. Stefanini et al. reported on the paraneoplastic association of eosinophilic gastroenteritis with a large cell carcinoma of the lung [28]. Some cases have been linked to the use of medications such as gemfibrozil [29]. In many cases, an etiology is not readily discernable.

Three types of eosinophilic gastroenteritis have been proposed linking the clinical manifestations and depth of the disease process [30].

Type I – predominantly mucosal and characterized by fecal blood loss, iron deficiency anemia, protein losing

enteropathy, and malabsorption. Patients normally present with colicky abdominal pain, nausea, vomiting, diarrhea, and weight loss. A history of atopy is common in up to half of patients.

Type II – a muscle layer disease with obstructive symptoms due to thickening and rigidity of the GI tract. Eosinophilic involvement in the majority of cases is localized to the stomach but can involve the small bowel. The history of atopy is much less common.

Type III – shows predominantly subserosal disease with eosinophilic ascites. This is the least common cause of the

Table 2: Cytokines regulating eosinophilia

Cytokine	Family	Effect on Eosinophils	Other Relevant Functions
TNF-α [59,60]	Monokine	CAM expression, recruitment	Vascular permeability increase, eosinophil degranulation
IL-1β [59,60]	Monokine	CAM expression, eosinophil recruitment	Eosinophil activation, eosinophil degranulation
IL-3 [59]	HP	survival, differentiation	Multipotential HP
IL-4 [59,60]	Th2	VCAM expression on EC	IgE synthesis
IL-5 [59]	Th2	Hematopoiesis, activation, survival, mediator	IgA synthesis
IL-13 [59,60]	Th2	VCAM expression on EC	IgE synthesis, Mucus production
GM-CSF [59,60]	Th1/2	Activation	MO activation, hematopoiesis
SCF [59]	HP	Adhesion	Mast cell growth
Eotaxins [59]	Chemokine	Chemoattractant	Multipotential HP
MCPs [59,60]	Chemokine	Chemoattractant	MO chemotaxis
RANTES [59,60]	Chemokine	Chemoattractant	Histamine release from basophils

CAM, Cell Adhesion Molecule; EC, endothelial cells; CSF, Colony Stimulating Factor; Th2, type 2 T helper cell; HP, hematopoietin; APR, acute phase response, MO, Monocyte-macrophage lineage cells; VCAM-vascular cell adhesion molecule; MCP-monocyte chemoattractant protein-I

disease. The entire GI wall is involved. The ascitic fluid is noted to have a high eosinophil count. A history of allergic reactions is common, and more than one site may be involved with a mixed clinical manifestation [16,30]

Pathologically the macroscopic portion of the bowel is thickened and swollen with varying degrees of induration, edema, hyperemia and nodularity. These changes can lead to obstruction of the lumen. Regional lymphadenopathy and ascites may be present. Microscopic features of eosinophilic infiltration usually occur in the lamina propria or submucosa with a tendency to see perivascular aggregation of eosinophils as seen in our patient [16,30].

Pathogenesis and role of cytokines in eosinophilic gastritis

Figure 2 demonstrates presumed pathways that could lead to the development of eosinophilic gastritis. Inciting events such as food allergens can trigger T cell and mast cell activation, and in the case of allergen, immunoglobulin E (IgE) is involved in mast cell degranulation. This leads to the elaboration of hematopoietic cytokines such as IL-5 and pluripotential cytokines such as IL-3 and GM-CSF that modulate bone marrow production of eosinophils. Eosinophilia in the blood stream is followed by eosinophil recruitment into tissue involving endothelial cell adhesion molecules and transendothelial migration of the eosinophil into tissue. Cytokines such as IL-4 and IL-13 as well as IL-1 beta and TNF- α are involved in induction of cell adhesion molecules leading to selective eosinophil recruitment. IL-4 can induce vascular cell adhesion molecule (VCAM)-1 on endothelial surfaces while IL-1 and TNF- α can induce intercellular adhesion molecule (ICAM)-1 expression. These bind corresponding ligands VLA-4 and LFA-1 respectively on eosinophils that leads to adhesion and transendothelial migration. Tissue level activation and survival of eosinophils are regulated by cytokines such as IL-5 and GM-CSF, some expressed by

the eosinophil itself in an autocrine manner [31,32]. Recruitment of eosinophils to tissue and their accumulation there could be regulated by eotaxin in association with IL-5 [33-36]. Eotaxin mediates some of its biological effects by binding to the receptor CCR3 on the eosinophil. Eosinophil infiltration is accompanied by degranulation and the release of a plethora of mediators, including cytokines, chemokines, major basic protein, eosinophilic cationic protein and lipid mediators, further accentuating the damage to gastric tissue [37]. Desreumaux and coworkers detected IL-3, IL-5 and GM-CSF in the duodenal and colonic tissue in 90% of patients with eosinophilic gastroenteritis [38]. Investigators have demonstrated some of these cytokines in vivo in humans affected by eosinophilic gastritis. Jaffe JS et al. showed enhanced expression of IL-4, IL-5, and interferon gamma in the peripheral T cells of patients with allergic eosinophilic gastroenteritis [39]. The importance of eotaxin in eosinophilic gastroenteritis was shown by Hogan et al [40]. These investigators used an animal model of food allergen-induced eosinophilic gastroenteritis and demonstrated that in the absence of eotaxin, eosinophil accumulation in the gut was ablated in spite of eosinophilia in the peripheral blood. Thus critical roles have been assigned to IL-5, GM-CSF, and eotaxin in eosinophil accumulation in eosinophilic gastroenteritis. A list of proinflammatory cytokines that mediate eosinophil migration, activation, and survival as related to eosinophilia are listed in Table 2.

Management of eosinophilic gastritis

There have been no prospective, randomized clinical trials reported in the current body of literature. This has led to empiric treatment, modified to the severity of the disease. The possible strategies for treatment are summarized in Table 3. Treatment with an elimination diet based on the results of skin prick and RAST testing can be done. In

Table 3: Treatment strategies for eosinophilic gastritis

Strategy	Intervention	Comments
Diet	elimination, food avoidance, elemental amino acid diet, total parenteral alimentation	allergic patient allergic patient poor tolerance and cost only in severe patient
Antihelminthics	mebendazole, others	empiric trial, endemic areas
Mast cell stabilizer	cromoglycate sodium	allergic patient, anecdotal cases, administer QID, therapeutic trial
Glucocorticoids	prednisone or equivalent	lowest dose, taper, alternate day therapy, many adverse effects
Montelukast	tablet given once/day	leukotriene blocker, only anecdotal evidence
Ketotifen	available in Canada	investigational
Azathioprine	immunosuppressive	bone marrow suppression
Others	cyclophosphamide, hydroxyurea, cyclosporine A	investigational investigational investigational
Biologicals	antibody to IL-5, antibody to CCR3, antibody to IgE	investigational investigational investigational (Food allergy)
Antibiotics	ciprofloxacin, metronidazole	for malabsorption bacterial overgrowth

severe cases, an elemental amino acid diet may need to be instituted [41,42]. However, a causative agent is frequently not evident.

Steroids have been successfully used in patients who fail elimination diet. Dosage is normally 20–40 mg of prednisone daily. Improvement usually occurs within two weeks of beginning therapy and the dose of steroids need to be rapidly tapered after remission. Relapses are common and some patients require continuous low dose steroids to control symptoms. In such cases, especially those who do not tolerate the complications of steroids, alternative strategies, such as in our patient, may be attempted. Glucocorticoids, the most effective agents for reducing eosinophilia, suppress the gene transcription of IL-3, IL-4, IL-5, GM-CSF, and various chemokines [1]. In many studies it has been proven that glucocorticoids can decrease both the number of eosinophils and the effects of their toxic products. After short term treatment with glucocorticoids a significant decrease in the levels of serum eosinophil cationic protein (ECP) and serum eosinophil peroxidase was observed [43]. Evidence supports that decreased level of serum ECP may serve as an objective indicator for the clinical activity and treatment of allergic asthmatics [44]. It has been shown that dexamethasone prevents antigen-induced hyperactivity by protecting neuronal M (2) muscarinic receptors from antagonism by eosinophil major basic protein. This protective mechanism appears to be specifically inhibiting eosinophil recruitment to the airway nerves [45]. Treatment with high dose methylprednisolone results in significant reduction in peripheral blood eosinophils and phenotypic changes characterized by decreased expression of CD11b, CD18, and CD13 which have an important role in the action of eosinophils [46]. In addition, glucocorticoids inhibit the cytokine-dependent survival of

eosinophils [47]. Treatment with systemic or topical (inhaled or intranasal) glucocorticoids causes a rapid reduction in eosinophils. It is important to note that a few patients have a resistance to glucocorticoid therapy and maintain eosinophilia despite high doses of steroids [48]. Patients with glucocorticoid resistance sometimes require alternative approaches.

Our patient failed use of oral cromolyn sodium (gastrocrom®) and montelukast sodium (10 mg/day), and continued to require frequent pulses of glucocorticoids in spite of the coadministration of these medications. This prompted us to use alternative agents. The use of ketotifen and hydroxyurea have been reported to have some success in a limited number of cases. Van Dellen and colleagues reported on the successful use of oral cromolyn in a 47 year old patient with documented food allergy and eosinophilic gastritis [49]. Ketotifen, an H1 class antihistamine, was used as an alternative in 6 patients with eosinophilic gastroenteritis [50]. Patients treated with ketotifen showed eosinophilic clearing in follow up biopsies with associated weight gain. Montelukast has also been used as a steroid sparing therapy. One case report displayed successful steroid tapering of a steroid dependent patient with eosinophilic gastroenteritis once montelukast was begun [51]. Daikh et al. commented on the reduction of eosinophilia with montelukast but the absence of any symptomatic relief in a patient with eosinophilic gastroenteritis [52]. However, Schwartz and coworkers successfully managed to wean a patient with eosinophilic gastroenteritis off glucocorticoids suggesting variable responses to this drug as seen in diseases such as asthma [53]. Given the benign quality of montelukast, this drug may be tried in eosinophilic gastroenteritis and continued therapy based on response rates. Our patient had no response to montelukast and vomiting continued

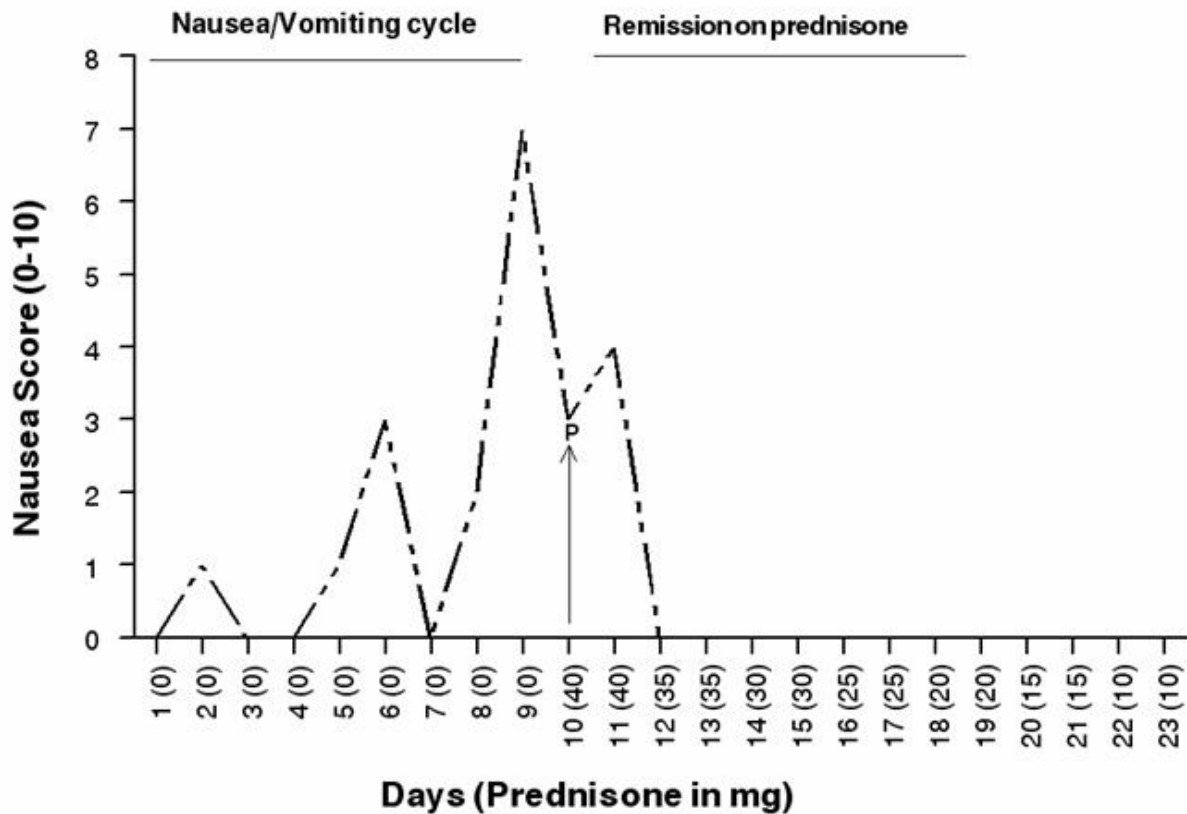


Figure 3

Remission of Nausea and Vomiting with Prednisone. One cycle shown. Nausea was graded by patient from 0 (absent) to 10 (constant/severe). "P" indicates where prednisone was initiated. Prednisone dose is provided in mg/day in parenthesis on x-axis. After prednisone was initiated and maintained at 10–20 mg/day, the patients cyclical vomiting was aborted for the next 2 years of follow up. Body weight, total protein, and albumin levels improved, while eosinophilia was absent.

unabated unless treated with glucocorticoids. Suplatast tosilate has also been reported as a successful treatment but is not currently available in the United States. There are also ongoing pilot studies investigating anti-IL-5 therapy. It is unknown whether these newer biological agents such as antibody to IL-4, IL-5, or CCR3 may have a beneficial effect on the course of eosinophilic gastroenteritis. It is likely in the food allergic individual, antibody to IgE may have some beneficial therapeutic effects. Alternatives in patients who are dependent on steroids or resistant to them include myelosuppressive drugs such as hydroxyurea, azathioprine, vincristine, methotrexate, or interferon alpha. Interferon alpha seem to be especially promising, and this is mostly due to its inhibitory effect on the

degranulation of eosinophils or on the expression of eosinophilic active cytokines by T cells and mast cells as described by us [54,55].

Our patient was started on prednisone (40 mg po once daily). Also at that time she was started on a proton pump inhibitor (lansoprazole 30 mg daily) for esophageal reflux which greatly improved her reflux symptomatology. Prednisone induced a dramatic remission in her symptoms and induced a feeling of well being. There was reversal of the protein losing enteropathy as well as improvements in eosinophilia and serum levels of total protein and albumin. The cyclical vomiting episodes were aborted (one such cycle is shown in Figure 3). On prednisone, these

cycles were completely abolished in the subsequent months). However, given the severe adverse effects of steroids including mood swings and weight gain, the patient opted for alternative therapies. She was started on azathioprine (Imuran®) at 50 mg/day and was quickly able to taper down to a maintenance dose of prednisone of 2 mg/day. She has remained on azathioprine for over 1 year with excellent benefits. It is likely that the combination of prednisone and azathioprine was more effective in this patient than either alone or 6-mercaptopurine. While it was likely that mesalamine induced an allergic reaction or in when administered concomitantly with 6-mercaptopurine, induced toxic side effects, the discontinuation of mesalamine had no beneficial effects on the eosinophilia or vomiting in this patient [56,57]. It is likely that the patient may have had a very low activity of thiopurine methyltransferase (TPMT) but this was not measured in the patient at the time of the study [58].

Conclusions

The patient responded to a combination of glucocorticosteroids and azathioprine with decreased eosinophilia and symptoms. It is likely that eosinophil-active cytokines such as interleukin-3 (IL-3), granulocyte macrophage colony stimulating factor (GM-CSF) and IL-5 play pivotal roles in this disease. Chemokines such as eotaxin may be involved in eosinophil recruitment. These mediators are downregulated or inhibited by the use of immunosuppressive medications.

Competing interests

None declared.

Authors' contributions

BC helped write the paper and organize the figures and patient data, OA helped write the paper, SW helped write the paper, SF helped write, organize, and correct the paper, GK supervised the writing and organization process.

Acknowledgments

This report was supported by NIH grants AI-43310 and HL-63070, and the Department of Internal Medicine at East Tennessee State University.

References

1. Rothenberg ME: **Eosinophilia.** *N Engl J Med* 1998, **338**:1592-1600.
2. Robinson J, Ahmed Z, Siddiqui A, Roy T, Berk S, Smith JK, Krishnaswamy G: **A patient with persistent wheezing, sinusitis, elevated IgE, and eosinophilia.** *Ann Allergy Asthma Immunol* 1999, **82**:144-149.
3. Simon MW, Simon NP: **Cutaneous larva migrans.** *Pediatr Emerg Care* 2003, **19**:350-352.
4. Brenner MA, Patel MB: **Cutaneous larva migrans: the creeping eruption.** *Cutis* 2003, **72**:111-115.
5. Despommier D: **Toxocariasis: clinical aspects, epidemiology, medical ecology, and molecular aspects.** *Clin Microbiol Rev* 2003, **16**:265-272.
6. Bahna SL: **Diagnosis of food allergy.** *Ann Allergy Asthma Immunol* 2003, **90**:77-80.
7. Bock SA: **Diagnostic evaluation.** *Pediatrics* 2003, **111**:1638-1644.
8. Bahna SL: **Clinical expressions of food allergy.** *Ann Allergy Asthma Immunol* 2003, **90**:41-44.
9. Sampson HA: **Food allergy.** *J Allergy Clin Immunol* 2003, **111**:S540-S547.
10. Park HS, Kim HS, Jang HJ: **Eosinophilic gastroenteritis associated with food allergy and bronchial asthma.** *J Korean Med Sci* 1995, **10**:216-219.
11. Sicherer SH: **Clinical aspects of gastrointestinal food allergy in childhood.** *Pediatrics* 2003, **111**:1609-1616.
12. Nowak-Wegryzn A, Sampson HA, Wood RA, Sicherer SH: **Food protein-induced enterocolitis syndrome caused by solid food proteins.** *Pediatrics* 2003, **111**:829-835.
13. Lhote F, Cohen P, Guillevin L: **Polyarteritis nodosa, microscopic polyangiitis and Churg-Strauss syndrome.** *Lupus* 1998, **7**:238-258.
14. Weller PF, Buley GJ: **The idiopathic hypereosinophilic syndrome.** *Blood* 1994, **83**:2759-2779.
15. Brito-Babapulle F: **The eosinophilias, including the idiopathic hypereosinophilic syndrome.** *Br J Haematol* 2003, **121**:203-223.
16. Guajardo JR, Plotnick LM, Fende JM, Collins MH, Putnam PE, Rothenberg ME: **Eosinophil-associated gastrointestinal disorders: a world-wide-web based registry.** *J Pediatr* 2002, **141**:576-581.
17. Meagher LC, Cousin JM, Seckl JR, Haslett C: **Opposing effects of glucocorticoids on the rate of apoptosis in neutrophilic and eosinophilic granulocytes.** *J Immunol* 1996, **156**:4422-4428.
18. Arlt W, Allolio B: **Adrenal insufficiency.** *Lancet* 2003, **361**:1881-1893.
19. Beishuizen A, Vermes I, Hylkema BS, Haanen C: **Relative eosinophilia and functional adrenal insufficiency in critically ill patients.** *Lancet* 1999, **353**:1675-1676.
20. Angelis M, Yu M, Takanishi D, Hasaniya NW, Brown MR: **Eosinophilia as a marker of adrenal insufficiency in the surgical intensive care unit.** *J Am Coll Surg* 1996, **183**:589-596.
21. Bori R, Cserni G: **Eosinophilic gastritis simulating gastric carcinoma.** *Orv Hetil* 2003, **144**:529-531.
22. Owen DA: **Gastritis and carditis.** *Mod Pathol* 2003, **16**:325-341.
23. Chaudhary R, Shrivastava RK, Mukhopadhyay HG, Diwan RN, Das AK: **Eosinophilic gastritis – an unusual cause of gastric outlet obstruction.** *Indian J Gastroenterol* 2001, **20**:110.
24. Kulkarni SH, Kshirsagar AY, Wader JV: **Eosinophilic antral gastritis presenting as pyloric obstruction.** *J Assoc Physicians India* 1998, **46**:744.
25. Scolapio JS, DeVault K, Wolfe JT: **Eosinophilic gastroenteritis presenting as a giant gastric ulcer.** *Am J Gastroenterol* 1996, **91**:804-805.
26. Ormeci N, Bayramoglu F, Tulunay O, Yerdel MA, Onbayrak A, Uzunalinoglu O: **Cancer-like eosinophilic gastritis.** *Endoscopy* 1994, **26**:509.
27. Esteve C, Resano A, Diaz-Tejero P, Fernandez-Benitez M: **Eosinophilic gastritis due to Anisakis: a case report.** *Allergol Immunopathol (Madr)* 2000, **28**:21-23.
28. Stefanini GF, Addolorato G, Marsigli L, Foschi FG, D'Errico A, Scarani P, Bonvicini F, Bernardi M, Gasbarrini G: **Eosinophilic gastroenteritis in a patient with large-cell anaplastic lung carcinoma: a paraneoplastic syndrome?** *Ital J Gastroenterol* 1994, **26**:354-356.
29. Lee JY, Medellin MV, Tumpkin C: **Allergic reaction to gemfibrozil manifesting as eosinophilic gastroenteritis.** *South Med J* 2000, **93**:807-808.
30. Lee M, Hodges WG, Huggins TL, Lee EL: **Eosinophilic gastroenteritis.** *South Med J* 1996, **89**:189-194.
31. Kita H: **The eosinophil: a cytokine-producing cell?** *J Allergy Clin Immunol* 1996, **97**:889-892.
32. Moqbel R, Levi-Schaffer F, Kay AB: **Cytokine generation by eosinophils.** *J Allergy Clin Immunol* 1994, **94**:1183-1188.
33. Forssmann U, Ugucioni M, Loetscher P, Dahinden CA, Langen H, Thelen M, Baggiolini M: **Eotaxin-2, a novel CC chemokine that is selective for the chemokine receptor CCR3, and acts like eotaxin on human eosinophil and basophil leukocytes.** *J Exp Med* 1997, **185**:2171-2176.
34. Jose PJ, Griffiths-Johnson DA, Collins PD, Walsh DT, Moqbel R, Totty NF, Truong O, Hsuan JJ, Williams TJ: **Eotaxin: a potent eosinophil chemoattractant cytokine detected in a guinea pig model of allergic airways inflammation.** *J Exp Med* 1994, **179**:881-887.
35. Rothenberg ME, Ownbey R, Mehlhop PD, Loisel PM, van de Rijn M, Bonventre JV, Oettgen HC, Leder P, Luster AD: **Eotaxin triggers eosinophil-selective chemotaxis and calcium flux via a dis-**

- tinct receptor and induces pulmonary eosinophilia in the presence of interleukin 5 in mice. *Mol Med* 1996, **2**:334-348.
36. Collins PD, Marleau S, Griffiths-Johnson DA, Jose PJ, Williams TJ: **Cooperation between interleukin-5 and the chemokine eotaxin to induce eosinophil accumulation in vivo.** *J Exp Med* 1995, **182**:1169-1174.
 37. Rankin SM, Conroy DM, Williams TJ: **Eotaxin and eosinophil recruitment: implications for human disease.** *Mol Med Today* 2000, **6**:20-27.
 38. Desreumaux P, Bloget F, Seguy D, Capron M, Cortot A, Colombel JF, Janin A: **Interleukin 3, granulocyte-macrophage colony-stimulating factor, and interleukin 5 in eosinophilic gastroenteritis.** *Gastroenterology* 1996, **110**:768-774.
 39. Jaffe JS, James SP, Mullins GE, Braun-Elwert L, Lubensky I, Metcalfe DD: **Evidence for an abnormal profile of interleukin-4 (IL-4), IL-5, and gamma-interferon (gamma-IFN) in peripheral blood T cells from patients with allergic eosinophilic gastroenteritis.** *J Clin Immunol* 1994, **14**:299-309.
 40. Hogan SP, Mishra A, Brandt EB, Foster PS, Rothenberg ME: **A critical role for eotaxin in experimental oral antigen-induced eosinophilic gastrointestinal allergy.** *Proc Natl Acad Sci USA* 2000, **97**:6681-6686.
 41. Sicherer SH, Noone SA, Koerner CB, Christie L, Burks AW, Sampson HA: **Hypoallergenicity and efficacy of an amino acid-based formula in children with cow's milk and multiple food hypersensitivities.** *J Pediatr* 2001, **138**:688-693.
 42. Justinich C, Katz A, Gurbindo C, Lepage G, Chad Z, Bouthillier L, Seidman E: **Elemental diet improves steroid-dependent eosinophilic gastroenteritis and reverses growth failure.** *J Pediatr Gastroenterol Nutr* 1996, **23**:81-85.
 43. Lonnkvist K, Hellman C, Lundahl J, Hallden G, Hedlin G: **Eosinophil markers in blood, serum, and urine for monitoring the clinical course in childhood asthma: impact of budesonide treatment and withdrawal.** *J Allergy Clin Immunol* 2001, **107**:812-817.
 44. Tang RB, Chen SJ: **Serum levels of eosinophil cationic protein and eosinophils in asthmatic children during a course of prednisolone therapy.** *Pediatr Pulmonol* 2001, **31**:121-125.
 45. Evans CM, Jacoby DB, Fryer AD: **Effects of dexamethasone on antigen-induced airway eosinophilia and M(2) receptor dysfunction.** *Am J Respir Crit Care Med* 2001, **163**:1484-1492.
 46. Uckan D, Hicsonmez G, Tunc B, Cetin M, Tezcan I, Tuncer M: **The analysis of eosinophil and lymphocyte phenotype following single dose of high-dose methylprednisolone in two siblings with marked hypereosinophilia.** *Clin Lab Haematol* 2001, **23**:33-37.
 47. Schleimer RP, Bochner BS: **The effects of glucocorticoids on human eosinophils.** *J Allergy Clin Immunol* 1994, **94**:1202-1213.
 48. Barnes PJ, Adcock IM: **Steroid resistance in asthma.** *QJM* 1995, **88**:455-468.
 49. Van Dellen RG, Lewis JC: **Oral administration of cromolyn in a patient with protein-losing enteropathy, food allergy, and eosinophilic gastroenteritis.** *Mayo Clin Proc* 1994, **69**:441-444.
 50. Melamed I, Feanny SJ, Sherman PM, Roifman CM: **Benefit of ketotifen in patients with eosinophilic gastroenteritis.** *Am J Med* 1991, **90**:310-314.
 51. Neustrom MR, Friesen C: **Treatment of eosinophilic gastroenteritis with montelukast.** *J Allergy Clin Immunol* 1999, **104**:506.
 52. Daikh BE, Ryan CK, Schwartz RH: **Montelukast reduces peripheral blood eosinophilia but not tissue eosinophilia or symptoms in a patient with eosinophilic gastroenteritis and esophageal stricture.** *Ann Allergy Asthma Immunol* 2003, **90**:23-27.
 53. Schwartz DA, Pardi DS, Murray JA: **Use of montelukast as steroid-sparing agent for recurrent eosinophilic gastroenteritis.** *Dig Dis Sci* 2001, **46**:1787-1790.
 54. Essayan DM, Krishnaswamy G, Oriente A, Lichtenstein LM, Huang SK: **Differential regulation of antigen-induced IL-4 and IL-13 generation from T lymphocytes by IFN-alpha.** *J Allergy Clin Immunol* 1999, **103**:451-457.
 55. Krishnaswamy G, Smith JK, Srikanth S, Chi DS, Kalbfleisch JH, Huang SK: **Lymphoblastoid interferon-alpha inhibits T cell proliferation and expression of eosinophil-activating cytokines.** *J Interferon Cytokine Res* 1996, **16**:819-827.
 56. Lowry PW, Franklin CL, Weaver AL, Szumlanski CL, Mays DC, Loftus EV, Tremaine WJ, Lipsky JJ, Weinsilboum RM, Sandborn WJ: **Leucopenia resulting from a drug interaction between azathioprine or 6-mercaptopurine and mesalamine, sulphasalazine, or balsalazide.** *Gut* 2001, **49**:656-664.
 57. Tanigawa K, Sugiyama K, Matsuyama H, Nakao H, Kohno K, Komura Y, Iwanaga Y, Eguchi K, Kitaichi M, Takagi H: **Mesalazine-induced eosinophilic pneumonia.** *Respiration* 1999, **66**:69-72.
 58. Baker DE: **Pharmacogenomics of azathioprine and 6-mercaptopurine in gastroenterologic therapy.** *Rev Gastroenterol Disord* 2003, **3**:150-157.
 59. Fitzgerald KA, O'Neill LAJ, Gearing AJH, Callard RE: *The Cytokine Facts Book* San Diego: Academic Press; 2001.
 60. Krishnaswamy G, Dube M, Counts M, Chi DS: **Cytokines and the pathogenesis of atherosclerosis.** In *Advances in Cell Aging and Gerontology Volume 11*. First edition. Edited by: Hagen T, Mattson MP. Amsterdam: Elsevier Press; 2002:79-126.

Publish with **BioMed Central** and every scientist can read your work free of charge

"BioMed Central will be the most significant development for disseminating the results of biomedical research in our lifetime."

Sir Paul Nurse, Cancer Research UK

Your research papers will be:

- available free of charge to the entire biomedical community
- peer reviewed and published immediately upon acceptance
- cited in PubMed and archived on PubMed Central
- yours — you keep the copyright

Submit your manuscript here:
http://www.biomedcentral.com/info/publishing_adv.asp

