
















ORIGINAL ARTICLE

Morphometric parameters and food preference in relation to sex and reference hematological values for *Upupa epops* from Pakistan

Rida Tahir¹ , Warda Zafar¹ , Muhammad Waseem Aslam¹ , Ahmad Waheed¹ , Ali Umar¹ , Sana Fatima² , Tariq Javed¹ , Tabish Liaqat³ , Allah Ditta¹ , Muhammad Ashfaq¹ , Muhammad Zaman¹ , Ali Nawaz¹ , Tehmina Khan¹ , Muhammad Wajid¹ , Muhammad Saleem Khan¹ 

¹Department of Zoology, Faculty of Life Sciences, University of Okara, Okara, Pakistan

²Department of Zoology, Wildlife and Fisheries, University of Agriculture, Faisalabad, Pakistan

³Department of Fisheries and Aquaculture, Faculty of Life Sciences, University of Okara, Okara, Pakistan

ABSTRACT

Objective: The study was conducted to investigate the gut content and record morphometric and hematological parameters in the common hoopoe (*Upupa epops*).

Materials and Methods: Twenty samples of healthy birds (10 from each sex) were collected from different locations in Okara District, Punjab, Pakistan, from September 2020 to March 2021. Birds were captured live for blood samples and morphometric and gut analyses.

Results: It was revealed that the concentrations of different hematological parameters were as follows: hemoglobin, 20.03g/dl; red blood cells, $3.28 \times 10^6/\mu\text{l}$; white blood cells, $326.67 \times 10^3/\mu\text{l}$; hematocrit, 56.47%; MCV, 173.33 FL; MCH, 57.4 pg; MCHC, 57.4 pg; PLT, 8.33/ μl ; and RDW, 8.33/ μl . The percentages of neutrophils, lymphocytes, monocytes, and eosinophils were 84.67%, 11.67%, 2.00%, and 1.67%, respectively. The gut content of the common hoopoe mostly consisted of Coleoptera and Acrididae larvae. However, Lepidoptera, Gryllotalpidae, and sand were also recorded, along with seeds of *Salvadora persica*.

Conclusions: There were no significant differences between male and female *U. epops* in feeding content, total weight of the gut, or weight of the empty gut. Regarding the morphometric parameters, there was a significant difference in both sexes' wingspan, body length, and body weight. Males were significantly heavier than females.

ARTICLE HISTORY

Received March 25, 2021

Revised March 30, 2022

Accepted April 02, 2022

Published June 27, 2022

KEYWORDS

Common hoopoe; gut contents; hematology; morphometry; Pakistan



© The authors. This is an Open Access article distributed under the terms of the Creative Commons Attribution 4.0 License (<http://creativecommons.org/licenses/by/4.0>)

Introduction

The common hoopoe (*Upupa epops*) is known by its Arabic name, "Hudhud," in Pakistan. It is a remarkable and unique old-world bird that belongs to the family Upupidae. It has its foraging style with special external features [1]. The distribution ranges from Europe and North and sub-Saharan Africa (including Madagascar) to Asia. They mainly breed in Europe, Africa, Malaysia, the Middle East, China, and Indonesia [2]. Most of the African and Southeast Asian populations of common hoopoe remain in their native areas in the winter and do not migrate [3].

They also migrate to the tropical region from North Asia and Europe during the winter seasons [4]. This bird is common in Pakistan and reaches Pakistan by flying over

the Karakoram and Sulaiman ranges and the Hindu Kush beside the Indus River [5]. It is also a summer-breed visitor in the northern Himalayas and Indus plains [2]. The best living places are wooded steppes, savannas, grasslands, and forest glades. Deserts and natural forests are avoided [2,6].

Upupa epops is a small to medium-sized, slender-shaped bird with a 29–31 cm body length and a 64–77 gm weight in males and 57–69 gm in females [7]. The head is mainly rufous orange to orange-brown or salmon pink in color, with sticking black and white wings of an average length of 13.6–15.3 cm [8]. During flight, the upper surface shows alternative white and black bars. *Upupa epops* has a long,

Correspondence Muhammad Saleem Khan ✉ samiikhan@uo.edu.pk 📧 Department of Zoology, Faculty of Life Sciences, University of Okara, Okara Pakistan.

How to cite: Tahir R, Zafar W, Aslam MW, Waheed A, Umar A, Fatima S, et al. Morphometric parameters and food preference in relation to sex and reference hematological values for *Upupa epops* from Pakistan. J Adv Vet Anim Res 2022; 9(2):290–294.

thin, downcurved black bill of 5–6.3 cm and a squared tipped, black and white striped tail of 9.8–10.9 cm [7]. Like the erectile crest crown, the high black tip fan consists of 28 feathers (long, narrow, and orange) on the common hoopoe's head [9]. They are usually held flat, curved downwards in the narrow tail in the rest position, and in excited or alarmed conditions, the crest is erect and fan-shaped [2,7].

Avian hematology started early in the 1960s. In veterinary practice, hematology is vital, and changes in avian blood's morphology and composition help detect and diagnose health issues [10]. The blood parameters change in response to health status and migration. For example, hemoglobin concentration increases significantly over the migratory period [11]. In many species, hemoglobin concentration starts to grow from the time of fledgling until adulthood [12]. Some species, along with heterophils, respond to stress with lymphocytosis (increased lymphocytes). In the case of any chronic disease, the number of monocytes increases, while in allergic or parasitic conditions, the number of eosinophils increases [13]. Therefore, building standard reference values is necessary for each avian species.

The common hoopoe is mostly insectivorous; it feeds on small worms (annelids), larvae of ant-lions (*Myrmeleonidae*), Elaleid beetles *Agrotis* larvae, Hemiptera bugs, etc. In some studies, small reptiles, frogs, and plant matter were also recorded in the food [2,6]. Hoopoes that inhabit farmland mainly feed on mole crickets (*Gryllotalpidae*) and *Lepidoptera* larvae [14], whereas hoopoes in pine plantations mainly feed on pupae of the pine moth (*Thaumetopoea pityocampa*) [6,15]. During the winter–autumn season, they feed on ants (*Componotus compresses*). The primarily young feed on soil invertebrates [2,16]. The study was conducted to investigate the gut content and record morphometric and hematological parameters in common hoopoe (*U. epops*).

Materials and Methods

Ethical approval

All procedures carried out on the animals in this study followed the rules set by the University of Okara's Ethical Committee (approval number: UO/DOZ/2020/misc.).

Study area and sampling

Samples of the common hoopoe were collected from the grassy wooded steppes area of Renala Khurd (30.88°N, 73.60°E), Pipli Pahar (30.68°N, 73.43°E), and alongside the Ravi river in Okara District. These places were visited in the morning and evening from December 2020 to March 2021, twice a day for sampling. Twenty samples of

the common hoopoe (10 from each gender) were captured with the help of local hunters using a net. After capture, we anesthetized the birds by using a combination of ketamine HCL (10 mg/kg) and diazepam (0.2 mg/kg) [17].

Blood sample analysis, gut content, and morphometry

Analyses of hematological and morphometric characteristics and gut content of the common hoopoe were carried out according to the methodology described by Aslam et al. [18].

Statistical analysis

Data were analyzed through mean, standard deviation (SD), standard error (SE), and range using GraphPad Prism 9.0 software. The significant difference was tested through an unpaired *t*-test at a 0.05 confidence level.

Results and Discussion

Hematology

The hematological values are used to indicate the health state of birds, as well as mammals. These are used for diagnosing and monitoring diseases, evaluation of disease therapy, or disease prognosis. These can also be used as physiological reference values for specific indicators for different bird species. Different physiological factors can affect the hematology of healthy birds [19,20]. The present study provides physiological reference values for normal values of the adult birds of this species (Table 1). No

Table 1. Hematological parameters of the common hoopoe collected from Okara District, Punjab, Pakistan.

Variable	SE	Mean ± SD
HGB (gm/dl)	2.16	20.03±3.73
WBC (×10 ³ /μl)	2.88	326.33±3.33
RBC (×10 ⁶ /μl)	0.22	3.28±0.37
HCT (%)	0.41	56.47±0.70
MCV (FL)	0.72	173.33±1.25
MCH (pg)	0.71	58.97±1.23
MCHC (gm/dl)	1.66	34.33±2.87
PLT (×10 ³ /μl)	1.19	8.33±2.05
RDW	1.28	75.00±2.21
Neutrophils	2.60	84.67±4.50
Lymphocytes	3.31	11.67±5.73
Monocytes	0.47	2.00±0.82
Eosinophils	0.27	1.67±0.47

SE = Standard error; SD = Standard deviation.

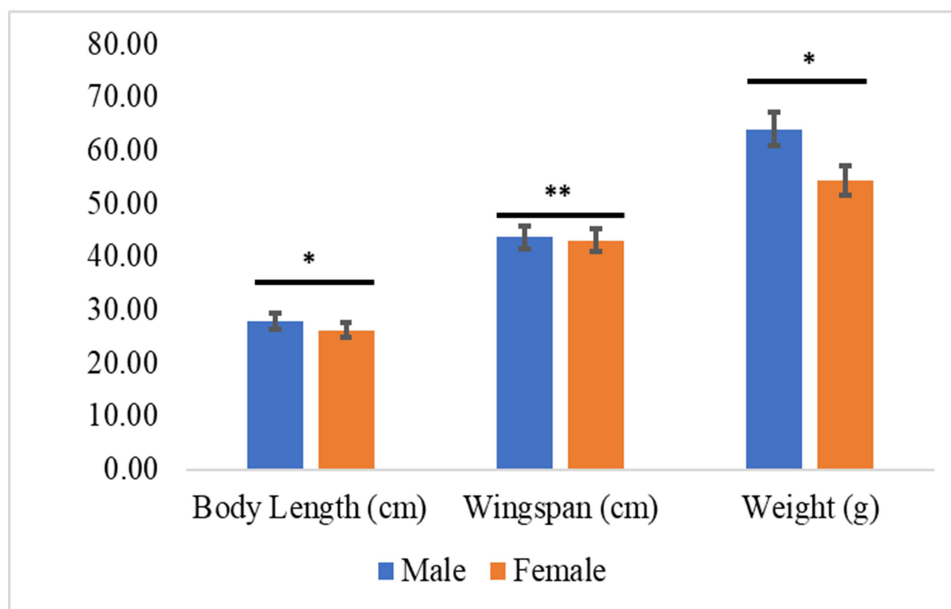


Figure 1. Comparison of body length, wingspan, and weight of both sexes of *U. epops* (* $p < 0.05$; ** $p < 0.01$)

Table 2. Comparison of morphometric characteristics between male and female *Upupa epops* collected from Okara District, Punjab, Pakistan.

Characters	Sex(n = 10 each)	SE	Mean	Range	p-value
Body weight (gm)	Male	2.07	64.03	57.70–68.00	0.01*
	Female	1.04	54.35	52.60–57.70	
Body length (cm)	Male	0.12	27.88	27.50–28.10	0.01*
	Female	0.21	26.23	26.40–27.50	
Tail length (cm)	Male	0.14	11.18	10.80–11.50	0.175 ^{NS}
	Female	0.11	10.85	10.50–11.10	
Wingspan (cm)	Male	0.06	43.70	43.60–43.90	<0.01**
	Female	0.03	43.05	43.00–43.10	
Wing length (cm)	Male	0.13	18.85	18.40–19.10	0.142 ^{NS}
	Female	0.08	18.55	18.40–18.70	
Longest primary feather (cm)	Male	0.12	13.53	13.20–13.90	0.518 ^{NS}
	Female	0.02	13.43	13.40–13.50	
Tarsus (cm)	Male	0.12	2.40	2.00–2.60	0.115 ^{NS}
	Female	0.05	2.13	2.00–2.30	
Central toe length (cm)	Male	0.03	2.15	2.10–2.20	0.228 ^{NS}
	Female	0.04	2.08	2.00–2.20	
Head length without bill (cm)	Male	0.08	3.25	3.10–3.50	0.085 ^{NS}
	Female	0.14	2.88	2.60–3.20	
Head length with bill (cm)	Male	0.01	8.75	8.60–8.90	0.055 ^{NS}
	Female	0.13	8.35	8.10–8.60	
Bill length (cm)	Male	0.04	5.50	5.40–5.60	0.620 ^{NS}
	Female	0.02	5.48	5.40–5.50	
Chest circumference (cm)	Male	0.17	13.78	13.40–14.20	0.007 ^{NS}
	Female	0.09	12.90	12.60–13.10	

* $p < 0.05$; ** $p < 0.01$; NS = Nonsignificant difference (p -value > 0.05).

Table 3. Weight of gut variables in male and female common hoopoes.

Characters	Gender	N	Mean	SD	SE	t-value	p-value
Total weight of gut (gm)	Male	10	2.30	0.62	0.36	0.01	0.9512 ^{NS}
	Female	10	2.33	0.37	0.22		
Weight of food material (gm)	Male	10	1.06	0.49	0.28	0.02	0.9052 ^{NS}
	Female	10	1.01	0.33	0.11		
Weight of empty gut (gm)	Male	10	1.24	0.13	0.07	0.74	0.4163 ^{NS}
	Female	10	1.32	0.04	0.33		

NS = Nonsignificant difference (p -value > 0.05).

Table 4. Gut content of male and female common hoopoes.

Type of Food	Weight of different gut contents (%)		p-value
	Male	Female	
Lepidoptera	0.00	10.33	0.3090 ^{NS}
Gryllotalpidae	0.00	4.00	0.3739 ^{NS}
<i>S. persica</i>	15.33	18.33	>0.9999 ^{NS}
Acrididae	0.00	2.67	0.3739 ^{NS}
Coleoptera	61.67	24.00	0.0866 ^{NS}
Sand	0.00	5.33	0.3739 ^{NS}
Digested material	23.00	35.33	0.4012 ^{NS}

NS = Nonsignificant difference (p -value > 0.05).

previous comparable records are present for the species in the present analysis.

Morphometry

Significant differences were observed in wingspan, body weight, and body length (Fig. 1), while all other morphometric parameters were nonsignificant (Table 2).

Morphological analysis helps understand the evolutionary processes [21,22]. The present study was similar to David [23] and Roberts [2] in the morphometric measurement of body weight, body length, wingspan, and length of the longest primary feather of male and female common hoopoes. In the case of bill length, similar values to our study were also reported by van Wijk et al. [7], Elshaer [24], and Roberts [2]. At the same time, all other remaining morphometric parameters were reported for the first time in the present study.

Food preferences

There were nonsignificant differences between total weight of the gut, weight of the food content, and weight of the empty gut for both sexes (Table 3). The gut analysis shows that the common hoopoe feeds mainly on Coleoptera and Acrididae larvae. However, Lepidoptera, Gryllotalpidae, and sand were also found. The seed of *Salvadora persica*

was found in the gut. The difference in feeding content between both sexes was nonsignificant (Table 4).

The study of feed preference is important from ecological and conservation perspectives [25]. The gut content of *U. epops* consisted of larvae of Lepidoptera, Gryllotalpidae and Acrididae, Coleoptera, and sand, which were also reported by Kristin [6] and Roberts [2]. We also found some plant matter, i.e., seeds of *S. persica*, in the gut of *U. epops*, which Fournier and Arlettaz [14] also reported. However, our outcomes differed from Roberts [2] in the case of small reptiles and frogs, as we did not find any of these in the gut content of *U. epops*. Namma and Rao [26], Myo et al. [27], and Tomás et al. [28] reported that *U. epops* preferred to eat insects. This difference might be due to the difference in habitat or food availability.

Conclusion

The morphometries of both sexes of the common hoopoe (except for body weight, body length, and wingspan), gut weight, and gut content were similar. Males were larger and heavier as compared to females. The gut analysis shows that the common hoopoe feeds on Coleoptera, Acrididae larva, Lepidoptera, Gryllotalpidae, sand, and seeds of different plants, such as *S. persica*. This study discusses all blood parameters of the common hoopoe for the first time.

List of abbreviations

HGB, Hemoglobin; WBC, White blood cells; RBC, Red blood cells; HCT, Hematocrit; MCV, Mean corpuscular volume; MCH, Mean corpuscular hemoglobin; MCHC, Mean corpuscular hematocrit; PLT, Platelets; RDW, Red cell distribution width.

Acknowledgment

Not applicable.

Conflict of interest

The authors declare that they have no conflict of interest.

Authors' contributions

RT, MW, and WZ designed the study. AD, TK, and MA interpreted the data. AW and AU drafted the manuscript. MWA, MZ, AN, TJ, TL, and SF were involved in the collection of data and also contributed in manuscript preparation. MSK took part in preparing and critically checking this manuscript.

References

- [1] Mahmoud FA, Gadel-Rab AG, Shawki NA. Functional morphological study of the choana in different bird species. *J Basic Appl Zool* 2018; 79(1):11; <https://doi.org/10.1186/s41936-018-0026-6>
- [2] Roberts TJ. *Birds of Pakistan*, vol. 2, Oxford University Press, Oxford, UK, 1992.
- [3] Hewitt GM. Some genetic consequences of ice ages, and their role in divergence and speciation. *Biol J Linnean Soc* 1996; 58 (3):247–76; <https://doi.org/10.1111/j.1095-8312.1996.tb01434.x>
- [4] Reichlin TS, Schaub M, Menz MHM, Mermod M, Portner P, Arlettaz R, Jenni L. Migration patterns of Hoopoe *Upupa epops* and Wryneck *Jynx torquilla*: an analysis of European ring recoveries. *J Ornithol* 2008; 150 (2):393; <https://doi.org/10.1007/s10336-008-0361-3>
- [5] Altaf M, Javid A, Munir MA, Ashraf S, Iqbal KJ, et al. Diversity, distribution and ecology of birds in summer season flathead Khanki, Punjab, Pakistan. *Biologia* 2013; 59(1):131–7.
- [6] Kristin A. *Family Upupidae (Hoopoe)*, Handbook of the birds of the world. vol.6, Lynx Edicions, Barcelona, Spain, 2001.
- [7] van Wijk RE, Schaub M, Hahn S, Juarez-Garcia-Pelayo N, Schafer B, Viktora L, et al. S Bauer. Diverse migration strategies in hoopoes (*Upupa epops*) lead to weak spatial but strong temporal connectivity. *Naturwissenschaften* 2018; 105(7–8):42; <https://doi.org/10.1007/s00114-018-1566-9>
- [8] Phillipps K. *A field guide to the birds of Borneo, Sumatra, Java, and Bali: the Greater Sunda Islands*. Oxford University Press, Oxford, UK, 1993.
- [9] Nicoll MJ. *Handlist of the birds of Egypt*. Government Press, Egypt, 1919; <https://doi.org/10.5962/bhl.title.14405>
- [10] Mitchell EB, Johns J. Avian hematology and related disorders. *Vet Clin North Am Exot Anim Pract* 2008; 11(3):501–22; <https://doi.org/10.1016/j.cvex.2008.03.004>
- [11] Piersma T, Everaarts JM, Jukema J. Build-up of red blood cells in refuelling bar-tailed godwits in relation to individual migratory quality. *Condor* 1996; 98 (2):363–70. <https://doi.org/10.2307/1369154>
- [12] Samour J, Naldo J, Libanan N, Rahman H, Sakkir M. Age-related hematology and plasma chemistry changes in captive Masai ostriches (*Struthio camelus massaicus*). *Comp Clin Path* 2010; 20(6):659–67; <https://doi.org/10.1007/s00580-010-1054-x>
- [13] DeNicola DB. Advances in hematology analyzers. *Top Companion Anim Med* 2011; 26(2):52–61; <https://doi.org/10.1053/j.tcam.2011.02.001>
- [14] Fournier J, Arlettaz R. Food provision to nestlings in the Hoopoe *Upupa epops*: implications for the conservation of a small endangered population in the Swiss Alps. *Ibis* 2001; 143(1):2–10; <https://doi.org/10.1111/j.1474-919X.2001.tb04163.x>
- [15] Barbaro L, Couzi L, Bretagnolle VN, Vetillard F. Multi-scale habitat selection and foraging ecology of the eurasian hoopoe (*Upupa epops*) in pine plantations. In Brockerhoff EG, Jactel H, Parrotta JA, Quine CP, Sayer J, Hawksworth DL (eds.), *Plantation forests and biodiversity: oxymoron or opportunity?* Springer, Dordrecht, The Netherlands, pp 149–163, 2007; https://doi.org/10.1007/978-90-481-2807-5_8
- [16] Martín-Vivaldi M, Palomino JJ, Soler M, Soler JJ. Determinants of reproductive success in the Hoopoe *Upupa epops*, a hole-nesting non-passerine bird with asynchronous hatching. *Bird Study* 1999; 46(2):205–16; <https://doi.org/10.1080/00063659909461132>
- [17] Abbas SW, Ali MN, Abbas G, Safwan HM, Sajid M, Mehmood M. Comparative effectiveness of general anesthesia in doves using a combination of ketamine and diazepam. *Adv Zool Bot* 2018; 6(4):95–100; <https://doi.org/10.13189/azb.2018.060401>
- [18] Aslam, MW, M Wajid, A Waheed, S Ahmad, K Jafar, H Akmal, et al. Revision of some mensural measurements, food preference, and haematological parameters in breeding pairs of blue rock pigeon, *Columba livia* sampled from punjab Pakistan. *Braz J Biol* 2021; 83; <https://doi.org/10.1590/1519-6984.252059>
- [19] Zapletal D, Kudělková L, Šimek V, Jakešová P, Macháček M, Straková E, et al. Haematological indicators in hybrid mallard ducks (*Anas platyrhynchos*) with regard to the use of meal from whole white lupin seeds in their diet. *Acta Vet Brno* 2017; 86 (3):309–15; <https://doi.org/10.2754/avb201786030309>
- [20] Kral I, Suchý P. Haematological studies in adolescent breeding cocks. *Acta Vet Brno* 2000; 69(3):189–94; <https://doi.org/10.2754/avb200069030189>
- [21] Anthwal N, Tucker AS. Q&A: Morphological insights into evolution. *BMC Biol* 2017; 15(1):83; <https://doi.org/10.1186/s12915-017-0425-z>
- [22] Aaron E, Hawthorne-Madell J, Livingston K, Long JH. Morphological evolution: Bioinspired methods for analyzing bioinspired robots. *Front Robot AI* 2021; 8:717214; <https://doi.org/10.3389/frobt.2021.717214>
- [23] David A. Hoopoes and Acacias: decoding an Ancient Egyptian Funerary Scene. *J Near East Stud* 2014; 73(2):235–52; <https://doi.org/10.1086/677251>
- [24] Elshaer F. Comparative morphometric studies of the cranium in the three types of birds with different feeding behaviors. *Egypt Acad J Biol Sci B. Zool* 2019; 11(1):47–57; <https://doi.org/10.21608/eajbsz.2019.29471>
- [25] Tryjanowski P, Møller AP, Morelli F, Indykiewicz P, Zduniak P, Myczko Ł. Food preferences by birds using bird-feeders in winter: a large-scale experiment. *Avian Res* 2018; 9(1):1–6; <https://doi.org/10.1186/s40657-018-0111-z>
- [26] Namma V, Rao VV. Exploitation of beneficial birds against major insect pests of castor *Ricinus communis* L. *Indian J Entomol* 2020; 82(1):29–31; <http://dx.doi.org/10.5958/0974-8172.2020.00006.1>
- [27] Myo Y, Zin T, Htay SS. Different types of foods foraged by various bird species in Pakokku environs, magway region. *Myanmar Acad Arts Sci* 2020; 18(3):187–97.
- [28] Tomás G, Zamora-Muñoz C, Martín-Vivaldi M, Barón MD, Ruiz-Castellano C, Soler JJ. Effects of chemical and auditory cues of hoopoes (*Upupa epops*) in repellence and attraction of blood-feeding flies. *Front Ecol Evol* 2020; 8:1–12; <https://doi.org/10.3389/fevo.2020.579667>