

# Prevalence of femoroacetabular impingement in elite baseball players

Carlos A. Uquillas<sup>1</sup>, Yuhang Sun<sup>1\*</sup>, Wade Van Sice<sup>2</sup>, Neal S. ElAttrache<sup>1</sup> and Michael B. Banffy<sup>1</sup>

<sup>1</sup>Kerlan Jobe Orthopedic Clinic, 6801 Park Terrace, Suite 500, Los Angeles, CA 90045, USA and <sup>2</sup>Kerlan Jobe Orthopedic Clinic, 2055 Military Trail #204, Jupiter, FL 33458, USA.

\*Correspondence to: Y. Sun. E-mail: [Ys436@cornell.edu](mailto:Ys436@cornell.edu)

## ABSTRACT

CAM-type femoroacetabular impingement continues to be an underrecognized cause of hip pain in elite athletes. Properties inherent to baseball such as throwing mechanics and hitting may enhance the risk of developing a cam deformity. Our goal is to gain an appreciation of the radiographic prevalence of cam deformities in elite baseball players. Prospective evaluation and radiographs of 80 elite baseball players were obtained during the 2016 preseason entrance examination. A sports medicine fellowship-trained orthopedic surgeon with experience treating hip disorders used standard radiographic measurements to assess for the radiographic presence of cam impingement. Radiographs with an alpha angle  $>55^\circ$  on modified Dunn views were defined as cam positive. Of the 122 elite baseball players included in our analysis, 80 completed radiographic evaluation. Only 7.3% (9/122) of players reported hip pain and 1.6% (4/244) had a positive anterior impingement test. The prevalence of cam deformities in right and left hips were 54/80 (67.5%) and 40/80 (50.0%), respectively. The mean alpha angle for cam-positive right and left hips were  $64.7 \pm 6.9^\circ$  and  $64.9 \pm 5.8^\circ$ , respectively. Outfielders had the highest risk of right-sided cam morphology (Relative Risk (RR) = 1.6). Right hip cam deformities were significantly higher in right-handed pitchers compared with left-handed pitchers ( $P = 0.02$ ); however, there was no significant difference in left hip cam deformities between left- and right-handed pitchers ( $P = 0.307$ ). Our data suggest that elite baseball players have a significantly higher prevalence of radiographic cam impingement than the general population.

## INTRODUCTION

Femoroacetabular impingement (FAI) has been increasingly recognized as a cause of hip pain in athletes at all levels of competition [1–6]. Despite the increased awareness, it continues to be an underrecognized cause of hip pain. In 2006, Burnett *et al.* published a study reporting that the average time for an athlete to receive an accurate diagnosis from the time of injury was 21 months and required evaluation by 3.3 different health-care providers [7]. Since then, there have been multiple studies demonstrating an increase in the incidence of FAI along with a concurrent increase in the use of surgical procedures [8, 9]. Studies have also demonstrated that a high percentage of asymptomatic patients have radiographs suggestive of FAI [10, 11]. This suggests that although significant investigational and educational advances have been made, further studies are needed to increase our understanding of the prevalence of FAI pathology.

FAI refers to the impingement which occurs due to an abnormal bony morphology of the proximal femur and/or the acetabulum [12]. Two distinct types of impingement have been described, the cam and the pincer [13]. Cam impingement occurs as a result of an abnormally shaped femoral head repeatedly impinging upon an acetabulum that cannot accommodate the increased radius of the femoral head [13, 14]. The primary pathology for pincer-type impingement, on the other hand, is

the acetabulum with the resultant over-coverage of the femoral head leading to abutment of the femoral head–neck junction on the acetabular rim in flexion [13, 14]. Both pathologies can lead to labral tears and traumatic intra-articular injuries from repetitive minor trauma or acute injury such as hyperabduction, direct hip impact and joint subluxation or dislocation [15, 16]. Certain positions and motions have been purported as risk factors for hip injury, in particular, flexion combined with internal rotation [17, 18]. Our focus for this study will be on cam-type impingement.

There may be sport-specific risk factors for developing cam-type FAI. Philippon *et al.* looked at the prevalence in youth ice hockey players and found they have a greater prevalence of  $\alpha$ -angles associated with cam deformity than skier-matched controls [3]. In a study of elite hockey players, Lerebours *et al.* found 69.5% cam-type deformity in at least one hip [5]. Gerhardt *et al.* looked at the epidemiology of elite soccer players and found males to have 68% prevalence of cam-type deformity and 27% pincer type [2]. These reports have been higher than the reported 14% prevalence in asymptomatic adults [11]. One theory for the development of cam-type FAI is from repetitive microtrauma to the proximal femoral growth plate, as may be seen with the exposure needed for athletes to achieve elite levels [17].

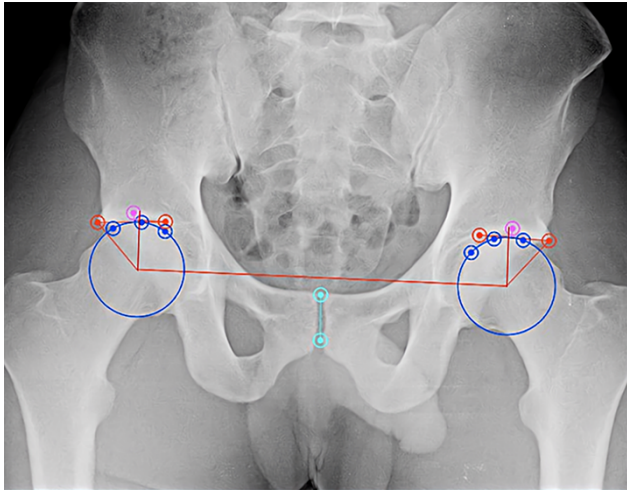


Fig. 1. AP pelvis radiograph with OsiriX measurements for lateral center-edge angle (LCEA, red).

While the exact etiology of cam-type FAI is not completely understood, recent literature has shown an increased prevalence of cam-type FAI in competitive athletes, specifically those participating at a high level at an early age [2, 3, 5]. Hip and groin injuries are common in baseball players [19]. A recent study showed that there were 1823 hip and groin injuries in professional baseball players between 2011 and 2014, with an average loss of 123 days for those requiring surgery [20]. The objective of this study was to determine the prevalence of hip pathology in a cohort of professional baseball players using physical examination and plain radiographs. We hypothesize that the prevalence of cam morphology in elite baseball players is higher than the average population.

## MATERIALS AND METHODS

The data gathered for this study were obtained during the athletes' 2016 preseason entrance examinations at Spring Training. All potential roster members of four Major League Baseball (MLB) organizations in the major and minor league systems were eligible. Players with a prior history of hip surgery were excluded from this study. Institutional review board approval and informed consent from participants were obtained for this study.

Each subject underwent a demographic assessment and screening radiography, including anteroposterior (AP) pelvis and modified Dunn views of both hips. Patients underwent a clinical hip examination consisting of the flexion/abduction/external rotation test, impingement testing including flexion/adduction/internal rotation test and extension external rotation. These tests were considered positive if the provocative maneuver elicited pain. Radiographs were performed by certified radiology technicians, and all images were evaluated by a fellowship-trained orthopedic sports medicine surgeon that was blinded to the player and position in order to determine the adequacy of the studies as well as the radiographic characteristics. AP images were deemed adequate if the coccyx was centered over, and approximately 3 cm above, the pubic symphysis and the obturator foramen were neutrally rotated. The modified Dunn views were considered acceptable if there was clear visualization

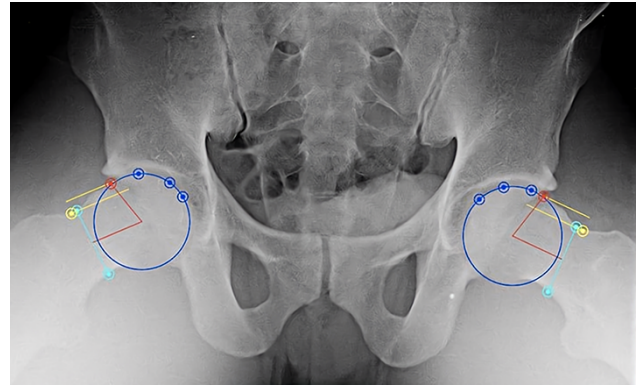


Fig. 2. Radiograph of the modified Dunn lateral view with OsiriX measurements of  $\alpha$ -angle (red).

of the anterior and posterior head-neck junctions. The radiographic measurements were performed with the use of OsiriX (Geneva, Switzerland) software with the orthopedic studio plugin (Figs 1 and 2). This program facilitated these measurements by allowing the user to identify several landmarks and then automatically calculating all angles that were of interest in the image.

Cam lesions were identified by an  $\alpha$ -angle  $> 55^\circ$  (correlates with the prominence of the anterior femoral head-neck junction) on the modified Dunn views. The  $\alpha$ -angle was measured by drawing a best fit circle surrounding the femoral head and then placing a line drawn perpendicular to the narrowest point of the femoral neck and another line perpendicular to this line bisecting the femoral neck. The angle subtending the latter line and the point where the femoral head protrudes anterior to the circle was defined as the  $\alpha$ -angle. In this study, the LCEA and crossover sign were used to identify pincer lesions. The crossover sign was considered positive if there was any overlap between the lines tracing the anterior and posterior acetabular walls on the AP pelvis view. The LCEA was considered positive if the angle formed by a line drawn from the center of the femoral head to the outer edge of the acetabular roof and a vertical line drawn through the center of the femoral head was greater than  $40^\circ$  on the AP pelvis view. The presence of hip dysplasia was identified by an LCEA  $< 25^\circ$ . Any radiograph that met the criteria for a cam lesion, pincer lesion or dysplasia as described by the criteria above was defined as an abnormal radiograph.

## STATISTICAL ANALYSIS

Descriptive statistics were used in our data analysis. Statistical calculations were performed using SAS version 9.2 (SAS Institute). The Fisher exact test was used to examine the significance of the associations between player positions and radiographic evidence of cam deformity. The independent-samples *t*-test was used to compare numerical variables (shown as mean 6 SD) across two groups, and the Fisher exact test was used to compare categorical variables (shown as *n* [%]) across groups. The 0.05 significance level was used throughout.

**Table I. Demographic information**

Patients	N = 80
Age	22.0 ± 3.0
BMI	25.2 ± 2.1
Throwing hand	
Right	62 (77.5%)
Left	18 (22.5%)
Batting side	
Right	52 (65.0%)
Left	23 (28.8%)
Switch	5 (6.2%)
Position	
Pitchers	46 (57.5%)
Outfielder	16 (20.0%)
Infield	15 (18.8%)
Catchers	3 (3.7%)

## RESULTS

A total of 122 players met criteria and agreed to participate in the physical exam and 80 ultimately underwent radiographic evaluation. Forty-two players did not obtain radiographs as per the decision of the organization and their desire to avoid unnecessary radiation exposure in asymptomatic players. There were no demographic differences between the players who obtained radiographs and those who did not obtain radiographs. Of the 80 players who obtained radiographs, the average age was 22.0 years ( $\pm 3.0$ ), and the average body mass index (BMI) was 25.2 ( $\pm 2.1$ ). Sixty-two were right-handed throwers and 18 were left-handed throwers. Fifty-two bat right, 23 left and 5 were switch hitters. The players were predominantly pitchers, with 46 pitchers, 16 outfielders, 15 infielders and 3 catchers (Table I). On physical examination, we found that 7.3% (9 /122) players reported hip pain and 1.6% (4/244) hips tested had a positive anterior impingement test.

Radiographic evaluation showed that 71% of players demonstrated a cam deformity with 67.5% in the right hip, 50% in the left hip and 46.3% bilaterally. The  $\alpha$ -alpha angle was  $65.7 \pm 7.0^\circ$  for right-sided cam deformities and  $64.9 \pm 5.8^\circ$  for left-sided deformities. Regarding pincer morphology, 51.3% of players demonstrated a pincer deformity with 40% in the right hip, 36% in the left hip and 25% bilaterally. Additionally, we found 22.5% of players had a center edge angle  $<25^\circ$  in either hip which represents either borderline or true dysplasia. Only 10% of subjects had normal radiographs (Table II).

Subgroup analysis showed that the players with cam morphology were significantly older (Right hip:  $22.6 \pm 3.2$  years versus  $20.8 \pm 1.9$  years, Left hip:  $23.0 \pm 3.4$  years versus  $21.1 \pm 2.1$  years). The average weight of players with cam morphology on the right was significantly greater ( $197 \pm 21.3$  versus  $189 \pm 17$  pounds). The average height of players with cam morphology on the left was significantly greater ( $74.1 \pm 2.3$  versus  $73.1 \pm 1.8$  inches). There were no statistically significant differences between patients with dysplasia or pincer morphology in regard to age, height, weight and BMI (Table III).

There was a difference in the prevalence of cam deformity based on position, with outfielders having a relative risk of 1.6 to have right-sided cam morphology (Table IV, Fig. 3).

The side of the cam morphology was not correlated with hitting side or throwing side when analyzing our series as a whole. However, when isolating pitchers, there was a higher prevalence of right hip cam deformity in right-handed pitchers (RHPs) compared with left-handed pitchers (LHPs;  $P = 0.02$ ) (Table V–VII).

## DISCUSSION

The main finding in our study established that two-thirds of elite baseball players have radiographic findings of cam-type FAI. When compared with the general population, the rate of cam-type deformity was higher in our cohort. In 2010, Hack *et al.* reported the prevalence of cam deformities to be 14% in asymptomatic individuals [11]. Frank *et al.* performed a systematic review and found the rate of asymptomatic cam deformities to be 23.1% [10]. Our findings are higher than a prior study looking at elite baseball players. In a study of professional Japanese baseball players, only 12.9% had findings of a cam-type deformity [6]. Other studies have demonstrated that the prevalence of cam deformities seems to be highly related to the sport activity [21]. Several studies have shown an increased prevalence of cam-type FAI in elite hockey and soccer athletes [2, 5].

While different types of FAI morphologies have been described, our study demonstrates that cam-type morphology is the most common morphology found in professional baseball players. Features of the cam-type morphology include an aspherical femoral head, decreased head-to-neck ratio, decreased femoral offset and femoral neck retroversion [22]. The lesion itself is typically most prominent in the anterosuperior aspect of the femoral head–neck junction [23]. Cam impingement occurs when the abnormally shaped femoral head is forced into the acetabulum causing shearing at the chondro-labral junction leading to cartilage delamination and labral injury, once again most commonly in the anterosuperior aspect of the acetabulum [12, 24, 25]. A secondary effect of the decreased head–neck offset is dynamic hip impingement which can lead to subsequent loss of motion in athletes [26, 27]. Evaluation of the cam-type morphology is best performed by calculating the  $\alpha$ -angle, which correlates with the prominence of the anterior femoral head–neck junction. This can be performed on either a frog leg lateral or a Dunn view [28, 29].

Currently, the exact cause of FAI has not been elucidated; however, many believe the origin to be an overuse phenomenon. Repetitive microtrauma in athletes with early high-level or high-frequency participation in sports may lead to poor remodeling and subsequent cam-type impingement. Disruption of the physis through repetitive trauma or abnormal loading can lead to significant effects on the morphologic development of the hip [30]. In basketball players, it was found that cam-type deformity may be preceded by an altered shape of the growth plate and associated decreased offset seen in cam deformity by epiphyseal extension rather than a reactive process [4]. Genetic factors may also play a role in the development of cam deformities [31]. Despite the theories on the origin, there seems to be a high association between cam deformities and high-level sports.

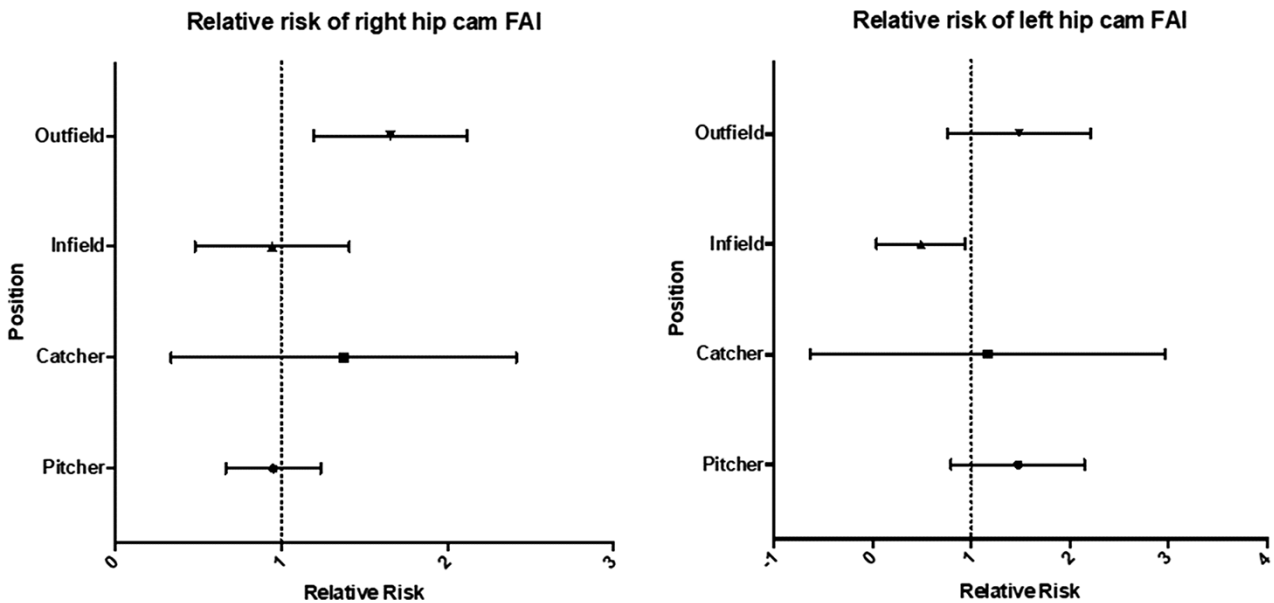
The presence of morphologic variants in baseball players has significance not only in the prevalence of cam deformities but may also play a role in altered mechanics of the lower extremities

**Table II. Patients with radiographic evidence of cam deformity, pincer deformity and hip dysplasia**

	Total	Right-sided	Left-sided	Bilateral
CAM	57/80 (71.3%)	54/80 (67.5%)	40/80 (50.0%)	37/80 (46.3%)
Pincer	41/80 (51.3%)	32/80 (40.0%)	29/80 (36.3%)	20/80 (25.0%)
Dysplasia	18/80 (22.5%)	13/80 (16.3%)	13/80 (16.3%)	8/80 (10.0%)

**Table III. Association with mean age, mean weight, mean height and mean BMI with cam morphology**

	Cam R+	Cam R-	P	Cam L+	Cam L-	P
Age	22.6 ± 3.2	20.8 ± 1.9	0.005	23.0 ± 3.4	21.1 ± 2.1	0.002
BMI	25.4 ± 2.3	24.8 ± 1.8	0.09	25.1 ± 1.9	25.3 ± 2.3	0.345
Height	73.8 ± 2.2	73.2 ± 1.9	0.128	74.1 ± 2.3	73.1 ± 1.8	0.023
Weight	197 ± 21.3	189 ± 17	0.04	196 ± 20.1	193 ± 20	0.207



**Fig. 3. Relative risk of cam morphology by position.**

**Table IV. Association of position with prevalence of cam morphology**

	Right hip Cam+ %	Left hip Cam+ %
Pitcher n = 46	65.2	56.5
Catcher n = 3	66.6	0
Infield n = 15	53.3	20
Outfield n = 16	87.5	68.7
P-value	0.003	0.007

**Table V. Prevalence of cam deformity by hitting side**

	Right hip	Left hip
Right (n = 52)	73.1	42.3
Left (n = 23)	56.5	56.5
Switch (n = 5)	60.0	60.0
P-value	0.303	0.525

and trunk leading to higher rates of injury. From 2011 to 2014, there were 1823 hip and groin injuries in MLB [20]. Decreased hip internal rotation and total arc of motion has been correlated with increased hip, groin and abdominal injuries [32]. Hip range of motion has been shown to decrease from youth to collegiate to professional levels [33]. Pitchers in particular are at risk of injury as the act of pitching a fastball approaches the maximal hip range of motion limits [34]. Alterations in hip range of motion

have also been shown to have a direct effect in upper-extremity mechanics [35] and have been identified as a risk factor for upper extremity injury [36]. Byrd and Jones noted a 75% incidence of ulnar collateral ligament elbow surgery among major league pitchers that underwent hip arthroscopy [37]. This has led to increased attention to the lumbopelvic hip complex not only in the prevention of groin and hip injuries but also in the core and upper extremity [38–40].

We found a low incidence of hip pain (7.3%) and positive anterior impingement (1.9%) in our population. One explanation



**Table VI. Prevalence of cam deformity by throwing side**

	Right hip	Left hip
Right ( <i>n</i> = 62)	71.0	48.3
Left ( <i>n</i> = 18)	55.6	55.5
<i>P</i> -value	0.172	0.394

**Table VII. Prevalence of cam deformity in pitchers, by throwing side**

	Right hip	Left hip
Right ( <i>n</i> = 35)	74.2	60.0
Left ( <i>n</i> = 11)	36.4	45.5
<i>P</i> -value	0.028	0.307

for this is because the exams were performed at Spring Training and studies have shown that strength diminishes throughout the season [41]. Another possible explanation is that players competing for a position are potentially less likely to report pain. Athletes have also been demonstrated to have a high prevalence of asymptomatic cam morphology [42]. Our study showed that the prevalence of cam-type deformities in right and left hips was 54/80 (67.5%) and 40/80 (50.0%), respectively. The mean  $\alpha$ -angle for cam-positive right and left hips was  $64.7 \pm 6.9^\circ$  and  $64.9 \pm 5.8^\circ$ , respectively. Players with cam-type impingement were older and had higher weight. Outfielder seemed to be at highest risk for cam-type deformity. RHPs had greater  $\alpha$ -angles in the right hip than their left hip. The prevalence of right hip cam deformity is greater in RHPs than LHPs. While we did not see this trend with LHPs and left hip FAI, it is unclear if there is an actual association or if our numbers were too low to detect a difference. We speculate that the difference in cam deformities may be related to differences in hip movement required for follow through or possible differences in force placed on the push off leg. The prevalence of pincer-type deformities in the right and left hips was 32/80 (40.0%) and 29/80 (36.3%). Additionally, we found that only 10% of the radiographs we analyzed were completely normal in morphology. While the origin or natural history of these deformities is not completely understood, this study demonstrates a clear difference in the prevalence of cam deformities based off a player's position and handedness. Future studies will need to be performed to assess the impact of game mechanics on the development of cam lesions. Long-term follow-up of these elite baseball players may also shed light on the impact of these lesions on player activity and the development of symptoms.

Our study's limitations include sample size, timing of evaluation and the radiographic evaluations that were utilized. With regard to sample size, although we did find a similar prevalence of radiographic FAI in this cohort compared with other groups of elite athletes, because of the reluctance to expose the asymptomatic player to unnecessary radiation, there were limitations in the number of participants. Power analysis was not performed for this study, creating the possibility of an unrecognized sample size error. Regarding timing, our ability to assess players during preseason evaluations may be limited as players may be reluctant

to identify hip pain prior to the season. As for radiographic evaluation, only the modified Dunn was used to evaluate  $\alpha$ -angle in our study. When comparing the Dunn view to the frog leg lateral, the Dunn view was found to be more sensitive and the frog to be more specific [43]. Finally, although X-rays can effectively diagnose radiographic FAI, further studies could look at labral and chondral pathology as well as version abnormalities utilizing Magnetic Resonance Imaging (MRI) and Computed Tomography (CT) radiography.

## CONCLUSIONS

Our study demonstrated that a high number of asymptomatic elite baseball players have morphologic abnormalities related to FAI when compared with the general population. While the origin and natural history of these deformities are still unclear, it is important to understand the prevalence within this population in order to guide research on adaptive and preventative interventions. A future longitudinal study may allow us to determine the impact of these findings on player activity and development of symptoms.

## DATA AVAILABILITY

The data underlying this article will be shared on reasonable request to the corresponding author.

## ACKNOWLEDGEMENT

Mauricio Elizondo.

## FUNDING

No external funding.

## CONFLICT OF INTEREST STATEMENT

None declared.

## IRB

Asentral IRB# 2016-414A.

## REFERENCES

1. Ayeni OR, Banga K, Bhandari M *et al*. Femoroacetabular impingement in elite ice hockey players. *Knee Surg Sports Traumatol Arthrosc* 2014; **22**: 920–5.
2. Gerhardt MB, Romero AA, Silvers HJ *et al*. The prevalence of radiographic hip abnormalities in elite soccer players. *Am J Sports Med* 2012; **40**: 584–8.
3. Philippon MJ, Ho CP, Briggs KK *et al*. Prevalence of increased alpha angles as a measure of cam-type femoroacetabular impingement in youth ice hockey players. *Am J Sports Med* 2013; **41**: 1357–62.
4. Siebenrock KA, Behning A, Mamisch CT *et al*. Growth plate alteration precedes cam-type deformity in elite basketball players. *Clin Orthop Relat Res* 2013; **471**: 1084–91.
5. Lerebours F, Robertson W, Neri B *et al*. Prevalence of cam-type morphology in elite ice hockey players. *Am J Sports Med* 2016; **44**: 1024–30.
6. Fukushima K, Takahira N, Imai S *et al*. Prevalence of radiological findings related to femoroacetabular impingement in professional baseball players in Japan. *J Orthop Sci* 2016; **21**: 821–5.
7. Burnett RS, Rocca GJD, Prather H *et al*. Clinical presentation of patients with tears of the acetabular labrum. *J Bone Joint Surg Am* 2006; **88**: 1448–57.

8. Hale RF, Melugin HP, Zhou J *et al.* Incidence of femoroacetabular impingement and surgical management trends over time. *Am J Sports Med* 2021; **49**: 35–41.
9. Zusmanovich M, Haselman W, Serrano B *et al.* The incidence of hip arthroscopy in patients with femoroacetabular impingement syndrome and labral pathology increased by 85% between 2011 and 2018 in the United States. *Arthroscopy* 2022; **38**: 82–7.
10. Frank JM *et al.* Prevalence of femoroacetabular impingement imaging findings in asymptomatic volunteers: a systematic review. *Arthroscopy* 2015; **31**: 1199–204.
11. Hack K, Di Primio G, Rakhra K *et al.* Prevalence of cam-type femoroacetabular impingement morphology in asymptomatic volunteers. *J Bone Joint Surg Am* 2010; **92**: 2436–44.
12. Ganz R, Parvizi J, Beck M *et al.* Femoroacetabular impingement: a cause for osteoarthritis of the hip. *Clin Orthop Relat Res* 2003; **417**: 112–20.
13. Kapron AL, Anderson AE, Aoki SK *et al.* Radiographic prevalence of femoroacetabular impingement in collegiate football players: AAOS Exhibit Selection. *J Bone Joint Surg Am* 2011; **93**: e111 (1–10).
14. Leunig M, Jüni P, Werlen S *et al.* Prevalence of cam- and pincer-type deformities on hip MRI in an asymptomatic young Swiss female population: a cross-sectional study. *Osteoarthritis Cartilage* 2013; **21**: 544–50.
15. Agricola R, Bessems JHJM, Ginai AZ *et al.* The development of cam-type deformity in adolescent and young male soccer players. *Am J Sports Med* 2012; **40**: 1099–106.
16. Harris-Hayes M, Royer NK. Relationship of acetabular dysplasia and femoroacetabular impingement to hip osteoarthritis: a focused review. *PM R* 2011; **3**: 1055–67 e1.
17. Chaudhry H, Ayeni OR. The etiology of femoroacetabular impingement: what we know and what we don't. *Sports Health* 2014; **6**: 157–61.
18. Siebenrock KA, Ferner F, Noble PC *et al.* The cam-type deformity of the proximal femur arises in childhood in response to vigorous sporting activity. *Clin Orthop Relat Res* 2011; **469**: 3229–40.
19. Mlynarek RA, Coleman SH. Hip and groin injuries in baseball players. *Curr Rev Musculoskelet Med* 2018; **11**: 19–25.
20. Coleman SH, Mayer SW, Tyson JJ *et al.* The epidemiology of hip and groin injuries in professional baseball players. *Am J Orthop (Belle Mead NJ)* 2016; **45**: 168–75.
21. Lee WY, Kang C, Hwang D-S *et al.* Descriptive epidemiology of symptomatic femoroacetabular impingement in young athlete: single center study. *Hip Pelvis* 2016; **28**: 29–34.
22. Schoeneker PL, Clohisy JC, Millis MB *et al.* Surgical management of the problematic hip in adolescent and young adult patients. *J Am Acad Orthop Surg* 2011; **19**: 275–86.
23. Sutter R, Dietrich TJ, Zingg PO *et al.* How useful is the alpha angle for discriminating between symptomatic patients with cam-type femoroacetabular impingement and asymptomatic volunteers? *Radiology* 2012; **264**: 514–21.
24. Parvizi J, Leunig M, Ganz R. Femoroacetabular impingement. *J Am Acad Orthop Surg* 2007; **15**: 561–70.
25. Ito K, Minka-II M-A, Leunig M *et al.* Femoroacetabular impingement and the cam-effect. A MRI-based quantitative anatomical study of the femoral head-neck offset. *J Bone Joint Surg Br* 2001; **83**: 171–6.
26. Yuan BJ, Bartelt RB, Levy BA *et al.* Decreased range of motion is associated with structural hip deformity in asymptomatic adolescent athletes. *Am J Sports Med* 2013; **41**: 1519–25.
27. Notzli HP, Wyss TF, Stoecklin CH *et al.* The contour of the femoral head-neck junction as a predictor for the risk of anterior impingement. *J Bone Joint Surg Br* 2002; **84**: 556–60.
28. Clohisy JC, Nunley RM, Otto RJ *et al.* The frog-leg lateral radiograph accurately visualized hip cam impingement abnormalities. *Clin Orthop Relat Res* 2007; **462**: 115–21.
29. Meyer DC, Beck M, Ellis T *et al.* Comparison of six radiographic projections to assess femoral head/neck asphericity. *Clin Orthop Relat Res* 2006; **445**: 181–5.
30. Ng VY, Ellis TJ. More than just a bump: cam-type femoroacetabular impingement and the evolution of the femoral neck. *Hip Int* 2011; **21**: 1–8.
31. Pollard TC, Villar RN, Norton MR *et al.* Genetic influences in the aetiology of femoroacetabular impingement: a sibling study. *J Bone Joint Surg Br* 2010; **92**: 209–16.
32. Li X, Ma R, Zhou H *et al.* Evaluation of hip internal and external rotation range of motion as an injury risk factor for hip, abdominal and groin injuries in professional baseball players. *Orthop Rev (Pavia)* 2015; **7**: 6142.
33. Cheatham SW, Shimamura KK, Kolber MJ. Differences in hip range of motion among collegiate pitchers when compared to youth and professional baseball pitcher data. *J Can Chiropr Assoc* 2016; **60**: 233–40.
34. Crawford EA, Whiteside D, Deneweth JM *et al.* In vivo hip morphology and kinematics in elite baseball pitchers. *Arthroscopy* 2016; **32**: 798–805.
35. Laudner K, Wong R, Onuki T *et al.* The relationship between clinically measured hip rotational motion and shoulder biomechanics during the pitching motion. *J Sci Med Sport* 2015; **18**: 581–4.
36. Saito M, Kenmoku T, Kameyama K *et al.* Relationship between tightness of the hip joint and elbow pain in adolescent baseball players. *Orthop J Sports Med* 2014; **2**: 2325967114532424.
37. Byrd JW, Jones KS. Hip arthroscopy in high-level baseball players. *Arthroscopy* 2015; **31**: 1507–10.
38. Erickson BJ, Sgori T, Chalmers PN *et al.* The impact of fatigue on baseball pitching mechanics in adolescent male pitchers. *Arthroscopy* 2016; **32**: 762–71.
39. Wilk KE, Arrigo CA, Hooks TR *et al.* Rehabilitation of the overhead throwing athlete: there is more to it than just external rotation/internal rotation strengthening. *PM R* 2016; **8**: S78–90.
40. Oliver GD, Weimar W. Hip range of motion and scapula position in youth baseball pitching pre and post simulated game. *J Sports Sci* 2015; **33**: 1447–53.
41. Zeppieri G Jr, Lentz TA, Moser MW *et al.* Changes in hip range of motion and strength in collegiate baseball pitchers over the course of a competitive season: a pilot study. *Int J Sports Phys Ther* 2015; **10**: 505–13.
42. Silvis ML, Mosher TJ, Smetana BS *et al.* High prevalence of pelvic and hip magnetic resonance imaging findings in asymptomatic collegiate and professional hockey players. *Am J Sports Med* 2011; **39**: 715–21.
43. Nepple JJ, Martel JM, Kim Y-J *et al.* Do plain radiographs correlate with CT for imaging of cam-type femoroacetabular impingement? *Clin Orthop Relat Res* 2012; **470**: 3313–20.