

## Case Report

# Internal Iliac Aneurysm Causing Hydroureteronephrosis

Tawfeeq Sangey<sup>1</sup> and Sibtain Moledina<sup>2</sup>

<sup>1</sup>Regency Medical Centre, Tanzania

<sup>2</sup>Shree Hindu Mandal Hospital, Tanzania

Correspondence should be addressed to Sibtain Moledina; sibumole@hotmail.com

Received 20 April 2020; Revised 27 October 2020; Accepted 4 November 2020; Published 16 November 2020

Academic Editor: Atsushi Komemushi

Copyright © 2020 Tawfeeq Sangey and Sibtain Moledina. This is an open access article distributed under the Creative Commons Attribution License, which permits unrestricted use, distribution, and reproduction in any medium, provided the original work is properly cited.

A 63-year-old presented with right lumbar pain and increased frequency of urination. Imaging revealed right internal iliac artery aneurysm causing hydroureteronephrosis and compressing the urinary bladder.

## 1. Case Presentation

A 63-year-old male presented at the urology clinic with complaints of right lumbar pain and increased frequency of urination. He carried a recent ultrasound exam showing a grade 2 right ureterohydronephrosis. A repeat ultrasound scan was performed. B-mode ultrasound demonstrated a large saccular type of lesion with a thick pulsating wall connected by feeding artery arising from the right iliac artery and intramural thrombus formation. Colour mode ultrasound confirmed the turbulent blood flow within the aneurysm. The prostate was mildly enlarged at 34 grams associated with a moderate residual volume of 61 cc. CT-IVU confirmed the right ureterohydronephrosis with an anteroposterior diameter of the renal pelvis of 15 mm (Figure 1). There was no evidence of renal or ureteric stones. A right internal iliac artery aneurysm was noted at the level of L4/L5 vertebra bodies measuring  $6.7 \times 6.0 \times 6.05$  cm (AP  $\times$  trans  $\times$  Sag) (Figure 2), and the right ureter was moderately dilated to the level of the right internal iliac aneurysm (Figure 3), which was possibly the cause of the obstruction.

The urinary bladder was superiorly compressed and laterally pushed on the left iliac fossa region by the aneurysm.

The patient was planned for surgical intervention and transferred to a specialized facility for surgery. Unfortunately, the patient succumbed to the illness while waiting for surgery due to rupture of the aneurysm,

## 2. Discussion

Aneurysms of the iliac arteries are found considerably less often. Most of the internal iliac artery (IIA) aneurysms occur in association with other intra-abdominal aneurysms (abdominal aorta, common, infrarenal, and iliac arteries) making up part of the polyaneurysm disease [1].

The incidence of iliac artery in conjunction with aneurysms of the abdominal aorta is approximately 10% but isolated iliac aneurysms are rare and occur in only 2% [2].

The majority of patients are elderly aged 65–75 years and commonly seen in males with a ratio 6 times more than in females [3].

IIA aneurysms are usually asymptomatic, due to the deep location of the internal iliac artery and can occur in the retroperitoneal or intraperitoneal spaces, compressing the rectum, ureter, or bladder triggering urological, gastroenterological, and neurological symptoms [4–6].

Compression of the ureter and bladder triggering the urinary symptoms has also been reported [7, 8].

Due to their deep location in the pelvis and the fact that they often are asymptomatic, diagnosis is often delayed until the aneurysm is of a significant size producing symptoms or coincidentally found by radiological imaging for other reasons.

The incidence of rupture is high and may be up to 38% at initial presentation. This has been reported to carry a 58%

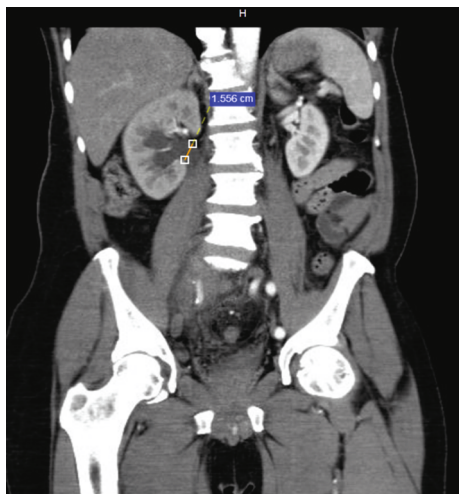


FIGURE 1: CT-IVU showing the right sided hydronephrosis

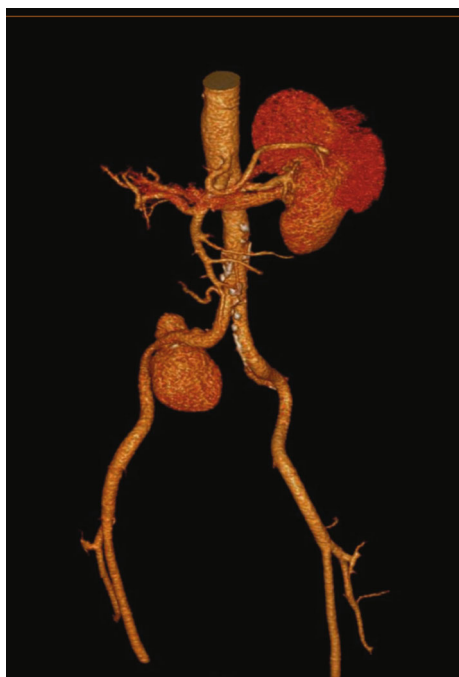

FIGURE 2: Multiplanar reformatted images show right internal iliac artery aneurysm just past the iliac bifurcation.

mortality rate [9]. The mean diameter of the aneurysm at the time of rupture is almost 7 cm delaying operative treatment until a diameter of 4 cm may be safe.

Ultrasound is useful in an initial investigation as it depicts the ureterohydronephrosis and other urinary track complications. With colour-flow Doppler, the blood flow within an aneurysm can be confirmed [10].

Helical computed angiography is the gold standard, showing the site, size, tortuosity, path, relationship with adjacent organs, signs of rupture, and retroperitoneal hemorrhage [4, 6, 11].

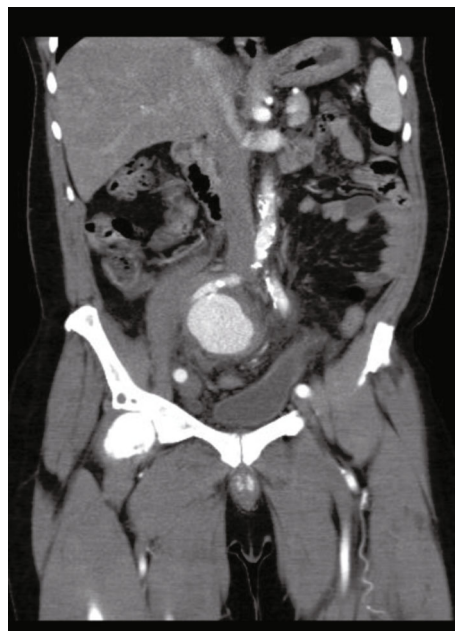

FIGURE 3: Contrast-enhanced CT scan of the abdomen and pelvis, with coronal images showing a large contrast-filled structure in keeping with iliac artery aneurysm compressing and pushing the urinary bladder laterally.

### Data Availability

Data supporting the information in this case report are in the patient files which are the property of the hospital where he was seen.

### Conflicts of Interest

The authors declare that they have no conflicts of interest.

### References

- [1] S. Métairie, F. Denimal, I. Floch et al., "Rupture of internal iliac artery aneurysm into the bladder following aortic aneurysm repair," *Annals of Vascular Surgery*, vol. 15, no. 6, pp. 693–695, 1992.
- [2] J. W. Richardson and L. J. Greenfield, "Natural history and management of iliac aneurysms," *Journal of Vascular Surgery*, vol. 8, no. 2, pp. 165–171, 1988.
- [3] R. M. Machado, D. N. Rego, P. N. Oliveira, and R. M. Almeida, "Endovascular treatment of internal iliac artery aneurysms: single center experience," *Brazilian Journal of Cardiovascular Surgery*, vol. 31, no. 2, pp. 127–131, 2016.
- [4] Jesus-Silva SG, M. A. M. Silva, M. V. Figueiredo, G. F. T. Okamoto, and R. S. Cardoso, "Aneurisma Isolado de Artérias Ilíacas - Relato de Caso / Isolated Iliac Artery Aneurysm - Case Report," *Revista Ciências Em Saúde*, vol. 6, no. 1, pp. 59–65, 2016.
- [5] S. J. Srirangam, R. Manikandan, D. Ross, and G. N. Collins, "Uretericobstruction caused by aneurysm of the hypogastric artery," *Scandinavian Journal of Urology and Nephrology*, vol. 37, pp. 364–365, 2009.

- [6] C. T. Afonso, R. J. Procópio, T. P. Navarro, G. H. D. Kleinsorge, B. D. S. Rodrigues, and M. A. G. Rodrigues, "Aneurisma de artéria ilíaca interna roto: relato de caso," *Jornal Vascular Brasileiro*, vol. 8, no. 1, pp. 92–96, 2009.
- [7] K. Mineta, M. Nomura, N. Fujimoto, K. Takahashi, and T. Matsumoto, "Ureteral obstruction due to retroperitoneal fibrosis secondary to a solitary internal iliac aneurysm," *International Journal of Urology*, vol. 11, no. 11, pp. 1024–1027, 2004.
- [8] D. O'Driscoll and E. Fitzgerald, "Isolated iliac artery aneurysms with associated hydronephrosis," *Journal of the Royal College of Surgeons of Edinburgh*, vol. 44, no. 3, pp. 197–199, 1999.
- [9] D. J. Parry, D. Kessel, and D. J. Scott, "Simplifying the internal iliac artery aneurysm," *Annals of the Royal College of Surgeons of England*, vol. 83, no. 5, pp. 302–308, 2001.
- [10] F. P. Dix, M. Titi, and H. Al-Khaffaf, "The isolated internal iliac artery aneurysm - a review," *European Journal of Vascular and Endovascular Surgery*, vol. 23, no. 2, pp. 170–175, 2005.
- [11] E. A. S. Góis, M. M. Barbosa, and P. GBB, "Aneurisma da artéria ilíaca interna corrigido por embolização e endoprótese," *Perspectivas Médicas*, vol. 21, no. 1, pp. 38–40, 2010.