


# Differences in Cross-Sectional Intervertebral Foraminal Area From C3 to C7

Global Spine Journal  
2018, Vol. 8(6) 600-606  
© The Author(s) 2018  
Article reuse guidelines:  
sagepub.com/journals-permissions  
DOI: 10.1177/2192568218758085  
journals.sagepub.com/home/gsj



Derrick M. Knapik, MD<sup>1,2</sup>, Matthew V. Abola, BA<sup>2</sup> ,  
Zachary L. Gordon, MD<sup>1,2</sup>, John G. Seiler, MD<sup>3</sup>,  
Randall E. Marcus, MD<sup>1,2</sup>, and Raymond W. Liu, MD<sup>1,2</sup>

## Abstract

**Study Design:** Anatomical comparative study.

**Objectives:** Few studies have evaluated foraminal areas in the cervical spine without degenerative changes. The purpose of this study was to determine and compare the mean cross-sectional foraminal areas between the C3/4, C4/5, C5/6, and C6/7 levels while also analyzing specimens for differences between sexes and races.

**Methods:** We performed an anatomic study of the intervertebral foramen at 4 levels (C3/4, C4/5, C5/6, C6/7) in 100 skeletally mature osseous specimens. Specimens were selected to obtain equal number of African American and Caucasian males and females ( $n = 25/\text{group}$ ) aged 20 to 40 years at time of death. Foramina were photographed bilaterally with and without a silicone rubber disc. The maximal vertical height and mid-sagittal width of each foramen were digitally measured and the areas were calculated using an ellipse as a model.

**Results:** The average age at death for all specimens was  $30 \pm 6$  years. The mean cross-sectional area of the C4/5 foramen was significantly smaller compared with the C5/6 ( $P < .001$ ). C5/6 was significantly narrower than C6/7 ( $P < .001$ ) foramen with and without disc augmentation. C3/4 was not significantly different from more caudal levels. There was no difference between male and female specimens, while African Americans had smaller foraminal sizes than Caucasians.

**Conclusions:** This study provides the largest anatomical reference of the cervical intervertebral foramen. In a mature spine without facet joint hypertrophy or osteophytic changes, the C4/5 foramen was narrower than C5/6, which was narrower than C6/7. Understanding the relative foraminal areas in the nonpathological cervical spine is crucial to understanding degenerative changes as well as the anatomical changes in pathologies that affect the intervertebral foramen.

## Keywords

cervical nerve root neurapraxia, intervertebral foramen, cervical spine, cervical anatomy, C5 palsy

## Introduction

The intervertebral foramen has been the focus of several anatomical studies exploring traumatic and degenerative radiculopathy in the cervical spine. Stenosis of the intervertebral foramen has been cited as a key contributory factor in pathologies such as postoperative C5 palsy and transient neurapraxia in athletes.<sup>1-6</sup> Multiple studies have evaluated the foramen in dynamic models and found that the cross-sectional area of the intervertebral foramen changes with flexion and extension of the cervical spine.<sup>7-10</sup> Specifically, increasing degrees of flexion lead to widening of the foraminal area and conversely, increasing degrees of extension lead to foraminal area narrowing.<sup>7-10</sup>

Few studies have extensively evaluated foraminal areas in young adults. Current studies evaluating foraminal areas in the cervical spine have focused on small samples sizes of elderly patients or cadaveric models.<sup>11,12</sup> The area of the intervertebral foramen is particularly sensitive to degenerative changes and

<sup>1</sup> University Hospitals Case Medical Center, Cleveland, OH, USA

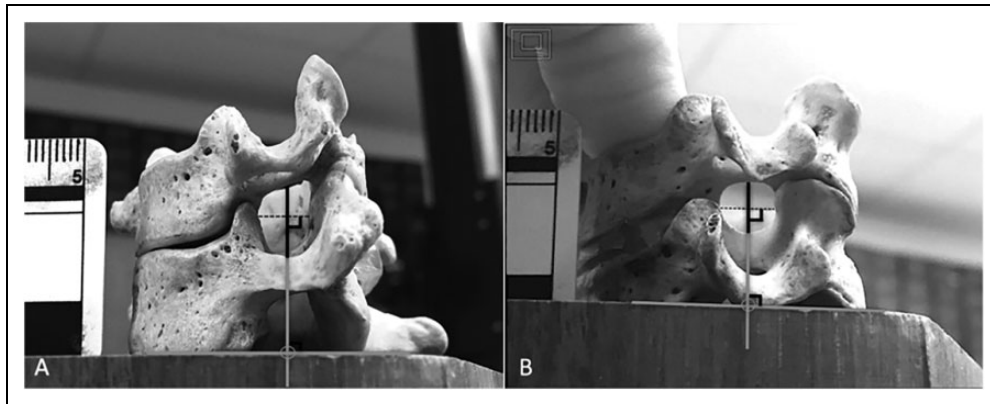
<sup>2</sup> Case Western Reserve University School of Medicine, Cleveland, OH, USA

<sup>3</sup> Georgia Hand Shoulder Elbow, Atlanta, GA, USA

### Corresponding Author:

Matthew V. Abola, Case Western Reserve University School of Medicine,  
10900 Euclid Avenue, Cleveland, OH 44106-4920, USA.  
Email: matthew.abola@case.edu





**Figure 1.** Set up of vertebrae without (A) and with (B) silicone disc augmentation demonstrating digital measurements of maximal vertical heights (solid line) and mid-sagittal width (dotted line) of the foramina.

can be drastically altered by facet hypertrophy or disc degeneration, both of which are common in elderly patients and may alter true foraminal dimensions.<sup>13-15</sup> Our study aims to improve on the existing literature by evaluating a large sample size of young cadaveric specimens to provide more accurate anatomical values. The purpose of this study was to characterize the osseous morphology of the cervical intervertebral foramen most commonly involved in radiculopathies and neurapraxias of the cervical nerve roots. Specifically, we sought to determine and compare the mean cross-sectional foraminal areas between the C3/4, C4/5, C5/6, and C6/7 levels while also analyzing specimens for differences between sexes and races (Caucasian vs African Americans).

## Materials and Methods

We examined 100 skeletally mature osseous specimens from the Hamann-Todd Osteologic Collection located at the Cleveland Museum of Natural History. A total of 800 intervertebral foramina ( $n = 500$  vertebrae) were analyzed between randomly selected African American and Caucasian males and females ( $n = 25$ /group). Inclusion criteria included intact C3, C4, C5, C6, and C7 vertebrae and foramen from human skeletons aged 20 to 40 years at the time of death. Specimens were randomly chosen, but consideration was made to select an equal number between ages 20 to 25, 26 to 30, 31 to 35, and 36 to 40 years. Exclusion criteria included specimens with evidence of foraminal narrowing secondary to arthritic changes, significant loss of bony anatomy due to damage following years of storage and handling that prevented accurate positioning, or vertebrae with evidence of prior cervical laminectomy or ankylosis.

Digital photographs were obtained of the intervertebral foramen one intervertebral level at a time. Vertebrae were positioned such that the superior vertebrae were placed onto the inferior vertebrae, which sat flush on a level surface. Anatomic disc space height was recreated and photographed using a silicone disc of appropriate diameter and thickness inserted between vertebral bodies (Figure 1), as validated in a previous anatomic investigation.<sup>16</sup> Vertebral congruency was

reproduced by articulating the superior and inferior uncovertebral and facet joints with the assistance of slight downward pressure applied by hand to the superior vertebral body.

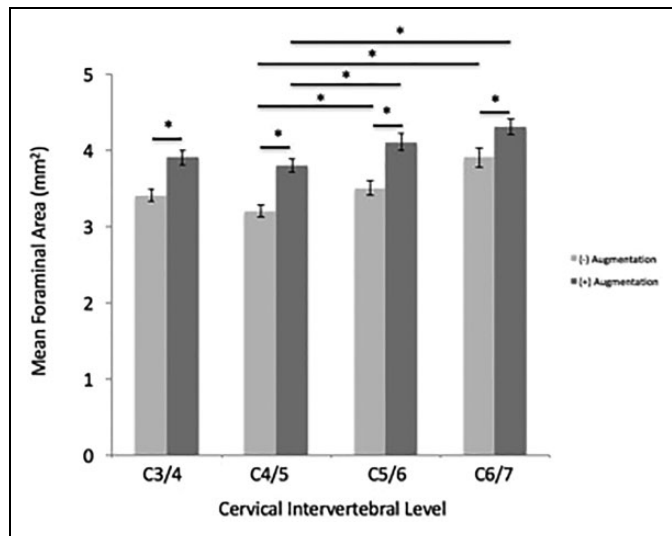
At each intervertebral level bilaterally, digital measurements of the maximal vertical foraminal height (Figure 1, solid line) was measured orthogonal to the table surface, and the mid-sagittal width (Figure 1, dotted line) parallel to the table surface. In Image J, a line was first drawn along the table edge. A perpendicular line to the table edge was then drawn from the table edge through the intervertebral foramen, which included the maximal vertical foraminal height. The maximal vertical foraminal height was then measured and from its midpoint, the mid-sagittal width was measured perpendicular to this height. Digital measurements were performed and recorded using Image J software (version 1.49, National Institutes of Health, Bethesda, MD). A No. 2 photomacrographic scale was used to calibrate measurements for each image and placed in the same plane as the foramen, equidistant to the camera. Using an ellipse as a model of 3-dimensional foraminal shape, measurements were used to calculate mean cross-sectional area of the foramina.

To establish interobserver reliability, 5 specimens ( $n = 30$  intervertebral foramen) were randomly chosen, and then independently positioned, photographed, and measured by 2 authors. Intraclass correlation coefficients (ICCs) were calculated between measurements using the SPSS statistical package (IBM Corporation, Armonk, NY). Following established recommendations, we considered an ICC of  $<0.4$  to be poor,  $0.4$  to  $0.75$  to be fair to good, and  $>0.75$  to be excellent.<sup>17,18</sup> In a study by Humphreys et al,<sup>15</sup> the authors calculated an average C4/5 foraminal area of  $0.364 \text{ cm}^2$  and an average C5/6 foraminal area of  $0.278 \text{ cm}^2$ .<sup>15</sup> With an estimated standard deviation of  $0.09$ , alpha of  $.05$ , and power level of  $80\%$ , estimated sample size was  $34$ . Standard deviation was derived from our own population since there are no published comparisons or standard deviations of foraminal area.

Foraminal areas on the right and left sides were averaged and the mean and standard deviation calculated. Variations in mean foraminal areas between sexes and races at each level

**Table 1.** Mean Age at the Time of Death for Specimens According to Sex and Race (N = 25 Specimens/Group).

	African American Males	Caucasian Males	African-American Female	Caucasian Females	Mean Total
Age, years, mean $\pm$ SD	29.2 $\pm$ 6.1	31.0 $\pm$ 6.7	30.5 $\pm$ 5.9	30.1 $\pm$ 5.8	30.2 $\pm$ 6.3

**Figure 2.** Graph showing differences in mean cross-sectional foraminal area at each tested cervical level with and without disc augmentation. \*Denotes statistical significance ( $P < .05$ ).

were analyzed using an unpaired  $t$  test. Multivariable linear regression models and 1-way repeated-measures analysis of variance (ANOVA) with post hoc tests as appropriate was conducted to compare foraminal areas between C3/4, C4/5, C5/6, and C6/7 overall and between sexes and races. Multicollinearity was determined acceptable based on a variable inflation factor of less than 10, and when independent variables had a 0.7 or larger correlation with each other, one was removed from the analysis. Differences were considered to be significant at a probability level of 95% ( $P < .05$ ). All statistical analysis was performed using SPSS (Version 23, IBM, Armonk, NY) software. This study was exempt from institutional review board approval.

## Results

Mean age of death for all specimens was  $30 \pm 6$  years (Table 1). Interobserver ICC for foraminal measurements was excellent with a calculated value of 0.87.

### Differences in Mean Cross-Sectional Foraminal Areas According to Cervical Levels

One-way repeated-measures ANOVA showed the mean cross-sectional area at the C4/5 foramen was significantly smaller compared with C5/6 ( $P < .001$ ) and C6/7 ( $P < .001$ ) but not C3/4 ( $P = .85$ ) (Figure 2). This finding was observed in both adjusted and unadjusted models. No demonstrable physical change within the foramen between specimens was visible,

as specimens with any evidence of osteophyte formation or narrowing secondary to arthritic changes within the foramen were excluded.

Results from our multivariable, linear regression analysis are reported in Table 2 (without disc augmentation) and Table 3 (with disc augmentation). For both adjusted and unadjusted models, C5/6 is a significant predictor of C4/5 (without, unstandardized beta = 0.457,  $P < .001$ ; with, unstandardized beta = 0.529,  $P < .001$ ). Additionally, we found the foraminal size of C6/7 to be a predictor of C5/6 (without, unstandardized beta = 0.174,  $P = .005$ ; with, unstandardized beta = 0.50,  $P < .001$ ).

### Differences in Mean Cross-Sectional Foraminal Area According to Sex

There was no statistically significant difference between males and female cross-sectional foraminal area at C3/4 ( $P = .45$ ), C4/5 ( $P = .40$ ), C5/6 ( $P = .56$ ), or C6/7 ( $P = .13$ ) (Figure 3). These findings were replicated in our multivariable regression analysis.

### Differences in Mean Cross-Sectional Foraminal Area According to Race

Caucasians had a significantly greater mean cross-sectional foraminal area at C4/5 ( $P = .02$ ), C5/6 ( $P = .05$ ), and C6/7 ( $P = .02$ ), but not C3/4 ( $P = .66$ ) when compared with African Americans (Figure 4). These results were not replicated in our multivariable linear regression models, with the suspicion that the effect of race dropped out when adjacent levels were incorporated. Indeed, when the multiple regression was run with only sex, age, and race as the independent variables the significant association between foramina width and race was significant at each level.

## Discussion

The principal finding from our analysis of 500 cervical vertebrae from young adult cadavers was that the C4/5 foramen was narrower than the more caudal levels at C5/6 and C6/7, however not cranially at C3/4. There were no significant differences between genders, while Caucasians had significantly larger areas than African Americans at C4/5, C5/6, and C6/7.

Our study sought to provide a large anatomical control of the cervical intervertebral foramen in young cadaveric models. We choose specimens without signs of significant degenerative changes (eg, osteophytes) as this can drastically alter the foraminal dimensions.<sup>13-15</sup> Furthermore, our analysis included foraminal comparisons by sex and race as data regarding these were limited in the previous literature. This data is relevant to many commonly occurring clinical conditions, such as

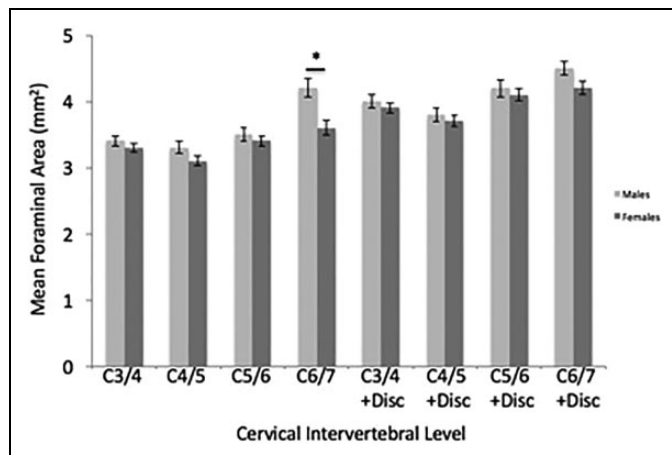
**Table 2.** Multivariable Regression Analysis of Variables on Each Cervical Level (Without Disc Augmentation).

	Unstandardized beta	95% Confidence Interval	Standardized beta	P
Dependent variable: C3/4				
Sex	-0.007	(-0.035, 0.021)	-0.043	.642
Age	-0.003	(-0.005, -0.001)	-0.223	.014
Race	0.008	(-0.02, 0.036)	0.053	.572
C4/5	0.378	(0.15, 0.607)	0.407	.001
C5/6	0.107	(-0.102, 0.316)	0.131	.311
C6/7	-0.033	(-0.162, 0.095)	-0.056	.607
Dependent variable: C4/5				
Sex	-0.003	(-0.027, 0.021)	-0.018	.81
Age	0	(-0.002, 0.002)	0.033	.653
Race	-0.006	(-0.03, 0.019)	-0.033	.651
C3/4	0.275	(0.109, 0.442)	0.256	.001
C5/6	0.457	(0.304, 0.609)	0.521	<.001
C6/7	0.08	(-0.028, 0.188)	0.124	.147
Dependent variable: C5/6				
Sex	0.01	(-0.018, 0.037)	0.051	.491
Age	0.001	(-0.001, 0.003)	0.08	.279
Race	-0.013	(-0.041, 0.014)	-0.071	.34
C3/4	0.103	(-0.098, 0.304)	0.084	.311
C4/5	0.605	(0.403, 0.806)	0.53	<.001
C6/7	0.174	(0.053, 0.295)	0.236	.005
Dependent variable: C6/7				
Sex	-0.054	(-0.097, -0.01)	-0.209	.017
Age	$2.53 \times 10^{-5}$	(-0.004, 0.004)	0.001	.989
Race	-0.034	(-0.079, 0.011)	-0.132	.139
C3/4	-0.086	(-0.416, 0.244)	-0.051	.607
C4/5	0.282	(-0.101, 0.665)	0.182	.147
C5/6	0.464	(0.141, 0.786)	0.341	.005

**Table 3.** Multivariable Regression Analysis of Variables on Each Cervical Level (With Disc Augmentation).

	Unstandardized beta	95% Confidence Interval	Standardized beta	P
Dependent variable: C3/4 <sup>a</sup>				
Sex	-0.007	(-0.038, 0.025)	-0.04	.664
Age	-0.003	(-0.006, -0.001)	-0.232	.014
Race	0.006	(-0.026, 0.039)	0.037	.699
C4/5	0.126	(-0.112, 0.364)	0.136	.297
C5/6	0.251	(0.053, 0.449)	0.32	.014
Dependent variable: C4/5 <sup>a</sup>				
Sex	-0.008	(-0.035, 0.019)	-0.044	.545
Age	0.001	(-0.001, 0.004)	0.094	.215
Race	-0.019	(-0.046, 0.008)	-0.103	.171
C3/4	0.092	(-0.082, 0.266)	0.085	.297
C5/6	0.529	(0.391, 0.666)	0.626	<.001
Dependent variable: C5/6				
Sex	0.013	(-0.013, 0.039)	0.058	.338
Age	0	(-0.002, 0.003)	0.028	.655
Race	0.006	(-0.021, 0.033)	0.027	.666
C3/4	0.126	(-0.041, 0.293)	0.099	.138
C4/5	0.516	(0.35, 0.682)	0.436	<.001
C6/7	0.5	(0.354, 0.645)	0.48	<.001
Dependent variable: C6/7				
Sex	-0.023	(-0.053, 0.007)	-0.109	.13
Age	0	(-0.002, 0.003)	0.02	.79
Race	-0.024	(-0.054, 0.007)	-0.112	.13
C3/4	0.084	(-0.111, 0.278)	0.068	.394
C4/5	-0.064	(-0.292, 0.163)	-0.057	.575
C5/6	0.665	(0.471, 0.859)	0.692	<.001

<sup>a</sup>C6/7 omitted due to multicollinearity with C5/6.

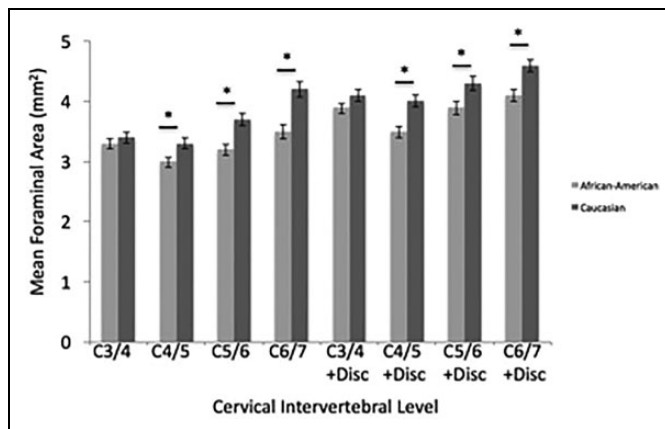


**Figure 3.** Differences in mean foraminal area with and without disc augmentation based on sex. \*Denotes statistical significance ( $P < .05$ ).

degenerative radiculopathy, C5 nerve root palsy, and transient neurapraxia.

Relative foraminal narrowing at C4/5 when compared with C5/6 and C6/7 has been previously corroborated in a cadaveric study by Ebraheim et al.<sup>11</sup> Analyzing 14 intact cervical spines, from C1-T8, Ebraheim et al<sup>11</sup> reported increasing foraminal height and width from C3 to C7. With intact soft tissue structures, each spinal specimen was positioned at a Cobb angle of 30° to preserve anatomic cervicothoracic lordosis.<sup>11</sup> Unlike the study results of Ebraheim et al, our study did not find any statistically significant difference between C3/4 and C4/5. This may be due to the difference in cadaver age populations as our study focused exclusively on young cadavers, aged 20 to 40 years, while Ebraheim et al<sup>11</sup> analyzed older cadavers aged 62 to 78 years. In older specimens, degenerative changes, most notably inferior facet hypertrophy, has been shown to decrease the width of the foramen, and subsequent area for the passing nerve root.<sup>15</sup> Additionally, in 2 separate cadaveric studies, Lu et al<sup>14</sup> and Sohn et al<sup>13</sup> found disc degeneration to be significantly correlated with decreases in foraminal area. Our study adds to the current literature and eliminates the potential confounding effects of facet hypertrophy and foraminal-narrowing secondary to disc degeneration by focusing exclusively on a younger patient population with placement of silicone discs to recreate the anatomy of the intervertebral disc.

Analysis of the cervical intervertebral foramen has also been undertaken in patients with cervical spondylotic myelopathy (CSM). In an analysis of 44 patients aged 42 to 84 years with CSM, Hegazy et al<sup>12</sup> used computed tomography (CT) imaging to calculate the foraminal area of C3/4, C4/5, C5/6, C6/7. The authors found no difference between levels or sex.<sup>12</sup> While this study was conducted in patients with CSM, we believe that a cadaveric model gives a clearer picture of the foramen than that which can be afforded by imaging. A high-resolution CT scan with 1-mm cuts in a particular plane can miss the optimal angle necessary to evaluate the cross-sectional area of the foramen, which, in the authors' experience, was best visualized from an inferolateral position



**Figure 4.** Differences in mean foraminal area with and without augmentation based on race. \*Denotes statistical significance ( $P < .05$ ).

relative to the foramen. Using cadaveric specimens, we were able to position the camera such that we could obtain the best view of the foramen, that is, where the camera lens and cross-sectional plane of the foramen were parallel.

In our stratified analysis, no statistically significant difference was found between genders. The only prior study evaluating sex difference between intervertebral foramen width by Rühli et al<sup>19</sup> using cadavers aged 20 to 60+ years and born between 1772 and 1837 found no difference in C3 or C7 between male and female cadaveric specimens. Although the vertebrae used by Rühli et al<sup>19</sup> were significantly older, the lack of sexual dimorphism in cervical foraminal area has also replicated in the aforementioned studies by Ebraheim et al<sup>11</sup> and Hegazy et al.<sup>12</sup>

Our study is also the first to evaluate potential differences between foraminal areas in Caucasians and African Americans. Race was a significant factor in our univariate analysis but not our multivariate analysis. This likely occurred due to the inclusion of adjacent cervical levels in our multivariate analysis, as these most likely overlapped with the effects of race. Indeed, when we ran multiple regression analyses with race, gender and age as the independent variables and each cervical level as the dependent variables race remained statistically significant.

The impact of cervical intervertebral dimensions on cervical nerve root palsies has also been examined in the surgical population. A systematic review examining 25 studies found that patients with narrow cervical intervertebral foramina seen on preoperative imaging were at significantly higher risk for C5 palsy following posterior cervical decompression (SMD,  $-0.972$ ; 95% CI,  $-1.398$  to  $-0.545$ ).<sup>1</sup> Others have corroborated this finding by demonstrating the impact of prophylactic foraminotomy following surgical decompression. Namely, Katsumi et al<sup>5</sup> examined 141 consecutive patients undergoing open-door laminoplasty for cervical myelopathy with or without prophylactic bilateral C4/5 foraminotomy. The authors reported in patients with prophylactic foraminotomy, there was a significantly lower incidence of C5 palsy postoperatively when compared with those without prophylactic foraminotomy (1.4% vs 6.4%,  $P < .05$ ). Komagate et al<sup>20</sup> further demonstrated

that bilateral partial foraminotomies prophylactically were effective in significantly decreasing the risk of C5 nerve palsy ( $P < .05$ ) following cervical expansive laminoplasty for spondylotic myelopathy or ossification of the posterior longitudinal ligament in 305 patients. By increasing the dimensions of the intervertebral foramen at C4/5, postoperative nerve palsies were significantly reduced, further supporting the importance of foraminal dimensions on injury etiology.

In another study, Imagama et al<sup>21</sup> studied 1858 patients to evaluate anatomical changes between patients with and without postoperative C5 palsy after cervical laminoplasty. Preoperative CT imaging showed bilateral foraminal narrowing in patients who experienced C5 palsy.<sup>21</sup> This and other studies suggest that preoperative evaluation of C4/5 foraminal area may be of use in determining a patient's risk for C5 nerve root palsy. Our study provides important anatomical references that may aid in this pre-operative evaluation and understanding the relationship between foraminal areas in a non-pathological spine.

There were a number of limitations within this study. We used skeletal specimens lacking any soft tissue and ligamentous structures, which have also been implicated in contributing to foraminal narrowing in the cervical spine.<sup>22</sup> However, our method using only osseous specimens allowed for more accurate and accessible analysis of the foramen, which is complexly positioned in 3-dimensional space. Finally, these cadaveric specimens were obtained from the early 1900s and it is well known that modern populations are slightly larger. However, intervertebral foramen width has been shown not to vary with stature, yet it is unclear if intervertebral foramen height does.<sup>15</sup> Also given that our study focused on comparative differences in foraminal area within the same subjects rather than absolute amounts, we do not think that this limitation impacts our ultimate conclusions.

## Conclusions

In our analysis of 500 vertebrae from C3 to C7, this study represents the largest evaluation of cervical intervertebral foramen. We found mean cross-sectional area of the cervical foramen at C4/5 was significantly narrower compared with C5/6 and C6/7 but not different from C3/4. There were no significant differences in foraminal areas between male and female foramen while Caucasians had significantly larger foraminal areas at C4/5, C5/6 and C6/7 when compared with African Americans. This study provides an anatomic reference for comparing foraminal areas; however, further investigations evaluating foraminal area in different pathologies and their clinical impact are needed.


## Declaration of Conflicting Interests

The author(s) declared no potential conflicts of interest with respect to the research, authorship, and/or publication of this article.

## Funding

The author(s) received no financial support for the research, authorship, and/or publication of this article.

## ORCID iD

Matthew V. Abola, BA  <http://orcid.org/0000-0001-8084-3515>

## References

1. Gu Y, Cao P, Gao R, et al. Incidence and risk factors of C5 palsy following posterior cervical decompression: a systematic review. *PLoS One*. 2014;9:e0101933. doi:10.1371/journal.pone.0101933.
2. Kelly JD 4th, Aliquo D, Sitler MR, Odgers C, Moyer RA. Association of burners with cervical canal and foraminal stenosis. *Am J Sports Med*. 2000;28:214-217.
3. Nakashima H, Imagama S, Yukawa Y, et al. Multivariate analysis of C-5 palsy incidence after cervical posterior fusion with instrumentation. *J Neurosurg Spine*. 2012;17:103-110. doi:10.3171/2012.4.SPINE11255.
4. Lubelski D, Derakhshan A, Nowacki AS, et al. Predicting C5 palsy via the use of preoperative anatomic measurements. *Spine J*. 2014;14:1895-1901. doi:10.1016/j.spinee.2013.10.038.
5. Katsumi K, Yamazaki A, Watanabe K, Ohashi M, Shoji H. Analysis of C5 palsy after cervical open-door laminoplasty: relationship between C5 palsy and foraminal stenosis. *J Spinal Disord Tech*. 2013;26:177-182. doi:10.1097/BSD.0b013e31823db346.
6. Levitz CL, Reilly PJ, Torg JS. The pathomechanics of chronic, recurrent cervical nerve root neurapraxia. The chronic burner syndrome. *Am J Sports Med*. 1997;25:73-76.
7. Kitagawa T, Fujiwara A, Kobayashi N, Saiki K, Tamai K, Saotome K. Morphologic changes in the cervical neural foramen due to flexion and extension: in vivo imaging study. *Spine (Phila Pa 1976)*. 2004;29:2821-2825.
8. Yoo JU, Zou D, Edwards WT, Bayley J, Yuan HA. Effect of cervical spine motion on the neuroforaminal dimensions of human cervical spine. *Spine (Phila Pa 1976)*. 1992;17:1131-1136.
9. Nuckley DJ, Konodi MA, Raynak GC, Ching RP, Mirza SK. Neural space integrity of the lower cervical spine: effect of normal range of motion. *Spine (Phila Pa 1976)*. 2002;27:587-595.
10. Chang V, Basheer A, Baumer T, et al. Dynamic measurements of cervical neural foramina during neck movements in asymptomatic young volunteers. *Surg Radiol Anat SRA*. 2017;39:1069-1078. doi:10.1007/s00276-017-1847-6.
11. Ebraheim NA, An HS, Xu R, Ahmad M, Yeasting RA. The quantitative anatomy of the cervical nerve root groove and the intervertebral foramen. *Spine (Phila Pa 1976)*. 1996;21:1619-1623.
12. Hegazy RM, Abdelrahman AY, Azab WA. Computed tomographic evaluation of C5 root exit foramen in patients with cervical spondylotic myelopathy. *Surg Neurol Int*. 2014;5(suppl 3):S59-S61. doi:10.4103/2152-7806.130668.
13. Sohn HM, You JW, Lee JY. The relationship between disc degeneration and morphologic changes in the intervertebral foramen of the cervical spine: a cadaveric MRI and CT study. *J Korean Med Sci*. 2004;19:101-106.
14. Lu J, Ebraheim NA, Huntoon M, Haman SP. Cervical intervertebral disc space narrowing and size of intervertebral foramina. *Clin Orthop Relat Res*. 2000;(370):259-264.

15. Humphreys SC, Hodges SD, Patwardhan A, Eck JC, Covington LA, Sartori M. The natural history of the cervical foramen in symptomatic and asymptomatic individuals aged 20-60 years as measured by magnetic resonance imaging. A descriptive approach. *Spine (Phila Pa 1976)*. 1998;23:2180-2184.
16. Cinotti G, De Santis P, Nofroni I, Postacchini F. Stenosis of lumbar intervertebral foramen: anatomic study on predisposing factors. *Spine (Phila Pa 1976)*. 2002;27:223-229.
17. Fleiss JL, ed. Reliability of measurement. In: *The Design and Analysis of Clinical Experiments*. Hoboken, NJ: Wiley; 1999: 1-32.
18. Shrout PE, Fleiss JL. Intraclass correlations: uses in assessing rater reliability. *Psychol Bull*. 1979;86:420-428.
19. Rühli FJ, Müntener M, Henneberg M. Human osseous intervertebral foramen width. *Am J Phys Anthropol*. 2006;129:177-188. doi:10.1002/ajpa.20263.
20. Komagata M, Nishiyama M, Endo K, Ikegami H, Tanaka S, Imaikiire A. Prophylaxis of C5 palsy after cervical expansive laminoplasty by bilateral partial foraminotomy. *Spine J*. 2004;4:650-655. doi:10.1016/j.spinee.2004.03.022.
21. Imagama S, Matsuyama Y, Yukawa Y, et al. C5 palsy after cervical laminoplasty: a multicentre study. *J Bone Joint Surg Br*. 2010;92:393-400. doi:10.1302/0301-620X.92B3.22786.
22. Albright JP, McAuley E, Martin RK, Crowley ET, Foster DT. Head and neck injuries in college football: an eight-year analysis. *Am J Sports Med*. 1985;13:147-152.