

An unusual anti–melanoma differentiation–associated protein 5 amyopathic dermatomyositis



Héloïse Barailler, MD,^a Sophie Charles, MD,^a Felix Goutorbe, MD,^b and Suzanne Devaux, MD^a
Bayonne, France

Key words: anti–melanoma differentiation-associated protein 5; dermatomyositis; digital necrosis; paraneoplastic.

INTRODUCTION

Dermatomyositis (DM), an inflammatory autoimmune disorder characterized by cutaneous manifestations and muscle involvement, is now well described with different myositis-specific antibodies (MSA), leading to specific therapeutic approaches according to the antibody type found. Melanoma differentiation–associated protein 5 (MDA-5), a new specific antibody, was first described by Sato et al in 2005,¹ mostly in the Asian population. It has been frequently associated with clinically amyopathic dermatomyositis (CADM). Previous studies found that anti–MDA-5 antibodies are associated with a rapidly progressive interstitial lung disease (ILD)² leading to a poor prognosis. Patients with anti–MDA-5 also present with characteristic skin features: Gottron papules, livedo, skin ulceration, and necrosis. Here we report an unusual case of anti–MDA-5 dermatomyositis without ILD occurring in a paraneoplastic context.

OBSERVATION

A 70-year-old white man was treated with sorafenib for nonmetastatic hepatocellular carcinoma starting in May 2017. Before introduction of this treatment, he already presented with painful cutaneous ulcers of both hands. Angio–computed tomography (CT) scan of both arms found no anomaly. Physical examination found facial erythema, painful digital cyanosis and ulcers, and erythematous and violaceous papules on the back of hands and fingers with necrotic paronychia (Fig 1).

The patient also had erythematous lesions on both elbows. There was no myalgia or dyspnea and

Abbreviations used:

CADM:	clinically amyopathic dermatomyositis
CT:	computed tomography
DM:	dermatomyositis
MSA:	myositis-specific antibodies
MDA-5:	melanoma differentiation–associated protein 5

lung auscultation was clear. Blood test found normal creatine phosphokinase level and normal coagulation parameters. Immunologic explorations found positive antinuclear antibodies (1/640), with the presence of anti–MDA-5 antibodies. Anti-scl70, anticentromere, anti-RNP, anti-Ro52, and anti-TIF1 γ were negative. Results of vascular tests including angio-CT scan, arterial echography, and capillaroscopy were normal. Echocardiography found no anomaly. Positron emission tomography found hyperfixation of the hepatic carcinoma without additional extrahepatic fixation. Muscular magnetic resonance imaging and electromyography did not find any specific characteristics of polymyositis. Thoracic CT scan and spirometry found a restrictive lung disease caused by active smoking but no images of ILD. Cutaneous biopsy of a papular lesion on the hand found a lichenoid reaction with mild lymphocytic infiltration without vasculitis (Fig 2). Direct immunofluorescence test was positive, with perivascular IgG, IgA, and C3 deposits.

On admission, intravenous vasodilator perfusions (iloprost) and antiplatelet drug were initiated. Then, with severe cutaneous necrotic anti–MDA-5 amyopathic dermatomyositis diagnosed, high doses of

From the Departments of Dermatology^a and Gastroenterology,^b Hôpital Côte Basque.

Funding sources: None.

Conflicts of interest: None disclosed.

Correspondence to: Héloïse Barailler, MD, Centre Hospitalier de la Côte Basque, 13, avenue de l'interne Jacques Loeb, 64100 Bayonne, France. E-mail: heloise.barailler@gmail.com.

JAAD Case Reports 2019;5:383-5.
2352-5126

© 2019 by the American Academy of Dermatology, Inc. Published by Elsevier, Inc. This is an open access article under the CC BY-NC-ND license (<http://creativecommons.org/licenses/by-nc-nd/4.0/>).

<https://doi.org/10.1016/j.jidcr.2019.02.019>

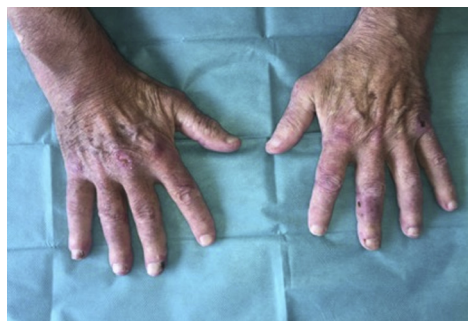

Fig 1. Acrocyanosis, painful erythematous and violaceous papules on the back of hands and fingers and necrotic paronychia.

intravenous corticotherapy (1 mg/kg/d) and immunoglobulin perfusions (2 g/kg every 4 weeks) were started. We did not diagnose Buerger disease based on the clinical presentation and the positivity of anti-MDA-5 antibodies. Hydroxychloroquine was added 1 month later, because he was refractory to standard immunosuppressive treatment with extension of cutaneous necrotic features (Fig 3).

A preventive surgery for finger necrosis was performed. Despite this treatment, cutaneous lesions kept progressing, with extension of necrosis and spontaneous amputation. Considering the severity of the disease, we started plasmapheresis and rituximab infusions. Symptomatic treatment was optimized, adding nifedipine and curative anticoagulant therapy by enoxaparine. Unfortunately, skin involvement worsened under maximum-tolerated treatment dose. Four months after the diagnosis, our patient ultimately died from hepatocarcinoma progression.

DISCUSSION

We present an original case of severe cutaneous digital necrosis in a context of amyopathic paraneoplastic dermatomyositis with anti-MDA-5 antibodies without ILD.

Dermatomyositis management is influenced by the presence of a specific type of MSA, since the clinical spectrum of this disease is heterogeneous.³ Detection of MSA can be useful for prognosis and therapeutic options, even if treatment is truly guided by patient presentation and co-morbidities. Usually, detection of anti-MDA-5 is known to be associated with a poor prognosis due to rapidly progressive ILD.

Recently, studies showed that anti-MDA-5 antibodies were associated with a specific cutaneous phenotype like severe skin ulcerations and painful palmar papules.⁴ Skin ulcerations are preferentially located on lateral nailfolds, Gottron papules, and elbows. There is also an increased risk of oral

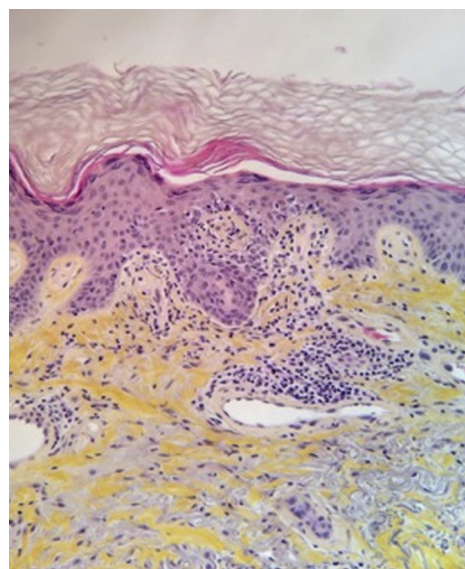


Fig 2. Cutaneous biopsy shows lichenoid reaction with mild lymphocytic infiltration without vasculitis. (Hematoxylin-eosin stain; original magnification: $\times 200$.)

ulceration, hand swelling, and hair loss. Our patient had a neoplastic disease and presented with a typically severe cutaneous involvement, but interestingly had no ILD. No pulmonary involvement was detected during follow-up with imaging and spirometry. Early initiation of immunosuppressive therapy might have helped to prevent interstitial lung involvement.

Treatment of anti-MDA-5 dermatomyositis is not well established. High doses of corticosteroids is the first-line treatment and should be started as soon as possible. Immunosuppressive treatment must be considered early after the onset of the disease, as anti-MDA-5 antibodies are usually associated with severe pulmonary involvement. A collaborative discussion is needed for each patient, as there are no official guidelines to follow for CADM treatment. In our case, we proceeded to a step-by-step treatment intensification. We think that anti-MDA-5 DM treatment should be guided by severity of the disease at presentation and undoubtedly if extracutaneous involvement is present.⁵

Rapidly cutaneous necrosis of fingers with spontaneous amputation has already been described but in most cases were associated with ILD.⁶⁻⁸ Consistently, a recent retrospective study showed that there was a strong association between cutaneous ulcers and risk of ILD.⁹ The first case of anti-MDA-5 DM described in Western Europe presented with a cutaneous necrosis, but pulmonary involvement was diagnosed. Prednisone, high-dose intravenous immunoglobulin, cyclophosphamide,

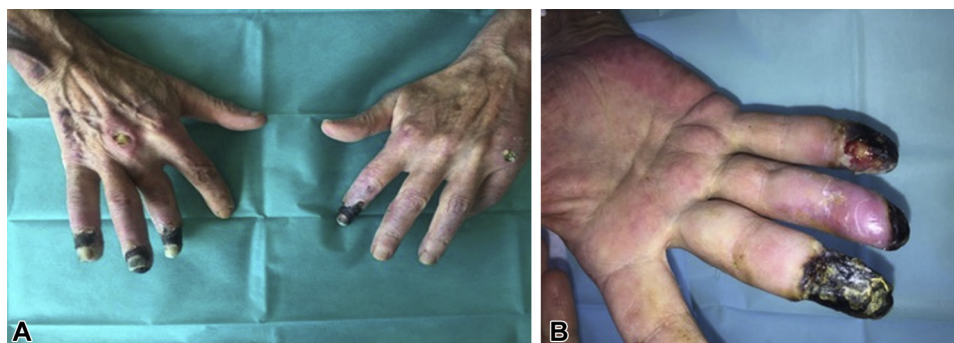


Fig 3. **A** and **B**, Necrotic evolution of cutaneous ulcers with spontaneous amputations of the fingers.

mycophenolate mofetil, iloprost, and rituximab, managed to stabilize the disease.⁶ Another patient with spontaneous amputation of the fingers also had ILD and was treated by corticosteroids, cyclophosphamide, intravenous immunoglobulin, and cyclosporine with a relative efficacy on the lungs but progression of cutaneous necrosis.⁷

To our knowledge, this is the only case of rapidly extensive digital necrosis caused by anti-MDA-5 dermatomyositis in a paraneoplastic context. Actually, frequent MSA associated with cancer are anti-TIF1 γ and anti-NXP2 antibodies. Neoplastic diseases are found in only 20% of dermatomyositis with anti-MDA-5.⁴ To date, only few cases have been reported.⁹ When occurring in a paraneoplastic context, treating DM with conventional therapy can be challenging because immunosuppressive therapy can lead to the spread of cancer. This was what probably caused patient death in our case. Surgical amputation can be considered sometimes to prevent infectious complications and discomfort. However, surgery does not stop necrosis from spreading afterward.

Our case highlights the clinical heterogeneity of CADM. It is, to our knowledge, the first case of paraneoplastic amyopathic anti-MDA-5 dermatomyositis without lung involvement. This case also shows that treating extensive digital necrosis can sometimes be challenging.

REFERENCES

1. Sato S, Hirakata M, Kuwana M, et al. Autoantibodies to a 140-kd polypeptide, CADM-140, in Japanese patients with clinically amyopathic dermatomyositis. *Arthritis Rheum.* 2005;52:1571-1576.
2. Moghadam-Kia S, Oddis CV, Sato S, Kuwana M, Aggarwal R. Anti-melanoma differentiation-associated gene 5 is associated with rapidly progressive lung disease and poor survival in US patients with amyopathic and myopathic dermatomyositis. *Arthritis Care Res.* 2016;68:689-694.
3. Fujimoto M, Watanabe R, Ishitsuka Y, Okiyama N. Recent advances in dermatomyositis-specific autoantibodies. *Curr Opin Rheumatol.* 2016;28:636-644.
4. Fiorentino D, Chung L, Zwerner J, Rosen A, Casciola-Rosen L. The mucocutaneous and systemic phenotype of dermatomyositis patients with antibodies to MDA5 (CADM-140): a retrospective study. *J Am Acad Dermatol.* 2011;65:25-34.
5. Kurtzman DJB, Vleugels RA. Anti-melanoma differentiation-associated gene 5 (MDA5) dermatomyositis: a concise review with an emphasis on distinctive clinical features. *Am Acad Dermatol.* 2018;78:776-785.
6. Clottu A, Laffitte E, Prins C, Chizzolini C. Response of mucocutaneous lesions to rituximab in a case of melanoma differentiation antigen 5-related dermatomyositis. *Dermatology.* 2012;225:376-380.
7. Charbit L, Bursztejn AC, Mohamed S, et al. Extensive digital necrosis during dermatomyositis associated with MDA-5 antibodies. *Ann Dermatol Venereol.* 2016;143:537-542.
8. Narang NS, Casciola-Rosen L, Li S, Chung L, Fiorentino DF. Cutaneous ulceration in dermatomyositis: association with anti-melanoma differentiation-associated gene 5 antibodies and interstitial lung disease. *Arthritis Care Res.* 2015;67:667-672.
9. Yamaoka T, Doi C, Yokomi A, et al. Anti-MDA5 antibody-positive dermatomyositis with lethal progressive interstitial lung disease and advanced gastric cancer. *Eur J Dermatol.* 2014;24:490-491.