

A CONTRIBUTION TO THE ETIOLOGY AND PATHOLOGY OF RAT-BITE FEVER.*

By RENJIRO KANEKO, M.D., AND KIKUZO OKUDA, M.D.

(From the First Medical Clinic of the Imperial University in Kyushu, Fukuoka,
Japan.)

PLATES 32 TO 34.

(Received for publication, February 20, 1917.)

Although rat-bite fever in Japan was recognized a long time ago by Miyake and others as a definite entity, and its symptomatology has been described in detail, we know little of its pathological anatomy. According to Ishiwara only two postmortem examinations have been reported, one by Blake, and another by Miura and Toriyama.

Our knowledge of the causative agent of rat-bite fever is of recent date. Futaki and his associates reported in their first communication the finding of a long spirochete, measuring 9 to 10 μ in the lymph glands on the 10th or 13th day of illness, and on the 33rd day in tissue fluid obtained from the bitten area. Those found in the lymph exudate had small waves, those from sections of lymph glands, numerous steep waves. Later on they discovered in man, in the wound of the rat bite, and in the blood of mice which had received injections of patient's blood, shorter, thick spirochetes, 2 to 6 μ long. These had regular, close, and steep waves, and a filament at each end. As these long and short spirochetes are morphologically distinct, and both have been demonstrated in rat-bite fever, the question arose whether they are of the same species, or whether rat-bite fever may be caused by two different spirochetes.

The problem could not be solved at the time by Futaki and his coworkers. In the meantime, Ishiwara and his associates found in their investigations of experimental rat-bite fever spirochetes of the shorter variety, which were morphologically identical with the short variety of Futaki. Kitagawa and Mukoyama, as well as Midzukuchi, reported finding these spirochetes in experimental rat-bite fever.

We performed recently a postmortem examination on an individual who had rat-bite fever in typical form, and were in a position to make

* Published in *Iji-Shimbun*, June, 1916, Nos. 951, 952.

definite anatomical studies. We found in the tissues certain spirochetes which will be described, and were able to confirm the work of Futaki and his associates, who were the first to designate these spirochetes as the cause of rat-bite fever. We have furthermore come to the conclusion that the long type of spirochetes found by them previously and the short variety discovered later in experimentally infected animals are not diverse in type, but belong to the same species of spirochete.

Spirochetes in the Tissues.

We examined the blood of a patient having rat-bite fever during the afebrile interval, guinea pigs inoculated with the patient's blood, as well as the swollen lymph glands, but found no spirochetes. Later Ido and other authors found in blood films taken at the height of the disease, a number of the short type of spirochetes.

Distribution in the Organs.—We focused our attention particularly upon the suprarenals and the kidneys, in view of the fact that Ishiwara and his associates in their experiments on guinea pigs found the organisms mainly in the suprarenals, and also because *Spirocheta icterohæmorrhagiæ* is present in these organs in the convalescent stage of Weil's disease. After repeated careful examinations, we discovered numerous organisms, particularly in the kidneys.

The spirochetes in the kidneys are located almost exclusively in the casts and cylindroids of the straight tubules, in the canals of Henle, and the intercalary portion of the boundary layer. They were never found free in the lumen and the interstitial spaces. In the suprarenals, we observed the organisms in the cortical cells. In addition, we found in the interstitial space of the testicle a specimen of the short spirochete. Other organs, *i.e.*, the liver, lymph glands, spleen, lungs, intestines, stomach, bladder, prostate, heart, and brain, showed no spirochetes; nor could any be found in the skin of the bitten area, treated with Orth's fluid, and in the swollen lymph glands.

The total number of spirochetes found in the organs was somewhat over 100 in 30 preparations; most of these were contained in renal casts and cylindroids. In the suprarenals, we observed seven specimens in ten preparations, and in the testicle one in several preparations. Their distribution is very irregular; in the densest regions five to six specimens were found in one cast, and twenty-eight in a preparation.

Forms of the Spirochete.

As shown in Fig. 1, the forms of the organism are various. The spirochete may be long or short, thick or thin, rigid or pliable, smooth or ragged. The waves may be regular or irregular, gradual or abrupt, many or few. The diversity of characteristics is so great as to lead to the belief that many kinds of spirochetes are present. They can, however, be classified according to size into long and short, with intermediary forms between the two groups.

The short spirochetes found by us are from 1.7 to 5.0 μ in length. As a rule, they have close and regular waves, from two to six steep waves to a specimen, are relatively thick, with smooth edges, and stain deeply when impregnated with silver. Occasionally one finds at one or both ends, fine thread-like extensions which stain somewhat less deeply. These regularly waved spirochetes are identical with the short spirochete of Ishiwara. But a large number of the short spirochetes are more rigid in form, have irregular waves, and are not smooth at the edges. These are atrophic abortive forms. The spirochetes found in blood films have regular waves.

The long type spirochete measures 6.0 to 10.0 μ , and has numerous, small, steep, irregular waves. These specimens are not smooth and regularly formed, and appear rigid.

We examined the mouse preparations (from the injection of patient's blood) sent us by Futaki, and are convinced that his short type of spirochete is identical with our own, with the exception that our specimens were somewhat thinner and more rigid, which may be due to the fact that our strain was taken from man. Futaki's long type, which we observed in great numbers in his preparations, is morphologically identical with ours.

In addition we made careful histological examinations of guinea pigs infected by Ido and his collaborators through rat bites. The spirochetes found in these animals are morphologically identical with our short spirochete.

DISCUSSION.

In Weil's disease, the distribution of *Spirochæta icterohæmorrhagiæ* varies with the different stages of illness. At the beginning the organ-

isms circulate in the blood, while in the convalescent stage, following the complete development of immune bodies, they can be demonstrated only in the kidneys. A similar distribution seems to prevail in rat-bite fever. In the experimental animals, the spirochetes circulate in the peripheral blood. That identical conditions exist in the human body is proved by the fact that mice and guinea pigs can be infected by the inoculation of patient's blood. At the height of the disease, the short spirochete, though not numerous, has been observed microscopically in the blood. In our case we found the spirochetes located mainly in the kidneys, although at the height of illness they could be demonstrated also in the peripheral blood. The localization within the kidneys is undoubtedly the usual order in later stages of the disease.¹

Inada was the first to suggest the formation of antibodies in rat-bite fever. He was followed by Ido and his associates of our clinic, who proved the truth of the assumption. Judging by analogy with Weil's disease, we suggest that the irregular distribution of spirochetes in the kidneys may be attributable to the partial destruction that has taken place owing to the action of the antibodies.

The characteristics of our spirochetes—their irregularity and rigidity—may also be considered as the result of the action upon them of the immune bodies. We know that in *spirochætosis ictero-hæmorrhagica* the organisms disappear in the course of the illness through the action of the spirochetolytic and spirocheticidal antibodies, leaving various irregular so called degenerated forms of spirochete. It is highly probable that this is also the case in rat-bite fever in man. On the other hand, in the animal body, where no specific immune bodies are developed, the spirochetes exist in their typical forms as found by Futaki (short spirochete) and also by Ishiwara. In conformity with this, we have our finding of short spirochetes in the blood of patients at the height of the disease.

Finally we are confronted with the important problem as to whether the short and long spirochetes constitute two different species or one species of spirochete. Futaki seems to regard them as organisms different in type, and for that reason was not clear

¹ At the time of death the patient had passed the height of the disease.

concerning the etiology of rat-bite fever. On the basis of histological investigations, we conclude that these two forms of spirochete belong to the same species, as one type grades into the other, morphologically speaking. Moreover, it does not seem probable in our case of rat-bite fever that spirochetes of different types simultaneously infected the same individual and localized in the renal casts.

The long spirochetes occur almost exclusively in human tissues and we may regard them as old or degenerated forms which have become irregular and stiffly bent. The short spirochetes, on the other hand, which have regular waves are the typical, young specimens. They can be found in the blood of patients having rat-bite fever, as well as in the experimental animals.

Futaki and his collaborators, 2 weeks prior to the appearance of our publication, on the basis of experiments made with pure cultures, arrived at a conclusion identical with our own.

Pathological Anatomy.

Case 1.—Z. I., male, age 70, locomotive engineer. Clinical diagnosis: rat-bite fever.

History.—A month previously the patient while asleep was bitten by a rat, in the forefinger of the left hand. The wound bled. After 2 weeks the area became swollen and red; very sensitive. Incision was made. The following day the patient observed blotches, the size of a finger, in rows on the left forearm. These disappeared gradually, only four remaining. Similar spots appeared in the left cubital region and upper arm, and along the tendon of the forefinger. 20 days after the bite, the patient observed swelling of left axillary lymph glands, which became as large as a pigeon's egg, and were very painful. Temperature was not taken, but after the incision there was fever. A few days ago, slight chills, fever, headache, and loss of appetite, which have continued.

Admitted to clinic, Oct. 18, 1915.

Present Illness.—Male, medium height. Nutrition fair. Conjunctivæ, mucosa of palate, and pharynx markedly hyperemic. Tongue swollen and coated. Lymph glands in left axilla, size of bean to pigeon's egg; very sensitive. Both cubital glands swollen to size of lentil; elastic, soft, not sensitive. Inguinal glands not swollen. Thickened arterial walls. Liver palpable two fingers below costal arch, not sensitive. Spleen not palpable. No ascites. Urine negative.

Left forefinger shows scar 1 cm. at point of incision. Joint somewhat affected. Skin on dorsal side of left second metacarpophalangeal articulation somewhat eroded and scarred. Surrounding area red and hot. On dorsal sur-

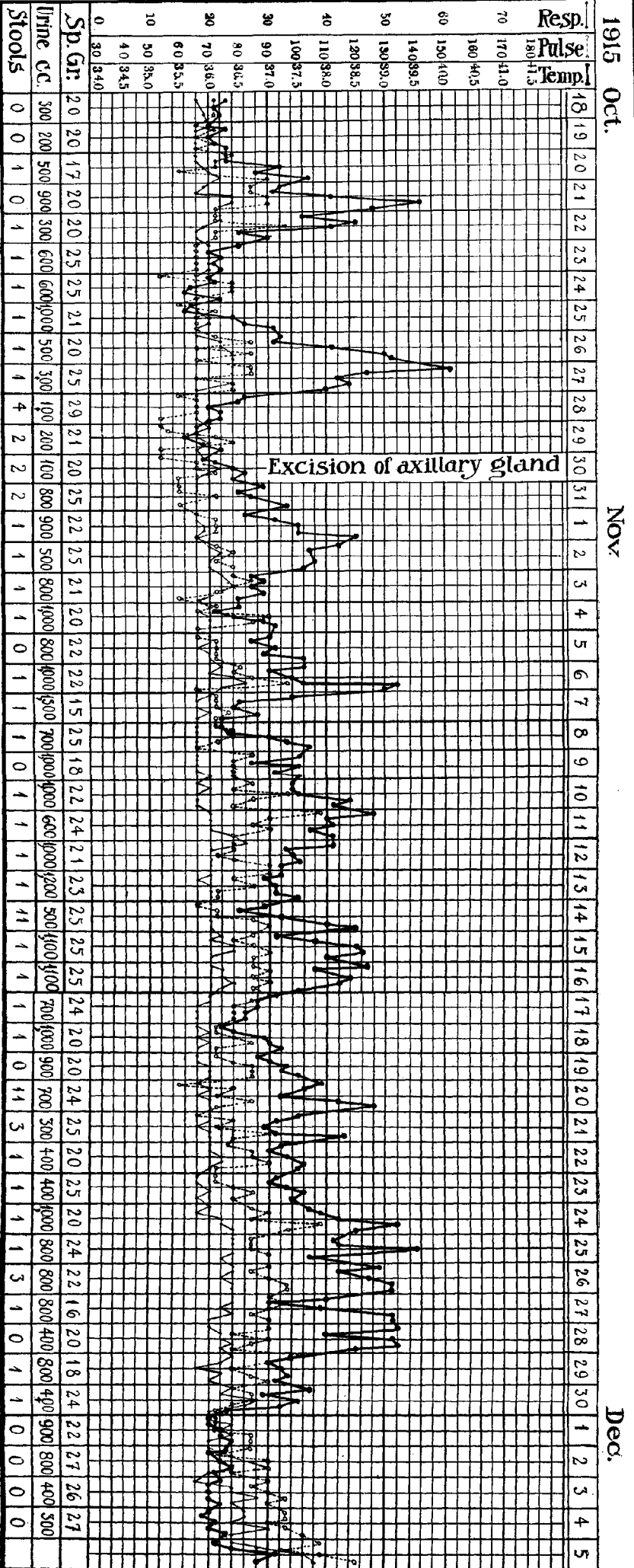
face of left hand, a number of reddened areas, size of quarter, somewhat raised, also along radial side of fore and upper arm. The spots are united by fine red stripes.

Blood.—Oct. 20, with ascending fever, hemoglobin (Sahli), 60 per cent, erythrocytes, 4,012,000, leukocytes 5,600. Oct. 29, interval; hemoglobin 64 per cent, erythrocytes 4,290,000, leukocytes 4,200. Nov. 2, rising fever, erythrocytes 3,090,000, leukocytes, 12,100.

Course.—Death from senile anorexia, 7 weeks after admission. Altogether eight fever attacks, each lasting 3 to 4 days, with afebrile intervals of 2 to 3 days. At onset of illness, typical fever; later, atypical, often remittent. Height of fever in an attack 38.5–39.5°C., once reaching 40.1°C. (Text-fig. 1).

Left axillary glands at first swollen to size of pigeon's egg, diminished gradually. Oct. 30, when excised, they were the size of a bean. Gland was flat and elastic, partly hyperemic, grayish white. Spots on skin became gradually fainter; none found on Oct. 26. Gradual loss of weight. Died of inanition and marasmus, Dec. 6.

Autopsy.—9 hours later. Body poorly nourished. Rigor mortis only in knee joints. Skin dry, dark brown. Scar on left forefinger. No edema or exanthemata. Peritoneum contained no abnormal fluid. Mesenteric lymph glands swollen, on section somewhat injected. Pericardium contained a table-spoonful of serous fluid, with fibrin fragments; inner surface of pericardium opaque. Heart in diastole, size of patient's fist, weight 265 gm. In left ventricle, no fluid or coagulated blood; in right ventricle, small mass of fatty coagulum. Pericardium somewhat opaque, endocardium without luster. Intima of root of aorta, marked arteriosclerotic spots; valves negative. Myocardium soft, yellowish brown. Spleen somewhat soft, small, 8.0 by 7.0 by 1.5 cm., 64 gm., capsule corrugated, trabecular. Lungs, marked anthracosis; hyperemic; scattered atelectatic foci. Glands of hilum somewhat swollen. Kidney, left, 1.2 by 5.0 by 3.0 cm., 116 gm., capsule adherent, surface not smooth, partly nodular and granulated, congested. Large cysts scattered on surface. On section hyperemic, cortex thin; columns of Bertin yellowish, granulated; mucous membrane of pelvis slightly hyperemic, somewhat enlarged. Parenchyma friable and cloudy. Right kidney, 11.0 by 4.5 by 2.5 cm., 98 gm., similar to left. Suprarenals hyperemic. Liver, 30.0 by 13.5 by 5.5 cm., 1,062 gm. Surface smooth, rib furrow on right lobe. Parenchyma on section yellowish, dull, but acini recognizable; congested, consistency tough. Gall bladder contained greenish mucous gall; mucosa negative. Stomach contained small quantity of mucus; mucosa hyperemic and opaque. The same may be said of mucosa of duodenum; papilla duodeni permeable. Pancreas, hyperemic. Intestines, mucosa opaque and hyperemic; follicles not swollen. Bladder contained small amount of turbid urine; marked hyperemia of mucosa. Prostate slate-colored, not hypertrophied. Cranium, subdurally, large mass of serous fluid; meninges soft, somewhat opaque and hyperemic; brain slightly hyperemic. Bone marrow of tibia negative.



TEXT-FIG. 1. Case 1, male.

Diagnosis.—Rat-bite fever. (1) Marasmus universalis. (2) Degeneratio parenchymatosa cordis, hepatis, renum. (3) Gastroenteritis catarrhalis. (4) Cystitis catarrhalis. (5) Edema and hyperemia meningeae. (6) Arteriosclerosis gradus gravioris. (7) Nephritis interstitialis chronica.

Histological Examination. Lymph Glands.—From left axilla, removed Oct. 30, negative. Stained with hematoxylin and eosin. Showed simple hyperplasia of adenoid tissue. In capsule and its surrounding area, infiltration with plasma cells and leukocytes. Parenchyma markedly hyperemic, but showed no regressive or marked inflammatory changes.

The other organs were placed in fixing solution, and stained. The following is a report of the hematoxylin and eosin preparations.

Kidney.—By low power, hyaline degeneration of glomeruli, interstitial proliferation, and casts, as well as cylindroid formation in the tubules. Cortex and medulla hyperemic here and there. Subcapsular lobulation of cortex, consisting of scar tissue, containing degenerated hyaline glomeruli and the remains of kidney tubules; marked cellular infiltration. By high power, marked changes in kidney tubules, particularly of the convoluted tubules. Cells markedly enlarged, partly degenerated, nuclei remaining unstained and cells necrotic, staining faintly reddish violet. Some cells when stained with Sudan show small fat globules. In other places, marked desquamation and destruction of cells, with stained nuclei. Slighter changes in wall epithelium of lower sections of convoluted tubules, Henle's loops, and the intercalary portion; nuclei stain well; no necrosis, though sometimes marked destruction and desquamation of epithelium. Infiltration of fat globules more marked in lower sections of the tubules. The epithelium of convoluted tubules contains very small fat globules resembling lipid substance, while in the epithelium, of straight tubules, infiltration of larger fat globules is common.² The renal casts and cylindroids are always hyaline, and rarely contain blood cells and desquamated epithelium. Numerous urinary casts particularly in the lower sections of the tubules, and in convoluted tubules, Henle's loops, intercalary portion, etc. Now and then in the enlarged tubules one finds a round, hyaline body composed of layers. The medullary canals also contain numerous casts. The glomeruli show total or partial hyaline degeneration, some being hyperemic. No abnormal fluid in Bowman's capsules. The interstitial spaces are markedly dilated, but without new connective tissue or cellular infiltration, generally edematous, and in part transformed into hyaline. The blood vessels show no marked changes.

Liver.—Cells stain faint reddish violet with hematoxylin and eosin, often contain fat globules, fine vacuoles, and yellowish brown pigment bodies in the neighborhood of the nuclei. No marked swelling or opacity of liver cells. With Sudan III, the cells in acini centers show infiltration with small fat globules, while

² This phenomenon was also observed by us in spirochætosis icterohæmorrhagica.

in the cells of the acini periphery there is an accumulation of large drops of fat. The central parts of the acini are broken up and markedly degenerated. The cells are atrophic, disintegrated, or necrotic; many have disappeared. The gaps are filled with blood cells; various grades of necrobiosis in cells. Nuclei are unstained or disintegrated; some have disappeared. Marked fatty degeneration. Liver cells of acini periphery are relatively compact. Stellate cells of Kupffer slightly enlarged; in part fatty degeneration has taken place. Some contain blood cells and pigment granules. The interstices show no marked changes. Slight infiltration of round cells here and there. In the bile duct nothing noteworthy. Wall epithelium rarely shows infiltration of fat globules.

Spleen.—Negative. Follicles not enlarged, trabeculae well developed. Scattered hyperemia. Central arteries thickened, intima shows hyaline degeneration. The nuclei of scattered pulp cells do not stain well; destroyed. No large necrotic foci, cellular infiltration, pigment deposits, erythrophagocytosis, or microorganisms.

Suprarenals.—Show in deep layer of cortex circumscribed hyperemia, causing slight scattering of cells.

Cardiac Muscles.—Somewhat pale and indistinct; no fatty or other degenerations present. In the fibers near the two ends of the nuclei, numerous pigment bodies, which stain yellowish with Sudan III (brown atrophy).

Lungs.—Catarrhal changes in consolidated parts.

Mesenteric Glands.—Blood vessels in the medulla are markedly dilated and filled; lymph sinuses dilated. Endothelium, desquamated and degenerated, often taking up erythrocytes. Some scattered degenerated cells in sinus and follicles. Mucosa of gastrointestinal tract covered with mucus; epithelium desquamated, and cellular infiltration in propria.

Muscle fibers of gastrocnemius here and there slightly swollen; partly changed into hyaline. No marked destruction of fibers or fatty degeneration.

Nerve Cells.—Cells of brain cortex and spinal cord here and there are slightly enlarged or destroyed; some are pyknotic, nuclei not stained. Nerve fibers show, though rarely, slight swelling and disintegration.

Skin.—Shows scar at site of bite.

Case 2.—R. H., female, age 40, peasant woman. Admitted to Second Medical Clinic, July 28, 1908.

History.—70 days ago, while asleep, the patient was bitten in the upper lip by a rat. The wound bled, but healed in a few days. After a month, the skin of the bitten area became red, swollen, and very sensitive. Swelling and redness extended gradually to the angle of the mouth on the right side, and then to the submaxillary region. Since that time, patient had attacks of chills and fever, with headache and malaise. First attack lasted for a week, followed after an interval of 1 week by a second. Patient observed also about ten scattered spots, varying from the size of a finger point to a walnut, on the extremities and the chest. High fever with nausea, vomiting, loss of appetite, headache, etc.

Swelling of lip and redness subsided gradually. Fever came in attacks, often accompanied by vomiting.

Present Illness.—Medium height and nutrition. At left angle of mouth, a reddish brown spot, 2 cm. in width. Neck in front shows numerous spots, some connected. Extremities also show spots, 1 to 4 cm. in width. Over the entire body, scattered exanthematous areas, which disappear on pressure. Tongue coated. Pulse 120, regular, tense. Breasts and abdominal organs negative. Biceps and brachialis anticus somewhat sensitive. No albumin in urine. No edema. Temperature 38.8°C.

Course.—July 30. Blood: leukocytes 14,333, erythrocytes 3,495,000. Aug. 8. Rising fever, up to 38.7°C. Vomiting. Aug. 10. Muscular pains in lower extremities. Aug. 12. Disappearance of spots and redness of mouth region. Aug. 15. Vomiting. Aug. 18. Rapid pulse. Aug. 20. Fever, 39°C., increased pulse (150 per minute), regular, small. No urination, marked meteorism. Aug. 22, unconscious. Death by cardiac insufficiency.

Autopsy.—12 hours after death. Height 150 cm., weight 36.4 kg. Nutrition poor. Rigor mortis only in knee joints. Diffuse postmortem discoloration on back and neck. Abdomen somewhat distended. Skin pale and dry, no exanthemata, no edema. In abdominal cavity about 100 cc. of clear yellowish fluid. Intestines moderately distended with gas. Serous membranes of intestines pale, slate-colored. Diaphragm, height of fourth intercostal space. No abnormal fluid in thorax. Lungs, no adhesions. Pericardium contained about a tablespoonful of clear yellow fluid; inner surface of pericardium somewhat injected. Heart, size of patient's fist. In right ventricle a large amount and in left ventricle moderate amount of dark red fluid blood and fatty coagulum. Epicardial fat tissue moderate, somewhat edematous. Endocardium smooth, myocardium somewhat opaque. Consistency of heart soft. Intima of root of aorta shows in the region of the aortic valves a number of yellow plaques. Left lung voluminous. Lower edge of lower lobe shows hypostatic induration. On section, congested. Bronchial mucosa markedly hyperemic. Peribronchial glands partly swollen and markedly anthroctic. Right lung moist and congested, resembling left. Spleen, 12.0 by 5.0 by 2.0 cm., weight 58 gm. Capsule wrinkled. On section congested, follicles and trabeculae visible, consistency soft. Left kidney, 11.5 by 6.0 by 2.5 cm., 117 gm. Capsule easily removed. On outer surface, urinary cyst the size of a pea. Parenchyma shows slight opacity. Columns of Bertin somewhat swollen, parenchyma yellowish, boundary of both substances partly indistinct. Right kidney, 11.3 by 6.0 by 2.8 cm., 121 gm., resembling the left. Liver, 24.0 by 16.0 by 6.0 cm., 1,340 gm. Surface smooth. On section somewhat yellowish and opaque. Gall bladder contained dark green gall. Mucosa negative. Stomach contained a large mass of sour smelling grayish green food. Mucosa in spots hyperemic. Intestines, small, held a large mass of dark yellowish green contents. Mucosa slate-colored or greenish yellow, somewhat edematous; scattered small nodules the size of pin-head.

These nodules are dark brown, somewhat coarse, and yellowish in the center. Lower section of small intestine contained twenty-four specimens of *Ascaris lumbricoides*; mucosa markedly injected. Large intestine contained small fecal (fluid) mass; mucosa somewhat injected. Retroperitoneal and mesenteric lymph glands not markedly swollen. Urinary bladder contained small amount of turbid urine; mucosa opaque and injected. Mucosa of vagina also somewhat injected. Portio uteri red. Mucosa of uterus slightly hyperemic.

Diagnosis.—Rat-bite fever. (1) Marasmus universalis. (2) Degeneratio parenchymatosa cordis, hepatis, renum. (3) Gastroenteritis catarrhalis. (4) Cystitis catarrhalis. (5) Hydrocele tubæ dextræ. (6) Ascariasis.

No microscopic examination.

Case 3.—N. H., female. Examination of swollen axillary gland excised at beginning of illness showed marked hyperplasia of parenchyma cells. The follicular substance is particularly hyperplastic. In places, the hemorrhages in the follicles are marked, leaving small islands of cells between. No necrosis of the parenchyma. In the peripheral zone of the gland there is quite a dense accumulation of polynuclear leukocytes. Corresponding with the site of hemorrhage, the epithelium shows here and there desquamation and degeneration. Erythrophagocytosis is present, but not as plainly as in spirochætosis ictero-hæmorrhagica. In the medullary substance, scattered leukocytes are found.

Case 4.—Skin preparation (old) from area bitten by rat. Corium and subcutaneous tissue markedly hyperemic, edematous, and infiltrated with polynuclear leukocytes. No abscess formation. Corium tissue shows hemorrhages and fibrin deposits. No changes in epidermis. Scattered necrotic cells in infiltration zone, but no extensive necrotic foci.

SUMMARY AND DISCUSSION.

Of the two postmortem examinations on rat-bite fever previously reported, the patient of Miura and Toriyama, a woman, aged 32 years, died on the 70th day after the onset of the disease.* Anatomically there were no marked changes. Histological examinations were not made. Macroscopically, the following findings are reported: increase of cerebrospinal fluid, hyperemia of the meninges, inflammatory edema of the lungs, cloudy swelling of the liver, etc.

The other, Blake's case, was a woman of 67, who died 1 month after the bite of a rat. The anatomical findings were acute ulcerative endocarditis, subacute myocarditis, interstitial hepatitis, glomerular and interstitial nephritis. The suprarenals contained a large amount of perivascular fluid. There were infarcts in the spleen and kidney. In general, the organs were hyperemic; the lung showed hemorrhages and edema. Histologically, Blake found marked degeneration, necrosis, and infiltration in the cardiac muscles, infiltration of polynuclear cells, and increase in the interstices of the liver, also marked polynuclear infiltration of the shrunken kidney.

Blake was able to demonstrate *Streptothrix muris rattii* in the tissues, which he assigned as the cause of rat-bite fever. He viewed the degeneration and infiltration in the organs, together with the ulcerative endocarditis, as the result of the streptothrix infection.

Pathological Anatomy.

Our Case 1 was that of a man of 70, who died 80 days after the bite of a rat, and 2 months from the onset of illness. In contrast to Blake's case, there were no marked pathological changes, with the exception of the parenchymatous changes in the organs. The kidney changes are attributable in part to the condition of shrunken kidney, which had existed for some years previous to the infection. Other changes, such as the marked hyperemia, swelling, and degeneration of the tubular epithelium, must be regarded as caused by the rat-bite fever. In part, the formation of casts can likewise be so interpreted. The liver shows marked changes, degeneration, necrosis, and destruction of liver cells, particularly in the acinus centers, with hyperemia and hemorrhages, the fatty degeneration of the liver cells being especially marked in the acinus centers. Parenchymatous changes of the liver and kidney were observed macroscopically in Case 2.

The hematopoietic organs, *i.e.*, the spleen, lymph glands, and the bone marrow, show in general no abnormalities. The local lymph glands at the beginning of illness show marked hyperplasia of the parenchyma cells. In this, the part played by the follicular substance must be taken into consideration. The cellular hyperplasia is simpler and of an inflammatory character. Although the hyperemia, hemorrhages, and the loosening of the follicles are distinct, there are no noteworthy regressive changes. There is a slight catarrhal condition of the sinus and erythrophagocytosis, while in spirochætosis icterohæmorrhagica these manifestations are marked. In the course of the disease, the swelling of the local lymph gland subsides gradually, and the corresponding changes become less. Other lymph glands, such as the mesenteric, also show slight swelling, with hyperemia and catarrhal changes.

In addition we noted in our case catarrhal changes in the mucous membrane of the stomach, cystitis catarrhalis, congestion of the

lungs, etc. The degeneration of the muscle and nerve cells, though slight, must be regarded as a phenomenon of this disease. The meninges were also hyperemic and edematous.

We have few comments to make on the exanthemata, as we lacked material for anatomical investigation. The site of the bite showed, as in the fourth case, cellular infiltration, edema, and degeneration (acute exudative inflammation). In the lungs, as already mentioned, we found signs of congestion, but the accompanying marked inflammatory changes must be regarded as the result of a mixed infection, because we found an accumulation of diplococci.

The changes observed by Miura and Toriyama agree with ours, but a great difference exists between Blake's case and ours. In his case there were marked infiltration of pus cells and regressive changes in the organs—even an ulcerative endocarditis. These differences cannot be explained on the basis of the duration of illness. Though the time of illness in our case was very long; it was marked up to the time of death by fever. In Blake's patient, we must attribute the marked changes, as emphasized also by the author, to streptothrix infection. If this streptothrix is the cause of rat-bite fever, the changes which have been described would be significant, but in view of our findings in Japan, and on the basis of the histological studies made by Ido, Ito, Wani, and Okuda,³ there is doubt in our minds whether the streptothrix should be so regarded. It is possible that Blake's case was one of mixed infection.

In their experiments with rat-bite fever, Ishiwara and his associates found in addition to swelling of the bitten area and lymph glands, acute inflammatory changes in the kidney, and hyperemia and hemorrhages in the suprarenals. We examined the guinea pigs of Ido and his associates, which were infected by the bite of rats; and also observed swelling of the bitten area and of the regional lymph glands, with slight nephritis, hyperemia of the lungs, catarrh of the mucosa of the stomach, and slight parenchymatous degeneration in the organs. These changes on the whole resemble those of human cases.

³ Ido, Y., Ito, H., Wani, H., and Okuda, K., Circulating immunity principles in rat-bite fever, *J. Exp. Med.*, 1917, xxvi, 377.

In conclusion we desire to express to Dr. Ryokichi Inada our thanks for his assistance in this work, to Dr. H. Nakayama of the Pathological Institute of the Imperial University in Kyushu for permitting us to use the protocols, and to Dr. Takeya of the Second Medical Clinic of the University for the use of patients' histories.

BIBLIOGRAPHY.

- Blake, F. G., *J. Exp. Med.*, 1916, xxiii, 39.
Futaki, Takaki, Taniguchi, and Osumi, *Tokyo Igaku-Kwai-Zasshi*, 1915, xxix, No. 23.
Futaki, Takaki, Taniguchi, and Osumi, *Igaku Chuozasshi*, 1916, No. 230, 1481.
Futaki, Takaki, Taniguchi, and Osumi, *J. Exp. Med.*, 1916, xxiii, 249.
Futaki, Takaki, Taniguchi, and Osumi, *J. Exp. Med.*, 1917, xxv, 33.
Ishiwara, Ohtawara, and Tamura, *Nippon Eisei Gaku-Kwai Zasshi*, 1916, xi, No. 6.
Ishiwara, K., Ohtawara, T., and Tamura, K., *J. Exp. Med.*, 1917, xxv, 45.
Kitagawa and Mukoyama, *Igaku Chuozasshi*, 1916, No. 230, 1483.
Midzukuchi, *Igaku Chuozasshi*, 1916, No. 230, 1485.
Miura and Toriyama, *Tokyo Igaku-Kwai-Zasshi*, 1897, xi, No. 23.

EXPLANATION OF PLATES.

PLATE 32.

FIG. 1. Various forms of spirochetes found in the tissues. From silver preparations.

PLATE 33.

FIG. 2. Spirochetes found in renal casts. From silver preparations.

PLATE 34.

Spirochetes in the tissues.

FIG. 3. Spirochete in cortex of suprarenal. $\times 1,130$.

FIGS. 4 to 6. Spirochetes in urinary casts. Fig. 4, $\times 630$. Fig. 5, $\times 380$. Fig. 6, $\times 460$.




FIG. 1.

(Kaneko and Okuda: Rat-bite fever.)

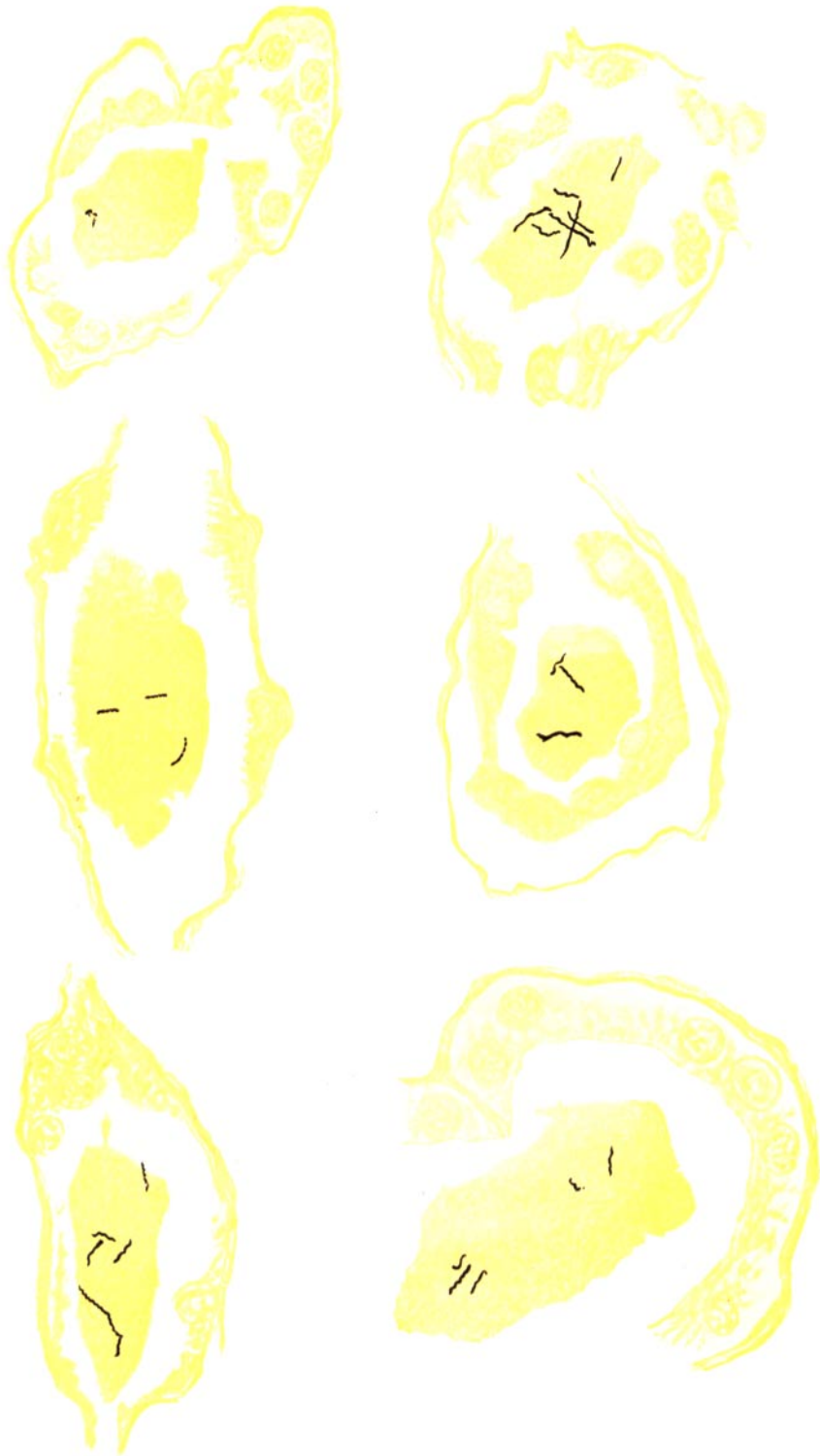

FIG. 2. (Kaneko and Okuda: Rat-bite fever.)




FIG. 3.

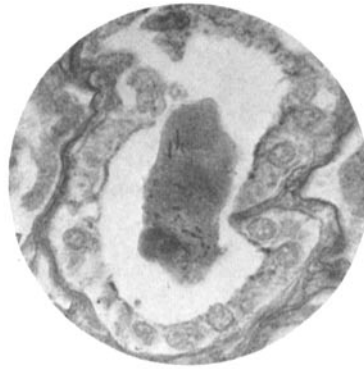

FIG. 4.

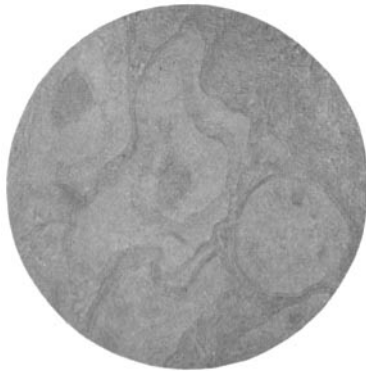


FIG. 5.

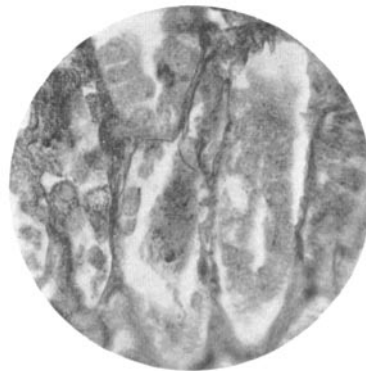


FIG. 6.

(Kaneko and Okuda: Rat-bite fever.)