

# Ultrasonographic evaluation of changes in the joint before and after intra-articular injection in children with juvenile idiopathic arthritis

 Seyma Turkmen,  Betul Sozeri

Department of Pediatric Rheumatology, University of Health Sciences, Umraniye Training and Research Hospital, Istanbul, Turkiye

## ABSTRACT

**OBJECTIVE:** The aim of this study is to ultrasonographically (US) evaluate the course of the knee joint in oligoarticular juvenile idiopathic arthritis (JIA) patients who received intra-articular steroid (IAS) application to the knee joint.

**METHODS:** 237 knee joints of 175 patients with oligoarticular JIA were evaluated retrospectively. The patients were divided into two groups: those who received only IAS therapy and those who were methotrexate to IAS therapy. Synovial fluid grade changes, synovial proliferation in B mode examination and power Doppler (PD) changes were evaluated with musculoskeletal ultrasonography (MSUS) separately for each joint before the treatment and at the 2<sup>nd</sup>, 6<sup>th</sup> and 12<sup>th</sup> weeks of the treatment.

**RESULTS:** The percentages of regression in synovial fluid grade at the second, sixth, and 12<sup>th</sup> weeks were respectively 73.4%, 88.6%, and 89.0% (n=174, 210, 211, respectively). Meanwhile, the percentages of regression in PD grade were 69.2%, 82.7%, and 84.0% (n=164, 196, 199, respectively). At the second, sixth and 12<sup>th</sup> weeks, the percentage of those with synovial fluid grade 0 was 24.1%, 54.9%, 73.4%, respectively (n=57, 130, 174, respectively), while the percentage of those with PD grade 0 was 39.7%, 67.9%, 80.6%, respectively (n=94,161,191, respectively). The percentage of those without synovial proliferation in the second, sixth and 12<sup>th</sup> weeks was found to be 26.2%, 54.9%, 73.8% respectively (n=62, 130, 175, respectively). The mean time to regression of synovial fluid, synovial proliferation, and PD in the only IAS group was significantly short. The percentage of synovitis regression was higher in the only IAS group at all weeks. This difference was especially more pronounced in the early period. When the 12<sup>th</sup>-week results were evaluated, there was no difference between the two groups.

**CONCLUSION:** This study highlights the utility of MSUS in evaluating the early results of IAS therapy applied to the knee joint in oligoarticular JIA patients.

*Keywords:* Intraarticular steroid; oligoarticular juvenile idiopathic arthritis; ultrasonography.

**Cite this article as:** Turkmen S, Sozeri B. Ultrasonographic evaluation of changes in the joint before and after intra-articular injection in children with juvenile idiopathic arthritis. *North Clin Istanbul* 2024;11(3):241–248.

Juvenile idiopathic arthritis (JIA), the most prevalent rheumatologic disease in childhood, emerges before age 16, persists beyond six weeks, and is diagnosed clinically, excluding other causes of arthritis [1, 2]. Oligoarticular JIA, the predominant subtype (over 40% of cases), involves arthritis in four or fewer joints during the initial six months [2, 3]. Diagnosis relies on clinical assessment, with elevated inflammation markers such as CRP and ESR being non-specific [4]. Synovitis, characterized by immune cell in-

filtration, is a key feature, emphasizing the need for effective treatment to prevent lasting damage [1–4]. While non-steroidal anti-inflammatory drugs (NSAIDs) are often a first-line option, they provide relief without controlling arthritis [3]. Intra-articular corticosteroid injections are commonly employed for rapid joint symptom relief, potentially obviating the need for regular systemic treatment [2–6]. Methotrexate, a primary disease-modifying agent (DMARD), is typically initiated after NSAIDs or intra-articular cor-

*Received:* December 10, 2023

*Accepted:* January 01, 2024

*Online:* June 24, 2024



**Correspondence:** Betul SOZERI, MD. Saglik Bilimleri Universitesi, Umraniye Egitim ve Arastirma Hastanesi, Cocuk Romatoloji Klinigi, Istanbul, Turkiye.

Tel: +90 216 660 47 97 e-mail: drbetulsozeri@gmail.com

Istanbul Provincial Directorate of Health - Available online at [www.northclinet.com](http://www.northclinet.com)

ticosteroids failures, with some practitioners combining it with intra-articular steroid (IAS) therapy to pursue early aggressive intervention for enhanced recovery and reduced recurrence risk, including uveitis [3].

Musculoskeletal ultrasound (MSUS) plays a crucial role in assessing disease activity, tracking therapeutic advancements, and determining the state of remission in pediatric rheumatic conditions [7]. It is an objective, easily accessible, fast, safe and non-invasive technique for evaluating treatment response in JIA. At the same time, it is a very sensitive method that can show subclinical inflammation [1, 4, 8].

The aim of this study is to ultrasonographically (US) evaluate the course of the knee joint in oligoarticular juvenile idiopathic arthritis (JIA) patients who received intra-articular steroid (IAS) application to the knee joint.

## MATERIAL AND METHODS

### Patients

This study is a retrospective, cross-sectional, single-center study conducted at the Pediatric Rheumatology Clinic of Umraniye Training and Research Hospital. Between 2019 and 2022, 248 patients diagnosed with oligoarticular JIA according to the International League of Rheumatology Association (ILAR) classification revised in 2001 [9] were included in the study.

According to our clinical protocol, when a patient is diagnosed with oligoarticular JIA, we perform IAS as initial treatment, especially if there is monoarticular involvement. However, we add subcutaneous methotrexate treatment to the following patients:

- ✦ The patients who are younger than five years old at the time of diagnosis
- ✦ The patients with multiple joint involvement and/or small joint involvement,
- ✦ The patients with uveitis at baseline,
- ✦ The patients who do not respond to IAS therapy at the second-week visit or who have a flare during follow-up.

The following patients were excluded from the study:

- ✦ Patients who had previously received treatment with synthetic or biological DMARDs,
- ✦ Patients who received systemic corticosteroids within 3 months before IAS treatment or during the 12-week follow-up period,
- ✦ Among patients receiving methotrexate treatment, patients who had to discontinue methotrexate treatment within the first 12 weeks due to intolerance or adverse effects,

### Highlight key points

- The study highlights the importance of utilizing musculoskeletal ultrasound (MSUS).
- MSUS is crucial in assessing the early responses to intra-articular steroid (IAS) therapy in the knee joint of oligoarticular juvenile idiopathic arthritis (JIA) patients.
- Traditional scoring systems fall short in detecting subclinical inflammation, a limitation overcome by MSUS.
- The use of MSUS provides clinicians with valuable insights for effectively managing JIA in its early stages.

- ✦ Patients who withdraw consent,
- ✦ Patients who were lost in follow-up,
- ✦ Patients with missing file data.

Patients who had received NSAID therapy were not excluded from the study. Finally, 237 knee joints of 175 patients were included in the study. Patients were divided into two groups: Group 1 and Group 2. 65 patients in Group 1 and 110 patients in Group 2 were obtained.

Group 1 was the group that received only IAS treatment, and Group 2 was the group that received IAS plus, subcutaneous methotrexate at a dose of 15 mg/m<sup>2</sup> (maximum 20 mg) weekly plus folic acid (25–50% of the methotrexate dose in mg, the day after methotrexate administration). IAS therapy was administered to all patients' knee joints as triamcinolone hexacetonide (1 mg/kg, maximum 40 mg). All parents were informed about the possible side effects of IAS application and written consent for the injection was obtained from each of them. The study was conducted in accordance with the Declaration of Helsinki and approved by the Umraniye Training and Research Hospital Clinical Research Ethics Committee (date: 21.03.2023, number: B.10.1.TKH.4.34.H.GP.01/81).

### Assessment of Treatment Responses

The first visit was called W0. At W0, patients' clinical histories, physical examinations, clinical Juvenile Arthritis Disease Activity Score 10 (c-JADAS 10) [10], disease activity classification according to c-JADAS 10 [10], and initial MSUS evaluation were scanned from the files and recorded in a database. Patients' files were also scanned for CRP and anti-nuclear antibody (ANA) tests at W0. Results were recorded at time point W0 in the same database. Visit data for the second (W2), sixth (W6), and twelfth (W12) weeks were recorded in the same way. Clinical history, physical ex-

amination, and MSUS evaluation results were scanned for all visits and recorded in the database in the relevant weeks. An additional c-JADAS 10 and disease activity classification based on c-JADAS 10 assessment were screened for W12 and recorded in the W12 column in the database. The obtained data were analyzed in computer environment.

In our clinic, the lighting in the examination room is always adapted to suit the physical examination and subsequent ultrasonographic evaluation, respectively. Before the MSUS evaluation, participants are seated with their examined knees bent at 30 degrees. Images are displayed in both B mode and power Doppler (PD). B-mode settings contain a frequency range of 9–15 MHz and Doppler is measured with low flow settings containing a pulse repetition frequency (PRF) <1.0, low wall filter and frequency are fixed to provide maximum sensitivity as well as gain set to just below artifact levels. Before treatment (W0), at the 2<sup>nd</sup> (W2), 6<sup>th</sup> (W6) and 12<sup>th</sup> (W12) weeks of treatment, synovial fluid degree change, synovial proliferation in B-mode examination and PD change were scanned from the files separately for each joint. MSUS evaluation is performed by an investigator (BS) who is experienced and trained (EULAR) in MSUS. Semi-quantitative scoring system ranging from 0 (normal) to 3 (severe) is used for both B-Mode and Doppler assessment.

We currently apply the current protocol described by Ting et al. [11] for the semiquantitative scoring system in our clinic.

For the suprapatellar recess, B-mode images were scored as follows [11]:

Images are obtained from the longitudinal position of the probe.

**Grade 0 (Normal Knee):** The image shows a slender slit of fluid/synovium without lifting the pre-patellar fat pad, with minimal extension beyond it.

**Grade 1 (Mild Knee):** A slight elevation of the pre-patellar fat pad is observed, with minimal fluid/synovial proliferation. The extension proximally is less than 50% of the visualized portion of the quadriceps tendon.

**Grade 2 (Moderate Knee):** There is a noticeable elevation of the pre-patellar fat pad due to moderate fluid/synovial proliferation. Extension proximally is more than 50% of the visualized portion of the quadriceps tendon.

**Grade 3 (Severe Knee):** Significant fluid/synovial proliferation causes considerable distension of the

suprapatellar recess, extending throughout the image. The most proximal portion of the synovial recess is greater than 50% of the maximum distension of the recess.

For the parapatellar recess, B-mode images were scored as follows [11]:

Images are obtained from the transverse position of the probe.

**Grade 0 (Normal Knee):** The parapatellar recess appears empty, but a small bulge of fluid/synovium may extend to the patellofemoral joint line.

**Grade 1 (Mild Knee):** There is the presence of fluid/synovial proliferation, filling less than one-third of the full area of the parapatellar recess.

**Grade 2 (Moderate Knee):** The parapatellar recess contains fluid/synovial proliferation filling between one-third and two-thirds of the full area.

**Grade 3 (Severe Knee):** The parapatellar recess exhibits severe fluid/synovial proliferation, filling more than two-thirds of the full area.

Synovitis grade is defined by the higher grade after both recesses were evaluated.

Doppler images were scored as follows [11]:

**Grade 0 (Normal Doppler):** No signals are detected.

**Grade 1 (Mild Doppler):** 1–3 signals are observed within the area of synovial proliferation.

**Grade 2 (Moderate Doppler):** More than 3 signals or confluent signals are present in less than 50% of the area of synovial proliferation.

**Grade 3 (Significant Doppler Signal):** Confluent signals are present in more than 50% of the area of synovial proliferation.

## Statistical Analysis

Statistical analyses were provided with the IBM SPSS (Statistics Package for Social Sciences for Windows, Version 22.0, Armonk, NY, IBM Corp.) package program. Quantitative data were expressed as mean±SD and median (range). Qualitative data were expressed as absolute frequencies (number) and relative frequencies (percent). Depending on the normal distribution of the tested variable, analyses were performed using X2 test for categorical data and analysis of variance (ANOVA) or Mann-Whitney U test for continuous data. All tests were two-sided. P-value <0.05 was considered statistically significant.

**TABLE 1.** Demographic and clinical characteristics of the groups

	Group 1 (n=65)	Group 2 (n=110)	p
Girls (%)	49.2	68.2	
Boys (%)	50.8	31.8	0.215
Mean age at diagnosis (years)	10.67±4.40	8.66±4.59	0.003
Mean injection age (years)	11.76±4.02	9.77±4.71	0.002
Mean time taken to add methotrexate (days)		11.65±7.02	
CRP positivity at W0 (%)	38.46	36.04	0.421
ANA positivity at W0 (%)	17 (26.15)	72 (65.45)	0.178
Median c-JADAS 10 at W0	6 (3–20)	7 (2–18)	
Median c-JADAS 10 at W12	0 (0–8)	0 (0–9)	
>G1 synovial fluid at W0 (%)	90.7	92.4	0.797
Synovial proliferation at W0 (%)	92	99.4	0.007
Power doppler activity at W0 (%)	89.2	96.5	0.160
Mean time to regression of synovial fluid (weeks)	5±3.41	6.88±3.93	0.004
Mean time to regression of synovial proliferation (weeks)	5.43±3.36	7.01±3.96	0.018
Mean time to regression of power doppler activity (weeks)	4.2±2.77	6.07±3.92	0.002
Patients with flare in synovial fluid (%)	1.53	9.09	0.145
Patients with flare in power doppler activity (%)	<b>1.53</b>	<b>10.0</b>	<b>0.112</b>

CRP: C-reactive protein; ANA: Anti-nuclear antibody; c-JADAS 10: Clinical Juvenile Arthritis Disease Activity Score 10; W: Week G: Grade.

## RESULTS

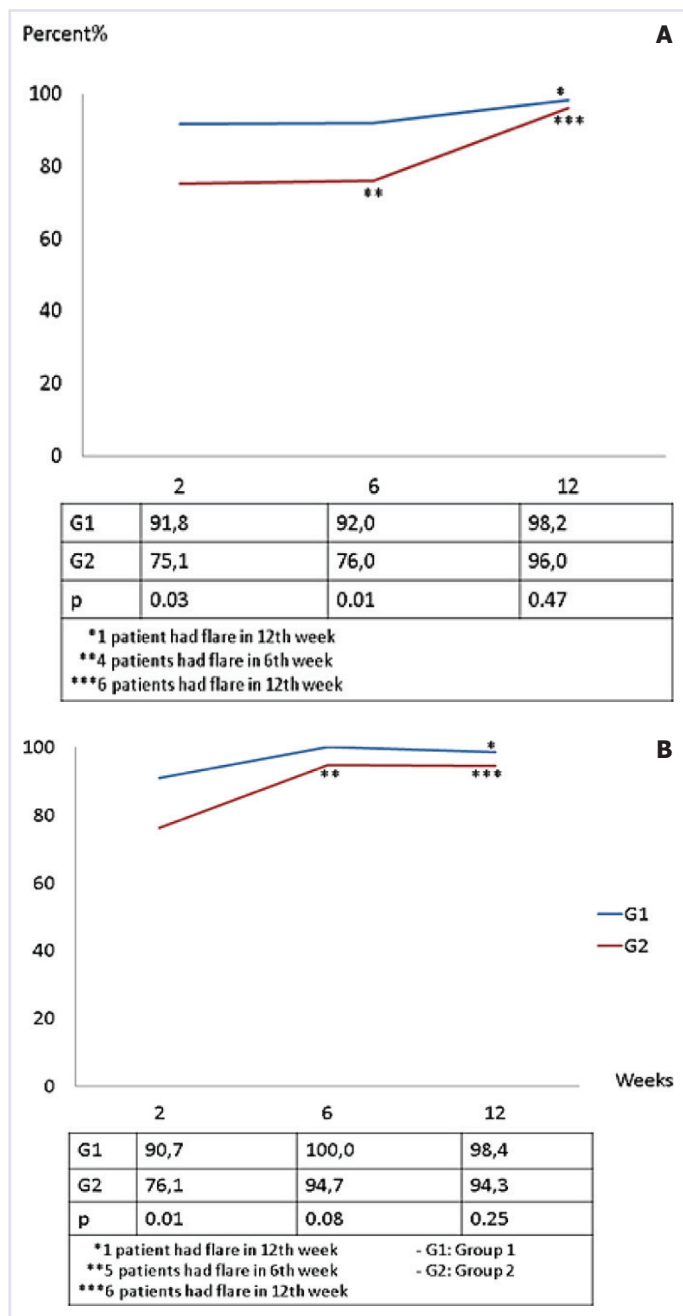
In this study; 237 knee joints of 175 patients with active oligoarticular JIA were evaluated. 61.1% of the patients were girls (n=107). The mean age at diagnosis was 9.21±4.62 (1–17.90) years. The mean of applying IAS age was 10.35±4.60 (1.33–17.90) years. 37.14% (n=65) of the patients constituted Group 1. The mean time for adding methotrexate to the treatment of patients in Group 2 was 11.65±7.02 (0–28) days.

While the mean age of the patients in Group 1 was older than those in Group 2 (respectively 10.67±4.40 and 8.66±4.59 years) (p=0.003). Likewise, the mean IAS age was greater than the other group (p=0.002). 36.70% of the patients (n=87) were CRP positive at W0. There was no difference in CRP positivity between Group 1 and Group 2 at W0 (p=0.42). ANA positivity was present in 50.8% (n=89) of patients. There was no difference in ANA positivity in Group 1 and Group 2 at W0 (p=0.178). The median c-JADAS 10 of the patients was 7 (2–20) at W0. All patients had moderate to high disease activity according to c-JADAS 10 at W0. There was no difference in terms of disease activity classification by c-JADAS 10 in Group 1 and Group 2 at W0

(p=0.50). At W12, 100% of patients had regression of c-JADAS 10. Median c-JADAS 10 was detected 0 (0–9) at W12. At W12, 94.09% (n=207) of patients had inactive disease or low disease activity according to c-JADAS 10. When the W12 results were evaluated, there was no difference in terms of disease activity classification according to c-JADAS 10 in Group 1 and Group 2 (p=0.13). The demographic and clinical characteristics of the groups are summarized in Table 1.

Patients' MSUS findings were as follows: While there was no difference between the two groups in terms of synovial fluid grade and PD activity at W0, patients in Group 2 had more synovial proliferation compared to Group 1 at W0 (p=0.797, p=0.16 and p=0.007, respectively) (Table 1).

When all patients who underwent IAS application were evaluated, the following data were obtained: The percentages of regression in synovial fluid grade at the second, sixth, and 12<sup>th</sup> weeks were respectively 73.4%, 88.6%, and 89.0% (n=174, 210, 211, respectively). Meanwhile, the percentages of regression in PD grade were 69.2%, 82.7%, and 84.0% (n=164, 196, 199, respectively). At the second, sixth and 12<sup>th</sup> weeks, the percentage of those with synovial fluid grade 0 was 24.1%,



**FIGURE 1.** Percentages of decrease in synovial fluid grade and power Doppler activity by weeks. **(A)** Percentages of regression of synovial fluid grades by weeks. **(B)** Percentages of regression of power Doppler activities by weeks.

54.9%, 73.4%, respectively (n=57, 130, 174, respectively), while the percentage of those with PD grade 0 was 39.7%, 67.9%, 80.6%, respectively (n=94,161,191, respectively). The percentage of those without synovial proliferation in the second, sixth and 12<sup>th</sup> weeks was found to be 26.2%, 54.9%, 73.8% respectively (n=62, 130, 175, respectively).

The mean time to regression of synovial fluid, synovial proliferation, and PD activity in Group 1 was significantly shorter than in Group 2 (p=0.004, p=0.018, p=0.002, respectively) (Table 1).

In W12 in the Group 1, the synovial fluid grade regressed to grade 0 in 80% (n=52) of the joints, and 46% of this regression occurred in the first 2 weeks, whereas in the Group 2, 75.5% of the joints' (n=130) synovial fluid grade showed regression to grade 0. And 73.8% (n=96) of this regression occurred after the first 2 weeks. The percentage of regression in synovial fluid grade and disappearance of synovial proliferation were higher in Group 1 in all weeks. This difference was especially evident in W2 and W6. In the period after W6, the recovery percentage in Group 2 was increasing rapidly. There was no significant difference in the percentage of regression of synovial fluid grade between the two groups at W12 (Fig. 1A). The percentage of flare in synovial fluid was 1.53% (n=1) in Group 1 and 9.09% (n=10) in Group 2. There was no difference between the two groups in terms of flare percentages during the follow-up period (Table 1).

The percentage of regression in PD activity was higher in Group 1 in all weeks. This difference was highest in W2. At W6, there was a regression in PD activity in all of the joints in Group 1 and in 94.7% of Group 2. There were no significant differences between the two groups in terms of PD activity at W6 and W12 (Fig. 1B). The percentage of flare in PD activity was 1.53% (n=1) in Group 1 and 10.0% (n=11) in Group 2. There was no difference between the two groups in terms of flare percentages during the follow-up period (Table 1).

No relationship was found between CRP positivity and synovial fluid grade, proliferation status and PD activation, at W0 (p=0.47, p=0.28, p=0.43, respectively). There was no relationship between CRP positivity at W0 and the percentages of flare in synovial fluid and PD activation (p=0.17, p=0.10, respectively). A decrease in synovial fluid grade was detected in 99.2% (n=138) of CRP-negative patients at W6 (p=0.02). However, when evaluating at W12, there was no significant difference between CRP positive and negative patients in terms of the percentage of synovial fluid regression (p=0.41).

No relationship was found between ANA positivity and synovial fluid grade, proliferation status and PD activation, at W0 (p=0.42, p=0.40, p=0.55, respectively). There was no relationship between ANA positivity at W0 and the percentages of flare in synovial fluid and PD activation (p=0.89, p=0.69, respectively). While synovi-

al fluid grade regression was observed in W2 in 93.3% (n=28) of ANA-negative patients in Group 1, this rate was 69.4% (n=41) in Group 2 (p=0.014). However, when the W12 results were examined, an improvement of 100% in Group 1 and 93.7% in Group 2 was observed, respectively, and no significant difference was found between the two groups (p=0.32).

## DISCUSSION

This study documents ultrasonographically the results of early period of the knee joint treated with IAS in oligoarticular JIA. We found that the majority of patients receiving IAS treatment entered the recovery period in the first two weeks, and that there was no difference in the 12<sup>th</sup> week results between those who received only IAS treatment and those who received IAS + subcutaneous methotrexate treatment. In our study, the average regression time of synovitis findings in the group receiving monotherapy was found to be shorter compared to combined treatment. This result may be due to higher synovial proliferation in the combined treatment group, although there was no difference between the two groups in terms of c-JADAS 10. This finding may suggest that subclinical inflammation detected by MSUS in oligoarticular JIA patients may play an important role in disease management. However, when the 12-week follow-up period was evaluated, the recovery process was accelerated in the group receiving combined treatment after the 6<sup>th</sup> week and no difference was found between the two groups at the 12<sup>th</sup> week. This finding is compatible with the 4–6-week period reported in the literature that requires the onset of methotrexate effect [11, 12].

In children with JIA, IAS provides symptomatic improvement in the early period and can prevent irreversible joint destruction in the long term [2, 6, 13–15]. In 1998, Padeh and Passwell [16] studied 300 IAS treatments on 61 JIA patients over 5 years, finding it both effective and safe. They observed that IAS alone in oligoarticular JIA not only eliminated the need for systemic therapy but also prevented joint destruction. Similarly, Breit et al. [13] in a 2000 study reported IAS effectiveness across all JIA subgroups with a low risk of major complications. In a 2011 study by Bloom et al. [6], the retrospective evaluation of IAS injections involved 61 JIA patients who received a total of 121 injections. Over three-month intervals, the effectiveness and safety of IAS were assessed in treated joints, considering swelling and range of motion. Patients and parents were interviewed about post-injection pain

and morning stiffness. The study concluded that IAS therapy, especially using triamcinolone hexacetonide at 1–1.5 mg/kg for large joints, proves effective and safe for JIA treatment. Honkanen et al. [14] found that after IAS was performed on the knee joint of 79 children with early JIA, the duration of remission was much longer than that of methylprednisolone, and this difference was still significant two years after the injection. Similarly, in 2017, Jana and Gupta [8] reported that IAS can be chosen as the primary treatment method in mild oligoarticular JIA because of the risks of side effects of systemic therapy. In a 2017 multicenter, prospective, randomized controlled study, Ravelli et al. [3] compared the efficacy of IAS alone and combined IAS with oral methotrexate in oligoarticular JIA based on clinical parameters. They concluded that the combination of IAS and methotrexate did not enhance the early effectiveness of IAS treatment. However, the group receiving combined therapy exhibited a longer median remission time until flare compared to the monotherapy group, suggesting potential long-term benefits. Notably, knee joints, when treated with IAS, had the lowest flare rate among the joints studied in this research.

In 2011, Lanni et al. [17] found that patients with JIA who had IAS had a higher risk of flare in patients with CRP positivity and those with negative ANA. In our study, the relationship between CRP and ANA positivity at baseline and flare status could not be demonstrated. Allen et al. [18] argued that CRP negativity in children who underwent IAS was associated with a short disease duration. Similar to our study, Harhay et al. [2] could not find a correlation between CRP positivity before treatment, treatment response and disease duration in children who underwent IAS.

Effectively treating JIA is crucial to prevent permanent morbidity, necessitating the assessment of disease activity and treatment response [8]. Various methods, including laboratory parameters, active joint count, pain visual analog scale (VAS), juvenile arthritis disease activity score (JADAS), and American College of Rheumatology (ACR) criteria, are commonly used [19]. However, these methods fall short in measuring the extent of synovial inflammation, thus lacking sensitivity and objective information [20]. Magnetic resonance imaging is the gold standard for detecting synovial inflammation, but it is time-consuming and costly and requires sedation in young children [21]. Laurell et al. [22] in a study they conducted in 2011, found that MSUS precisely showed the anatomical location of synovial inflammation in the ankle of JIA patients. Eich et al. [23] examined the pre-

and post-treatment imaging findings of patients with JIA who had IAS and stated that MSUS is a useful tool to evaluate effusion and pannus and can be used to monitor treatment response. In 2017, Baikar et al. [4] utilized Power Color Doppler and Spectral Doppler ultrasonography to assess the response to IAS treatment in 27 JIA patients with 36 knee joints. They observed reductions in synovial hypertrophy, effusion, and color fraction, alongside increased joint range of motion and resistance index at one and two-month follow-ups. Comparison with traditional scoring systems revealed a significant correlation between ultrasonographic parameters and the number of active joints. Similarly, in 2013, Ranjan et al. [1] proposed the use of Power Color Doppler and Spectral Doppler ultrasonography indices for early diagnosis, disease activity monitoring, and treatment response assessment in JIA patients. In 2017, Mortada et al. [24] assessed the efficacy of intra-articular methotrexate versus IAS in rheumatoid arthritis (RA) patients using gray scale and power Doppler ultrasonography, suggesting that repeated intra-articular methotrexate improved clinical and ultrasonographic findings in RA patients. A 2014 study involving 36 JIA patients and 36 healthy controls detected subclinical synovitis in 41.7% of JIA patients in clinical remission and 11.1% of controls using Power Doppler imaging [25]. In 2022, Baydoun et al. [26] emphasized the effectiveness of MSUS in identifying subclinical synovitis in JIA patients. However, they found no association between subclinical synovitis detected by MSUS and treatment modifications.

In our study, we explored the use of ultrasonographic parameters as an objective measure of synovial inflammation in JIA patients undergoing IAS treatment. While operator-related effects can impact MSUS evaluations, our study maintained objectivity by having the same operator follow a standardized protocol for all patients.

Nevertheless, our study has limitations, being retrospective and cross-sectional, focused solely on oligoarticular JIA patients with knee joint involvement. Consequently, the findings may not be generalized to other JIA subtypes or joints.

## Conclusion

Our research underscores the significance of employing MSUS to assess early responses to IAS therapy in the knee joint of oligoarticular JIA patients. It reveals subclinical inflammation undetectable by traditional scoring systems, offering valuable insights for clinicians managing JIA.

**Ethics Committee Approval:** The Umraniye Training and Research Hospital Clinical Research Ethics Committee granted approval for this study (date: 21.03.2023, number: B.10.1.TKH.4.34.H.GP.0.01/81).

**Authorship Contributions:** Concept – BS, ST; Design – BS, ST; Supervision – BS, ST; Fundings – BS, ST; Materials – BS, ST; Data collection and/or processing – BS, ST; Analysis and/or interpretation – BS, ST; Literature review – BS, ST; Writing – ST; Critical review – BS.

**Conflict of Interest:** No conflict of interest was declared by the authors.

**Use of AI for Writing Assistance:** Not declared.

**Financial Disclosure:** The authors declared that this study has received no financial support.

**Peer-review:** Externally peer-reviewed.

## REFERENCES

1. Ranjan S, Jahan A, Yadav TP, Sachdev N, Dewan V, Singh S. Evaluation of synovial inflammation in juvenile idiopathic arthritis by power color Doppler and Spectral Doppler ultrasonography. *Indian J Pediatr* 2014;81:29–35. [\[CrossRef\]](#)
2. Harhay R, Jeelani W, Agbor BTA, Hennon T, Wrotniak BH, Abdul-Aziz R. Response to treatment with intra-articular triamcinolone hexacetonide and triamcinolone acetonide in oligo articular juvenile idiopathic arthritis. *Pediatr Rheumatol Online J* 2021;19:36. [\[CrossRef\]](#)
3. Ravelli A, Davì S, Bracciolini G, Pistorio A, Consolaro A, van Dijkhuizen EHP, et al. Intra-articular corticosteroids versus intra-articular corticosteroids plus methotrexate in oligoarticular juvenile idiopathic arthritis: a multicentre, prospective, randomised, open-label trial. *Lancet* 2017;389:909–16. [\[CrossRef\]](#)
4. Baikar T, Chhabra A, Yadav TP, Sachdev N, Dewan V. Power Color doppler and spectral doppler ultrasonography to evaluate response to intra-articular steroid injection in knee joints in juvenile idiopathic arthritis. *Indian J Pediatr* 2017;84:826–32. [\[CrossRef\]](#)
5. Batu ED. Glucocorticoid treatment in juvenile idiopathic arthritis. *Rheumatol Int* 2019;39:13–27. [\[CrossRef\]](#)
6. Bloom BJ, Alario AJ, Miller LC. Intra-articular corticosteroid therapy for juvenile idiopathic arthritis: report of an experiential cohort and literature review. *Rheumatol Int* 2011;31:749–56. [\[CrossRef\]](#)
7. Windschall D, Trauzeddel R, Haller M, Krumrey-Langkammerer M, Nimitz-Talaska A, Berendes R, et al. Pediatric musculoskeletal ultrasound: age- and sex-related normal B-mode findings of the knee. *Rheumatol Int* 2016;36:1569–77. [\[CrossRef\]](#)
8. Jana M, Gupta AK. USG doppler in juvenile idiopathic arthritis treatment response assessment: a much needed objective tool. *Indian J Pediatr* 2017;84:813–4. [\[CrossRef\]](#)
9. Petty RE, Southwood TR, Manners P, Baum J, Glass DN, Goldenberg J, et al. International League of Associations for Rheumatology classification of juvenile idiopathic arthritis: second revision, Edmonton, 2001. *J Rheumatol* 2004;31:390–2.
10. Consolaro A, Negro G, Chiara Gallo M, Bracciolini G, Ferrari C, Schiappapietra B, et al. Defining criteria for disease activity states in nonsystemic juvenile idiopathic arthritis based on a three-variable juvenile arthritis disease activity score. *Arthritis Care Res (Hoboken)* 2014;66:1703–9. [\[CrossRef\]](#)
11. Ting TV, Vega-Fernandez P, Oberle EJ, De Ranieri D, Bukulmez H, Lin C, et al. Novel ultrasound image acquisition protocol and scoring system for the pediatric knee. *Arthritis Care Res (Hoboken)* 2019;71:977–85. [\[CrossRef\]](#)

12. van de Meeberg MM, Hebing RCF, Nurmohamed MT, Fidler HH, Heymans MW, Bouma G, et al. A meta-analysis of methotrexate polyglutamates in relation to efficacy and toxicity of methotrexate in inflammatory arthritis, colitis and dermatitis. *Br J Clin Pharmacol* 2023;89:61–79. [\[CrossRef\]](#)
13. Breit W, Frosch M, Meyer U, Heinecke A, Ganser G. A subgroup-specific evaluation of the efficacy of intraarticular triamcinolone hexacetonide in juvenile chronic arthritis. *J Rheumatol* 2000;27:2696–702.
14. Honkanen VE, Rautonen JK, Pelkonen PM. Intra-articular glucocorticoids in early juvenile chronic arthritis. *Acta Paediatr* 1993;82:1072–4. [\[CrossRef\]](#)
15. Rocha RH, Natour J, Dos Santos RM, Furtado RNV. Time effect of intra-articular injection with triamcinolone hexacetonide and its correlations: a case-control prospective 12-month study. *Am J Phys Med Rehabil* 2019;98:872–8. [\[CrossRef\]](#)
16. Padeh S, Passwell JH. Intraarticular corticosteroid injection in the management of children with chronic arthritis. *Arthritis Rheum* 1998;41:1210–4. [\[CrossRef\]](#)
17. Lanni S, Bertamino M, Consolaro A, Pistorio A, Magni-Manzoni S, Galasso R, et al. Outcome and predicting factors of single and multiple intra-articular corticosteroid injections in children with juvenile idiopathic arthritis. *Rheumatology (Oxford)* 2011;50:1627–34. [\[CrossRef\]](#)
18. Allen RC, Gross KR, Laxer RM, Malleson PN, Beauchamp RD, Petty RE. Intraarticular triamcinolone hexacetonide in the management of chronic arthritis in children. *Arthritis Rheum* 1986;29:997–1001. [\[CrossRef\]](#)
19. Consolaro A, Ruperto N, Bazso A, Pistorio A, Magni-Manzoni S, Filocamo G, et al. Development and validation of a composite disease activity score for juvenile idiopathic arthritis. *Arthritis Rheum* 2009;61:658–66. [\[CrossRef\]](#)
20. Giannini EH, Ruperto N, Ravelli A, Lovell DJ, Felson DT, Martini A. Preliminary definition of improvement in juvenile arthritis. *Arthritis Rheum* 1997;40:1202–9. [\[CrossRef\]](#)
21. Miller E, Uleryk E, Doria AS. Evidence-based outcomes of studies addressing diagnostic accuracy of MRI of juvenile idiopathic arthritis. *AJR Am J Roentgenol* 2009;192:1209–18. [\[CrossRef\]](#)
22. Laurell L, Court-Payen M, Nielsen S, Zak M, Boesen M, Fasth A. Ultrasonography and color Doppler in juvenile idiopathic arthritis: diagnosis and follow-up of ultrasound-guided steroid injection in the ankle region. A descriptive interventional study. *Pediatr Rheumatol Online J* 2011;9:4. [\[CrossRef\]](#)
23. Eich GE, Hallé F, Hodler J, Seger R, Willi UV. Juvenile chronic arthritis: imaging of the knees and hips before and after intraarticular steroid injection. *Pediatr Radiol* 1994;24:558–63. [\[CrossRef\]](#)
24. Mortada MA, Abdelwhab SM, Elgawish MH. Intra-articular methotrexate versus corticosteroid injections in medium-sized joints of rheumatoid arthritis patients-an intervention study. *Clin Rheumatol* 2018;37:331–7. [\[CrossRef\]](#)
25. Bugni Miotto e Silva V, de Freitas Tavares da Silva C, de Aguiar Vilela Mitraud S, Nely Vilar Furtado R, Esteves Hilário MO, Natour J, et al. Do patients with juvenile idiopathic arthritis in remission exhibit active synovitis on joint ultrasound? *Rheumatol Int* 2014;34:937–45. [\[CrossRef\]](#)
26. Baydoun S, Jousse-Joulin S, Saraux A, Dusser-Benesty P, Borocco C, Galeotti C, et al. Criteria associated with treatment decisions in juvenile idiopathic arthritis with a focus on ultrasonography: results from the JIRECHO cohort. *Rheumatol Ther* 2023;10:225–38. [\[CrossRef\]](#)