



## Supplement Article

# Navigation bronchoscopy: A new tool for pulmonary infections

Syed Faaz Ashraf and Kelvin K.W. Lau\*

Department of Thoracic Surgery, Barts Thorax Centre, St Bartholomew's Hospital, West Smithfield, London EC1A 7BE, UK

\*To whom correspondence should be addressed. Kelvin K.W. Lau, Department of Thoracic Surgery, Barts Thorax Centre, St Bartholomew's Hospital, West Smithfield, London EC1A 7BE, UK. Tel.; Fax;; E-mail: [kelvin.lau@bartshealth.nhs.uk](mailto:kelvin.lau@bartshealth.nhs.uk)

Received 24 January 2019; Editorial Decision 20 March 2019

## Abstract

Infections remain a common cause of lung nodules, masses, and cavities. Safe tissue sampling is required to establish a diagnosis, differentiate between malignant and infectious causes, and provide microbiological material for characterization and sensitivity analysis. Tissue samples could be obtained bronchoscopically, percutaneously, or through surgical biopsy. Among these, bronchoscopy is the safest by avoiding the complications of pleural and chest wall puncture including pneumothorax, pain, pleural contamination and empyema, and hemothorax. However, the diagnostic yield with conventional bronchoscopy for small, peripheral lesions is poor. Electromagnetic navigation bronchoscopy (ENB) is a technique where the bronchoscope and working channel are guided through the bronchial tree to accurately reach a peripheral lesion. It dramatically improves on the diagnostic yield of peripheral lesions especially of small lesions, and its role has developed beyond diagnosis to treatment enablement and to direct therapy. Its role in infection is less defined, but it has value especially in the diagnosis of fungal and mycobacterial infections and in cavitating lesions. This review will explore what electromagnetic navigation bronchoscopy is, its use in diagnosis and therapy, and its role in the management of pulmonary infections. The potential for local therapy delivery for infection is also discussed.

**Key words:** Navigation Bronchoscopy, Cone beam CT, Hybrid theatre, Guided bronchoscopy, Cavitating lesion.

## Introduction

Small pulmonary lesions are increasingly identified as cross-sectional imaging becomes more and more common in clinical practice. Nodules are identified in patients presenting with respiratory symptoms and also incidentally on scans for other purposes. This is even more pertinent in patients presenting with common symptoms of breathlessness and fever, where infection is a significant differential diagnosis, with the subsequent need to confirm this and identify the causative organism.

The most common noninvasive approach to biopsy lung lesions is computed tomography (CT) guided transthoracic needle aspiration (TTNA). A recent meta-analysis reported a pooled diagnostic yield of 92%.<sup>1</sup> Ultrasound-guided TTNA is also used for subpleural lesions where there is no intervening air that would attenuate the ultrasound waves. It has a similarly high diagnostic yield of 89%.<sup>1</sup> TTNA, however, has a high

complication rate, the most common being pneumothorax (20–40%) with many requiring chest drain insertion and a period of hospital stay.<sup>2</sup> In addition, TTNA may not be suitable for lung lesions in the lower part of the chest, which moves with the diaphragm and so has a high excursion range during the respiratory cycle and are difficult to target, central lesions in the hilum in proximity to the hilar vascular structures, or those beneath the scapula. Certain patient characteristics are also unfavourable for percutaneous biopsy. Patients with severe chronic obstructive pulmonary disease (COPD) are at high risk of poorly tolerated pneumothorax and persistent airleak requiring chest drainage and prolonged hospitalizations. Patients with multiple lung nodules require multiple punctures, which are both uncomfortable and increases the risk of pneumothorax. Patients with bilateral lesions for bilateral biopsy, and patients with previous pneumonectomy and new lung nodules where collapse of the only lung can be fatal, are also high risk for TTNA.

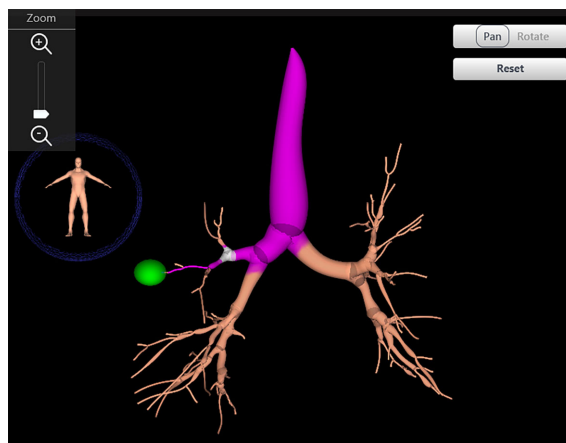
Pneumothoraces contribute to significant patient morbidity especially if chest drain insertion is required, leading in most cases to an admission and an increased length of stay. They can also be fatal, especially in patients with poor lung function. Furthermore, chest drain insertion is a very uncomfortable experience and carries risks of bleeding, damage to structures such as heart, lung, and liver, and empyema. Other risks of transpleural puncture include hemorrhage most commonly from injury to an intercostal vessel, pleuritis, and pleural effusion. In the context of infection, transpleural puncture can seed infection into the pleural space and lead to an empyema. Furthermore, pleural contamination and empyema could compound the infection and treatment burden for the patient.

Bronchoscopy is widely used for the diagnosis and treatment of benign and malignant diseases of the trachea and proximal bronchial tree. It has the advantage of not puncturing the chest wall or pleura and so carries a much lower rate of pneumothorax and has a minute risk of hemothorax, pain, pleuritis, or pleural effusion. Conventional flexible bronchoscopy can reach the fifth generation (subsegmental) bronchi. It is carried out in one sitting and has a very low complication rate.<sup>3</sup> While bronchoscopy can be extremely effective for lesions located in the proximal bronchial tree, nodules located in the peripheral third of the lung are beyond the subsegmental bronchi and so could not normally be reached with a conventional bronchoscopy. As the bronchial tree divides, the luminal diameter reduces and the bronchoscope becomes wedged in and cannot advance further. The view is also lost as the scope is pushed against the bronchial wall.<sup>4</sup> Furthermore, the number of branches increases as the bronchi divides, it can be very difficult to tell which of the many divisions lead to the lesion. Diagnostic yield for peripheral lesions is therefore as low as 14% for peripheral nodules under 2 cm.<sup>5</sup> Not only is it difficult to identify the correct bronchus to the lesion, it is also very difficult to judge how far to advance a biopsy instrument down the bronchus. For small lesions, even a slight movement may mean the biopsy instrument going past the lesion.

In many areas of medicine, from gastroenterology to vascular surgery, from urology to neurosurgery, the approach to organs has increasingly moved to an endoluminal approach with endoscopy, supplemented by real-time image-guidance. The lung has been one of the last organs to benefit from this revolution, in part due to the complex configuration and arborization of the bronchial tree and its continuous movement with respiration. The technology behind ENB finally allows lung lesions to be reached and treated endoluminally.

### What is electromagnetic navigation bronchoscopy (ENB)?

Electromagnetic navigation bronchoscopy (ENB) is a form of guided bronchoscopy. It consists of a conventional broncho-

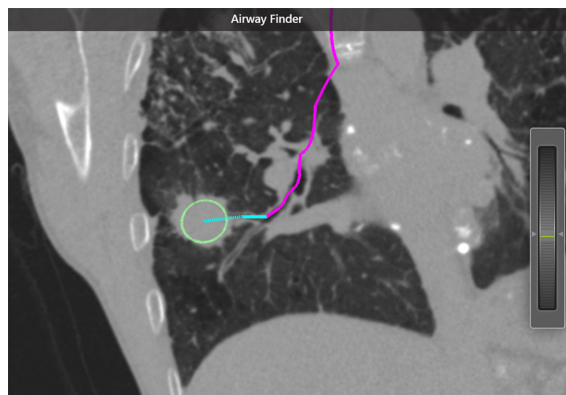

**Figure 1.** The virtual bronchial tree: the bronchial tree and its arborization are recreated from the CT scan using a process called segmentation. This Figure is reproduced in color in the online version of *Medical Mycology*.

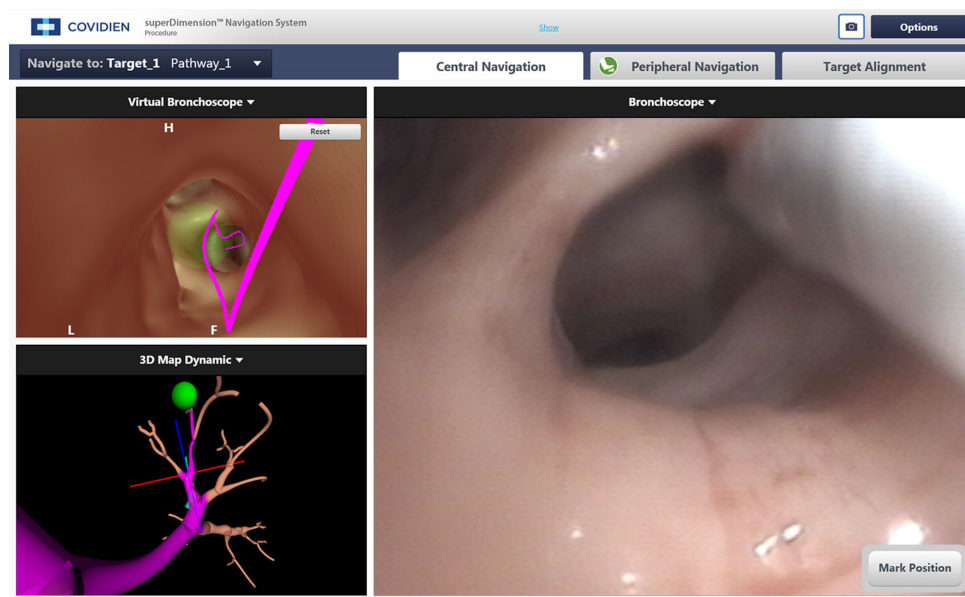
scope, an electromagnetic generator with sensors and computer software loaded with the patient's CT thorax images. A small, flexible channel (extended working channel [EWC]) extends out from the bronchoscope and is guided through the bronchial tree to a lesion. The EWC is very small and can reach all the way to the periphery and pleura of the lung.

Prior to the procedure, the system uses the CT to create a virtual bronchial tree much like a road map (Fig. 1). The operator identifies the target lesion and the system plans a pathway through the bronchial tree to the target (Fig. 2).

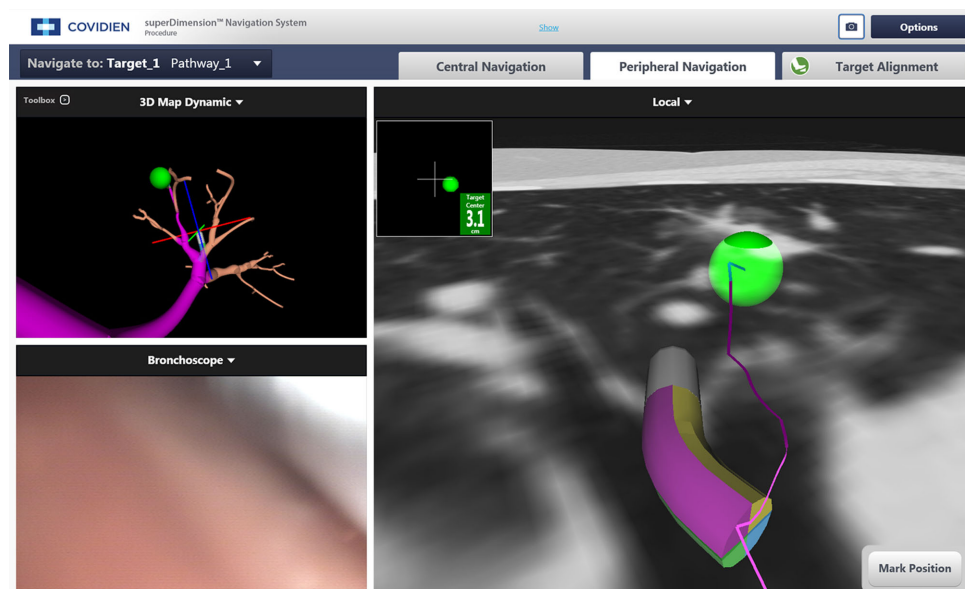
There is a removable sensor at the tip of the EWC, the locatable guide. This localizes the probe within the sensing volume. During the procedure the electromagnetic field and locatable guide allows the computer to track the location of the probe in the patient's lungs. The operator can then follow the pre-planned path through the bronchial tree to the target location, much like GPS navigation when driving (Fig. 3). When it is no



**Figure 2.** Target selection and pathway creation: the operator selects the target of interest, shown here by the green circle. The software then automatically plans the quickest pathway to the lesion (pink line). This Figure is reproduced in color in the online version of *Medical Mycology*.



**Figure 3.** Navigation through the central airways: On the right is the view from the bronchoscope. On the top left is the virtual bronchoscopy indicating the pathway to take. This Figure is reproduced in color in the online version of *Medical Mycology*.



**Figure 4.** Peripheral navigation: The bronchoscope is in a wedged position and cannot be advanced any further (left lower image). The dynamic CT reconstruction allows the pathway ahead and the target to be visualized virtually to enable navigation to proceed despite lack of vision. This Figure is reproduced in color in the online version of *Medical Mycology*.

longer possible to visualize the airway after the bronchoscope is wedged in, the computer software and electromagnetic sensors allow navigation to continue in a virtual reality mode using the known position of the sensor and the CT scan around that position (Fig. 4).

There are several guided bronchoscopy systems on the market, but here we will restrict our discussion to the system with the largest body of real-world experience and evidence: SuperDimension (Medtronic, Minneapolis, MN, USA).

## How is ENB carried out?

### Planning the procedure

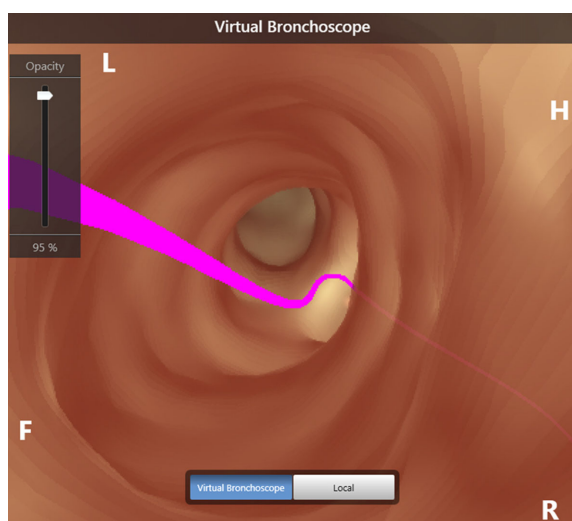
There are two main steps involved in ENB: planning the procedure and the bronchoscopy procedure itself. Planning can be carried out prior to the procedure without the patient. A planning CT is performed according to parameters defined by the manufacturers to optimise bronchial tree reconstruction. The CT thorax images are uploaded into the planning software.

The software identifies the airway wall by looking for the sharp change in Hounsfield units transitioning from airway lumen to the surrounding tissue. The software labels these pixels of sharp transition as the bronchial wall and can therefore reconstruct the entire bronchial tree. This process of selecting pixels of the CT scan based on a defined common criteria and labeling them is called segmentation.

The patient's CT scan is loaded into the software. The bronchial tree is segmented out. The operator then defines the target and the nearest bronchus to the lesion, and the software will plot the pathway to the lesion.

It is not always necessary to perform a new CT scan. It is also possible to use a preexisting CT scan to avoid an additional scan, but a trial run with this scan should be carried out before the procedure to ensure segmentation is satisfactory. Furthermore, the CT should not be more than a couple of weeks old, as the lesion appearance and location may change especially in infective processes. In a number of scans, the lesions may resolve thereby obviating the need to perform the procedure. One study found that 6.9% of 116 patients' lung lesions on the same day CT scan decreased in size or had completely resolved when compared to their previous scan. This meant that their procedure was no longer necessary, and a new planning CT therefore prevented one unnecessary procedure in every 15 cases.<sup>6</sup>

Once the bronchial tree is reconstructed, the operator defines the target lesion on the CT scan, and a pathway to the lesion can be identified by the software or defined manually by the operator. The software then displays a preview run of the bronchoscopy as seen at bronchoscopy using the planned pathway (Fig. 5). This preview gives the operator an idea of which bronchi to steer down during the procedure.



**Figure 5.** Virtual bronchoscopy: the preview allows the operator to visualize the pathway prior to the start of the procedure. This Figure is reproduced in color in the online version of *Medical Mycology*.

## Performing the procedure

The patient lies supine on a board that emits an electromagnetic field. This projects a low frequency (<30 kHz) electromagnetic field in the volume containing the patient's chest. There are also electromagnetic sensor coils attached to the patient's chest to compensate for changes in the position of the lungs during the respiratory cycle. The bronchoscope with the EWC and locatable guide is then introduced in the airway, and their position in the field is recognized by the software.

The patient's airway is then matched to the virtual bronchial tree using a process called registration. This superimposes the virtual tree on the volume of space of the patient's chest, thus allowing the system to identify which part of the bronchial tree the locatable guide is in. The bronchoscope is moved through the bronchial tree sampling each lobe, and the system will match the locus of movement to the CT bronchial tree, thus locking in the bronchial tree map to the patient's airways. Once registration is complete, the probe is placed at each primary and secondary carinas to check they are correctly matched to the carina on each scan (Fig. 6).

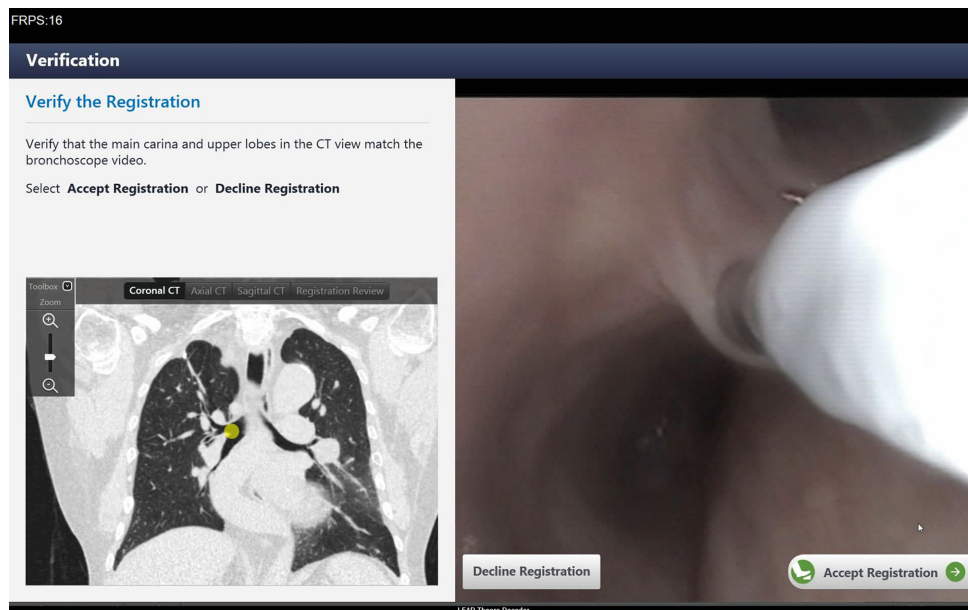
The procedure can be conducted with the patient awake, sedated, or under general anesthesia. A procedure takes, on average, 30–45 minutes and so is much more comfortable for the patient with some form of sedation.

After registration, the operator follows the predefined path to reach the lesion. The bronchoscope is advanced along the planned pathway illustrated by the virtual bronchoscopy (Fig. 3). When the bronchoscope is not able to advance any more, the EWC is advanced out of the end of the bronchoscope to continue navigating toward the lesion by following a virtual CT image of the pathway (Fig. 4). Once at the lesion, the EWC is locked into position, and the locatable guide is removed from the channel. This leaves just the EWC, which leads directly to the lesion, allowing the operator to pass long instruments straight to the target, such as needles, forceps, and brushes.

The accuracy of the procedure can be enhanced by image-guided confirmation of the location of the instruments. Several modalities are available. Fluoroscopy is commonly used in the United States but rarely so in Europe, but many small lesions are not visible on fluoroscopy.

Radial EBUS can be used to confirm if the lesion is at the end of EWC and whether it is in the middle of it or to one side. It was developed in its own right as a diagnostic tool for peripheral nodules, but the lack of navigation system guidance means the need for repeated and often random sampling of different bronchi in the hope of arriving at the target. It also has the disadvantage of only showing what is around the tip but not directly in front of it and has to be removed during sampling so the visualization is not in real time. A study with 118 patients directly compared the use of ENB alone, radial EBUS alone, and with combined ENB and radial EBUS. The diagnostic yield was highest when both modalities were used together (59% vs 69% vs 88%).<sup>7</sup>





**Figure 6.** Registration: correct matching of the CT scan is confirmed by landmarks such as the carinas. This Figure is reproduced in color in the online version of *Medical Mycology*.

Rapid on-site cytopathologic evaluation (ROSE) is an indirect way of confirming location by analysing the aspirate to confirm the presence of abnormal cells thereby confirming correct positioning at the target. It has been shown to increase diagnostic yield.<sup>8,9</sup> However, it is more helpful in the diagnosis of malignancy and less so for infection where the cytological features are less striking.

Cone beam CT allows direct visualization of the location of the instruments and the lesion (Fig. 7).<sup>10</sup> Not only does it improve diagnostic yield, the ability to provide a global view of the chest, the probe location, and its relationship to the lesion with instruments in position, it is an essential requirement for performing ablation safely and effectively.

If there are multiple nodules to sample, the operator can incorporate the various lesions into the plan and repeat the procedure to the next lesion with the next pathway.

### How well does ENB work?

To date there have been three meta-analysis published on the role of ENB in diagnosis lung nodules. Memoli et al. looked at 39 studies with a total of 3004 patients with pulmonary lung nodules. The pooled diagnostic yield of ENB was found to be 70%.<sup>11</sup> Gex et al. included 15 trials with a total of 971 patients with peripheral lung nodules. Overall diagnostic accuracy was found to be 73.9%.<sup>5</sup> Finally, Zhang et al. looked at a total of 17 studies consisting of 1106 patients with peripheral lung nodules. They found a sensitivity of 82% and specificity of 100%, the diagnostic yield ranged from 60 to 94%.<sup>12</sup> The three meta-analyses reported 1.5%, 3.1%, and 0% pneumothorax rates for ENB, respectively. The majority of studies listed in these three

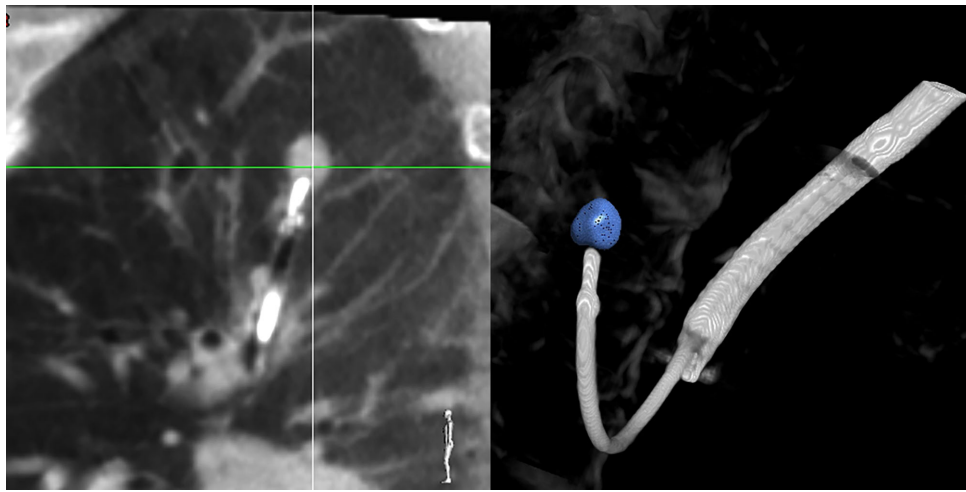
meta-analysis are small, single centered, and were done by expert operators. Similarly in studies where ENB was compared to TTNA or flexible bronchoscopy, there could be selection bias as ENB could have been used in the more difficult patients not suitable for either techniques, leading to an apparently lower diagnostic yield in some other studies.<sup>13</sup>

The NAVIGATE trial is a large, pragmatic, multicenter, prospective cohort study. The 1-year results of the 1215 patients in the US cohort showed a 12-month diagnostic yield of 73%, although the true diagnostic yield would be higher but will not be available for another year to establish whether the negative biopsies are true negatives. While 91% cases used fluoroscopy, the lesion was visible only 60% of the time. Only 4.9% cases used cone beam CT confirmation. The grade  $\geq 2$  pneumothorax rate was 2.9%.<sup>14</sup>

Several factors affect the diagnostic yield of ENB. The larger the lesion, the higher the diagnostic yield.<sup>11,15</sup> Diagnostic yield was also higher in upper lobe lesions; when compared to lower lobe lesions, this is due to a greater excursion of lower lobe lesions during the respiratory cycle as a result of diaphragmatic movement, resulting in lower accuracy.<sup>16</sup> When a bronchus leads straight into a lesion (positive bronchus sign), the diagnostic yield is also higher than if the bronchus is adjacent or at a distance away from the nearest bronchus.<sup>17</sup>

From the results of ENB and its use in diagnosing peripheral lung lesions, ENB has a higher diagnostic yield than conventional flexible bronchoscopy, but lower than that of TTNA. The rate of adverse events such as pneumothorax, hemothorax, and pain, however, is much lower when compared to TTNA.

The American College of Chest Physicians Evidence-based Clinical Practice guidelines for the Diagnosis and Management



**Figure 7.** Cone beam CT: the cone beam CT confirms probe location at the lesion. Three-dimensional (3D) rendering allows visualization of the 3D relationship of the probe to the lesion and surrounding structures. This Figure is reproduced in color in the online version of *Medical Mycology*.

of Lung Cancer (2013) recommends that patients with peripheral lung lesions, which are difficult to reach with conventional bronchoscopy, ENB is recommended, provided that equipment and expertise are available.<sup>18,19</sup>

### ENB in infection

Apart from cancer, ENB is useful in the diagnosis of infection, which is often a significant differential diagnosis for pulmonary nodules. In our practice we routinely send samples for microbiological investigations including mycobacterial and fungal studies. Fungal infections can be diagnosed from these samples.<sup>20</sup> In this case report, severe emphysema also precluded a percutaneous, transpleural approach. Coexisting pulmonary disease and poor lung function is common in patients with fungal lung disease, and ENB has the benefit of avoiding transpleural puncture and the risks of pneumothorax, hemothorax, and pain. Furthermore, percutaneous sampling carries the risk of contamination of the pleural space and empyema, which is a morbid complication that can be very difficult to treat.

Malignancy and mycobacterial infections can coexist. In our institution we have identified a number of patients with coexisting infection and malignancy, where there are multiple infectious nodules but where one of the lesions turns out to be cancer. ENB allows biopsies and sampling from multiple different areas and multiple lesions safely to help maximize the likelihood of identifying the multiple aetiologies of the lesions.

Another role for ENB is the diagnosis and characterisation of cavitating lesions. Cavitating lesion often raises the possibility of infection or a cavitating malignancy such as squamous cell carcinoma. Transpleural puncture of cavitating lesions carries a high risk of pneumothorax as well as empyema if the aetiology is infection. Again, an infection can coexist in a cavitating malignancy, and so a reliable biopsy is required. Navigation

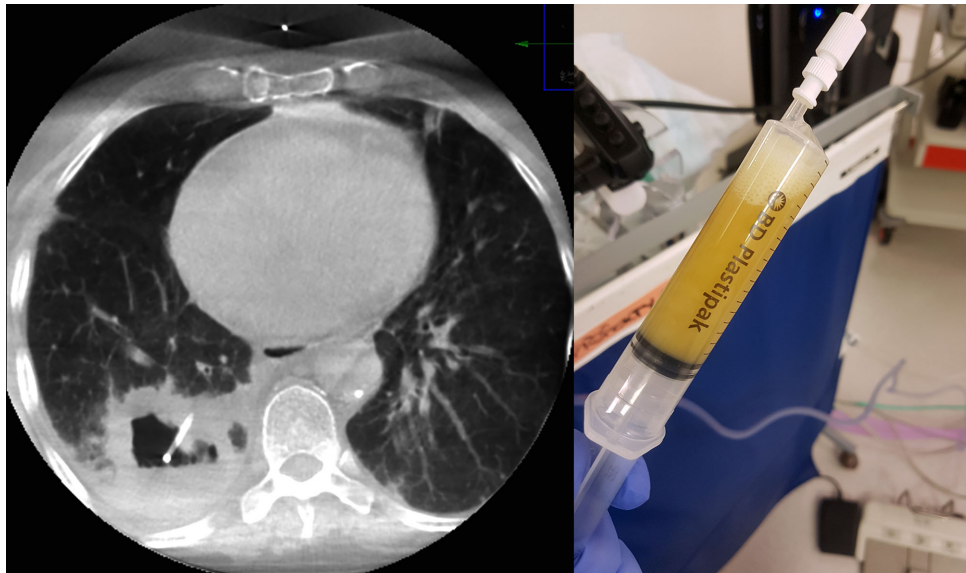
bronchoscopy allows the cavity to be entered bronchoscopically without pleural puncture (Fig. 8a). The contents of the cavity can be sent for culture (Fig. 8b), and the walls of the cavity biopsied for culture and for histology.

Aside from diagnosis, the possibility of therapy is real. Percutaneous intracavitary amphotericin has been used for the short-term control of aspergilloma-associated severe hemoptysis but is complicated by a 26% pneumothorax rate. This procedure thus lends itself to a bronchoscopic approach with the additional benefit of airway control, while examination and bronchial toilet could be carried out in the same procedure. Furthermore, as antifungal penetration into a cavity is poor, the possibility of intracavitary topical antifungal treatment is an exciting prospect on the horizon.

### Future

The role of navigation bronchoscopy has evolved from diagnosis to treatment enablement with fiducials to guide stereotactic radiotherapy and markers to guide surgery, through to recent reports of therapy with tumor ablation. Its role in infection is less well established, but it is increasingly used for targeted sampling to diagnose complex infections. In a similar vein to malignancy, locally targeted treatment delivery, especially where tissue penetration from systemic therapy is poor, and systemic toxicity is high, could become a possibility with ENB.

Electromagnetic navigation bronchoscopy allows peripheral lung lesions to be reached through the bronchial tree, thereby avoiding transpleural puncture and contamination. Its role has extended from diagnosis to treatment enablement to therapy in its own right. ENB is useful for the diagnosis of infection and where infection coexists with malignancy and helps guide treatment.



**Figure 8.** Cavitating lesions: cavitating lesions can be entered with navigation bronchoscopy. (a) The cone beam CT image confirms the EWC is within the cavity; (b) here the contents of the cavity is aspirated to dryness. This Figure is reproduced in color in the online version of *Medical Mycology*.

### Declaration of interest

The authors report no conflicts of interest. The authors alone are responsible for the content and the writing of the paper.

### References

- DiBardino DM, Yarmus LB, Semaan RW. Transthoracic needle biopsy of the lung. *J Thorac Dis.* 2015; 7: S304–S316.
- Larscheid RC, Thorpe PE, Scott WJ. Percutaneous transthoracic needle aspiration biopsy: a comprehensive review of its current role in the diagnosis and treatment of lung tumors. *Chest.* 1998; 114: 704–709.
- Jin F, Mu D, Chu D, Fu E, Xie Y, Liu T. Severe complications of bronchoscopy. *Respir Int Rev Thorac Dis.* 2008; 76: 429–433.
- Reynisson PJ, Leira HO, Hernes TN et al. Navigated bronchoscopy: a technical review. *J Bronchol Interv Pulmonol.* 2014; 21: 242–264.
- Gex G, Pralong JA, Combescure C, Seijo L, Rochat T, Soccal PM. Diagnostic yield and safety of electromagnetic navigation bronchoscopy for lung nodules: a systematic review and meta-analysis. *Respiration.* 2014; 87: 165–176.
- Semaan RW, Lee HJ, Feller-Kopman D et al. Same-day computed tomographic chest imaging for pulmonary nodule targeting with electromagnetic navigation bronchoscopy may decrease unnecessary procedures. *Ann Am Thorac Soc.* 2016; 13: 2223–2228.
- Eberhardt R, Anantham D, Ernst A, Feller-Kopman D, Herth F. Multimodality bronchoscopic diagnosis of peripheral lung lesions: a randomized controlled trial. *Am J Respir Crit Care Med.* 2007; 176: 36–41.
- Lamprecht B, Porsch P, Pirich C, Studnicka M. Electromagnetic navigation bronchoscopy in combination with PET-CT and rapid on-site cytopathologic examination for diagnosis of peripheral lung lesions. *Lung.* 2009; 187: 55–59.
- Balbo PE, Bodini BD, Patrucco F et al. Electromagnetic navigation bronchoscopy and rapid on site evaluation added to fluoroscopy-guided assisted bronchoscopy and rapid on site evaluation: improved yield in pulmonary nodules. *Minerva Chir.* 2013; 68: 579–585.
- Pritchett MA, Schampaert S, de Groot JAH, Schirmer CC, van der Bom I. Cone-beam CT with augmented fluoroscopy combined with electromagnetic navigation bronchoscopy for biopsy of pulmonary nodules. *J Bronchol Interv Pulmonol.* 2018; 25: 274–282.
- Wang Memoli JS, Nietert PJ, Silvestri GA. Meta-analysis of guided bronchoscopy for the evaluation of the pulmonary nodule. *Chest.* 2012; 142: 385–393.
- Zhang W, Chen S, Dong X, Lei P. Meta-analysis of the diagnostic yield and safety of electromagnetic navigation bronchoscopy for lung nodules. *J Thorac Dis.* 2015; 7: 799–809.
- Ost DE, Ernst A, Lei X et al. AQuIRE bronchoscopy registry, diagnostic yield and complications of bronchoscopy for peripheral lung lesions: results of the AQuIRE registry. *Am J Respir Crit Care Med.* 2016; 193: 68–77.
- Folch EE, Pritchett MA, Nead MA et al. Electromagnetic navigation bronchoscopy for peripheral pulmonary lesions: one-year results of the prospective, multicenter NAVIGATE study. *J Thorac Oncol.* 2019; 14: 445–458.
- Jensen KW, Hsia DW, Seijo LM et al. Multicenter experience with electromagnetic navigation bronchoscopy for the diagnosis of pulmonary nodules. *J Bronchol Interv Pulmonol.* 2012; 19: 195–199.
- Chen A, Pastis N, Furukawa B, Silvestri GA. The effect of respiratory motion on pulmonary nodule location during electromagnetic navigation bronchoscopy. *Chest.* 2015; 147: 1275–1281.
- Seijo LM, de Torres JP, Lozano MD et al. Diagnostic yield of electromagnetic navigation bronchoscopy is highly dependent on the presence of a Bronchus sign on CT imaging: results from a prospective study. *Chest.* 2010; 138: 1316–1321.
- Rivera MP, Mehta AC, Wahidi MM. Establishing the diagnosis of lung cancer. *Chest.* 2013; 143: e142S–e165S.
- Gould MK, Donington J, Lynch WR et al. Evaluation of individuals with pulmonary nodules: when is it lung cancer?: Diagnosis and management of lung cancer, 3rd edn: American College of Chest Physicians Evidence-Based Clinical Practice Guidelines. *Chest.* 2013; 143: e93S–e120S.
- Chan S, Pumar MI, Leong SC et al. Electromagnetic navigation bronchoscopy for the diagnosis of *Aspergillus* infection. *Respirol Case Rep.* 2014; 2: 30–32.