

Fenestrated stent graft in treatment of type IV thoracoabdominal aneurysm involving all visceral arteries



Wacław Majewski¹, Robert Juszkat², Michał Stanisić¹, Jerzy Kulesza², Natalia Majewska², Bartłomiej Perek³, Grzegorz Oszkinis¹

¹Department of General and Vascular Surgery, Poznan University of Medical Sciences, Poznan, Poland

²Department of Clinical Radiology, Poznan University of Medical Sciences, Poznan, Poland

³Department of Cardiac Surgery and Transplantation, Poznan University of Medical Sciences, Poznan, Poland

Kardiochirurgia i Torakochirurgia Polska 2015; 12 (2): 162-165

Abstract

Conventional open surgical repair of thoracoabdominal aortic aneurysm (TAAA) is associated with high perioperative mortality and morbidity risk. Our report of successful treatment of a 56-year-old patient with TAAA involving all visceral arteries and with many comorbidities with a fenestrated stent graft supports its application in high-risk TAAA patients.

Key words: thoracoabdominal aortic aneurysm, visceral arteries, fenestrated stent graft, outcome.

Introduction

Recent advances in repair of thoracoabdominal aortic aneurysms (TAAA) allow one to choose between three therapeutic options: conventional open surgery, a hybrid open-endovascular procedure or endovascular repair. Despite significant progress in operative technique and procedural anesthesia, a conventional open surgical repair of TAAA is still accompanied by significant morbidity and mortality [1]. A number of large studies dealing with outcomes following open TAAA surgical treatment indicate that the 30-day mortality of elective cases ranges between 5% and 19%, while one-year mortality increases to even 30% [1, 2]. However, only experienced high-volume vascular centers can treat TAAA surgically with a mortality rate below 10% [2].

In high-risk patients, hybrid procedures combining extra-anatomic bypasses and endovascular techniques with branched and fenestrated aortic stent grafts have been used to reduce the risk of conventional TAAA with the repair of visceral arteries [3]. In patients with Crawford type IV TAAA, employment of fenestrated aortic stent grafts has

Streszczenie

Tradycyjne otwarte leczenie chirurgiczne tętniaka aorty piersiowo-brzuszej (*thoracoabdominal aortic aneurysm* – TAAA) powiązane jest z wysokim okołoperacyjnym ryzykiem śmiertelności i powikłań. W pracy przedstawiono przypadek 56-letniego pacjenta z tego typu tętniakiem obejmującym wszystkie tętnice trzewne oraz z wieloma chorobami współistniejącymi; dobre wyniki leczenia, które przeprowadzono przy użyciu fenestrowanego stentgraftu, wspierają tezę o możliwości zastosowania tego zabiegu u pacjentów wysokiego ryzyka z TAAA.

Słowa kluczowe: tętniak aorty piersiowo-brzuszej, tętnice trzewne, stentgraft fenestrowany, wynik.

been proved to provide better early results than open surgical procedures [4].

Endovascular repairs in patients with TAAA are limited so far to anatomical factors, such as ostial stenosis, severe vessel angulations and tortuosity as well as narrow iliac, renal and visceral arteries. Other limitations to the common use of fenestrated stent grafts include high costs and the time delay between qualification and manufacture of the tailored grafts.

Today, there are only a few studies in the literature reporting application of fenestrated stent grafts in the treatment of complex abdominal aortic aneurysms involving four visceral vessels. We describe a case of a high-risk patient with TAAA involving the visceral vessels in which the endovascular technique was chosen as the most appropriate therapeutic option.

Case study

A 56-year-old man was diagnosed with asymptomatic type IV TAAA with a maximal diameter of 55 mm (Fig. 1B).

Address for correspondence: Bartłomiej Perek, MD, Department of Cardiac Surgery and Transplantation, Poznan University of Medical Sciences, 1/2 Długa St., 61-848 Poznan, Poland, phone: +48 61 854 92 10, e-mail: bperek@yahoo.com

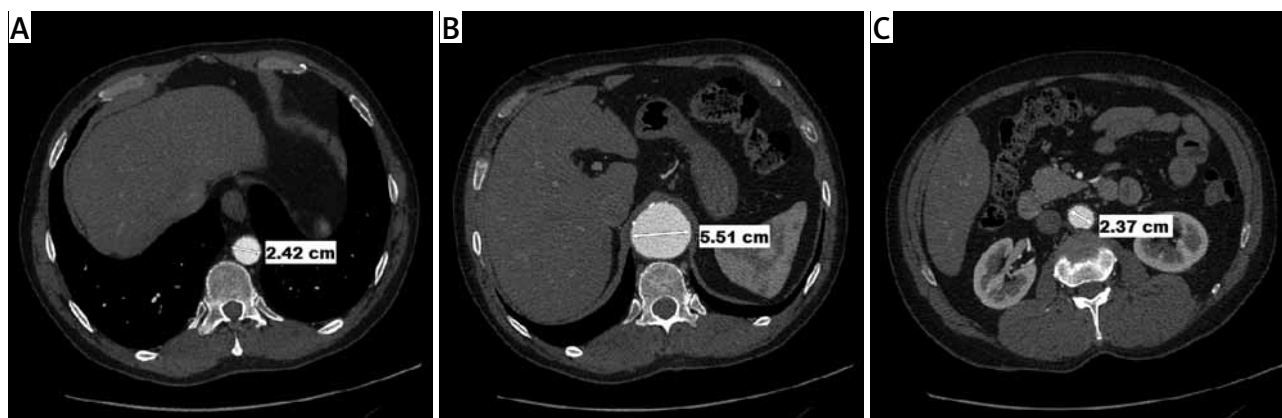


Fig. 1. Preoperative imaging of the descending aorta in CT angiography. (A) CT scan with thoracic aorta (24 mm in diameter) above an aneurysm. (B) CT scan at the level of the aneurysm with maximal diameter of 55 mm. (C) CT scan with abdominal aorta below the aneurysm

A number of risk factors that could increase predicted mortality and morbidity rate such as hypertension, type II diabetes mellitus treated with insulin, symptomatic coronary artery disease (Canadian Cardiovascular Society, CCS class II) and severe chronic obstructive pulmonary disease (FEV_1 below 1L) were diagnosed. The pre-operative computed tomography angiography (CTA) that confined the whole descending aorta from the arch to bifurcation and further to the common femoral arteries demonstrated a type IV TAAA and patent normal celiac trunk as well as the superior mesenteric artery originating from the aneurysm.

The stent graft was customized after meticulous calculations such as length and diameter at the proximal and distal implantation sites within normal aortic segments (Fig. 1), diameters of both iliac and femoral arteries, all angulations, the ostial diameter of the renal arteries, the superior mesenteric artery and the celiac trunk as well as distances between these vessels were done. The manufacture of the fenestrated stent graft (Cook Inc., Bloomington, IN, USA) and its delivery lasted over two months. The stent graft diameter at both ends was 28 mm, length was 178 mm, and it had four holes (two 8 mm and the other two 6 mm in diameter).

The procedure was performed under spinal anesthesia. The main surgical access was both femoral arteries. They were exposed surgically through longitudinal skin incisions approximately 5 cm in length in both groins. After the arteries were dissected free intravenous heparin was given to achieve an activated clotting time (ACT) > 300 seconds. Then a purse-string stitch with 5-0 monofilament polypropylene non-absorbable suture was placed on the right femoral artery and an endovascular graft was delivered using the Seldinger technique (the sheath size was 20 Fr). After an appropriate position was achieved in the region of the aortic aneurysm, a stent graft was deployed. Then the superior mesenteric and both renal arteries were successfully cannulated from the left common femoral artery. The same surgical technique of femoral artery exposure as described above was employed. The covered Advanta V12 stents (Atrium Medical Corporation, NH, USA) were placed

to secure the interface between the stent graft fenestrations and superior mesenteric and both renal arteries' orifices. The sizes of the renal and superior mesenteric stents were 6 mm × 22 mm and 8 mm × 38 mm, respectively. Afterwards, the celiac trunk was cannulated from the left brachial artery open surgical approach (as described above) and was stented with a covered 8 mm × 60 mm Fluency stent (Bard Peripheral Vascular, Tempe, AR, USA) (Fig. 2).

Complete exclusion of the aneurysm with no endoleak and with preservation of flow in the celiac trunk, the superior mesenteric artery and both renal arteries was confirmed. The sites of cannulation of surgically exposed peripheral arteries (both femoral and left brachial) were fixed with previously placed purse-string stitches and the wounds were closed with layers with absorbable sutures. No arterial reconstructions following stent graft or stents were necessary. The total stent graft implantation time was 250 minutes and the fluoroscopy time was 54 minutes. The patient was discharged from hospital on the 5th postprocedural day. All wounds of surgically exposed arteries healed correctly. Follow-up CTA at 6 months after endovascular repair showed successful sealing with complete exclusion of the aneurysm and proper perfusion in the four target vessels (Fig. 3).

Discussion

Pararenal and TAAA repair by fenestrated or branched stent grafts as a minimally invasive technique seems to offer good short- and medium-term results in comparison to conventional open surgery [5]. A conventional operation for TAAA requires extensive exposure that requires opening not only the abdominal but also not uncommonly the pleural cavity. This surgical excess itself is associated with at least moderate risk for the development of serious postoperative complications. Treatment with stent grafts is really minimally invasive. An access through small incisions in both groins is usually enough. A percutaneous approach is still not recommended since the sheath size is 20 Fr. Moreover, rehabilitation after open surgery is long, and mobilization of the patient is only possible a few days after the operation. Our patient was mobilized and rehabilitation

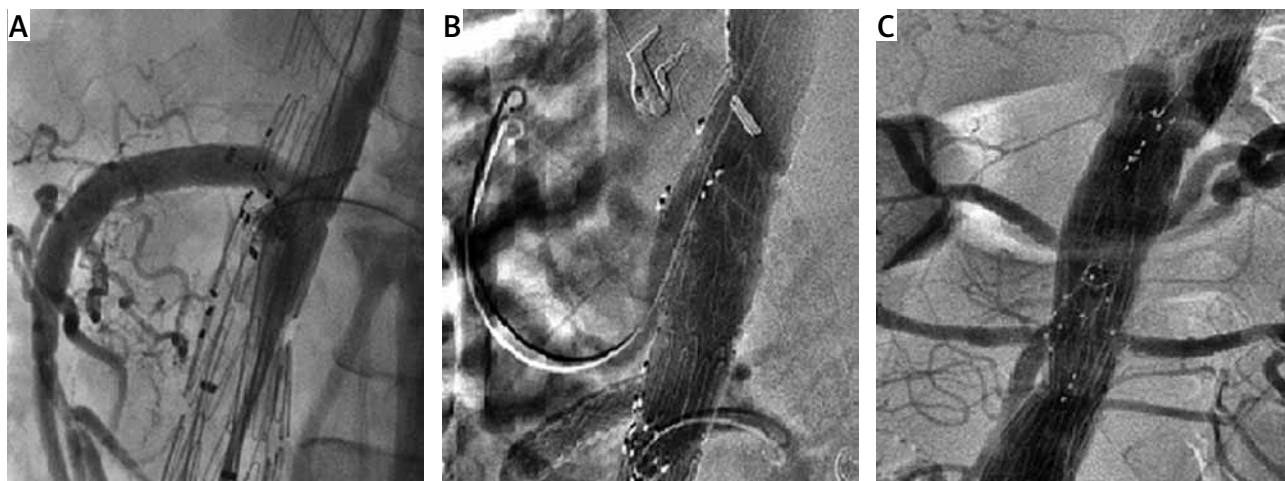


Fig. 2. Consecutive steps of endovascular procedure under guidance of digital subtraction angiography (DSA)

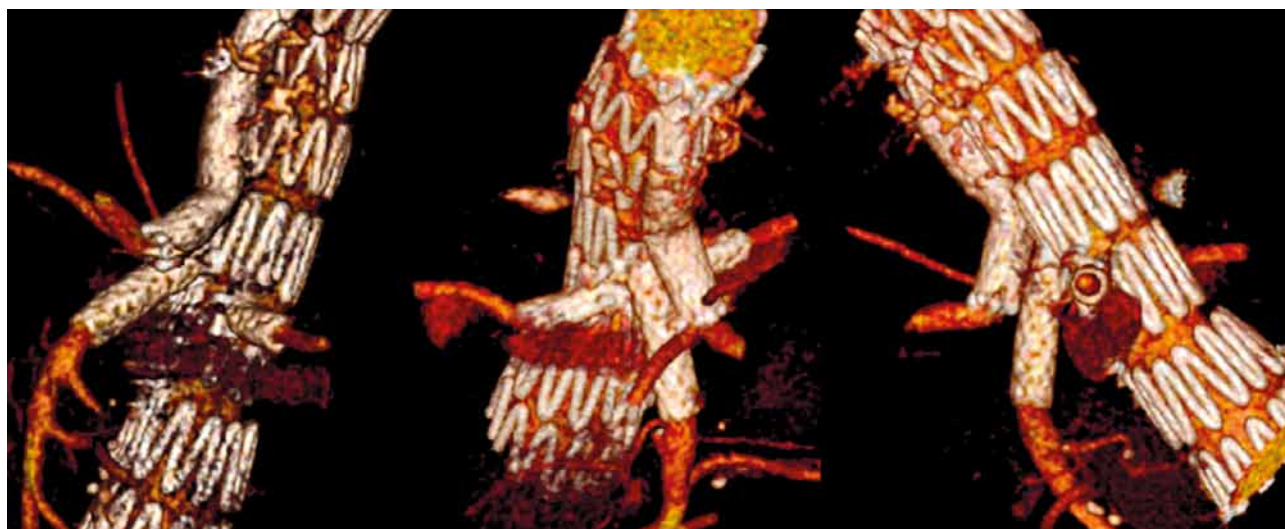


Fig. 3. Six-month follow-up three-dimensional CT reconstruction. Properly deployed stent graft in the abdominal aorta and stents in the proximal segments of the visceral vessels (celiac trunk, upper mesenteric and both renal arteries)

was initiated on the second day after surgery. Additionally, in our case, no general anesthesia was employed. We are convinced it enabled us to avoid many possible complications related to mechanical ventilation of an individual with advanced chronic obstructive pulmonary disease. Thus, the indications for endovascular repair of type IV TAAA are high-risk patients (e.g. elderly subjects, individuals with several comorbidities) with favorable anatomy that makes it possible to manufacture the customized fenestrated stent grafts [6]. Adequate visualization of all visceral branches and proper sizing of the fenestrated stent grafts are of crucial importance to ensure success in the endovascular treatment of TAAA. These devices were manufactured on the basis of CTA data with bespoke fenestrations at the level of the orifices of four target vessels. Considerable experience in endovascular grafting is necessary, especially during deployment of the fenestrated graft in an accurate position and fixation of the graft fenestrations with renal and visceral orifices by implantation covered stents.

Stenting of the fenestrated graft to the renal and visceral orifices as well as the branched graft have a favorable impact on preservation of blood flow through the graft-ostial junctions and target arteries. Additionally, these covered stents placed in the graft-ostial tracts may also prevent graft migration and endoleaks as well as renal and visceral artery occlusions.

The significant injury during open surgery especially in high-risk patients leads to the development of serious perioperative complications [7]. Meanwhile, during endovascular repair there are real chances to avoid or at least significantly decrease the rate of organ complications. Despite the good outcome of endovascular repair of TAAA, the 30-day mortality risk is still between 1% and 5% [8]. Post-operative complications occurred in 11% to 14% of patients and included heart failure or myocardial infarction (5.5% to 6.5%), stroke (1.4% to 2.5%), respiratory insufficiency (3.8% to 6.8%), neurological events such as paraplegia or paraparesis (1.1% to 2.7%) and renal dysfunction (1.4%) [8]. In the

perioperative period prevalence of endoleaks was found in 3% to 11% of cases [5]. The early occurrence of renal dysfunction may be provoked by the use of a large volume of contrast agents predisposing to contrast-induced nephropathy or embolization of the renal arteries during deployment of the stent graft [9]. Moreover, the use of fenestrated and branched stent grafts was proved to be beneficial, particularly in patients with preexisting severe cardiovascular, pulmonary, neurological or renal dysfunction. For these reasons, even complex endovascular therapy with fenestrated stent grafts may offer shorter hospitalization and faster post-procedural rehabilitation. Our uncomplicated case demonstrated at 6 months after the procedure complete aneurysm exclusion with 18 mm reductions in aneurysm sac diameter and preserved perfusion in the stent graft and four visceral arteries.

Thus, complex and diffuse aortic pathologies such as thoracoabdominal aneurysms may be treated successfully with fenestrated stent grafts. However, appropriate patient selection, proper graft design and a multidisciplinary team experienced in endovascular procedures are of paramount importance in successful treatment of this particular group of patients.

Disclosure

Authors report no conflict of interest.

References

1. Rigberg DA, McGory ML, Zingmond DS, Maggard MA, Agustin M, Lawrence PF, Ko CY. Thirty-day mortality statistics underestimate the risk of repair of thoracoabdominal aortic aneurysms: A statewide expedience. *J Vasc Surg* 2006; 43: 217-222.
2. Coselli JS, Bozinovski J, LeMaire SA. Open surgical repair of 2286 thoracoabdominal aortic aneurysms. *Ann Thorac Surg* 2007; 83: S862-864.
3. Donas KP, Czerny M, Guber Z, Teufelsbauer H, Nanobachvili J. Hybrid open-endovascular repair for thoracoabdominal aortic aneurysms current status and level of evidence. *Eur J Vasc Endovasc Surg* 2007; 34: 528-533.
4. Anderson JL, Adam DJ, Berce M, Hartley DE. Repair of thoracoabdominal aortic aneurysms with fenestrated and branched endovascular stentgrafts. *J Vasc Surg* 2005; 42: 600-607.
5. Haulon S, Amiot S, Magnan P-E, Becquemin JP, Lermusiaux P, Koussa M, Batt M, Favre JP. An analysis of the French Multicentre Experience of fenestrated aortic endografts. *Ann Surg* 2010; 251: 357-362.
6. Malkawi AH, Resch TA, Bown MJ, Manning BJ, Poloniecki JD, Nordon IM, Lofthus IM, Thompson MM, Hinchliffe RJ. Sizing fenestrated aortic stent-grafts. *Eur J Vasc Endovasc Surg* 2011; 41: 311-316.
7. Fischbein MP, Miller DC. Long-term durability of open thoracic and thoracoabdominal aneurysm repair. *Semin Vasc Surg* 2009; 22: 74-80.
8. Roselli EE, Greenberg RK, Pfaff K, Francis C, Svensson LG, Lytle BW. Endovascular treatment of thoracoabdominal aortic aneurysms. *J Thorac Cardiovasc Surg* 2007; 133: 1474-1482.
9. Verhoeven EL, Prins TR, Tielliu IF, van den Dungen JJ, Zeebregts CJ, Hulsebos RG, van Andringa de Kempnaer MG, Oudkerk M, van Schilfgaarde R. Treatment of short-necked infrarenal aortic aneurysms with fenestrated stent-graft: short-term results. *Eur J Vasc Endovasc Surg* 2004; 27: 477-483.