

# Simultaneous placement of an interpositional free gingival graft with nonsubmerged implant placement

Joo-Yeon Sohn<sup>1</sup>, Jung-Chul Park<sup>1</sup>, Kyoo-Sung Cho<sup>1</sup>, Chang-Sung Kim<sup>2,\*</sup>

<sup>1</sup>Department of Periodontology, Research Institute for Periodontal Regeneration, Yonsei University College of Dentistry, Seoul, Korea

<sup>2</sup>Department of Periodontology, Research Institute for Periodontal Regeneration, Oral Science Research Center, Yonsei University College of Dentistry, Seoul, Korea

**Purpose:** Various surgical techniques target achieving adequate keratinized tissue around dental implants; however, these techniques are usually performed before implant placement or upon the exposure of submerged implants. The aim of this case report is to describe a simultaneous placement of an interpositional free gingival graft (iFGG) with that of nonsubmerged implants in a patient lacking keratinized tissue and to assess the long-term outcome of this grafted gingiva.

**Methods:** A wedge-shaped free gingival graft (FGG), including an epithelium-connective tissue (E-C) portion and a connective-tissue-only (CT) portion, was harvested from the palate. The CT portion was inserted under the buccal flap, and the E-C portion was secured tightly around the implants and to the lingual flap.

**Results:** At the 8-year follow-up, the gingival graft remained firmly attached and was well maintained, with no conspicuous shrinkage or reported discomfort during oral hygiene procedures. The use of an iFGG at a nonsubmerged implant placement minimizes the required number of surgical steps and patient discomfort while providing adequate buccal keratinized tissue.

**Conclusions:** Therefore, the technique could be considered an alternative method in increasing the keratinized tissue for cases that have a minimal amount of keratinized tissue.

**Keywords:** Free gingival graft, Interpositional onlay graft, Keratinized tissue, Nonsubmerged implant.

## INTRODUCTION

The sealing ability of the peri-implant nonkeratinized tissue [1] and the critical role of bacterial plaque control in some patients are the main arguments for justifying a gingival graft at the implant site [2]. Several clinical and experimental investigations have shown that the absence of the attached keratinized tissue is compatible with the maintenance of periodontal health [3]. Furthermore, some authors have reported no correlation between the implant success rate and the presence of keratinized tissue in the peri-implant soft tissue [4-6]. On the other hand, some reports have suggested that a lack of keratinized tissue contributes to implant failure and that mobile mucosa can disrupt the implant-epithelial attachment zone and contribute to an increased risk of inflammation due to the accumulation of plaque [7-12].

However, there is a lack of consensus in the literature regarding the relationship between

pISSN 2093-2278  
eISSN 2093-2286



**JPIS** >  
Journal of Periodontal  
& Implant Science

## Case Report

J Periodontal Implant Sci 2014;44:94-99  
<http://dx.doi.org/10.5051/jpis.2014.44.2.94>

Received: Feb. 27, 2014

Accepted: Mar. 21, 2014

### \*Correspondence:

Chang-Sung Kim  
Department of Periodontology, Research Institute  
for Periodontal Regeneration, Yonsei University  
College of Dentistry, 50 Yonsei-ro, Seodaemun-gu,  
Seoul 120-752, Korea  
E-mail: dentall@yuhs.ac  
Tel: +82-2-2228-3186  
Fax: +82-2-392-0398

This is an Open Access article distributed under the terms of the Creative Commons Attribution Non-Commercial License (<http://creativecommons.org/licenses/by-nc/3.0/>).

the width of the keratinized tissue and the health of peri-implant tissues [13–15]. Nevertheless, it is generally accepted that a more ideal and healthy soft tissue-implant interface can be established if an adequate zone of keratinized tissue is present [16,17], based on the rationale of enhanced esthetics, easier restorative manipulation, less gingival recession, easier plaque control, and regular maintenance care [18–20].

Various surgical techniques have been used to obtain adequate amounts of keratinized tissue around dental implants, including the gingival autograft, apically positioned flap (APF), coronally positioned palatal sliding flap, and acellular dermal matrix graft (ADM) [21–24]. Performing a free gingival graft (FGG) prior to implant surgery has been suggested when there is minimal keratinized tissue over the edentulous ridge [25,26], and APF and FGG can be combined in shallow vestibules with minimal keratinized tissue [27].

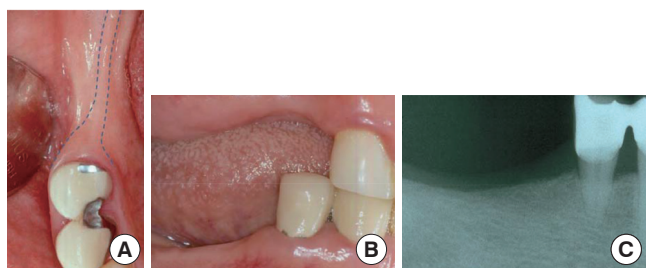
These procedures are usually performed before implant placement or during the exposure of submerged implants, which can extend the healing period and result in patients suffering from pain and discomfort through several surgical stages. In addition, these can be time-consuming procedures in cases that already have good primary implant stability and do not need hard-tissue augmentation.

Here, we describe an interpositional gingival graft technique that is performed at the time of implant placement. The graft consists of two parts—an epithelium-connective tissue (E-C) portion and a connective-tissue-only (CT) portion—and is partially inserted under the buccal flap. The aims of this case report are to describe a simultaneous interpositional FGG (iFGG) procedure with the placement of nonsubmerged implants in a patient lacking keratinized tissue, and to report the findings of our assessment of the long-term outcome of this grafted tissue.

## CASE DESCRIPTION

### Patient information and site analysis

A 50-year-old female patient presented to the Department of Periodontology at Yonsei University Dental Hospital, Seoul, Korea, complaining of partial edentulism in the right mandible. The patient had no contributing medical history. The mandibular right



**Figure 1.** Preoperative clinical photographs and radiograph. (A) Occlusal view of the edentulous ridge of the right mandibular area. The dotted line indicates the buccal and lingual mucogingival junctions. (B) Buccal view. (C) Slight vertical bone resorption was observed in the posterior area.

second premolar and molars had been extracted 10 years previously, and she had been wearing a removable partial denture.

The posterior molar site of the edentulous mandible presented a thin band (approximately 2 mm) of keratinized tissue on the ridge crest and inadequate vestibular depth (Fig. 1). The treatment plan included the placement of three nonsubmerged implants in the positions of the mandibular right second premolar, first molar, and second molar. In addition, simultaneous interpositional free gingival grafting was planned in the molar area to increase the amount of keratinized tissue.

The protocol was reviewed and approved by the Yonsei University Institutional Review Board. The patient provided written informed consent before the onset of the surgery.

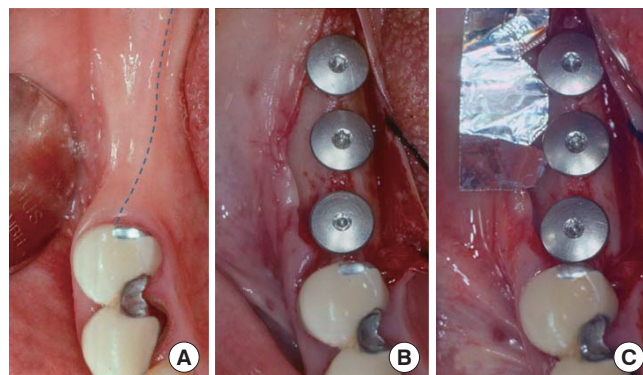
### Surgical procedure

#### Recipient site preparation and implant placement

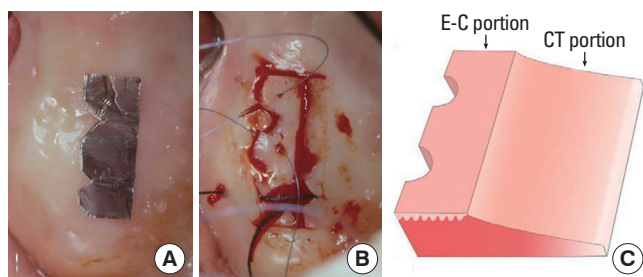
A horizontal incision was made on the ridge crest starting from the distal gingiva of the first premolar and extending to the posterior area (Fig. 2). The horizontal incision line of the molar area was on the mucogingival junction. Thus, the lingual flap had 2 mm of keratinized tissue. Full-thickness buccal and lingual flaps were elevated, and the keratinized tissue band of the molar area was then repositioned to the lingual flap. Nonsubmerged implants (Standard implant, Straumann, Basel, Switzerland; second premolar and first molar: diameter 4.1 mm, length 12 mm; second molar: diameter 4.1 mm, length 10 mm) were placed, and healing caps (diameter 6.5 mm, height 1.5 mm) were connected following a standardized technique.

#### Donor site preparation

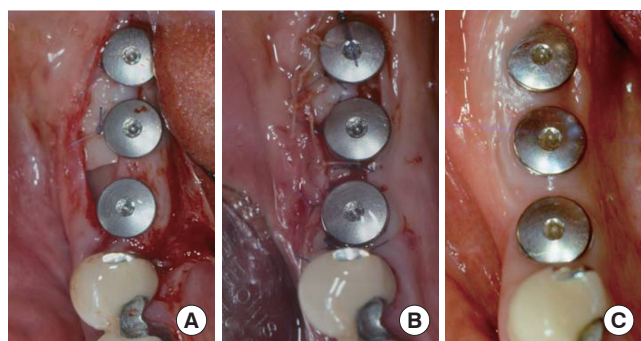
The right palate was chosen as the donor site. The thickness of the palatal tissue, as measured by penetrating to the bone with a periodontal probe, was approximately 3.0 mm. A tinfoil template was used to guide the palatal incision (approximately 7 mm high and 20-mm wide). The graft contouring was performed with a



**Figure 2.** The recipient site preparation. (A) The dotted line represents the horizontal incision line. (B) Healing caps were connected after installing the implants. (C) The template for guiding the palatal incision was constructed from tinfoil.



**Figure 3.** The palatal donor site preparation. (A) The incision for the graft was carried out using a tinfoil template. (B) A presuture was created for immediate adaptation and fixation, and then, the interpositional free gingival graft, containing connective tissue, was harvested from the palate. (C) A three-dimensional schematic view of the graft. The partial-thickness graft consists of an epithelium-connective tissue (E-C) portion and a connective-tissue-only (CT) portion.



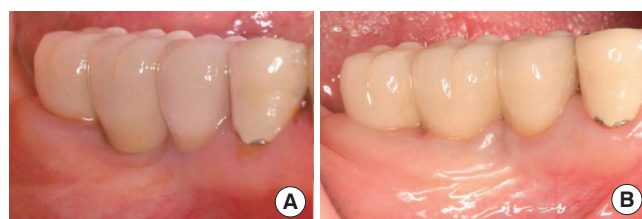
**Figure 4.** Placement of the interpositional free gingival graft (FGG). (A) The interpositional FGG was positioned over the recipient bed, and the connective-tissue-only portion was inserted under the buccal flap. The presuture silk was tied around the healing abutments using the sling suturing technique. (B) The buccal and lingual flaps were sutured with grafted gingiva, and primary closure was obtained. (C) Occlusal view after 1 month of healing.

fresh No. 15C scalpel to ensure close adaptation around the implant abutment and a butt-joint marginal adaptation with the lingual tissues. A presuture for the sling suture was made to adapt and fix the graft immediately, and a partial-thickness graft was harvested (Fig. 3A and B).

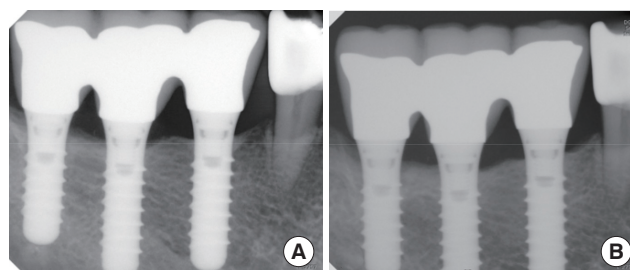
The flap design of the palatal graft followed the technique for the interpositional onlay graft described by Seibert and Louis [28]. The E-C and CT portions of the graft were determined; the graft was rectangular in shape in the frontal view and wedge shaped in the cross-sectional view (Fig. 3C).

#### Fixation of the graft and postoperative care

The graft was positioned over the recipient bed, and the CT portion was inserted under the buccal flap and sutured to the buccal mucosa flap to promptly obtain a blood supply from the buccal flap and the underlying bone tissue. The presutured silk on the E-C portion was tied around the healing caps using sling sutures. The graft was then closely connected to the lingual flap by using an interrupted suture to obtain primary closure in the interproximal



**Figure 5.** Healing states of the grafted gingiva after 1 year and 8 years. (A) Buccal view after 1 year of healing. (B) Buccal view after 8 years of healing.



**Figure 6.** Periapical radiographs of the implants after 1 year and 8 years. (A) Postoperative, 1 year. (B) Postoperative, 8 years. Saucerization occurred around fixtures, but there was no additional alveolar bone resorption in the interproximal area up to the 8-year follow-up.

area. Consequently, the buccal flap was positioned apically and fixed at the inferior border level of the E-C portion (Fig. 4).

Light compression was applied to the graft with moistened gauze for about 5 minutes to reduce the thickness of the blood clot and enhance fibrin adhesion. All surgical procedures were performed by one of the authors (K.S.C.).

Postoperatively, the patient was instructed to rinse her mouth twice a day with 0.1% chlorhexidine solution (Hexamedine, Bukwang Pharmaceuticals, Seoul, Korea) for the first 2 weeks after the surgery. Antibiotic regimens were prescribed for 7 days, and the sutures were removed after 10 days. The patient was rehabilitated with a fixed partial denture after 4 months.

#### Healing and analysis

The healing was uneventful during the initial healing period, and the graft appeared well integrated with the surrounding tissues. The patient was seen at 2, 4, 6, 8, 16, and 20 weeks postoperatively, and yearly thereafter for 8 years to monitor healing and for plaque control. Clinical and radiographic examinations were carried out once or twice a year (Figs. 5 and 6). Plaque control and oral hygiene reinforcement were performed at each visit.

A clinical examination performed 8 years after surgery found no significant signs or symptoms of inflammation, such as bleeding on probing, gingival redness, or swelling on the keratinized tissue around the implants, and increased keratinized tissue by the creeping attachment was observed. The grafted gingiva had been well maintained throughout the healing period. Table 1 lists the changes in the width of the keratinized tissue after specific periods of heal-

**Table 1.** The width (mm) of keratinized gingiva on the buccal side of implant-healing abutments was measured with a periodontal probe (CP15UNC, Hu Friedy, Chicago, IL, USA).

	After surgery	Postoperative follow-up			
		1 month	4 months	1 year	8 years
Width of keratinized gingiva on buccal side of #46	3.8	3.5	3.5	3.5	4.5
Width of keratinized gingiva on buccal side of #47	3.5	3.3	3.5	3.5	3.5

ing. The width of keratinized buccal gingiva had increased to 4 mm, and the buccal vestibule was deeper than in the preoperative condition.

## DISCUSSION

In the presented case, iFGG was performed simultaneously at the time of implant placement to increase the amount of keratinized tissue around the implants. The presented graft technique was modeled on the "interpositional onlay graft" technique developed by Seibert and Louis [28], and retained the advantages of their technique. The interpositional onlay graft was originally developed for treating large class-III ridge defects. Interpositional grafts can receive their new blood supply from the connective tissue bed and provide buccolingual ridge augmentation. Onlay grafts were designed primarily to achieve apicocoronal ridge augmentation. The interpositional onlay graft was meant to combine the advantages of the interpositional graft and the onlay graft into a single procedure.

In the present case, the graft was positioned over the recipient bed and the CT portion was inserted under the buccal flap. The expected healing was more rapid and favorable at the recipient site. This feature might have also helped to prevent the postoperative shrinkage of the grafted gingiva; there was no conspicuous shrinkage of the grafted gingiva in this case. It is presumed that the buccal flap and the recipient bed provided a copious blood supply and that the graft itself was sufficiently wide.

Vertical shrinkage of FGGs is a well-known clinical phenomenon that occurs mainly during healing in the first postoperative year, with an average of 42.3% shrinkage reported in thin grafts [29]. Orsini et al. [30] investigated the dimensional changes of FGGs for 1 year after surgery. Average vertical shrinkages of 10.2%, 28.4%, 37.2%, and 43.5% were identified after 1, 4, 26, and 52 weeks, respectively. The width of the keratinized buccal gingiva in the present case had increased to 4.5 mm at the site of the first molar. In addition, the buccal vestibule had deepened and the mucogingival junction had shifted apically. The results were favorable and stable compared with those of other studies using FGGs, APFs, or ADMs. Barone et al. [31] found that the width of the masticatory mucosa at 12 months after FGG prior to implant surgery was  $3.7 \pm 1.0$  mm (mean  $\pm$  standard deviation), and was  $3.2 \pm 0.9$  mm after APF with

second-stage surgery. Park [32] demonstrated that the use of an ADM increased the width of the peri-implant keratinized mucosa from  $0.8 \pm 0.6$  mm to  $3.2 \pm 0.9$  mm at 3 months and  $2.2 \pm 0.6$  mm at 6 months.

Interestingly, the gingival margin of the first molar implant in this case had coronally shifted 8 years postoperatively compared with 1 year postoperatively. This shift was associated with a slight increase in the thickness of the keratinized tissue compared to the baseline. The probing depth increased to 4 mm, but there was no sign of inflammation (such as bleeding) on probing. There is no report in the literature of a postoperative "coronal" migration of the gingival tissue around implants. A controlled trial of this surgical protocol is needed to elucidate the precise changes in the soft tissue that occur around implants during the healing period.

The long-term clinical and radiographic observations presented here suggest that this surgical protocol provides several clinical benefits over other techniques for increasing the amount of keratinized tissue, such as deepening of the buccal vestibule, rapid revascularization of the grafted gingiva, shortening of the healing time, and prevention of graft shrinkage. The use of simultaneous iFGG with the placement of an implant could minimize the number of surgical stages required and thus, the level of patient discomfort, while predictably providing an adequate zone of buccal keratinized tissue. Therefore, the technique may be considered an alternative method for increasing the amount of keratinized tissue for cases that have a minimal amount of keratinized tissue around implants.

## CONFLICT OF INTEREST

No potential conflict of interest relevant to this article was reported.

## ACKNOWLEDGEMENTS

This study was supported by a faculty research grant of Yonsei University College of Dentistry for 2011 (6-2011-0052). The authors thank Jae-Min Lee for the schematic description of the graft.

## ORCID

Joo-Yeon Sohn <http://orcid.org/0000-0002-4229-5869>  
Jung-Chul Park <http://orcid.org/0000-0002-2041-8047>  
Kyoo-Sung Cho <http://orcid.org/0000-0002-6777-5287>  
Chang-Sung Kim <http://orcid.org/0000-0003-3902-1071>

## REFERENCES

- Ericsson I, Lindhe J. Probing depth at implants and teeth. An experimental study in the dog. *J Clin Periodontol* 1993;20:623-7.
- Salonen MA, Oikarinen K, Virtanen K, Pernu H. Failures in the osseointegration of endosseous implants. *Int J Oral Maxillofac Implants* 1993;8:92-7.



3. Wennstrom JL, Bengazi F, Lekholm U. The influence of the masticatory mucosa on the peri-implant soft tissue condition. *Clin Oral Implants Res* 1994;5:1-8.
4. Adell R, Eriksson B, Lekholm U, Branemark PI, Jemt T. Long-term follow-up study of osseointegrated implants in the treatment of totally edentulous jaws. *Int J Oral Maxillofac Implants* 1990;5:347-59.
5. Lekholm U, Adell R, Lindhe J, Branemark PI, Eriksson B, Rockler B, et al. T. Marginal tissue reactions at osseointegrated titanium fixtures. (II) A cross-sectional retrospective study. *Int J Oral Maxillofac Surg* 1986;15:53-61.
6. Schou S, Holmstrup P, Hjorting-Hansen E, Lang NP. Plaque-induced marginal tissue reactions of osseointegrated oral implants: a review of the literature. *Clin Oral Implants Res* 1992;3:149-61.
7. Block MS, Kent JN. Factors associated with soft- and hard-tissue compromise of endosseous implants. *J Oral Maxillofac Surg* 1990;48:1153-60.
8. Chung DM, Oh TJ, Shotwell JL, Misch CE, Wang HL. Significance of keratinized mucosa in maintenance of dental implants with different surfaces. *J Periodontol* 2006;77:1410-20.
9. Listgarten MA, Lang NP, Schroeder HE, Schroeder A. Periodontal tissues and their counterparts around endosseous implants [corrected and republished with original paging, article originally printed in *Clin Oral Implants Res* 1991Jan-Mar;2(1):1-19]. *Clin Oral Implants Res* 1991;2:1-19.
10. Zigdon H, Machtei EE. The dimensions of keratinized mucosa around implants affect clinical and immunological parameters. *Clin Oral Implants Res* 2008;19:387-92.
11. Bengazi F, Lang NP, Caroprese M, Urbizo Velez J, Favero V, Botticelli D. Dimensional changes in soft tissues around dental implants following free gingival grafting: an experimental study in dogs. *Clin Oral Implants Res* 2013 Oct 24 [Epub]. <http://dx.doi.org/10.1111/clr.12280>.
12. Lin GH, Chan HL, Wang HL. The significance of keratinized mucosa on implant health: a systematic review. *J Periodontol* 2013;84:1755-67.
13. Cario E. Barrier-protective function of intestinal epithelial Toll-like receptor 2. *Mucosal Immunol* 2008;1 Suppl 1:S62-6.
14. Warrar K, Buser D, Lang NP, Karring T. Plaque-induced peri-implantitis in the presence or absence of keratinized mucosa. An experimental study in monkeys. *Clin Oral Implants Res* 1995;6:131-8.
15. Cairo F, Pagliaro U, Nieri M. Soft tissue management at implant sites. *J Clin Periodontol* 2008;35(8 Suppl):163-7.
16. Lee KH, Kim BO, Jang HS. Clinical evaluation of a collagen matrix to enhance the width of keratinized gingiva around dental implants. *J Periodontal Implant Sci* 2010;40:96-101.
17. Park JC, Yang KB, Choi Y, Kim YT, Jung UW, Kim CS, et al. A simple approach to preserve keratinized mucosa around implants using a pre-fabricated implant-retained stent: a report of two cases. *J Periodontal Implant Sci* 2010;40:194-200.
18. Bouri A Jr, Bissada N, Al-Zahrani MS, Faddoul F, Nouneh I. Width of keratinized gingiva and the health status of the supporting tissues around dental implants. *Int J Oral Maxillofac Implants* 2008;23:323-6.
19. Kim BS, Kim YK, Yun PY, Yi YJ, Lee HJ, Kim SG, et al. Evaluation of peri-implant tissue response according to the presence of keratinized mucosa. *Oral Surg Oral Med Oral Pathol Oral Radiol Endod* 2009;107:e24-8.
20. Schrott AR, Jimenez M, Hwang JW, Fiorellini J, Weber HP. Five-year evaluation of the influence of keratinized mucosa on peri-implant soft-tissue health and stability around implants supporting full-arch mandibular fixed prostheses. *Clin Oral Implants Res* 2009;20:1170-7.
21. Langer B, Langer L. Overlapped flap: a surgical modification for implant fixture installation. *Int J Periodontics Restorative Dent* 1990;10:208-15.
22. Langer B, Sullivan DY. Osseointegration: its impact on the inter-relationship of periodontics and restorative dentistry: Part I. *Int J Periodontics Restorative Dent* 1989;9:84-105.
23. Tinti C, Parma-Benfenati S. Coronally positioned palatal sliding flap. *Int J Periodontics Restorative Dent* 1995;15:298-310.
24. Sanz M, Lorenzo R, Aranda JJ, Martin C, Orsini M. Clinical evaluation of a new collagen matrix (Mucograft prototype) to enhance the width of keratinized tissue in patients with fixed prosthetic restorations: a randomized prospective clinical trial. *J Clin Periodontol* 2009;36:868-76.
25. Agudio G, Nieri M, Rotundo R, Cortellini P, Pini Prato G. Free gingival grafts to increase keratinized tissue: a retrospective long-term evaluation (10 to 25 years) of outcomes. *J Periodontol* 2008;79:587-94.
26. Hatipoglu H, Keceli HG, Guncu GN, Sengun D, Tozum TF. Vertical and horizontal dimensional evaluation of free gingival grafts in the anterior mandible: a case report series. *Clin Oral Investig* 2007;11:107-13.
27. Landi L, Sabatucci D. Plastic surgery at the time of membrane removal around mandibular endosseous implants: a modified technique for implant uncovering. *Int J Periodontics Restorative Dent* 2001;21:280-7.
28. Seibert JS, Louis JV. Soft tissue ridge augmentation utilizing a combination onlay-interpositional graft procedure: a case report. *Int J Periodontics Restorative Dent* 1996;16:310-21. Erratum in: *Int J Periodontics Restorative Dent* 1996;16:521.
29. Mormann W, Schaer F, Firestone AR. The relationship between success of free gingival grafts and transplant thickness. Revascularization and shrinkage: a one year clinical study. *J Periodontol* 1981;52:74-80.
30. Orsini M, Orsini G, Benlloch D, Aranda JJ, Lazaro P, Sanz M. Esthetic and dimensional evaluation of free connective tissue grafts in prosthetically treated patients: a 1-year clinical study. *J Periodontol* 2004;75:470-7.
31. Barone R, Clauser C, Grassi R, Merli M, Prato GP. A protocol for maintaining or increasing the width of masticatory mucosa around submerged implants: a 1-year prospective study on 53

---

patients. *Int J Periodontics Restorative Dent* 1998;18:377-87.  
32. Park JB. Increasing the width of keratinized mucosa around en-

osseous implant using acellular dermal matrix allograft. *Im-*  
*plant Dent* 2006;15:275-81.