

**REVIEW**

# Complications associated with ventriculoperitoneal shunts in dogs and cats with idiopathic hydrocephalus: A systematic review

Gabriele Gradner  | Rose Kaefinger | Gilles Dupré

Department of Small Animal Surgery, Clinic of Small Animal Surgery, Vienna, Austria

**Correspondence**

Gabriele Gradner, Clinic of Small Animal Surgery, Veterinärplatz 1, 1210 Vienna, Austria.

Email: gabriele.gradner@vetmeduni.ac.at

**Background:** Several case series and case reports have been published about idiopathic hydrocephalus treatment in dogs and cats using ventriculoperitoneal shunts (VPS).**Objectives:** To determine the risk and type of complications in dogs and cats after VPS placement.**Animals:** Sixteen papers were included. Sixty dogs and 13 cats with idiopathic hydrocephalus treated by VPS placement were identified.**Methods:** The databases CAB, Scopus, and Medline were used. Idiopathic/congenital hydrocephalus, feline/canine patients, ventriculoperitoneal shunting, complications, and outcomes were inclusion criteria. The focus was on complication type and time frame within which they arose.**Results:** Complications in dogs (n = 60) were shunt obstruction (6/60; 10%), pain (4/60; 5.5%), shunt infection (3/60; 4.1%), disconnection (3/60; 4.1%), excessive shunting (2/60; 2.7%), and kinking (1/60; 1.6%). Complications in cats (n = 13) were coiling of the shunt in the SC tissue (2/13; 15.4%); kinking (1/13; 7.7%); and shunt obstruction (1/13; 7.7%). Complications were most likely during the first 6 months after shunt placement.**Conclusion and Clinical Importance:** Ventriculoperitoneal shunting is considered a viable treatment option for patients with hydrocephalus. Potential complications should be discussed with the owner. Early diagnosis of complications is essential.**KEYWORDS**

canine hydrocephalus, feline hydrocephalus, hydrocephalus shunting systems, idiopathic hydrocephalus, shunt complications, ventriculoperitoneal shunt

## 1 | INTRODUCTION

Hydrocephalus is defined as any increase in the volume of cerebrospinal fluid (CSF) within the brain. Developmental obstructive hydrocephalus is not fully understood yet, and therefore is also known as congenital hydrocephalus.<sup>1</sup> As in acquired obstructive hydrocephalus, the developmental type also results in hypertensive noncommunicating hydrocephalus. Malformations such as stenosis of the mesencephalic aqueduct, which often is related to fusion of the parenchyma of both rostral colliculi and, rarely, partially united or incompletely divided caudal colliculi may be the reasons. This malformation forms

the basis of the “bulk-flow” concept of CSF accumulation, where excessive fluid accumulation results from obstruction of CSF flow within the ventricular system. The “hydrodynamic theory” contends that brain capillaries do not remain open during the entire cardiac cycle because of poor intracranial compliance as an underlying disorder. This distinction is important because much CSF absorption actually occurs at the capillary level, rather than via the arachnoid villi.<sup>2</sup> Dogs with congenital hydrocephalus and malformed or missing brain structures such as the limbic system, capsula interna, basal ganglia, and other structures might not have the same prognosis as dogs with hydrocephalus and intact brain anatomy. In veterinary medicine, information about intracranial pressure, brain compliance, and other important functional parameters justifying installation of a shunt, and consequently equipment most likely to be suitable for a good

**Abbreviations:** CI, confidence interval; CSF, cerebrospinal fluid; MRI, magnetic resonance imaging; VPS, ventriculoperitoneal shunt.

This is an open access article under the terms of the Creative Commons Attribution-NonCommercial License, which permits use, distribution and reproduction in any medium, provided the original work is properly cited and is not used for commercial purposes.

© 2019 The Authors. *Journal of Veterinary Internal Medicine* published by Wiley Periodicals, Inc. on behalf of the American College of Veterinary Internal Medicine.

outcome is chosen. Clinically, in some cases, a shunt can be helpful, but a methodical approach to standardize decision-making is lacking. Common physical characteristics are presentation within the first 6 months of life, a large dome-shaped head, open fontanelles or larger calvarial defects, and bilateral ventrolateral strabismus. Clinical signs usually reflect a forebrain disorder and include obtundation, behavior abnormalities, difficulty in house training, decreased vision or blindness, circling, pacing, restlessness, and seizure activity. Affected dogs predominantly present with enlarged lateral as well as third ventricles, although distension of the 4th ventricle also has been described.<sup>3</sup> The purpose of ventriculoperitoneal shunt (VPS) surgery is to allow CSF flow through a shunting mechanism from the intracranial ventricles to the peritoneum. Although surgery is the treatment of choice when treating hydrocephalus, complications are relatively common. In humans, causes for shunt failure include mechanical failure of the shunt, infection, and functional failure from overshunting or undershunting. Attention was focused on the identity of the complications and the time frame within which they arose. The applied shunt systems were assessed for complications. The hypotheses were the main complication when placing a VPS in dogs and cats is shunt occlusion, and there are no differences in the kind of complications between dogs and cats.

## 2 | MATERIALS AND METHODS

For this systematic review, the “RCVS Knowledge” and the published standard for reporting systematic reviews following the “Preferred Reporting Items for Systematic Reviews and Meta-Analyses (PRISMA) guidelines” were used as a guideline for evidence-based medicine.<sup>4,5</sup> By “The PICO Method” (P-Populations/People/Patient/Problem, I-Interventions, C-Comparison, O-Outcome), the following keywords were defined: Patient/Population (dog, dogs, puppy, puppies, cat, cats, feline, veterinary patients, hydrocephalus); Intervention (VPS, ventriculoperitoneal shunt, ventriculoperitoneal shunt placement, ventriculoperitoneal shunting systems, treatment, surgery, surgical); Comparison/Control (human medicine, animal model); Outcome (shunt-related complications, overshunting, undershunting, shunt infection, shunt occlusion, complications with ventriculoperitoneal shunting systems, long-term outcome after VPS placement, shunt failure). The databases CAB, Medline, and Scopus were searched on March 19, 2018, for all relevant papers published until that date. The languages English and German were accepted, including when only the abstract was written in English.<sup>6</sup> Further inclusion criteria were feline and canine patients with idiopathic hydrocephalus, congenital hydrocephalus, external hydrocephalus, treatment by VPS, case reports and case series, clear outcome of complications, and timeline. A search in the databases resulted in 752 articles (Figure 1). In 1 study, outcomes of idiopathic and acquired hydrocephalus were evaluated as a single disease, and thus the study had to be excluded. The corresponding author could not be reached for comment.<sup>7</sup>

Ultimately, 16 papers were included in the literature review and classified in “Levels of Evidence for Prognostic Studies”. Case reports were assigned to Level V (expert opinion, case report, or clinical example) and case series to Level IV.<sup>8</sup> Among these were 3 case series and 13 case reports. As a case number, 60 dogs were included, 50 from

case series and 10 from case reports. Thirteen cats were eligible, 7 were part of case series and 6 were case reports.

The papers were scanned for complications that arose after VPS placement. Clinical signs before shunt placement and the main diagnostic imaging findings were recorded. Complications were defined as obstruction, pain, infection, disconnection, overshunting, kinking, coiling, breakage, and postoperative seizures with no seizures in the preoperative period. Complications were assigned to time periods: the short-term period (from surgery till 4 weeks post-surgery), median term period (4 weeks to 6 months post-surgery), or long-term period (>6 months post-surgery). The outcomes were defined as survival, death, euthanasia, or lost-to-follow-up. To specify more detailed outcome in mild, moderate, and life-threatening complications, the Spine Adverse Events Severity System (SAVES V2) was used.<sup>9</sup> This system contains 6 grades: grade 1 (does not require treatment and has no adverse effect) and grade 2 (requires simple or minor treatment but has no long-term effect on patient outcome) are defined as minor complications, whereas grade 3 (invasive or complex treatment necessary, with a temporary adverse effect of < 6 months) and higher (grade 4: invasive or complex treatment with a prolonged adverse effect of more than 6 months; grade 5: life-threatening or necessitating institutional investigation; grade 6: resulting in patient death) are considered major complications.

For identification of possible risk factors, the shunt systems were assigned by different valve types. The category of differential pressure was subdivided into the following valves with variable opening pressures: low-low-pressure valve (<1 cm H<sub>2</sub>O), low-pressure valve (0-5 cm H<sub>2</sub>O), medium-pressure valve (5-10 cm H<sub>2</sub>O), and high-pressure valve (10-15 cm H<sub>2</sub>O).<sup>10</sup> The paedigAV (Miethke, Germany), with an opening pressure of 4/14 cm H<sub>2</sub>O horizontal/vertical, was treated as its own category. The valve types were divided into valveless, gravity-assisted valves, diaphragm valves, and ball-in-cone valves. In order to sum up the general complications that occur in dogs and cats after placing a VPS and to determine if a significant difference in complications evolves in dogs and cats, these species are described separately. In 2 dogs and 2 cats, the shunt type and valve were not specified, leaving 57 dogs and 11 cats for statistical analysis.<sup>11-13</sup>

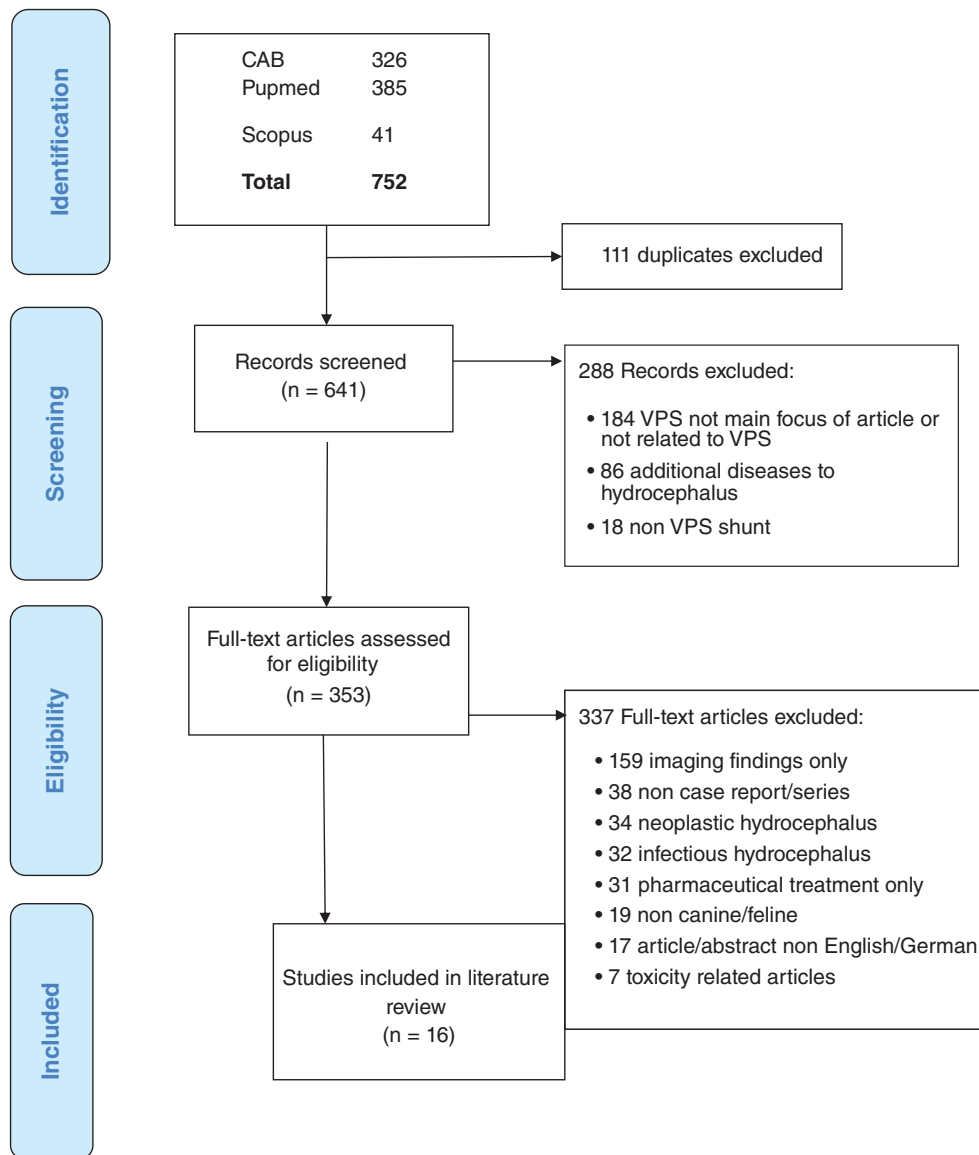
### 2.1 | Statistics

To determine if any significant differences occurred in complications between dogs and cats, the confidence interval (CI) was used in statistical analysis. The CI is the range of values in which the true value in the population is expected to fall, based on the study results. The probability that the true value lies outside the CI was given <5%.<sup>14</sup> To assess significant differences in complications between dogs and cats, the level of confidence of 95% was assumed. To assess the complication rate of different shunt systems, the CI of 95% also was applied.

## 3 | RESULTS

### 3.1 | Case series

From the case series, 50 dogs and 7 cats could be analyzed (Table 1). The cats had no shunt-related complications described. One study



**FIGURE 1** Flow of information through the different phases of systematic review; inclusion criteria were feline and canine patients with idiopathic hydrocephalus, surgical treatment through ventriculoperitoneal shunt, case reports and case series, clear outcome of complications and timeline, and articles in English or German

described the outcome of 30 dogs and 6 cats after VPS placement.<sup>15</sup> In this case series, a paedigAV Shunt (Fa. Miethke; gravity-assisted valve) was used. Complications were shunt obstruction (n = 4 dogs; 11% of all animals; range, 2-13 months; median postoperative interval, 5 months; 3 died); shunt infection (n = 3 dogs; 8.5% of all animals, at 13 months and 21 months after surgery; 2 died); overshunting (n = 1 dog; 2.8% of all animals, 2 weeks after the operation; 1 died); and, disconnection of the catheter (n = 1 dog; 2.8% of all animals, 2 months after implantation). In this study, 8 dogs and 4 cats had preoperative seizures. Two patients continued with postoperative seizure events, and in 3 dogs and 1 cat, seizure activity recurred after a period free of clinical signs of 3-22 months. One dog with no preoperative seizures developed postoperative seizure activity (time after surgery not given). Seven dogs and 2 cats were lost to follow-up. Among the 36 animals, median follow-up time after shunt implantation was 6 months (range, 1 day to 118 months). Eighteen months after surgery, 20 of 36 animals (55%) were alive.<sup>15</sup>

Another study described 12 dogs with VPS placement (Medtronic ultra-small, very low pressure, diaphragm valve).<sup>16</sup> Four dogs (4/12; 33.3%) developed pain within the first 10-18 days after surgery. One dog with no preoperative seizures experienced 1 seizure after shunt placement, occurring 6 months after surgery (n = 1; 8%). Kinking of the catheter with resulting undershunting occurred 4 months after surgery and the operation was successfully revised. Altogether, 4 dogs died or were euthanized: 1 dog because of recurrent painful episodes, 2 dogs because of neurologic deterioration, and 1 dog for other causes. Eight dogs were alive after a median follow-up time of 22.5 months (range, 6-19 months).<sup>16</sup>

Another case series consisted of 13 dogs and 2 cats.<sup>17</sup> Based on the structured layout, 8 dogs and 1 cat with idiopathic hydrocephalus could be included in our study. Six valveless paedigAV gravity-assisted valves (Fa. Miethke) and 3 spring-loaded ball-in-cone valves (Hakim valves) were used. Excluded were dogs and cats with secondary hydrocephalus (n = 2), euthanasia at the time of diagnosis (n = 2), and conservative treatment only (n = 2). Complications were

**TABLE 1** Case series: clinical signs, shunting system applied, and the resulting 18 complications

	Biel et al. (2013) <sup>15</sup> : 30 dogs, 6 cats <sup>a</sup>	Shihab et al. (2013) <sup>16</sup> : 12 dogs	Lautersack (2003) <sup>17</sup> : 8 dogs, 1 cat <sup>a</sup>	Summation of complications: 50 dogs, 7 cats
Clinical signs at the time of presentation				
Blindness	17 dogs, 4 cats	5 dogs	5 dogs	31
Ataxia	17 dogs, 2 cats	11 dogs	2 dogs	30
Circling	11 dogs	8 dogs	1 dog	20
Strabismus	6 dogs, 1 cat	4 dogs		11
Shunting system				
	paediGAV	Low-low pressure Medtronic	Valveless (6); Hakim ball in cone valve (3)	
Shunt occlusion	4		1	5
Pain		4		4
Overshunting	1			1
Shunt infection	3			3
Disconnection, Kinking	1	1 <sup>b</sup>	1	3
Postoperative seizures <sup>c</sup>	1	1		2

<sup>a</sup> Cats had no shunt related complication.

<sup>b</sup> Kinking.

<sup>c</sup> Postoperative seizures excluded are patients with preoperative seizures.

obstruction of the catheter associated with a punctured ependymal vessel, which was revised 3 days after the first surgery and ended in euthanasia (1/9; 12.5% of the dogs). One shunt failure as a consequence of disconnection between the ventricular tube and the burr hole deflectors was described and successfully revised 7 months after the first surgery (1/9; 12.5% of the dogs). Two dogs had preoperative epileptiform seizures with worsening after VPS placement and were lost to follow-up on days 19 and 21 (2/9; 25%). One cat also was presented with preoperative seizures. The median follow-up time was 49 days (range, 9 days - 24 months). The cat had a follow-up time of 11 months with no clinical signs. Removing the dog that died after obstruction, the 2 dogs lost to follow-up and the dog that died of other causes 2 months after surgery left 4 dogs and 1 cat with a median follow-up time of 12 months (range, 1-24 months).<sup>17</sup> A summary of the complications described in case series can be found in Table 1.

### 3.2 | Case reports

Six cats and 10 dogs with VPS shunt placement were reported in 14 case reports. In cats, coiling (2/6; 33.3%) in combination with migration of the peritoneal catheter was described as the most common complication.<sup>6,18</sup> Other complications were obstruction (1/6; 16.7%) and subdural hematoma in combination with kinking of the distal catheter (1/6; 16.7%).<sup>6,19</sup> Two cats had preoperative and postoperative seizures.<sup>11</sup> The median follow-up time in cats was 27.8 months (range, 13-42 months). All cats were alive at the time of writing (Table 2).

In dogs described in case reports, the complications were disconnections (1/10; 10%),<sup>20</sup> obstruction (1/10; 10%),<sup>21</sup> overshunting with slit-like ventricle (1/10; 10%),<sup>20</sup> and postoperative seizures in combination with breakage of the tube (1/10; 10%).<sup>22</sup> Subdural fluid on postoperative magnetic resonance imaging (MRI) (2/10; 20%) was not clinically relevant.<sup>23</sup> Two dogs had preoperative as well as postoperative seizures.<sup>22,24</sup> Three dogs with preoperative seizures had no further seizure activity after VPS placement.<sup>12,25,26</sup> Median follow-up time was 11 months (range, 2-42 months) with 2 nonsurvivors (Table 3).

One dog died as a consequence of seizures 32 months after the 1st surgery; 1 dog was euthanized because of overshunting after 2 surgeries 5 months after the initial surgery.<sup>20,22</sup>

To summarize, the complications described in case reports were coiling (n = 2), obstruction (n = 1), kinking (n = 1), disconnection (n = 1), overshunting (n = 1), and breakage of the tube (n = 1). The complications of case series and case reports are summarized in Table 4. The complications were related to the time after surgery. Twenty-one of 26 complications occurred within the first 6 months.

#### 3.2.1 | Overall complications

Obstruction was the most common complication (7/73; 9.6%). In 1 dog, an ependymal vessel was punctured during placement of the VPS, which led to shunt obstruction. The dog was euthanized within a short period of time.<sup>17</sup> One dog was successfully treated for shunt occlusion using prednisolone, amoxicillin, 0.9% NaCl fluids, buprenorphine, and omeprazole during the short term.<sup>21</sup> Two dogs were euthanized mid-term and 1 was euthanized long-term because of shunt occlusion. Two of those dogs had infection identified as an underlying cause. One dog developed shunt occlusion mid-term and underwent successful revision surgery.<sup>15</sup> One cat had a diagnosis of shunt obstruction, but lack of clinical signs precluded further treatment.<sup>6</sup>

Three dogs (3/73; 4.1%) with shunt infection were described in 1 case series.<sup>15</sup> In 2 cases, this resulted in occlusion of the shunt and the owners chose euthanasia (1 in the short-term and 1 in the mid-term). The causative agents could not be identified. One patient had successful revision surgery in the long-term period.<sup>15</sup> The dog underwent successful shunt replacement 21 months after the first surgical intervention. No bacteria were cultured from a CSF sample, but the diagnosis was made on the basis of neutrophilic pleocytosis with karyolysis.

Overshunting was found in 2 dogs (2/73; 2.7%). One dog died acutely in the short-term, 2 weeks after surgery, because of overshunting and brain collapse.<sup>15</sup> The second dog developed overshunting within the mid-term period and was treated by a slow injection of saline solution and disconnection of the shunt. Neurological signs did

**TABLE 2** Case reports about 6 cats treated with ventriculoperitoneal shunts

Author	Clinical signs at the time of presentation	Device used	Complication	Treatment	Follow-up time in months
Bennett et al. 2016 <sup>18</sup>	Circling, ataxia, blindness	Medtronic low-low pressure; diaphragm valve	Cranial migration and coiling in the subcutaneous tissue 13 weeks post-op	Revision surgery 13 weeks after surgery	26
Dewey et al. 2003 <sup>11</sup>	Lethargy, seizure	Unknown	Seizure preoperatively and postoperatively	Phenobarbital	42
Dewey et al. 2003 <sup>11</sup>	Seizure, bilateral strabismus	Unknown	Seizure preoperatively and postoperatively	Phenobarbital	8
Ori et al. 1997 <sup>6</sup>	Ataxia	Valveless tube	Obstruction of the drainage tube	No clinical signs so no treatment	60
Ori et al. 1997 <sup>6</sup>	Ataxia	Valveless tube	Coiling of the tube into the subcutaneous tissue of the dorsal chest	No clinical signs so no treatment	17
Tani et al. 2001 <sup>19</sup>	Ataxia, blindness	Fuji Systems low pressure shunt, diaphragm valve	Subdural hematoma, several times kinking of the distal catheter	Revision surgery	14

not improve and the dog was euthanized.<sup>20</sup> In 2 dogs (11 days and 6 months after surgery) and 1 cat (immediately after surgery), a subdural hematoma could be found on the initial MRI (n = 3; 4.1%). There were no clinical findings related to the hematoma, and it was not included in the evaluation.<sup>19,23</sup> Pain (4/73; 5.6%) occurred in 4 dogs during the short-term period. One was euthanized because of persistent pain and another because of neurological deterioration. In the other 2 dogs, the pain spontaneously resolved. Pain as a result of overshunting was discussed.<sup>16</sup>

Disconnection occurred in 3 dogs (3/73; 4.1%) in the mid-term period. Two dogs underwent successful revision surgery.<sup>15,17</sup> One dog had revision surgery after 2 months because of overshunting and, after a further 3 months, the shunt system was reconnected. Disconnections of the valve led to euthanasia in this case.<sup>20</sup>

Kinking of the peritoneal catheter with insufficient drainage was described in 2 (2/73; 2.7%) patients. In the dogs, the time of onset was 4 months after surgery.<sup>16</sup> Kinking of the catheter occurred in 1 cat in the short-term period. In both cases, revision surgery resulted in sustained clinical improvement.<sup>19</sup> Coiling of the peritoneal catheter in the SC tissue occurred in 2 cats (2/73; 2.7%). The first cat had revision surgery 13 weeks after implantation with a follow-up time of 26 months.<sup>18</sup> The second cat with SC coiling showed no neurological signs after a follow-up time of 17 months.<sup>6</sup>

In 1 dog, breakage of the ventricular tube occurred 3 months after surgery (1/73; 1.4%). This dog had 2 revision surgeries and finally died 32 months after the first surgery because of clonic seizures.<sup>22</sup> A second dog died of status epilepticus 10 days after surgery in a published case series.<sup>15</sup> Postoperative seizures were described within 6 months after surgery in 2 dogs that did not show preoperative seizure activity (2/73; 2.7%).<sup>15,16</sup> Seventeen patients, 11 dogs and 6 cats (17/73; 23.3%), had preoperative as well as postoperative seizures. Eight dogs (8/73; 19.2%) had preoperative seizures only, whereas 2 dogs (2/73; 2.7%) developed seizures postoperatively as a new clinical problem. Neurological deterioration was a cause of euthanasia in 7 dogs and in 1 cat.<sup>15,16</sup> Four dogs and 1 cat died of other causes.<sup>15-17</sup>

No VPS shunt placement-related complications were found in the publications.<sup>23-28</sup>

### 3.3 | Outcome and survival of dogs and cats

Of the 73 patients, 10 animals died or were euthanized because of shunt-related complications (13.7%). The reasons for death or euthanasia were obstruction (4/7, 57%), infection (2/3; 66.7%), overshunting (2/2; 100%), disconnection (1/3; 33.33%), and pain (1/4; 25%) (Table 4).

Seven dogs and 1 cat were euthanized because of neurological deterioration. Neurological deterioration, pain, and seizures may result from the progressive nature of the disease. Four dogs and 1 cat died or were euthanized for other reasons (6.8%). One dog died of renal failure, 1 cat because of hypertrophic cardiomyopathy, and for the other dogs, the reason was unknown.<sup>15,16</sup> The median follow-up time of the survivors was 16.5 months (range, 1 day-42 months). Survival times after surgery were (n = 73): 1 month (47; 64.4%); 6 months (41; 56.1%); 12 months (33; 45.2%); 18 months (31; 42.5%); 24 months (12; 16.4%); and 42 months (1; 1.4%). One dog survived >9.5 years after surgery. The first 6 months after surgery seem to be critical: 9 complications occurred within the first 3 months, 12 complications between 3 and 6 months, and 3 occurred after 6 months. In 2 complications, the time of onset was not described. Nine dogs and 2 cats were lost to follow-up (11/73; 15%).

### 3.4 | CI for the complications and valves used

In 2 cats and 2 dogs, the employed shunt device and valve were unknown (4/73; 5.5%). Therefore, valve-related complications were calculated for the known 69 valves. In dogs, 22 complications occurred after shunt placement (22/60; 36.6%; 95% CI, 24%-49%). In cats, 4 complications occurred (4/13; 30.7%; 95% CI, 6%-56%). The gravity-assisted valve type was used in 37 patients (37/69; 53.6%), and 11 complications occurred (11/37; 29.72%; 95% CI, 17%-48%). The diaphragm valve was placed in 20 patients (20/69; 29%), and 10 complications occurred (10/20; 50%; 95% CI, 28%-72%). Four patients

**TABLE 3** Case reports about 10 dogs treated with ventriculoperitoneal shunts

Author	Clinical signs at the time of presentation	Device used	Complication	Treatment	Follow-up time in months
Bittermann et al. 2016 <sup>20</sup>	Circling, head tilt	PaediGAV, low-pressure gravity-assisted valve	1 month after surgery overshunting	The shunt system was disconnected and after 3 months reconnected. A disconnection of the valve occurred 2 weeks later. The owner elected for euthanasia because of neurological deterioration	5
da Rocha Filgueiras et al. 2009 <sup>27</sup>	Blindness, lethargy	High-pressure Hakim valve system, spring-loaded ball in cone valve	Seizure preoperatively and postoperatively	Phenobarbital	20
Giacinti et al. 2016 <sup>21</sup>	Lethargy, strabismus	Medtronic, diaphragm valve	Obstruction 17 days after surgery	Ventriculocentesis, cortisone, omeprazole, amoxicillin; successful	3
Hasegawa et al. 2005 <sup>22</sup>	Blindness, Ataxia	Low-pressure type abdominal tube Fuji Systems, diaphragm valve	<ul style="list-style-type: none"> <li>• 3 months post-op broken ventricular tube</li> <li>• after 9 months seizures occurring every 3 months</li> <li>• 28 months after the 1st surgery tonic clonic seizures</li> </ul>	<ul style="list-style-type: none"> <li>• Revision surgery and reinsertion of a ventricular tube</li> <li>• 11 months (8 months after 2nd operation) after 1st operation on the MRI the tip of the ventricular tube was in the right hippocampus; 9 months after the 2nd operation, the dog developed seizures; and 25 months after the 2nd operation, generalized seizures, died 32 months after the 1st surgery of clonic seizures</li> </ul>	32
Kim et al. 2006 <sup>25</sup>	Ataxia, lethargy, blindness	LPV II Heyer-Schulte, diaphragm valve	Preoperative seizures, no postoperative ones		4
Kitagawa et al. 2008 <sup>23</sup>	Obtunded, blindness	Fuji Systems low-pressure shunt, diaphragm valve	MRI signs of overshunting in terms of subdural fluid accumulation		30
Kitagawa et al. 2008 <sup>23</sup>	General hyperesthesia, blindness, ataxia	Fuji Systems low-pressure diaphragm valve	MRI: subdural fluid accumulation		2
Mateo et al. 2012 <sup>12</sup>	Lethargy, hypermetria, strabismus	Unknown valve	Preoperative seizure improved		6
Scarpante et al. 2013 <sup>13</sup>	Fly catching episodes, circling, ataxia, blindness, strabismus	Unknown valve			12
Woo et al. 2009 <sup>26</sup>	Ataxia, seizure, nystagmus	Low-low pressure Medtronic, diaphragm valve	Preoperative seizures, postoperative none, not complete neurological recovery		2

Abbreviation: MRI, magnetic resonance imaging.

(4/69; 5.8%) received a spring-loaded ball-in-cone valve, and 1 complication occurred (1/3; 33.3%; 95% CI, 0-67%). Eight patients (8/69; 11.6%) received a valveless shunt type, and 3 complications occurred (3/8; 37.5%; 95% CI, 4%-71%). Two patients received a ball-in-cone valve, and no complications occurred. The CI of the different valve types used among the dogs and cats overlapped. No significant difference was found among the different valve types in the prevalence of complications.

## 4 | DISCUSSION

Shunt catheter obstruction was by far the most common cause for shunt malfunction. Obstructions may occur within every part of the shunting system. Obstruction of the proximal catheter occurred in 9.6% of the patients and kinking of the distal catheter in 2.7%. The most common site of obstruction was the proximal catheter, which is comparable to studies of humans.<sup>28</sup> One study evaluated long-term

**TABLE 4** Complications using the SAVE V2 grading system

Complication (n = 26)	Leading to death or euthanasia (Grade 6; n = 10)	Successful surgical revision (Grade 3; n = 8)	Medical treatment (Grade 2; n = 6)	No treatment necessary (Grade 1; n = 2)	Total number (n = 73) (%)
Obstruction	4	1	1	1	7 (9.6)
Pain	1		3		4 (5.5)
Infection	2	1			3 (4.1)
Disconnection	1	2			3 (4.1)
Overshunting	2				2 (2.7)
Kinking		2			2 (2.7)
Coiling		1		1	2 (2.7)
Breakage of the tube		1			1 (1.4)
Postoperative seizures <sup>a</sup>			2		2 (2.7)

Minor complications are defined as grades 1 and 2, whereas grade 3 and higher were considered major complications.

<sup>a</sup> Patients without preoperative seizures; grade 1: does not require treatment and has no adverse effect; grade 2: requires simple or minor treatment but have no long-term effect on patient outcome; grade 3: invasive or complex treatment (surgery <6 months adverse effect); grade 4: invasive or complex treatment (surgery >6 months adverse effect); grade 5: life threatening or necessitate institutional investigation; grade 6: resulting in patient death.

follow-up shunting therapy and determined that obstruction was responsible for 56% of shunt failures in children.<sup>29</sup> One speculation is that the proximal catheter may become obstructed by brain parenchyma as it is passed through the cerebral cortex. However, protecting the proximal catheter with a removable sheath has not improved revision rates.<sup>30</sup> Another hypothesis to explain the causes of shunt obstruction is that blood and proteinaceous fluid may gradually occlude the catheter tubing. An analysis of 58 pediatric patients at or just before VPS placement did not find any association of shunt failure or infection with CSF cell count, protein concentration, or glucose concentration. The average concentration of protein in CSF in dogs and cats is slightly lower than in humans (< 30 mg/dL as compared with 50-150 mg/dL).<sup>31</sup> The lower incidence of obstruction of the proximal catheter and valves in dogs and cats as compared with humans may support this hypothesis that high protein concentration contributes to obstruction. In our study, no obstruction of the valve systems was reported. Most of the proximal shunt obstructions occurred during the first 6 months after surgery (5/7). When shunt obstruction develops, revision surgery usually is necessary. In 1 dog, successful revision surgery was performed. In 4 cases, the complication led to euthanasia whether or not costs or prognostic factors played a role in the decision remains unknown.

#### 4.1 | Infection

In human patients with clinical signs of shunt malfunction, infection should always be suspected. Infection is the second most common cause of malfunction with a reported rate of approximately 8%-15% among patients who undergo VPS placement.<sup>32</sup> In our study, 2 of the 3 described dogs subsequently developed an obstruction. In both cases, bacterial cultures were positive. In the third dog, a CSF sample had neutrophilic pleocytosis with evident karyolysis, but bacterial culture was negative. In pediatric surgery, infection rates after VPS placement are 5%-20%.<sup>28</sup> The infecting agent is most likely inoculated at the time of surgery, with staphylococci most commonly isolated.<sup>29</sup> As a result, infection develops a short time after surgery in children, with most infections progressing within 2 months after shunt insertion. These findings do not fully correlate with our results because the dogs developed infection at 2, 13, and 21 months after shunt implantation.

It can be challenging to distinguish primary obstruction from infectious-related obstructions because the clinical signs of primary obstructions are nausea, vomiting, headache, and fever. One study found that the presence of fever and >10% neutrophils ventricular fluid had a specificity of 99%, a positive predictive value of 93%, and a positive test probability of 92% for predicting shunt infection.<sup>33</sup> In the human medical literature, risk factors for shunt infection have been identified: young age, postoperative CSF leakage, glove holes during shunt handling, African American race, public insurance, previous shunt infections, and intraventricular hemorrhage.<sup>34</sup> To prevent shunt infection in humans, risk reduction is achieved by restriction of operating room personnel, effective asepsis, VPS surgery early in the morning, as well as minimal skin exposure, double gloving, and prophylactic administration of antimicrobials.<sup>29</sup> Antibiotic-impregnated shunt systems seem to be a viable option to prevent infection in human medicine. The impregnated shunt systems provided anti-staphylococcal protection, particularly during the early postoperative period, which is prone to shunt infections.<sup>35</sup> Another approach to decrease the infection risk in pediatric patients is to inject vancomycin and gentamicin in the reservoir of the shunt and around the peritoneal catheter once or twice.<sup>36</sup> The usage of antibiotic-impregnated shunt systems in veterinary medicine has yet to be described. However, the difference in time of onset of infection between animals and children may play a role in the effectiveness of the impregnated shunts.

#### 4.2 | Overshunting

Overshunting with neurological deterioration and slit-like ventricles was found in 2 patients. In 3 animals with VPS placement, baseline MRI identified a subdural hematoma. The animals showed no clinical signs, and overshunting was reported as an incidental finding during baseline MRI with no further consequences. In human medicine, subdural hematomas after shunt placement have been described in up to 53% of patients with normal pressure hydrocephalus. Some subdural hematomas do not cause clinical signs and can resolve spontaneously, but in approximately 16%, the subdural collections require surgical intervention.<sup>37</sup> It is thought that bridging veins are stretched as the brain sinks away from the skull when the pressure inside the ventricles decreases after shunting.<sup>34</sup> Programmable shunt valves, in which the opening pressure of the valve can be changed postoperatively,

seem to work efficiently. Cases have been reported in which adjustment of the shunt valve alone has allowed for complete resolution of subdural hematomas.<sup>38</sup> The costs of these valves may limit their use in veterinary medicine. In order to prevent this phenomenon, low-pressure or very-low-pressure valves are used most frequently in animals. In 2 described cases in our review, a paedGAV system was used. The opening pressure (ie, if it was 4/14 or 4/24) was not described in 1 case series.<sup>15</sup> In the described case report, a 4/24 valve was used and sutured to the long axis of the dog in a horizontal direction.<sup>20</sup> This may be crucial for the mechanism used in this type of shunt designed for humans. In humans, veins undergo a high pressure difference between standing and lying down. While the patient is lying down, the free-floating balls in the cone do not cause any occlusion and the canals are kept open. In the vertical position, the balls close the canals up to a certain pressure and prevent overshunting. Theoretically, the horizontal position is like a valveless system and careful consideration should be taken where and in which position this particular valve is sutured. One study found no difference in complications between valveless and valve systems, but because of our overall low case number, no conclusion can be drawn about these findings.<sup>17</sup>

### 4.3 | Pain

Between the 2nd and the 3rd weeks, 4 dogs were readmitted with signs of pain. In people, severe, life-modifying headaches have been reported after shunt placement because of intermittent obstruction of the ventricular catheter. Another reason reported was intracranial hypotension because of overshunting, and this complication should be considered when unexplained pain occurs after surgery.<sup>16</sup>

### 4.4 | Disconnection, kinking, and coiling

Shunt occlusion, disconnection, kinking, and coiling of the VPS shunt system are causes for undershunting. Disconnection may occur between the ventricular catheter and the anchor, between the anchor and the proximal catheter, between the proximal catheter and the valve system, or between the valve and the distal catheter. In the 3 described cases, the disconnection occurred between the valve and the distal catheter ( $n = 2$ ) and between the anchor and the abdominal catheter ( $n = 1$ ).<sup>15,17</sup> Two underwent successful revision surgery and 1 was euthanized because of shunt disconnection. In that dog, it was suspected that tension occurred because of SC adhesion of the tube in the neck area.<sup>20</sup> Eight percent (25/305; 8.1%) of revision surgeries in a published study of children were performed because of disconnection of the catheters. The most common location for disconnection was in the cervical region in 12 patients and the distal valve junction in 6 patients.<sup>39</sup> In humans, the most common complications are associated with undershunting: headaches, vomiting, and drowsiness. These clinical signs are not described in veterinary medicine. Except for vomiting, these signs are subjective and may be overlooked by pet owners. Veterinary patients do not necessarily show any clinical signs after disconnection of the shunting system, and routing postoperative imaging studies should be recommended. In human medicine, disconnection occurs as a consequence of scar formation along the catheter in the mobile cervical region. Uni-shunts may prevent disconnection, but no parts of the

shunt system can be changed in cases of kinking or obstruction.<sup>39</sup> To allow free movement of the head and to address growth of the animal, some surgeons place loops of the catheter on the neck. Two catheters kinked and became ineffective: In 1 dog a loop led to kinking of the catheter in the neck or cranial vault area.<sup>16</sup> In the second case, the abdominal portion of the catheter in a cat kinked, but the exact location was not described. Thus, it is unclear if the kinking appeared at the entry point into the abdomen, in the abdomen, or along the SC pathway.<sup>19</sup> Revision surgery resulted in sustained clinical improvement. Coiling of the abdominal catheter occurred in 2 cats, a complication that was not observed in dogs. The incidence of retrograde migration of the peritoneal catheter in human medicine is as high as 0.6% and occurs in the first 3 months after surgery.<sup>40</sup> In our review, 1 cat had revision surgery at 13 weeks after surgery, in the other cat coiling was an incidental finding with no clinical signs.<sup>6,18</sup> Revision surgery and replacement of the peritoneal catheter within a new SC tunnel was successfully performed. This approach also is the current treatment recommendation.<sup>41</sup> Upward migration could have a combination of causes: suction from negative intracranial pressure created by CSF drainage, extrusion from the abdomen by positive intra-abdominal pressure (which occurs secondary to physiological processes), excessive CSF within the abdomen, convoluted SC tunneling as well as lack of correct fixation of the catheters. A “windlass effect” also has been described. A proximal anchoring point (eg, granulation tissue), facilitates flexion-extension movements of the head, which is conducted to the peritoneal catheter, generating a proximal winching effect.<sup>42</sup> It is possible that because of an increased range of motion in the neck and thoracic region of the cat, a similar “windlass effect” was created.

### 4.5 | Study limitations

One weakness of our study is the low evidence level of case series and case reports. Therefore, the published information is incomplete and inconsistent with regard to clinical presentation and diagnostic imaging, which makes the information less valuable. The complications cannot be linked to the clinical presentation. Our study concentrated on complications that may arise through the disease and shunt placement in idiopathic and congenital hydrocephalus only. The clinical findings on initial presentation were inconsistently reported. To complete the clinical picture, the clinical findings are included in Tables 1–3. It is also difficult to distinguish between shunt-related complications and disease progression. The data regarding diagnostic imaging is very sparse and therefore was not included in our results: only 6 MRI studies have been repeated: 3 showed a reduction of ventricle size (median 129 days after surgery; range, 60–208 days).<sup>19,23,25,26</sup> One had a slit-like ventricle because of overshunting 2 months later on.<sup>20</sup> One had clinical improvement, but similar ventricular dilatation as before 8 months after surgery.<sup>22</sup> There is a need for a standardized diagnostic evaluation and follow-up of hydrocephalus patients regarding neurological examination and diagnostic imaging. Two studies had an overlap in time and location.<sup>15,17</sup> The data collection in 1 study was between 2001 and 2009 and mainly at the University of Giessen, Germany.<sup>15</sup> The other study enrolled cases from 2001 to 2003 at the University of Giessen.<sup>17</sup> In 4 cases, the specification of the shunt type used was missing. Some overlap of cases cannot be excluded completely.<sup>15,17</sup>



## 5 | CONCLUSION

Ventriculoperitoneal shunting is a viable treatment option for patients with hydrocephalus. It may increase survival time and also improve quality of life. However, potential complication should be discussed with the owner. It appears that complications are most likely to occur during the first 6 months after shunt placement. Early diagnosis of complications is essential so as to intervene immediately and improve outcome. Therefore, frequent neurological examinations as well as MRI may be essential during the first 6 months after shunt placement.

## ACKNOWLEDGMENT

Thanks to Alexander Tichy for his patient and constant support in statistical questions. A poster with this topic was presented at the ECVS meeting in Athens Greece.

## CONFLICT OF INTEREST DECLARATION

Authors declare no conflict of interest.

## OFF-LABEL ANTIMICROBIAL DECLARATION

Authors declare no off-label use of antimicrobials.

## INSTITUTIONAL ANIMAL CARE AND USE COMMITTEE (IACUC) OR OTHER APPROVAL DECLARATION

Authors declare no IACUC or other approval was needed.

## HUMAN ETHICS APPROVAL DECLARATION

Authors declare human ethics approval was not needed for this study.

## ORCID

Gabriele Gradner  <https://orcid.org/0000-0002-7985-8928>

## REFERENCES

- de Lahunta A. Cerebrospinal fluid and hydrocephalus. In: de Lahunta A, Glass E, Kent M, eds. *Veterinary Neuroanatomy and Clinical Neurology*. 4th ed. Toronto, ON, Canada: Saunders; 2015:78-101.
- Dewey CW. Encephalopathies: disorders of the brain. In: Dewey CW, da Costa RC, eds. *Practical Guide to Canine and Feline Neurology*. 3rd ed. Singapore: Wiley; 2016:141-236.
- Kent M, Glass EN, Haley AC, et al. Hydrocephalus secondary to obstruction of the lateral apertures in two dogs. *Aust Vet J*. 2016;94:415-422.
- RCVS Knowledge [Internet]. London [cited March 17, 2018]. <https://knowledge.rcvs.org.uk>.
- Moher D, Liberati A, Tetzlaff J, Altman DG. Preferred reporting items for systematic reviews and meta-analyses: the PRISMA statement. *PLoS Med*. 2009;6:1-6.
- Ori JY, Komiya M, Yoshikai T. Two cases of feline hydrocephalus treated by ventriculoperitoneal shunt. *J Vet Med Assoc*. 1997;50:599-602.
- de Stefani A, de Risio L, Platt SR, Matiassek L, Lujan-Feliu-Pascual A, Garosi LS. Surgical technique, postoperative complications and outcome in 14 dogs treated for hydrocephalus by ventriculoperitoneal shunting. *Vet Surg*. 2011;40:183-191.
- Burns PB, Rohrich RJ, Chung KC. The levels of evidence and their role in evidence-based medicine. *Plast Reconstr Surg*. 2011;128(1):305-310.
- Chen BP, Garland K, Roffey DM, et al. Can surgeons adequately capture adverse events using the spinal adverse events severity system (SAVES) and orthoSAVES? *Clin Orthop Relat Res*. 2017;475:253-260.
- Arvind S, Anuj S. Pediatric hydrocephalus: does the shunt device pressure selection affect the outcome? *J Indian Assoc Pediatr Surg*. 2012;17(2):54-57.
- Dewey CW, Coates JR, Ducoté JM, Stefanacci JD, Walker MA, Marino DJ. External hydrocephalus in two cats. *J Am Anim Hosp Assoc*. 2003;39:567-572.
- Mateo I. Diverticulum of the third ventricle and absence of interthalamic adhesion in a dog. *Can Vet J*. 2012;53:539-542.
- Scarpante E, Palus V, Cherubini GB. Congenital hydrocephalus case study: pathophysiology, treatment and prognosis. *Companion Anim*. 2013;18:206-209. <https://doi.org/10.12968/coan.2013.18.5.206>.
- Rudolf M, Kuhlisch W, eds. *Biostatistik eine Einführung für Biowissenschaftler*. 1st ed. München: Pearson Studium; 2008.
- Biel M, Kramer M, Forterre F, et al. Outcome of ventriculoperitoneal shunt implantation for treatment of congenital internal hydrocephalus in dogs and cats: 36 cases (2001-2009). *J Am Vet Med Assoc*. 2013;242:948-958.
- Shihab N, Davies E, Kenny PJ, Loderstedt S, Volk A. Treatment of hydrocephalus with ventriculoperitoneal shunting in twelve dogs. *Vet Surg*. 2011;40:477-484.
- Lautersack O, Joedicke A, Tacke S, Bluhm J, Irnich B, Schimke E. Hydrocephalus bei Hund und Katze—therapeutische Möglichkeiten und erste eigene Ergebnisse. [Internet] 2003 [cited March 17, 2018]. <https://www.kleintierklinik-ettlingen.de/assets/uploads/glossar/neurologie/hydrozephalus-teil-2-pdf>.
- Bennett SE, Behr S. Retrograde migration and subcutaneous coiling of a ventriculoperitoneal shunt in a cat. *JFMS Open Rep*. 2016;2:205511691664638. <https://doi.org/10.1177/2055116916646387>.
- Tani K, Tanga A, Itamoto K, et al. Hydrocephalus and syringomyelia in a cat. *J Vet Med Sci*. 2001;63(12):1331-1334.
- Bittermann S, Precht C, Henke D, Forterre F, Karli P. Slit ventricle syndrome and subdural haemorrhage due to suspected overshunting in a dog with hydrocephalus internus. *Vet Rec*. 2016;4:e000284. <https://doi.org/10.1136/vetreccr-2015-000284>.
- Giacinti JA. Ventriculoperitoneal shunt for treatment of hydrocephalus in a French bulldog puppy. *Can Vet J*. 2016;57:309-312.
- Hasegawa T, Taura Y, Kido H, Shibasaki A, Katamoto H. Surgical management of combined hydrocephalus, syringohydromyelia, and ventricular cyst in a dog. *J Am Anim Hosp Assoc*. 2005;41:267-272.
- Kitagawa M, Ueno H, Watanabe S, et al. Clinical improvement in two dogs with hydrocephalus and syringohydromyelia after ventriculoperitoneal shunting. *Aust Vet J*. 2008;86:36-42.
- Dewey CW, Krotscheck U, Bailey KS, Marino DJ. Craniotomy with cystoperitoneal shunting for treatment of intracranial arachnoid cysts in dogs. *Vet Surg*. 2007;36:416-422.
- Kim H, Itamoto K, Watanabe M, Nakaichi M, Taura Y. Application of ventriculoperitoneal shunt as a treatment for hydrocephalus in a dog with syringomyelia and Chiari I malformation. *J Vet Sci*. 2006;7(2):203-206.
- Woo JN, Lee HB, Kim MS, Lee KC, Kim NS. Application of ventriculoperitoneal shunt placement through fontanelle in a hydrocephalus dog: a case report. *Vet Med (Praha)*. 2009;54:498-500.
- da Rocha Figueiras R, de Souza Martins C, de Almeida RM, et al. Long term evaluation of a new ventriculoperitoneal shunt valve system in a dog. *J Vet Emerg Crit Care*. 2009;19(6):623-628.
- McGirt MJ, Leveque J, Wellons JC, Villavicencio AT, Hopkins JS, Fuchs HE. Cerebrospinal fluid shunt survival and aetiology of failures: a seven year institutional experience. *Pediatr Neurosurg*. 2002;36:248-255.
- Kang J. Long-term follow-up shunting therapy. *Childs Nerv Syst*. 1999;15:711-717.
- Kehler U, Langer N, Gliemroth J, et al. Reduction of shunt obstructions by using a peel-away sheath technique? A multicentre prospective randomized trial. *Clin Neurol Neurosurg*. 2012;114(4):381-384.
- Huehmer AF, Biringer RG, Amato H, Fonteh NA, Harrington MG. Protein analysis in human cerebrospinal fluid: physiological aspects, current progress and future challenges. *Dis Markers*. 2006;22:3-26.

32. McGirt MJ, Buck DW, Sciubba D, et al. Adjustable vs set-pressure valves decrease the risk of proximal shunt obstruction in the treatment of pediatric hydrocephalus. *Childs Nerv Syst.* 2007;23:289-295.
33. McClinton D, Carracciao R, Englander R. Predictors of ventriculoperitoneal shunt pathology. *Pediatr Infect Dis J.* 2001;20:593-597.
34. Samuelson S, Long DM, Chou SN. Subdural hematoma as a complication of shunting procedures for normal pressure hydrocephalus. *J Neurosurg.* 1972;37:548-551.
35. Govender ST, Nathoo N, Van Dellen JR. Evaluation of an antibiotic-impregnated shunt system for the treatment of hydrocephalus. *J Neurosurg.* 2003;99(5):831-839.
36. Moussa W, Mohammed M. Efficacy of postoperative antibiotic injection in and around ventriculoperitoneal shunt in reduction of shunt infection: a randomized controlled trial. *Clin Neurol Neurosurg.* 2016; 143:144-149.
37. Boon AJW, Tans JTJ, Delwel EJ, et al. Dutch normal-pressure hydrocephalus study: randomized comparison of low- and medium-pressure shunts. *J Neurosurg.* 1998;88:490-495.
38. Fukuhara T, Vorster SJ, Luciano MG. Critical shunt-induced subdural hematoma treated with combined pressure-programmable valve implantation and endoscopic third ventriculostomy. *Pediatr Neurosurg.* 2000;33: 37-42.
39. Park MK, Kim M, Park KS, Park SH, Hwang JH, Hwang SK. A retrospective analysis of ventriculoperitoneal shunt revision cases of a single institute. *J Korean Neurosurg Soc.* 2015;57(5):359-363.
40. Martinez-Lage J, Poza M. Retrograde migration of the abdominal catheter as a complication of ventriculoperitoneal shunts: the fishhook sign. *Childs Nerv Syst.* 1993;9:425-427.
41. Gupta P, Dev E, Lad S. Total migration of a ventriculo peritoneal shunt into the ventricles. *Br J Neurosurg.* 1999;13:73-74.
42. Scott M, Wycis H, Murtagh F. Observations on ventricular and lumbar subarachnoid peritoneal shunts in hydrocephalus in infants. *J Neurosurg.* 1955;12:165-175.

**How to cite this article:** Gradner G, Kaefinger R, Dupré G. Complications associated with ventriculoperitoneal shunts in dogs and cats with idiopathic hydrocephalus: A systematic review. *J Vet Intern Med.* 2019;33:403-412. <https://doi.org/10.1111/jvim.15422>