



Case report

Treatment of persistent COVID-19 in two B-cell-depleted patients with the monoclonal antibody Sotrovimab

David Totschnig^{a,*}, Daniel Doberer^b, Renate Haberl^c, Christoph Wenisch^a,
Arschang Valipour^b

^a Department of Medicine IV, Klinik Favoriten, Vienna Healthcare Group, Kundratstraße 3, 1100 Vienna, Austria

^b Department of Respiratory and Critical Care Medicine, Klinik Floridsdorf, Vienna Health Care Group, Bruenner Straße 68, 1210 Vienna, Austria

^c Consultant of Infectious Diseases, Klinik Floridsdorf, Bruenner Straße 68, 1210 Vienna, Austria



ARTICLE INFO

Keywords:

SARS-CoV-2
COVID-19
Monoclonal antibody
Sotrovimab
B-cell depletion
Anti-CD20-antibody
Persistent COVID-19

ABSTRACT

Background: Patients having undergone B-cell-depletion with anti-CD20-antibodies have a higher risk of mortality, delayed viral clearance and prolonged infection due to severe acute respiratory syndrome coronavirus 2 (SARS-CoV-2). We report two cases of patients with persistent coronavirus disease 2019 (COVID-19) in association with B-cell-depletion that were treated with the monoclonal antibody Sotrovimab.

Case presentation: Both patients presented with chronic symptoms of COVID-19 such as dyspnea, fatigue, and chest pain. Nasopharyngeal swabs remained positive months after the initial infection with fluctuating cycle threshold (Ct) values around 30. Both patients received a single infusion with the monoclonal SARS-CoV-2 antibody Sotrovimab, which resulted in a rapid improvement of symptoms and inflammation markers as well as negative SARS-CoV-2 swabs. A follow-up after a month showed ongoing improvement of symptoms, persistent negative SARS-CoV-2 swabs, and positive serum antibodies.

Conclusion: Infusion with the monoclonal SARS-CoV-2 antibody led to rapid improvement in two patients with persistent COVID-19 after B-cell depletion.

Introduction

In December 2019, a novel coronavirus, termed SARS-CoV-2, was first described in Wuhan, China [1], causing COVID-19. It has since spread across the world, leading to a global health crisis with over 300 million cases and 5.4 million deaths reported thus far [2].

Iatrogenic B-Cell depletion with anti-CD20-antibodies, such as Rituximab or Obinutuzumab is used to treat hematologic malignancies, especially non-Hodgkin lymphoma [3], and autoimmune diseases such as rheumatoid arthritis and systemic lupus erythematosus [4].

In COVID-19, B-cell depletion has been associated with increased risk for severe disease and mortality [5–10]. Furthermore, delayed viral clearance and prolonged infection has also been described [11,12].

More recently, monoclonal antibodies (mABs) against the SARS-CoV-2 spike protein have been developed as a potent therapeutic option for COVID-19 [13,14]. They are currently indicated for high-risk patients

with mild to moderate COVID-19, but their use for prolonged COVID-19 has not yet been studied. Several case reports have previously reported successful treatment of prolonged SARS-CoV-2 infection with mABs [15–17].

Case presentation

Case 1

At the age of 58 a woman was first diagnosed with follicular lymphoma in 2017. She received systemic chemotherapy with Bendamustine followed by maintenance therapy with Obinutuzumab until July 2020.

She initially tested positive for SARS-CoV-2 in April 2021 after suffering from fever, chest pain, anosmia and ageusia. After 2 weeks of quarantine at home, her condition worsened and she was admitted to the Department of Respiratory and Critical Care Medicine at Klinik

List of abbreviations: SARS-CoV-2, Severe acute respiratory syndrome coronavirus type2; COVID-19, Coronavirus disease 2019; Ct, Cycle threshold; mABs, monoclonal antibodies; PCR, polymerase chain reaction; LTOT, Long term oxygen therapy; CoV-2-S-AB, SARS-CoV-2 S protein antibodies.

* Correspondence to: Kundratstraße 3, 1100 Vienna, Austria.

E-mail address: David.totschnig@gmail.com (D. Totschnig).

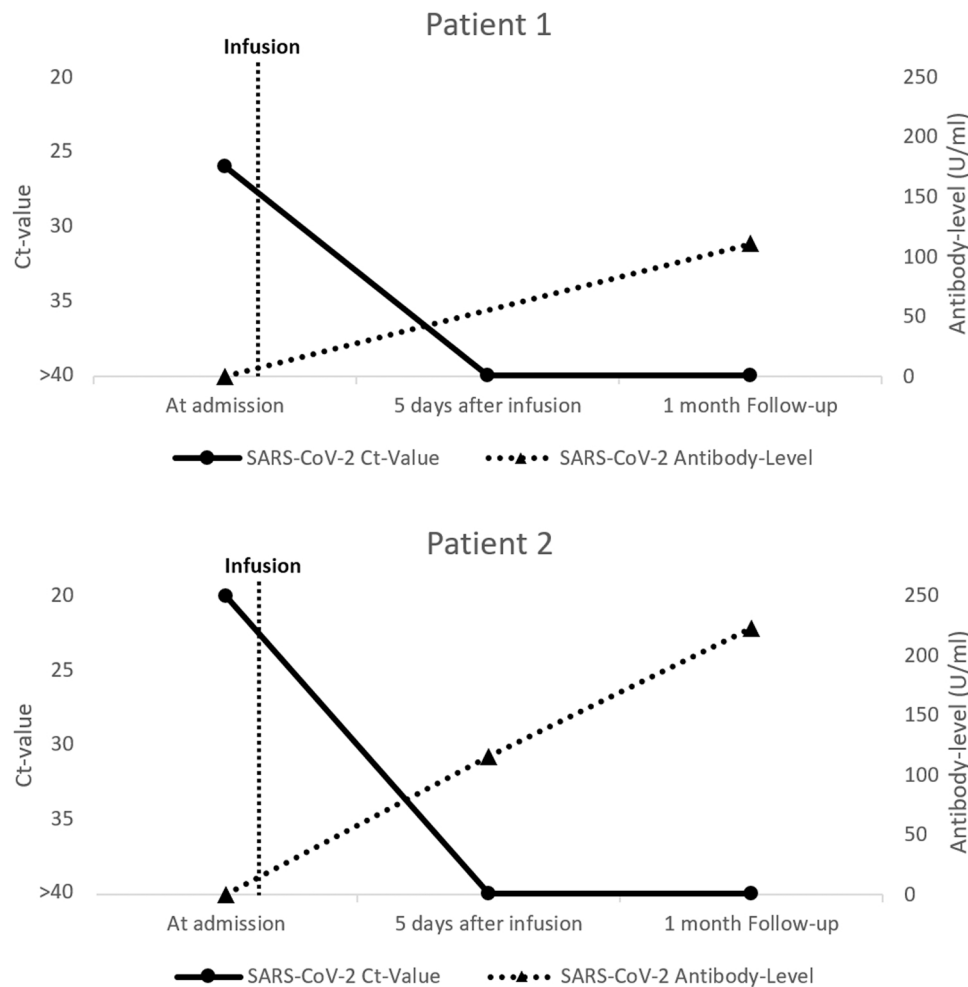
¹ Postal address: Kundratstraße 3, 1100 Vienna.

<https://doi.org/10.1016/j.idcr.2022.e01528>

Received 3 April 2022; Accepted 4 June 2022

Available online 7 June 2022

2214-2509/© 2022 The Authors. Published by Elsevier Ltd. This is an open access article under the CC BY-NC-ND license (<http://creativecommons.org/licenses/by-nc-nd/4.0/>).



Graph 1&2. Changes in SARS-CoV-2 PCR Ct-Value and serum antibody levels of both patients, measured at admission, 5 days after Sotrovimab infusion and at a follow-up 1 month later. Negative SARS-CoV-2 PCRs were represented with a Ct-value of > 40.

Floridsdorf, testing positive for SARS-CoV-2 by polymerase chain reaction (PCR) with a Ct-value of 20. On initial chest-x-ray she demonstrated bilateral infiltrates, consistent with COVID-19 pneumonia. Due to hypoxemia, she received oxygen supplementation with 2 L O₂/min at admission. Her clinical condition improved over the subsequent days and after treatment with dexamethasone and low-flow oxygen supplementation. She was discharged in May 2021 after a total 20 days of hospital stay, still testing positive with a Ct-value of 37 and requiring long term oxygen therapy (LTOT) with 2 L/min. In the following months, she persistently suffered from fatigue, retrosternal pain, chronic cough, and dyspnea, restricting her daily activities. SARS-CoV-2 swabs remained positive (Ct-values around 30).

In September 2021, she was re-admitted due to worsening of her condition. At admission, she presented with chest pain and dyspnea, severe hypoxemia requiring high-flow oxygen therapy, and elevated inflammatory markers. A SARS-CoV-2 swab was positive with a Ct-value of 26, serum SARS-CoV-2 S protein antibodies (CoV-2-S-AB) remained negative, despite prior infection and one vaccination with AZD1222 in March 2021. Computed tomography of the chest revealed extensive ground-glass opacity in both lungs. Flow-cytometry showed a complete depletion of B-cells. She received a singular infusion of 500 mg Sotrovimab. Within 5 days, she no longer required supplementary oxygen, her CRP value dropped from 74 to 4 mg/L, the SARS-CoV-2 swab came back negative and her symptoms markedly improved.

One month after discharge the patient's condition had continued to improve: She was able to walk 8.000 steps, up from 70, and was feeling less fatigued. SARS-CoV-2 tests had remained negative throughout, and

her serum CoV-2-S-Ab levels were 111 U/ml.

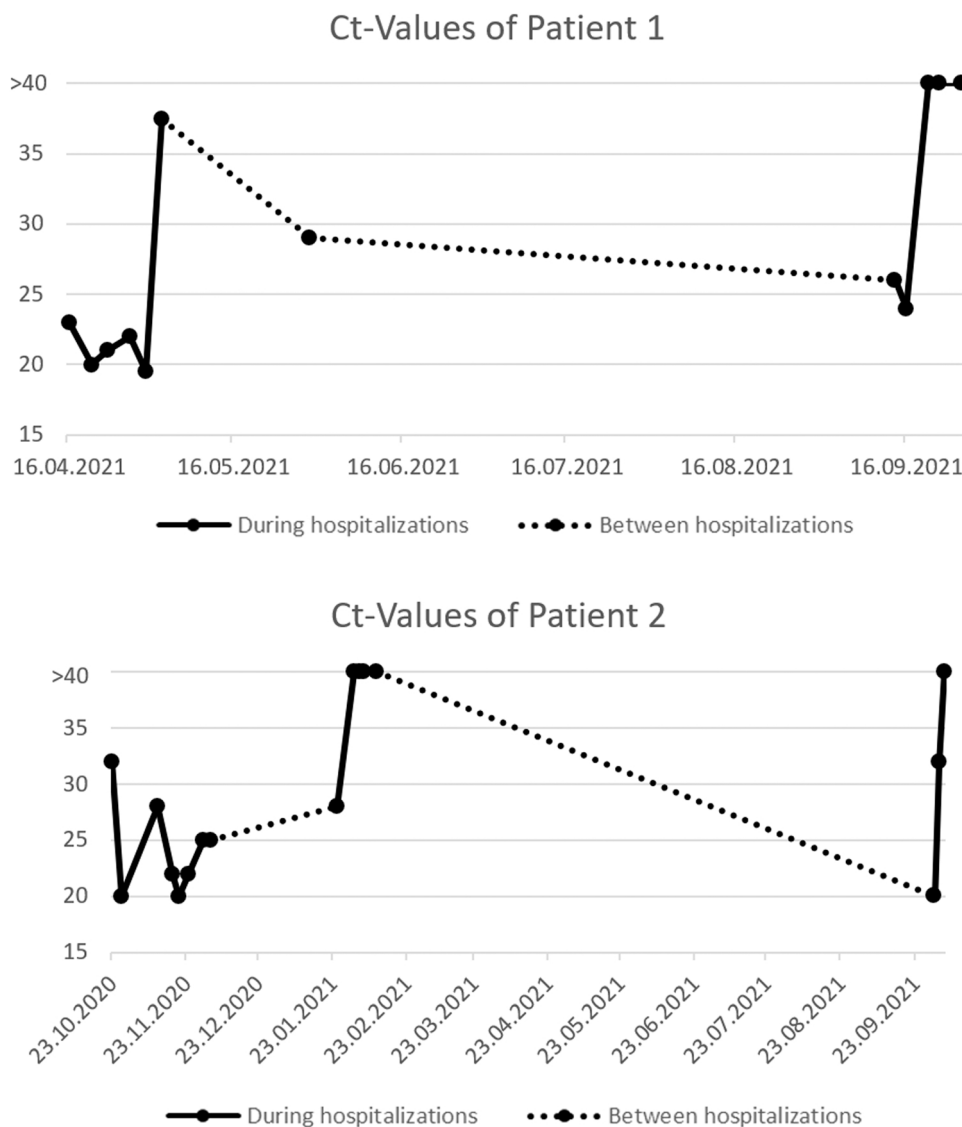
Case 2

A woman at the age of 55 was first diagnosed with follicular lymphoma in January 2017. She received treatment with Bendamustin followed by lifelong maintenance therapy with Obinutuzumab every 2 months.

She initially tested positive for SARS-CoV-2 in October 2020 (presumably wild type) after presenting to the emergency department with dyspnea. Due to rapidly worsening respiratory failure, she was transferred to the ICU and, after one week on non-invasive ventilation, was intubated for 10 days and treated with high-dose dexamethasone (20 mg daily for 5 days followed by tapering). Almost two months after her initial diagnosis she was discharged into quarantine in December 2020, asymptomatic but with evidence of persistent SARS-CoV-2 shedding and a Ct-value of 25.

In January 2021, she was readmitted due to worsening dyspnea, fever and a positive SARS-CoV-2 swab (Mutational analysis: N501 = wild-type). She received treatment with IVIG and dexamethasone, which led to a rapid recovery. Due to suspected secondary organizing pneumonia, a therapy with 25 mg prednisolone daily was established. She was discharged after having tested negative for SARS-CoV-2.

In the following months, she suffered from dyspnea, fatigue and repeatedly tested again positive for SARS-CoV-2. In October 2021, she was admitted for treatment with monoclonal SARS-CoV-2 antibodies. At admission, she continued to test positive for SARS-CoV-2 (variant



Graph 3&4. All recorded SARS-CoV-2 PCR Ct-Values of both patients since their initial infection. Undocumented Ct-values between hospitalizations: Both patients report fluctuating Ct-Values around 30.

B.1.617), with a Ct-value of 20 and negative CoV-2-S-Abs despite previous infection and having received a vaccination with BNT162b2 in September 2021 (Graphs 3 & 4, Table 2). She reported some dyspnea and fatigue but did not require oxygen supplementation. Chest X-ray revealed subtle consolidations in both lungs. Flow-cytometry showed a complete depletion of B-cells. She received 500 mg of Sotrovimab without any complications, and within 4 days, the SARS-CoV-2 swab was negative. Furthermore, the patient reported a reduction of her symptoms.

At a follow-up 1 month later, the patient reported improved symptoms and had repeatedly tested negative for SARS-CoV-2. CoV-2-S-AB levels remained high with 223 U/ml. Chest X-ray showed significant improvement of the previous pulmonary infiltrates.

Discussion

The two presented cases highlight the potential value of mAb-therapies in B-cell-depleted individuals with persistent COVID-19 (Table 1, Graph 1 & 2). Both patients experienced a pronounced improvement in their symptoms as well as objective disease parameters such as inflammatory markers, SARS-CoV-2 swab positivity, and respiratory function. These improvements were ongoing at a follow-up one

month later, and both patients remained seropositive for CoV-2-S-Abs.

There have been several successful attempts to treat prolonged COVID-19, both with convalescent plasma and mAbs. In the largest case series to date, Hueso et al. treated 17 patients with B-cell depletion and prolonged COVID-19 (median of 56 days since symptom onset) with convalescent plasma, resulting in improvement in symptoms and laboratory parameters in 16 out of 17 patients [12]. Similarly, Zimmerli et al. and Jassem et al. both successfully treated two patients with B-cell depletion due to hematologic malignancies with convalescent plasma [18,19]. More recently, several groups have reported successful treatment of such patients with mAbs [15–17, 20].

Differing from these reports, our case series was the first to employ Sotrovimab, and highlights a successful treatment of two especially long cases of COVID-19, with the mAb infusion occurring 150 and 346 days after the first admission to hospital. The main limitations of our study are the incomplete mutational analysis of patient 1 and the lack of documented Ct-values between the patients' hospitalizations.

Concerning the cases presented here, two questions remain unresolved.

Patient 2 was tested positive with two different SARS-CoV-2 variants (in October 2020, presumably, wild-type, and B.1.617 in October 2021). It remains unclear to what degree the infection with a new variant was

Table 1

Tabular view of key facts for both patients presented in this case series.

	Patient 1	Patient 2
Demographic parameters		
Age	61	59
Gender	Female	Female
BMI	31	20
Comorbidities	Follicular Lymphoma, Hypothyroidism	Follicular Lymphoma, Diabetes mellitus type 2, Depression, Hypothyroidism
Smoker	5 pack-years	Ex-Smoker, 12 pack-years
Vaccination status	1x AZD1222 03/2021	1x BNT162b2 in 09/2021
First COVID-19 admission		
Date	16.04.2021	20.10.2020
Respiratory support	Low-flow oxygen	Intubated
Maximum FiO ₂	0,5	0,9
Length of Stay (days)	20	46
Ct-value at admission	20	32
Ct-value at discharge	37	25
Initial Laboratory values		
CRP (mg/L)	80	211
Leukocytes (G./L)	4.8	2.2
Lymphocytes abs. (G./L)	0.2	0.5
D-Dimer (mg/L)	0.6	1.7
Admission for mAb-Infusion		
Date	14.09.2021	01.10.2021
Ct-value	26	20
CRP (mg/L)	74	29
Leukocytes (G./L)	8.6	2.8
Antibody-levels at admission (BAU)	< 0.40	< 0.40
Days between first COVID-19 hospitalization and Sotrovimab Infusion	150	346

Table 2

Tabular view of all recorded Ct-values for both patients including mutational analysis where available.

Patient 1			Patient 2		
Date	Ct-Value	Mutational analysis	Date	Ct-Value	Mutational analysis
16.04.2021	23	B.1.1.7	23.10.2020	32	
20.04.2021	20		27.10.2020	20	
23.04.2021	21		11.11.2020	28	
27.04.2021	22		17.11.2020	22	
30.04.2021	19,5		20.11.2020	20	
03.05.2021	37,5		24.11.2020	22	
30.05.2021	29		30.11.2020	25	
14.09.2021	26		03.12.2020	25	
16.09.2021	24		25.01.2021	28	N501
20.09.2021	> 40		01.02.2021	> 40	
22.09.2021	> 40		03.02.2021	> 40	
26.09.2021	> 40		05.02.2021	> 40	
			10.02.2021	> 40	
			01.10.2021	20	B.1.617
			03.10.2021	32	
			05.10.2021	> 40	

associated with the worsening of her symptoms. Unfortunately, there were no mutational analysis of the SARS-CoV-2 swabs obtained from patient 1 available. Further studies will need to examine the impact of re-infection with new variants in B-cell-depleted patients.

Another important question is the longevity of the SARS-CoV-2 mAbs. The median terminal half-life of Sotrovimab according to the emergency use of authorization fact sheet is estimated at 49 days. Both our patients showed sustained response with persistent seropositivity 1 month after infusion. The long half-life of SARS-CoV-2 mAbs also presents an interesting therapeutic opportunity and these drugs could be used prophylactically in B-cell depleted individuals. These patients have

an increased risk of severe disease and higher mortality due to COVID-19 [5–8]. Moreover, cases of persistent SARS-CoV-2 infection, leading to significant morbidity in the afflicted patients such as presented in this case series, could be prevented.

In conclusion, this case series highlights the potential value of mAb-therapies in B-cell-depleted individuals with persistent COVID-19. Further, multi-center studies to evaluate the potential benefits and harms of therapeutic but also prophylactic treatment with SARS-CoV-2 mAbs, especially in at-risk populations such as B-cell depleted individuals, will be needed.

Funding

This case report received no funding of any kind.

Ethics Approval and Consent to Participate

Not applicable.

Consent for publication

Both patients described in this article have given consent for publication in an academic journal and signed a standardized consent form for case reports.

CRedit authorship contribution statement

David Totschnig wrote the initial manuscript, Arschang Valipour, Renate Haberl and Daniel Doberer improved the manuscript and provided guidance, Arschang Valipour, Daniel Doberer and Christoph Wenisch were involved in the treatment of the patient. All authors have read and approved the manuscript.

Competing interests

The authors declare that they have no known competing financial interests or personal relationships that could have appeared to influence the work reported in this paper.

Availability of data and materials

The data referred to during the current study are available from the corresponding author on reasonable request.

Acknowledgments

Not applicable.

References

- [1] Weston S, Frieman MB. COVID-19: knowns, unknowns, and questions. *mSphere* 2020;5(2):e00203–20.
- [2] COVID-19 Dashboard by the Center for Systems Science and Engineering (CSSE) at Johns Hopkins University (JHU) [Internet]. 2021 [cited 4 July 2021].
- [3] Plosker GL, Figgitt DP. Rituximab: a review of its use in non-Hodgkin's lymphoma and chronic lymphocytic leukaemia. *Drugs* 2003;63(8):803–43.
- [4] Berghen N, Vulsteke JB, Westhovens R, Lenaerts J, De Langhe E. Rituximab in systemic autoimmune rheumatic diseases: indications and practical use. *Acta Clin Belg* 2019;74(4):272–9.
- [5] Strangfeld A, Schäfer M, Gianfrancesco MA, Lawson-Tovey S, Liew JW, Ljung L, et al. Factors associated with COVID-19-related death in people with rheumatic diseases: results from the COVID-19 Global Rheumatology Alliance physician-reported registry. *Ann Rheum Dis* 2021;80(7):930–42.
- [6] Sormani MP, De Rossi N, Schiavetti I, Carmisciano L, Cordioli C, Moiola L, et al. Disease-Modifying Therapies and Coronavirus Disease 2019 Severity in Multiple Sclerosis. *Ann Neurol* 2021;89(4):780–9.
- [7] Duléry R, Lamure S, Delord M, Di Blasi R, Chauchet A, Hueso T, et al. Prolonged in-hospital stay and higher mortality after Covid-19 among patients with non-Hodgkin lymphoma treated with B-cell depleting immunotherapy. *Am J Hematol* 2021;96(8):934–44.

- [8] He W, Chen L, Chen L, Yuan G, Fang Y, Chen W, et al. COVID-19 in persons with haematological cancers. *Leukemia* 2020;34(6):1637–45.
- [9] Calderón-Parra J, Muñoz-Rubio E, Fernández-Cruz A, García Sánchez MC, Maderuelo-González E, López-Dosil M, et al. Incidence, clinical presentation, relapses and outcome of SARS-CoV-2 infection in patients treated with anti-CD20 monoclonal antibodies. *Clin Infect Dis: Publ Infect Dis Soc Am* 2021.
- [10] Loarce-Martos J, García-Fernández A, López-Gutiérrez F, García-García V, Calvo-Sanz L, Del Bosque-Granero I, et al. High rates of severe disease and death due to SARS-CoV-2 infection in rheumatic disease patients treated with rituximab: a descriptive study. *Rheumatol Int* 2020;40(12):2015–21.
- [11] Tepasse PR, Hafezi W, Lutz M, Kühn J, Wilms C, Wiewrodt R, et al. Persisting SARS-CoV-2 viraemia after rituximab therapy: two cases with fatal outcome and a review of the literature. *Br J Haematol* 2020;190(2):185–8.
- [12] Hueso T, Poudoux C, Péré H, Beaumont A-L, Raillon L-A, Ader F, et al. Convalescent plasma therapy for B-cell-depleted patients with protracted COVID-19. *Blood* 2020;136(20):2290–5.
- [13] Weinreich DM, Sivapalasingam S, Norton T, Ali S, Gao H, Bhoore R, et al. REGN-COV2, a Neutralizing Antibody Cocktail, in Outpatients with Covid-19. *N Engl J Med* 2021;384(3):238–51.
- [14] Gupta A., Gonzalez-Rojas Y., Juarez E., Casal MC, Moya J., Faldi DR, et al. Early Covid-19 Treatment With SARS-CoV-2 Neutralizing Antibody Sotrovimab. *medRxiv*, 2021:2021.05.27.21257096.
- [15] D'Abramo A, Vita S, Maffongelli G, Mariano A, Agrati C, Castilletti C, et al. Prolonged and severe SARS-CoV-2 infection in patients under B-cell-depleting drug successfully treated: A tailored approach. *Int J Infect Dis: IJID: Publ Int Soc Infect Dis* 2021;107:247–50.
- [16] Drouin AC, Theberge MW, Liu SY, Smither AR, Flaherty SM, Zeller M, et al. Successful Clearance of 300 Day SARS-CoV-2 Infection in a Subject with B-Cell Depletion Associated Prolonged (B-DEAP) COVID by REGEN-COV Anti-Spike Monoclonal Antibody Cocktail. *Viruses* 2021;13(7).
- [17] Rabascall CX, Lou BX, Navetta-Modrov B, Hahn SS. Effective use of monoclonal antibodies for treatment of persistent COVID-19 infection in a patient on rituximab. *BMJ Case Rep* 2021;14(8).
- [18] Zimmerli A, Monti M, Fenwick C, Eckerle I, Beigelman-Aubry C, Pellaton C, et al. Case report: stepwise anti-inflammatory and anti-SARS-CoV-2 effects following convalescent plasma therapy with full clinical recovery. *Front Immunol* 2021;12: 613502.
- [19] Jassem J, Marek-Trzonkowska NM, Smiatacz T, Arcimowicz Ł, Papak I, Jassem E, et al. Successful Treatment of Persistent SARS-CoV-2 Infection in a B-Cell Depleted Patient with Activated Cytotoxic T and NK Cells: A Case Report. *Int J Mol Sci* 2021; 22(20).
- [20] Daher A, Müller T, Spiesshoefer J, Dreher M, Panse J. Successful treatment of prolonged COVID-19 with Bamlanivimab in a patient with severe B-Cell aplasia due to treatment with an anti-CD20 monoclonal antibody: A case report. *Respir Med Case Rep* 2021;34:101560.