

Case report

Ultrasonography in patients with congenital thenar hypoplasia (Cavanagh syndrome) and co-morbid carpal tunnel syndrome

Vasudeva G. Iyer*

Neurodiagnostic Center of Louisville, 2505 Bush Ridge Drive, Louisville, KY, USA



ARTICLE INFO

Article history:

Received 17 July 2021

Received in revised form 5 September 2021

Accepted 12 September 2021

Available online 13 October 2021

Keywords:

Congenital thenar hypoplasia

Cavanagh syndrome

Carpal tunnel syndrome

Ultrasound

Thenar muscle atrophy

Nerve conduction studies

ABSTRACT

Objective: Patients with congenital thenar hypoplasia (Cavanagh syndrome) may undergo surgical intervention with a mistaken diagnosis of severe carpal tunnel syndrome. Conversely, patients with Cavanagh syndrome can develop co-morbid median nerve entrapment at the carpal tunnel later in life and may go untreated. This study is aimed at evaluating the role of ultrasonography in confirming/ruling out median nerve entrapment at the carpal tunnel in patients with Cavanagh syndrome.

Methods: 6 patients with Cavanagh syndrome were identified during a 10-year period from among patients referred for preoperative electrodiagnostic confirmation of carpal tunnel syndrome. All patients underwent ultrasound imaging as well as electrodiagnostic studies including motor conduction study of the median nerve with recording electrodes over the lumbrical muscles.

Results: Age range of patients was 39–76. The right hand was affected in 5 and left hand in 1 patient. Electrodiagnostic studies (EDX) confirmed carpal tunnel syndrome in 4 of the 6 patients. In one patient the nerve conduction studies were non-diagnostic due to absence of compound muscle action potential (CMAP) over the thenar, and the 2nd lumbrical muscles and absent sensory nerve action potentials (SNAP). Ultrasound images confirmed entrapment of median nerve at the carpal tunnel in all 5 patients. The sixth patient was mistakenly diagnosed with severe carpal tunnel syndrome by the referring physician, based on the thenar atrophy; the median nerve was normal in both ultrasound and electrodiagnostic studies.

Conclusion: Ultrasound was useful for confirming/ruling out comorbid carpal tunnel syndrome in all 6 patients with Cavanagh syndrome.

Significance: Ultrasound complements electrodiagnostic study findings in patients with congenital thenar hypoplasia and comorbid carpal tunnel syndrome. It is even more valuable when EDX findings are non-diagnostic due to absent CMAP and SNAP.

© 2021 International Federation of Clinical Neurophysiology. Published by Elsevier B.V. This is an open access article under the CC BY-NC-ND license (<http://creativecommons.org/licenses/by-nc-nd/4.0/>).

1. Introduction

Patients presenting with isolated thenar muscle atrophy pose diagnostic challenge as the differential diagnoses include severe median nerve entrapment at the carpal tunnel, neurogenic thoracic outlet syndrome, disuse atrophy due to arthritis of the joints of the thumb, and rare conditions like congenital thenar hypoplasia (CTH). CTH can be an isolated defect as in Cavanagh syndrome (Cavanagh et al., 1979) or may be accompanied by cardiac abnormalities (Holt and Oram, 1960) or ocular abnormalities (Okhiro et al., 1977). Absence of radial artery has also been reported in association with CTH (Fernandez et al., 2009). CTH may be unilat-

eral or bilateral. Incidence of CTH is unknown but is considered rare.

Use of high-resolution ultrasonography (HRUS) has been shown to be of significant value in severe distal median nerve neuropathies causing thenar atrophy and loss of compound muscle action potential (CMAP) of the thenar muscles (Iyer, 2019); likewise, it should be of value in CTH to rule out or confirm co-morbid carpal tunnel syndrome (CTS). The goal of this study is to determine the utility of HRUS in diagnosing co-morbid CTS in patients with CTH.

2. Methods

2.1. Patients (Table 1)

Among patients referred during a 10-year period for electrodiagnostic (EDX) confirmation of carpal tunnel syndrome (CTS), we

* Corresponding author at: 2505 Bush Ridge Drive, Suite A, Louisville, KY 40245, USA.

E-mail address: pavaiyer@gmail.com

Table 1
Clinical Findings in 6 patients with congenital thenar hypoplasia.

Patient	Age	Gender	Side	Prior surgery	Symptoms	Signs
1	40	F	R	None	A, B, C, D, E, F	G, H1, H2, H3, J
2	39	F	R	Opponenspalsty by ADM transfer at age 8	B, D, E, F	G, H1, J Opposition and flexion of thumb at MP joint by transferred ADM.
3	57	F	R	None	A, B, C, E, F	G, H1, H2, H3, J Marcus Gunn (Jaw winking)
4	64	M	L	None	A, B, C, E, F	H1, H2, H3, J
5	76	M	R	Opponensplasty by ADM transfer at age 6; unsuccessful revision after 18 years	A, B, C, E, F	G, H1, H2, H3, J
6	41	F	R	None	A, B, C,	G, H1, H2, H3

Symptoms: A: Small thumb; B: Flat thenar area from childhood; C: Weak pinch strength; D: Pain wrist/fingers E: Paresthesia of radial 3 digits F: Nocturnal exacerbation of pain/paresthesia.

Signs: G: Thenar muscle atrophy; H: Thenar muscle strength H1 weak/no abduction H2 weak/no opposition H3 weak/no flexion at the MP joint; J: Decreased pain/light touch sensation over radial 3 digits.

Abbreviations: F: Female; M: Male; R: Right; L: Left; MP: Metacarpal phalangeal joint; ADM: Abductor digiti minimi.

identified 6 patients with a diagnosis of Cavanagh syndrome; the diagnosis was based upon the history of “flat” thenar eminence noticed from birth/early childhood, weakness of pinch grip and hypoplastic thumb. Two of the patients were diagnosed in childhood with CTH and had undergone opponensplasty to provide pinch grip. Referral for EDX by the hand surgeon was prompted by suspicion of severe carpal tunnel syndrome due to the thenar atrophy and new onset paresthesia of fingers in patients 1–5. In patient 6, the presence of thenar atrophy led to the suspicion of severe carpal tunnel syndrome by the hand surgeon, even in the absence of sensory symptoms.

Informed consent was obtained from each patient for scientific publication of their data.

2.2. EDX

The median nerve motor conduction was studied with recording electrodes over the thenar eminence and the 2nd lumbrical and stimulation at the wrist and at the elbow. For the lumbrical study, the active electrode was placed in the palm at the radial side of the 3rd metacarpal and reference electrode over the 2nd metacarpophalangeal joint as per the technique described by Lee et al. (2013). Sensory conduction study was done by antidromic stimulation of the median nerve at the wrist with recording electrodes over the digits (Iyer, 1993).

2.3. HRUS

High resolution ultrasound studies were performed with 12–18 MHz linear array probe and GE LOGIQ E machine; median nerve

cross sectional area (CSA) was measured by trace technique just inside the hyperechoic rim of the nerve at the distal wrist crease (CSAw) as well as mid forearm (CSAf). The echogenicity, vascularity, and mobility of the nerve within the carpal tunnel were also examined. HRUS imaging of thenar area was performed to identify any intact muscle (Fig. 1 shows position of the ultrasound probe).

3. Results

3.1. Clinical data (Table 1)

The patients ranged in age from 39 to 76; there were 4 females and 2 males. Five of the 6 patients showed hypoplastic thumb on the affected side. Patient 3 exhibited Marcus Gunn phenomenon of jaw winking (Pratt et al., 1984); however, there were no additional ocular abnormalities in this patient to suggest the diagnosis of Okhiro syndrome. Patients 2 and 5 had undergone opponensplasty in childhood to provide pinch grip. Patient 6 had thenar atrophy from childhood, but no sensory symptoms.

3.2. EDX & HRUS findings (Table 2)

All the patients showed absent compound muscle action potential (CMAP) over the thenar eminence. Absent or small CMAP over the 2nd lumbrical with prolonged latency and abnormal median nerve sensory nerve action potentials (SNAPs) were seen in patients 1–5. In those 5 patients, HRUS showed increase in CSA of the median nerve at the carpal tunnel inlet and drop in diameter within the carpal tunnel, findings typical of entrapment at the carpal tunnel. Patient 6 showed normal median nerve at the carpal tunnel; HRUS of the thenar area showed absence of muscles (Fig. 1). HRUS image from patient 2 showed muscle tissue superfi-

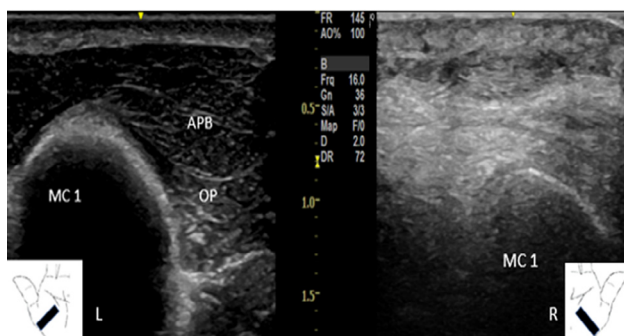


Fig. 1. Ultrasound image of thenar muscles (short axis view) in patient 6: Congenital thenar hypoplasia in the right hand and normal thenar muscles in the left hand. Abbreviations: APB: Abductor pollicis brevis, OP: Opponens pollicis, MC1: 1st Metacarpal bone.

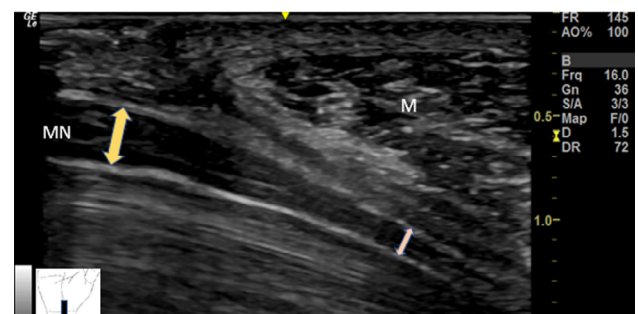


Fig. 2. Long axis view of median nerve (MN) showing drop in diameter within the carpal tunnel in patient 2: The muscle tissue (M) represents the transferred abductor digiti minimi (opponensplasty).

Table 2
EDX and HRUS findings in 6 patients with CTH.

Patient	CMAP Thenar Lat ms/Amp mV (<4.5/ >4.0)	CMAP Lumbrical Lat ms/Amp mV (<4.4/>2.5)	SNAP Digit 1 Lat ms/Amp mV (<3.0/>10)	SNAP Digit 2 Lat ms/Amp uV (<3.5/>25)	SNAP Digit3 Lat ms/Amp uV (<3.5/>25)	Needle EMG MUP: Thenar	US findings CSAw (mm ²) (<13) (CSAw/CSAf) (<1.4)
1	NR	5.1/1.22	NR	NR	NR	NR	25 (4.1) H
2	NR	NR	NR	NR	NR	Y	24 (2.4) H
3	NR	8.7/0.67	NR	NR	NR	NR	15 (2.5) H
4	NR	6.4/0.64	NR	NR	NR	NR	19 (1.6) H
5	NR	8.0/0.14	NR	NR	NR	NR	15 (1.5) H
6	NR	3.2/2.5	2.9/27.9	3.4/48.7	3.2/35.5	NR	9 (1.1)

Columns 2, 3, 4, 5 and 6 represent motor and sensory response to median nerve stimulation at the wrist. Numbers in parenthesis indicate normal values.

Y: Motor units noted on opposition and flexion of thumb, presumably from contraction of the transferred abductor digiti minimi (Opponensplasty).

Abbreviations: CMAP: Compound muscle action potential, SNAP: Sensory nerve action potential, Lat: Latency, Amp: Amplitude, ms: milliseconds, mV: millivolt, uV: microvolt, NR: No response, N: Normal, CSAw: Cross sectional area of median nerve at wrist, CSAf: Cross sectional area of median nerve at mid forearm, H: Hypochoic median nerve at the wrist.

cial to the flexor retinaculum, representing the transferred abductor digiti minimi (ADM) from the opponensplasty (Fig. 2).

4. Discussion

CTH being rare, can be mistaken for thenar atrophy resulting from severe median nerve entrapment at the carpal tunnel; this may lead to unnecessary surgical intervention (Sonel et al., 2002; Parsa et al., 2018; Tas and Top, 2015). On the other hand, patients with CTH may develop carpal tunnel syndrome (CTS) later in life from various causes and it is important to identify and initiate appropriate treatment in those patients. In patients with CTH, the occurrence of sensory symptoms in the median nerve distribution should warrant evaluation for CTS.

Hypoplasia of thenar muscles can potentially cause problems with interpretation of EDX and may lead to erroneous conclusion of severe carpal tunnel syndrome; presence of normal median nerve SNAPs and normal motor conduction to lumbrical should point to CTH. However, diagnosing median nerve entrapment in the presence of CTH can be even more challenging. Due to rarity of CTH, there are no large series of cases discussing the incidence of CTS in CTH. Kumbhare (Kumbhare et al., 2017), reported a case of Cavanagh syndrome with extensive literature survey; all reported cases with Cavanagh syndrome presented with thenar muscle weakness, but mostly without significant pain or paresthesia. They surmised that in Cavanagh syndrome without co-morbid carpal tunnel syndrome, the APB and or OP was absent in more than 80% leading to absent or low amplitude CMAP over the thenar area. When CTS is suspected in cases of CTH, they recommended additional study of median nerve with recording electrode over the lumbrical muscle, which should be normal in Cavanagh syndrome and abnormal in the presence of CTS. All our patients in this series, except for patient 6 showed abnormal median nerve motor and sensory conduction confirming the presence of nerve entrapment at the carpal tunnel, in addition to CTH. Patient 6 did not have symptoms of CTS; referral for EDX was triggered by presence of thenar atrophy and consideration of surgery for carpal tunnel syndrome. EDX was helpful in avoiding unnecessary carpal tunnel release in patient 6.

HRUS substantiated the diagnosis of median nerve entrapment at the carpal tunnel in patients 1–5. The abnormal findings included increase in CSA of the median nerve at the carpal tunnel inlet (CSAw) and abnormal wrist: forearm CSA ratio (CSAw/CSAf). Long axis view showed drop in diameter of the median nerve within the carpal tunnel. The nerve appeared hypochoic at the carpal tunnel inlet in patients 1–5 with decreased mobility within the tunnel. Both EDX studies and ultrasonic imaging were helpful

in ruling out carpal tunnel syndrome in patient 6 and avoid unnecessary surgery. In CTH patients with comorbid severe CTS leading to absence of CMAP over the APB and lumbrical as in patient 2 leading to non-diagnostic EDX, HRUS is an excellent tool to confirm the diagnosis of CTS.

HRUS is also useful in identifying the pattern of thenar muscle hypoplasia, as there is considerable variation regarding which muscle or muscles may be hypoplastic in Cavanagh syndrome (Iyer and Stanley, 1982; Koca et al., 2012; Sahin et al., 2016; Priyadharshini et al., 2019). In this series all thenar muscles were absent in patients 3, 5 and 6; in the other 3, while no APB or OP was present, flexor pollicis brevis (FPB), although small, was detectable. Fig. 2 (Patient 2) shows significant drop in the diameter of the median nerve, at the site where the ADM (transferred during opponensplasty) crosses over the flexor retinaculum; during opposition of thumb, the muscle mass seems to narrow the carpal tunnel even more, suggesting the possibility that it may have a role in causing median nerve entrapment in this patient.

5. Conclusions

In conclusion, US is highly useful in diagnosing comorbid carpal tunnel syndrome in patients with CTH; while it effectively complements the EDX findings, HRUS is even more valuable when EDX is non-diagnostic or in children with CTH, who may not tolerate EDX. HRUS also provides insight into the pattern of thenar muscle hypoplasia in CTH.

Disclosure of funding

None.

Conflict of interest statement

None.

Reference

- Cavanagh, N.P.C., Yates, D.A.H., Sutcliffe, J., 1979. Thenar hypoplasia with associated radiologic abnormalities. *Muscle Nerve* 2, 431–436.
- Fernandez, D., Gupta, S., Fallon, P., 2009. Congenital thenar hypoplasia with absent radial artery—a case report. *Eur. J. Paediatr. Neurol.* 13 (3), 277–279.
- Holt, M., Oram, S., 1960. Familial heart disease with skeletal malformations. *Br. Heart J.* 22 (2), 236–242.
- Iyer, K.M., Stanley, J.K., 1982. Congenital absence of flexor pollicis brevis and abductor pollicis brevis. *Hand* 14, 313–316.
- Iyer, V., 2019. Role of ultrasonography in severe distal median nerve neuropathy. *J. Clin. Neurophysiol.* 36 (4), 312–315.

- Iyer, V.G., 1993. Understanding nerve conduction and electromyographic studies. *Hand Clinics* 9 (2), 273–287.
- Koca, K., Ekinci, S., Ege, T., Ozyurek, S., Kurklu, M., Battal, B., et al., 2012. Bilateral congenital absence of flexor pollicis brevis and abductor pollicis brevis muscles with bilateral thenar atrophy: a case report. *Clin. Med. Insights Arthritis Musculoskelet Disord.* 5, 59–62.
- Kumbhare, D., Mian, N., Singh, D., Rathbone, A.T.L., Agur, A., 2017. Diagnosing carpal tunnel syndrome in Cavanagh syndrome: a literature review and proposed electro physiologic protocol. *J. Pain Manage. Med.* 2 (3), 125–131.
- Lee, H.J., Kwon, H.K., Kim, D.H., Pyun, S.B., 2013. Nerve conduction studies of median motor nerve and median sensory branches according to the severity of carpal tunnel syndrome. *Ann. Rehabil. Med.* 37 (2), 254–262.
- Okiihiro, M.M., Tasaki, T., Nakano, K.K., Bennett, B.K., 1977. Duane syndrome and congenital upper limb anomalies. *Arch. Neurol.* 34, 174–179.
- Parsa, A., Kashani, F.O., Moghaddam, M., Malek, A., Birjandinejad, A., 2018. Abductor digiti minimi opponensplasty for a patient with Cavanagh's syndrome: a case report. *Rev. Clin. Med.* 5 (1), 23–25.
- Pratt, S.G., Beyer, C.K., Johnson, C.C., 1984. The Marcus Gunn phenomenon. A review of 71 cases. *Ophthalmology* 91 (1), 27–30.
- Priyadharshini, N.A., Kumar, V.D., Rajprasath, R., 2019. Unilateral and isolated absence of opponens pollicis and adductor pollicis: Could it be Cavanagh's syndrome? *J. Curr. Res. Sci. Med.* 5 (1), 62–64.
- Sahin, C., Aribal, S., Tekeli, H., Sever, C., 2016. Isolated bilateral absence of abductor pollicis brevis and opponens pollicis muscles: a case report. *Hand Microsurg.* 5, 29–31.
- Sonel, B., Senbil, N., Gurer, Y.K., Evcik, D., 2002. Cavanagh's syndrome (congenital thenar hypoplasia). *J. Child Neurol.* 17 (1), 51–54.
- Tas, S., Top, H., 2015. Bilateral congenital absence of the opponens pollicis muscle: a case report. *Hand (N Y)* 10 (1), 143–146.