

Safety of Incision Placement with Nipple-sparing Mastectomy and Immediate Prepectoral Breast Reconstruction

Michael Holland, MD*
 Adam Wallace, MD*
 Jennifer Viner, NP, MSN*
 Hani Sbitany, MD†
 Merisa Piper, MD*

Background: In nipple-sparing mastectomy, adequate perfusion to the nipple-areolar complex (NAC) during reconstruction is paramount to avoiding unwanted outcomes. Previous studies have suggested that periareolar incisions may result in higher rates of NAC complications. However, studies to date have not specifically investigated this in prepectoral reconstruction. The purpose of this study is to evaluate the impact of incision location on NAC complications in patients undergoing prepectoral breast reconstruction.

Methods: We performed a retrospective review of all patients who underwent immediate two-stage prepectoral breast reconstruction following nipple-sparing mastectomy between 2015 and 2018 at a single institution. We identified two types of incisions utilized: superior periareolar or inframammary fold (IMF). Patient demographics, comorbidities, and surgical details were compared between incision types, as were NAC complications.

Results: A total of 181 consecutive prepectoral breast reconstructions were included for analysis. A superior periareolar incision was used in 113 reconstructions (62%), and an IMF incision was used in 68 reconstructions (38%). There were 33 (18%) total NAC complications in our series. The periareolar incision group had a higher rate of any NAC complication (25% versus 7.4%; $P < 0.01$), as well as a higher rate of nipple necrosis requiring debridement (9.7% versus 1.5%; $P = 0.03$).

Conclusions: In patients undergoing immediate two-stage prepectoral breast reconstruction following nipple-sparing mastectomy, periareolar incisions are associated with an increased risk of NAC complications compared with IMF incisions. For patients who are candidates for either an IMF or periareolar incision, a periareolar incision should be avoided. (*Plast Reconstr Surg Glob Open* 2023; 11:e4736; doi: 10.1097/GOX.0000000000004736; Published online 11 January 2023.)

INTRODUCTION

Breast reconstruction over the past 20 years has involved a continual refinement of older approaches with the introduction of new techniques in an effort to achieve the most natural appearing breast following mastectomy. With the understanding of the oncologic safety of nipple preservation during mastectomy, this option has

become the gold standard for patients when both technically and oncologically feasible.¹⁻⁷ For plastic surgeons, incision placement in nipple-sparing mastectomies is a critical decision that allows for control of the postmastectomy skin envelope and ultimately affects the perfusion of the nipple-areolar complex (NAC). Previous studies have shown varied results of incision location on NAC complications, but tend to suggest that incisions placed away from the areola result in decreased rates of ischemic complications.⁸⁻¹²

Prepectoral breast reconstruction is another technique which, when matched with a nipple-sparing approach, can result in an aesthetically pleasing outcome with high patient satisfaction.^{13,14} Adjuncts, such as fat grafting and

From the *Division of Plastic and Reconstructive Surgery, University of California, San Francisco, San Francisco, Calif.; and †Division of Plastic and Reconstructive Surgery, Mount Sinai Medical Center, New York, N.Y.

Received for publication August 16, 2022; accepted November 3, 2022.

Copyright © 2023 The Authors. Published by Wolters Kluwer Health, Inc. on behalf of The American Society of Plastic Surgeons. This is an open-access article distributed under the terms of the Creative Commons Attribution-Non Commercial-No Derivatives License 4.0 (CCBY-NC-ND), where it is permissible to download and share the work provided it is properly cited. The work cannot be changed in any way or used commercially without permission from the journal.

DOI: 10.1097/GOX.0000000000004736

Disclosure: Dr. Sbitany is a consultant for Allergan, Inc. The other authors have no financial interest to declare.

Related Digital Media are available in the full-text version of the article on www.PRSGlobalOpen.com.

acellular dermal matrix (ADM) use, have been studied with this newer technique and have demonstrated good outcomes.¹⁵⁻¹⁷ However, there have been no comparative or outcome studies specifically analyzing the effect of incision placement on outcomes of the NAC specifically in patients undergoing prepectoral reconstruction. Our goal was to evaluate the effect of the two most common incisions utilized during prepectoral breast reconstruction at our institution to determine whether incision choice had any effect on NAC complications.

PATIENTS AND METHODS

A retrospective chart review of consecutive patients undergoing immediate breast reconstruction with prepectoral tissue expanders following nipple-sparing mastectomy between February 2015 and October 2018 at the University of California, San Francisco Medical Center was performed, with all reconstructions done by a single plastic surgeon (H.S.). Eligibility of nipple preservation during mastectomy was based on accepted oncologic criteria, as well as breast size and degree of nipple ptosis. No preoperative NAC biopsy was required for nipple preservation candidacy; however, all retrorareolar breast tissues were removed in the mastectomy and subsequently analyzed on permanent section. The decision for prepectoral placement of expanders was based on both the preoperative evaluation of skin and subcutaneous tissue quality, and the intraoperative assessment of postmastectomy skin flaps. In our series, both NAC and skin flap viability were assessed based on clinical examination without the use of adjunct assessments, such as indocyanine green angiography. ADM was used in all cases for additional soft tissue support of the expander, as were closed suction drains, which were kept in place until output decreased to less than 30 ml per day for 3 consecutive days. Tissue expanders were filled intraoperatively at the discretion of the surgeon, to fill out the skin envelope to prevent significant wrinkling or creasing of skin from the underlying expander; however, they were never filled to any degree that would place tension on closure or pressure on overlying skin.

We analyzed patients based on the two types of incisions used for both the mastectomy and reconstruction in this study: either a superior periareolar incision, which

Takeaways

Question: Does incision placement in nipple-sparing mastectomy affect nipple-areola-complex and other outcomes in prepectoral breast reconstruction?

Findings: Periareolar incisions were associated with higher rates of nipple-areola-complex necrosis than infra-mammary fold incisions.

Meaning: Patients undergoing immediate prepectoral breast reconstruction after nipple-sparing mastectomy should avoid periareolar incisions when possible.

coursed along the top half of the junction between the areola and breast skin, or an incision overlying the infra-mammary fold (IMF). To compare these cohorts, demographics, medical comorbidities, surgical details, and postoperative outcomes were reviewed and recorded, and were compared between incision types. Our primary endpoint was the development of any NAC necrosis ranging from superficial epidermolysis of the areola to total nipple and areolar necrosis (Figs. 1, 2). Our secondary endpoint was the development of NAC necrosis requiring operative debridement (deemed major necrosis). Patients who healed without operative intervention were classified as minor necrosis. All patients were evaluated both preoperatively and postoperatively by the operative surgeon to determine the presence and severity of clinical endpoints.

Statistical analysis was performed using IBM SPSS v23.0 (Armonk, N.Y.) and included the use of the Fisher exact test for categorical variables and the Mann-Whitney U test for continuous variables. Cases were analyzed on a per reconstructed breast basis rather than per patient basis, which simplifies analysis due to the fact that bilateral reconstructions double the risk of complications. To control for interactions among the predictors of complications that exist in our study beyond incision type, a multivariable binary logistic regression was performed. This was done for the outcome of any nipple necrosis by including all predictor variables in our regression model and performing backward elimination of variables with a significance cutoff of 0.05 and using the likelihood ratio as a goodness of fit statistic until the parsimonious model was achieved. A value of *P* less than 0.05 was used to

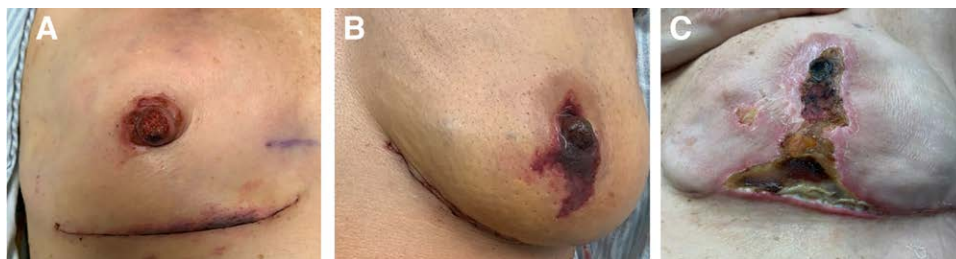

Fig. 1. Examples of varying degrees of NAC and mastectomy flap necrosis in patients with IMF incisions. A, IMF incision with superficial epidermolysis of NAC and marginal epidermolysis of the mastectomy skin flap at IMF. B, IMF incision with partial thickness necrosis of the NAC extending onto inferior mastectomy skin flap. C, IMF incision with full-thickness tissue loss and eschar involving both NAC and large portion of inferior mastectomy skin flap.

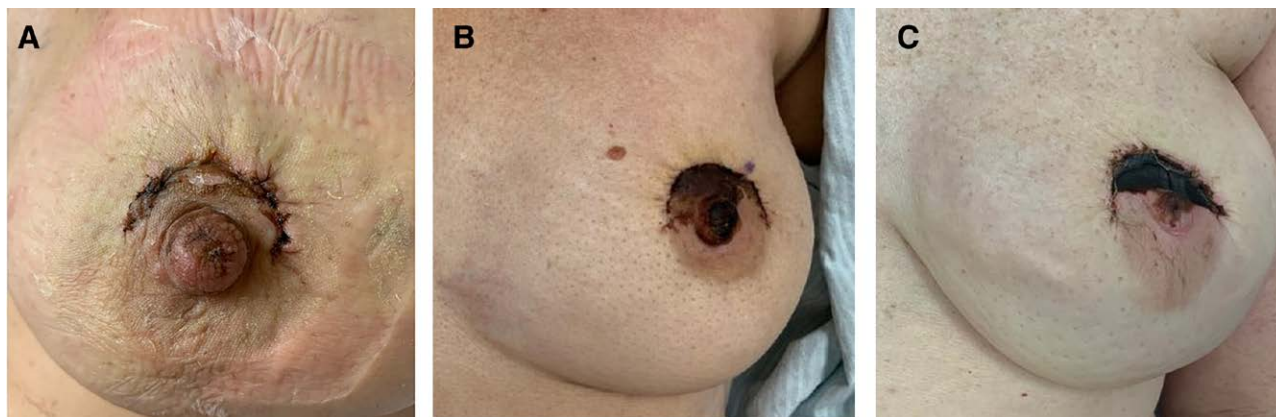


Fig. 2. Examples of varying degrees of NAC and mastectomy flap necrosis in patients with superior periareolar incisions. A, Superior periareolar incision with superficial epidermolysis along the margin of incision and nipple. B, Superior periareolar incision with partial thickness necrosis of top half of areola and majority of nipple. C, Full-thickness necrosis and eschar of top half of areola and partial thickness necrosis of nipple.

determine statistical significance. STROBE guidelines for clinical research were followed throughout the course of the study, and this study was approved by the institutional review board.

RESULTS

A total of 181 consecutive breast reconstructions were included for analysis in 108 patients over the 3-year study period. A superior periareolar incision was utilized in 113 reconstructions (62%), and an IMF incision was utilized in 68 reconstructions (38%). When comparing characteristics of these cohorts, we found that the average age was higher in the periareolar cohort (48.4 years vs 43.7 years; $P = 0.003$). Average body mass index was also higher in this group (24.2 vs 22.8; $P = 0.005$), as was the incidence of hypertension (19% vs 4.4%; $P = 0.006$), and average American Society of Anesthesiologists (ASA) classification (2.0 vs 1.8; $P = 0.025$). On average, patients with IMF incisions had slightly less ptotic breasts than periareolar patients (1.9 vs 2.0; $P = 0.016$). Periareolar patients also had larger sized expanders placed, greater percentage of expanders filled intraoperatively, and larger final fill volume before exchange. The remaining risk factors that were analyzed were similar in both groups, including incidence of diabetes, smoking, prophylactic mastectomy, breast surgeon, size of ADM utilized, days until first clinic expansion, tissue expansion rate, or final fill as percentage of total tissue expander volume, and history of adjuvant oncologic therapies (Table 1).

There were 33 (18%) total NAC complications in this series, which ranged from superficial epidermolysis of the areola to complete NAC necrosis. The periareolar incision cohort had a higher total NAC complication rate when compared with the IMF incision cohort (25% versus 7.4%; $P = 0.003$). The periareolar group also had higher rates of nipple necrosis requiring operative debridement (9.7% versus 1.5%; $P = 0.033$) (Table 2). All NAC necrosis was related to the original surgery and did not occur following initiation of tissue expansion in clinic. There was

no difference in rate of hematoma, seroma, or infection between groups.

The multivariable binary logistic regression performed assessed for the association of age, BMI, presence of diabetes, hypertension, hyperlipidemia, smoking, prior radiation, neoadjuvant chemotherapy, ASA classification, and incision type on the outcome of any nipple necrosis. The parsimonious equation revealed that hypertension (OR, 4.1; $P = 0.004$), smoking (OR, 9.6; $P = 0.029$), and a periareolar incision (OR, 3.6; $P = 0.018$) were the factors independently associated with an increased odds of nipple necrosis. The remaining variables were not significantly associated with nipple necrosis (Table 3).

DISCUSSION

Nipple preservation during a mastectomy and reconstruction in the prepectoral plane have been two major leaps in breast reconstruction to more closely achieve the appearance of a native breast.^{6,7,13,14} The adjuncts of ADM and fat grafting have further contributed to the plastic surgeons ability to recreate a natural appearing breast for patients who have been affected by cancer.¹⁵⁻¹⁷ With a nipple-sparing approach, it is critically important to maintain viability to the NAC, which if disrupted can result in disastrous consequences, including complete loss of the NAC and exposure of the prosthesis.

When considering incision placement in the average patient not requiring significant skin envelope reduction, numerous variations have been described, and the majority can be categorized into three incisional locations: radial, IMF, and periareolar. The latter two can be inconspicuous, hiding the incision at the junction of the native breast and areolar skin or along the IMF, whereas the radial incision can be more visible. Multiple studies over the past decade have examined the complication profile of incision location for nipple-sparing mastectomies. While the individual studies have mixed results relating to NAC complications, the overall sentiment has been that incisions that avoid the NAC tend to result in fewer NAC

Table 1. Patient Demographics and Comorbidities Based on Incision Utilized

Analyzed Characteristics	Inframammary Fold		Periareolar		P
	N/Mean	%/SD	N/Mean	%/SD	
Total breasts (N = 181)	68	37.6	113	63.4	
Total patients (N = 108)	40	37	68	63	
Age (y)	43.7	11.3	48.4	9.3	0.003*
BMI (kg/m ²)	22.8	4.2	24.2	4	0.005*
Diabetes mellitus	0	0	6	5.3	0.085†
Hypertension	3	4.4	21	18.6	0.006†
Hyperlipidemia	2	2.9	8	7.1	0.324†
ASA score (N = 1–5)	1.8	0.4	2	0.5	0.025*
Current smoking	2	2.9	3	2.7	1.000†
Preop Ptosis Grade	1.9	0.4	2.0	0.4	0.016*
History of breast radiation	1	1.5	3	2.7	1.000†
Neoadjuvant chemotherapy	29	42.6	32	28.3	0.053†
Breast surgeon					
Breast surgeon 1	26	38.2	32	28.3	0.365‡
Breast surgeon 2	22	32.2	39	34.5	
Breast surgeon 3	10	14.7	27	23.9	
Breast surgeon 4	10	14.7	15	13.3	
Prophylactic mastectomy	35	51.5	56	49.6	0.878†
Tissue expander size (ml)	423.5	75.5	454.9	64.0	0.002*
% fill in OR	3.3	7.5	17.4	20.6	<0.001*
Days until the first clinic expansion	19.3	9.3	20.8	10.5	0.176*
Total expansion days	44.7	34.7	56.9	83.8	0.898*
Final volume	315.4	159.6	361.7	164.8	0.048*
Final volume %	75.2	33.1	78.9	31.7	0.280*
Alloderm use	68	100	113	100	1.000†
Alloderm size (SqCm)	315.3	27.2	318.0	21.1	0.302*
Drain days	24.4	7.3	26.1	7.7	0.040*

*Mann-Whitney U test.

†Fisher exact test.

‡Pearson chi square.

Table 2. NAC and Other Complications Based on Incision Utilized

Outcome	Inframammary Fold, N = 68		Periareolar, N = 113		OR (95% CI)	P
	N	%	N	%		
Any NAC complication	5	7.4	28	24.8	4.2 (1.5–11.3)	0.003*
Nipple necrosis requiring debridement	1	1.5	11	9.7	7.2 (0.9–57.3)	0.033*
Hematoma	2	2.9	2	1.8	0.6 (0.1–4.3)	0.632*
Seroma	1	1.5	4	3.5	2.5 (0.3–22.5)	0.652*
Any infection	7	10.3	18	16.0	1.7 (0.7–4.2)	0.375*

*Fisher exact test.

Table 3. Multivariable Binary Logistic Regression for Any Nipple Necrosis

Variable	B	SE	Sig	Exp(B)/OR	95% CI of OR
Hypertension	1.4	0.5	0.004	4.1	1.6–10.8
Periareolar incision	1.3	1.0	0.018	3.6	1.2–10.3
Current smoking	2.3	0.5	0.029	9.6	1.3–73.6
Constant	-2.8	0.5	0.000	0.1	—

complications.^{8–12} However, one caveat with this impression is that in several studies, the comparison of incision choice is not binomial, and multiple incision types are contained within one cohort, which makes direct comparison of individual incision choice more difficult. All studies to date have evaluated patients with submuscular or partial submuscular reconstructions, which may limit generalizability to patients undergoing prepectoral reconstruction. After mastectomy, the perfusion to the skin and NAC is based on the extensive subdermal plexus, as all direct cutaneous perforating vessels through the gland have been disrupted.

The presence of the pectoralis muscle intervening between the tissue expander and skin may be favorable, as it has the potential to provide a path for revascularization

of the skin and NAC in patients with borderline skin or nipple ischemia following mastectomy. In prepectoral reconstruction, the implant is placed directly underneath the skin, and typically covered at least on its anterior surface with ADM. This lack of vascularized tissue may affect the viability of the skin or NAC in patients with significant ischemia after mastectomy.

Here, our data suggest that in prepectoral reconstructions, the use of a superior periareolar incision is associated with an increased risk of NAC complications (25% versus 7.4%; $P = 0.003$). We also found that when compared with the IMF incision, the superior periareolar incision was associated with more severe degrees of necrosis, with 9.7% of patients in this cohort requiring operative debridement versus only 1.5% in the IMF cohort. This

suggests two things: the first and most obvious is that the periareolar incision likely contributes to increased ischemia of the NAC. This likely occurs due to the reliance of the subdermal plexus to perfuse the NAC after mastectomy, and utilizing an incision adjacent to the NAC disrupts this plexus in proportion to the size of incision. Additionally, healing an incision requires increased metabolic requirements that may exceed the capacity of the subdermal plexus around the areola after mastectomy. On the other hand, incisions at the IMF are significantly closer to more vascularized tissue, as the limit of the mastectomy typically does not go beyond this border.

Our second finding is that independent of incision choice, most patients with ischemic complications will be able to be managed without operative debridement. In those who developed postoperative ischemia, 39% of patients (11 of 28) with a periareolar incision went on to require debridement, while only 20% of patients (one of five) with an IMF incision required this.

We performed a multivariable logistic regression to control for some of the potential confounding variables present in our study population. Our regression identified hypertension, smoking, and the use of periareolar incisions as significant factors associated with increased odds of nipple necrosis. Prior radiation may also affect NAC perfusion, which supports its inclusion in our initial logistic regression; however, likely due to small prevalence in our series, this had no association with outcomes. This regression supports the notion that incision type may affect outcomes of the NAC, as well as introduces smoking as a modifiable risk factor for unwanted outcomes.

Although we did see larger expanders placed in the periareolar group, this is likely a reflection of both the base width of the chest and size of premastectomy breast, rather than a preference for placing overly large expanders in equally sized breast pockets. This is likely supported by the slightly higher ptosis average in the periareolar group, as well as larger final tissue expander volume, while the ratio of volume to expander size remained equivalent between groups at around 75%–80%. These larger expanders require more intraoperative fill to prevent any substantial wrinkling and creasing of the overlying skin, and were seen in the differences shown in [Table 1](#). However, this discrepancy of fill volume we feel is not a factor that confounds our results because meticulous attention is always paid to ensuring no pressure on the overlying skin flaps or NAC. Additionally, we did not start expanding the groups at different times postoperatively nor have different rates of expansion.

We did not have any differences in rates of prophylactic mastectomy or breast surgeon between groups. Some surgeons feel these two variables may create discrepancies between mastectomy flap thicknesses. However, in our experience, our mastectomy flap thickness is consistent between surgeons at our institution and does not differ in any meaningful way between prophylactic and oncologically performed mastectomies. Additionally, we do not preoperatively biopsy the NAC as a means to determine candidacy for nipple preservation.

Neoadjuvant chemotherapy or preoperative radiation were not statistically different between groups, despite a trend toward higher rates of neoadjuvant chemotherapy in the IMF group. This may suggest more aggressive or significant disease burden in the IMF group; however, this group had more favorable rates of healing of NAC despite this. Adjuvant therapy, including chemotherapy and radiation, was not analyzed as part of this study, as we would not start either of these therapies until any wound healing complications have been resolved.

At our institution, our breast and plastic surgeons have traditionally favored either the IMF or superior periareolar incision. For breasts with more advanced ptosis, the superior periareolar incision allows more central access to the gland for mastectomy and can be designed with a crescent mastopexy to help elevate the NAC position relative to the breast. However, with these results, we have moved away from the superior periareolar incision in patients who would otherwise be candidates for IMF incisions. In patients who would benefit from the superior periareolar approach, typically with grade II ptosis, we have added a lateral extension to minimize traction on the NAC intraoperatively, which may further injure the adjacent subdermal plexus. In grade I or nonptotic patients, we prefer an IMF incision, which can similarly be designed with or without skin reduction. Ultimately, the most important decision for incision placement is based on the ability of the breast surgeon to safely perform their surgery.

In our practice, patients are evaluated at 1 week postoperatively to examine the incisions, evaluate NAC perfusion, and evaluate drain output. Patients who develop any degree of NAC necrosis, ranging from superficial epidermolysis to more significant necrosis, are managed with dry dressings until the NACs have a chance to declare themselves or there is development of an infection, at which point debridement becomes necessary. In patients who develop some degree of necrosis but recover, we find that hypopigmentation or hyperpigmentation can occur but is rare, and we find that those who develop a widened scar can have this excised at the time of implant exchange with excellent results.

Limitations of our study include the retrospective nature and the selection bias associated with incision choice. Typically, incisions are chosen for an anatomic reason rather than surgeon preference. Additionally, there were differences in patient comorbidities between cohorts that may have contributed to negative outcomes that we attempted to control for using regression analysis. Nonetheless, our findings suggest that avoidance of the periareolar incision in prepectoral nipple-sparing mastectomy may help improve NAC outcomes, and we have changed our practice based on this.

CONCLUSIONS

In patients undergoing immediate two-stage prepectoral breast reconstruction following nipple-sparing mastectomy, periareolar incisions may result in an increased risk of NAC complications compared with IMF incisions;

however, our experience suggests that most ischemic complications can be conservatively managed. Future prospective studies may better elucidate this absolute risk. Nonetheless, care should be taken when designing mastectomy incisions to consider this potentially increased complication risk.

Merisa Piper, MD

Division of Plastic and Reconstructive Surgery
UCSF Helen Diller Family Comprehensive Cancer
University of California, San Francisco
505 Parnassus Avenue, M593
San Francisco, CA 94143
E-mail: merisa.piper@ucsf.edu

REFERENCES

1. Spear SL, Hannan CM, Willey SC, et al. Nipple-sparing mastectomy. *Plast Reconstr Surg*. 2009;123:1665–1673.
2. Endara M, Chen D, Verma K, et al. Breast reconstruction following nipple-sparing mastectomy: a systematic review of the literature with pooled analysis. *Plast Reconstr Surg*. 2013;132:1043–1054.
3. Piper M, Peled AW, Foster RD, et al. Total skin-sparing mastectomy: a systematic review of oncologic outcomes and postoperative complications. *Ann Plast Surg*. 2013;70:435–437.
4. Tokin C, Weiss A, Wang-Rodriguez J, et al. Oncologic safety of skin-sparing and nipple-sparing mastectomy: a discussion and review of the literature. *Int J Surg Oncol*. 2012;2012:921821.
5. Adam H, Bygdeson M, De Boniface J. The oncological safety of nipple-sparing mastectomy—a Swedish matched cohort study. *Eur J Surg Oncol*. 2014;40:1209–1215.
6. Mesdag V, Régis C, Tresch E, et al. Nipple sparing mastectomy for breast cancer is associated with high patient satisfaction and safe oncological outcomes. *J Gynecol Obstet Hum Reprod*. 2017;46:637–642.
7. Howard MA, Sisco M, Yao K, et al. Patient satisfaction with nipple-sparing mastectomy: a prospective study of patient reported outcomes using the BREAST-Q. *J Surg Oncol*. 2016;114:416–422.
8. Frey JD, Salibian AA, Levine JP, et al. Incision choices in nipple-sparing mastectomy: a comparative analysis of outcomes and evolution of a clinical algorithm. *Plast Reconstr Surg*. 2018;142:826e–835e.
9. Peled AW, Foster RD, Ligh C, et al. Impact of total skin-sparing mastectomy incision type on reconstructive complications following radiation therapy. *Plast Reconstr Surg*. 2014;134:169–175.
10. Daar DA, Abdou SA, Rosario L, et al. Is there a preferred incision location for nipple-sparing mastectomy? A systematic review and meta-analysis. *Plast Reconstr Surg*. 2019;143:906e–919e.
11. Rawlani V, Fiuk J, Johnson SA, et al. The effect of incision choice on outcomes of nipple-sparing mastectomy reconstruction. *Can J Plast Surg*. 2011;19:129–133.
12. Donovan CA, Harit AP, Chung A, et al. Oncological and surgical outcomes after nipple-sparing mastectomy: do incisions matter? *Ann Surg Oncol*. 2016;23:3226–3231.
13. Storm-dickerson T, Sigalove NM. The breast surgeons' approach to mastectomy and prepectoral breast reconstruction. *Gland Surg*. 2019;8:27–35.
14. DeLong MR, Tandon VJ, Farajzadeh M, et al. Systematic review of the impact of acellular dermal matrix on aesthetics and patient satisfaction in tissue expander-to-implant breast reconstructions. *Plast Reconstr Surg*. 2019;144:967e–974e.
15. Sbitany H. Important considerations for performing prepectoral breast reconstruction. *Plast Reconstr Surg*. 2017;140(6S Prepectoral Breast Reconstruction):7S–13S.
16. Highton L, Johnson R, Kirwan C, et al. Prepectoral implant-based breast reconstruction. *Plast Reconstr Surg Glob Open*. 2017;5:e1488.
17. Manrique OJ, Huang TC, Martinez-Jorge J, et al. Prepectoral two-stage implant-based breast reconstruction with and without acellular dermal matrix: do we see a difference? *Plast Reconstr Surg*. 2020;145:263e–272e.