

Relapsing remitting multiple sclerosis in an Iranian patient with neurofibromatosis type 1

Nafiseh Mohebi, Mehdi Moghaddasi,
Maryam Zaribafian

Department of Neurology, Iran University
of Medical Science, Tehran, Iran

Abstract

Neurofibromatosis type 1 (NF-1) is a common hereditary neuro-cutaneous disease, with known gene mutations, that mainly involves the skin and nervous system. Multiple sclerosis (MS) is an acquired inflammatory disease in which the myelin of nerve cells in the brain and spinal cord is damaged. These two disease do not share any apparent pathological similarities. We herein present a 32-year-old woman with definite NF-1, who has recently been diagnosed with MS, which to the best of our knowledge is a rare co-occurrence. Though there are often neurologic sign and symptoms in patients with NF-1, they should not always be considered as the natural history of the disease, and other overlapped pathologies should be kept in mind, in order to not miss or postpone the efficient treatment.

Introduction

Neurofibromatosis (NF) is actually two separate disease that are clinically and genetically distinct and carry a high risk of tumor formation, particularly in the brain.¹ The neurological sign and symptoms of NF-1 include mild intellectual impairment, epilepsy, macrocephaly, vision loss resulting from visual pathway gliomas, weakness, numbness, bowel/bladder dysfunction due to spinal nerve roots neurofibromas or schwannomas.²⁻⁴

Multiple sclerosis (MS) is the most common inflammatory demyelinating disease of the central nervous system (CNS). The most common sign and symptoms of MS consist of vision loss, sensory disturbances, weakness, bowel/bladder dysfunction, diplopia and ataxia.⁵

Primary progressive multiple sclerosis occurs with increased frequency in NF-1 and relapsing remitting disease has also been reported.⁶⁻⁸ Co-occurrence of MS and NF-1 is therefore rare.⁹

We report a 32-year-old woman with definite NF-1, presenting with upper limb weakness in whom the previous history of self-limited cerebellar attack and neuroimaging findings of

brain and spinal cord are compatible with relapsing remitting MS.

Case Report

A 32-year-old Iranian woman, known case of NF-1, was admitted to Rasoul-Akram Hospital, affiliated to Iran University of Medical Science, with weakness of right arm and distal paresthesia of both hands since the previous week. She did not have lower limbs weakness nor visual or sphincter problem. Her past history was remarkable for a self-limited binocular diplopia with no eye pain, congestion or visual loss and a history of vertigo accompanied with imbalance, five months and two weeks prior to her admission respectively. The past drug history was negative. Her family history was remarkable for her mother and three sisters suffering from NF-1. The physical examination of skin revealed diffuse *cafe-au-lait* spots in variable sizes, axillary freckling and multiple subcutaneous neurofibromas (Figure 1). Her mental state was normal. The motor force of right arm was 4/5 with normal sensation and generalized hyperreflexia was detected. Other neurologic examination including cranial nerves, fundoscopic exam and motor and sensory systems of other limbs were entirely normal. Magnetic resonance imaging (MRI) of the cervical spinal cord, with and without gadolinium (GD), was performed showing an intraxial hypersignal lesion with enhancement (Figure 2). In addition, brain MRI, with and without GD revealed multiple hypersignal lesions in T2-weighted and fluid attenuated

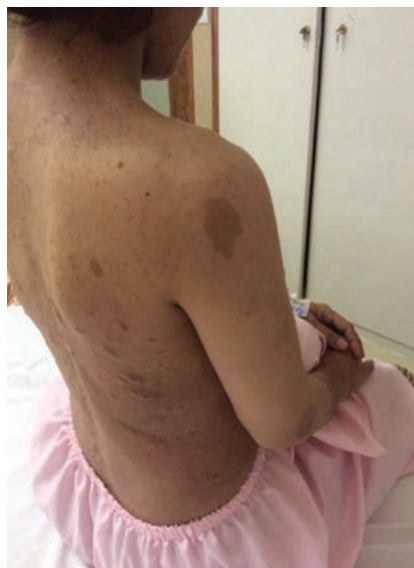

Figure 1. Multiple *cafe-au-lait* spots and cutaneous neurofibroma.

Correspondence: Nafiseh Mohebi, Department of Neurology, Iran University of Medical Science, Hemmat Highway, 1449614535 Tehran, Iran. Tel.: +98.2186709. E-mail: nfs.mohebi@gmail.com

Key words: Multiple sclerosis; neurofibromatosis type 1; relapsing remitting.

Contributions: the authors contributed equally.

Conflict of interest: the authors declare no potential conflict of interest.

Received for publication: 25 April 2015.

Revision received: 5 June 2015.

Accepted for publication: 15 June 2015.

This work is licensed under a Creative Commons Attribution NonCommercial 3.0 License (CC BY-NC 3.0).

©Copyright N. Mohebi et al., 2015
Licensee PAGEPress, Italy
Neurology International 2015; 7:5966
doi:10.4081/ni.2015.5966

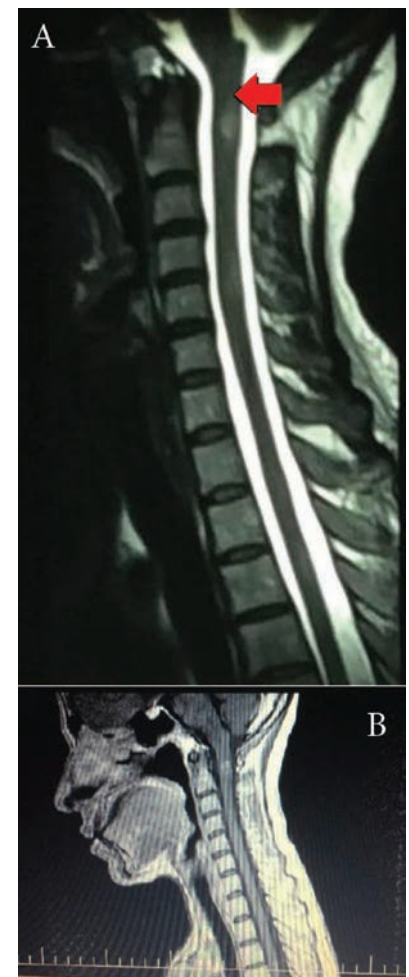


Figure 2. T2/W cervical magnetic resonance imaging showing a hypersignal intramedullary demyelinating plaque (A, red arrow), with enhancement on T1 with gadolinium (B).

inversion recovery (FLAIR) sequences in periventricular and juxtacortical white matter and cerebellum with enhancement (Figure 3), which all were compatible with demyelinating plaques in MS and obviously distinct from non-enhancing unidentified bright objects occasionally seen symmetrically in the basal ganglia, brain stem and cerebellum in NF-1.³ Brain MRI also showed an asymptomatic large extra-axial avidly enhancing lesion at left side of the neck probably an intracranial neurofibroma or schwannoma (Figure 4); however, no biopsy was performed. Infectious etiologies such as varicella zoster virus, herpes simplex virus and cytomegalovirus were tested by polymerase chain reaction (PCR) in cerebrospinal fluid (CSF) and all were negative. Oligoclonal bands (OCB) was positive in CSF and visual evoked potential was normal bilaterally. The patient symptoms improved significantly with methylprednisolone pulse therapy with total dose of 5 grams.

Discussion

The association of MS with NF-1 is unusual and rarely has been reported in literature.^{6,10} Only twenty cases of co-occurrence of NF-1 and MS have been written down so far,^{6-8,11-15} among which seven cases were reported from Iran introduced by Etemadifar *et al.* in 2009.⁹ According to the available data, all clinical forms of MS can be found in patients with NF-1.⁶ In this report we describe a 32-year-old woman with NF-1 presenting with motor symptoms and history of self-limited cerebellar impairment. Typical demyelinating enhancing plaques on brain and cervical cord MRI with positive OCB and excluding other common causes, confirmed the diagnosis of multiple sclerosis. This association is particularly interesting because the gene for oligodendrocyte myelin glycoprotein (*OMgp*), a membrane glycoprotein found in central nervous system dur-

ing myelination, might be one of the possible target antigens of the autoimmune attack in demyelinating diseases and embedded within intron 27b of the NF-1 gene, located on chromosome 17q11.2 and a single mutation in the *OMgp* gene may occur in patients with MS.^{16,17}

Conclusions

Reporting another case of co-occurrence of MS and NF-1, we intended to strengthen the possible causal relationship between MS as an acquired inflammatory demyelinating disease and NF-1 as a hereditary disease, indicating higher risk of MS incidence among patients suffering from NF-1 and not to counting on all new neurologic findings as the natural history of NF-1 involving central or peripheral nervous system, so take a holistic review of patient presenting with a new neurologic complaint.

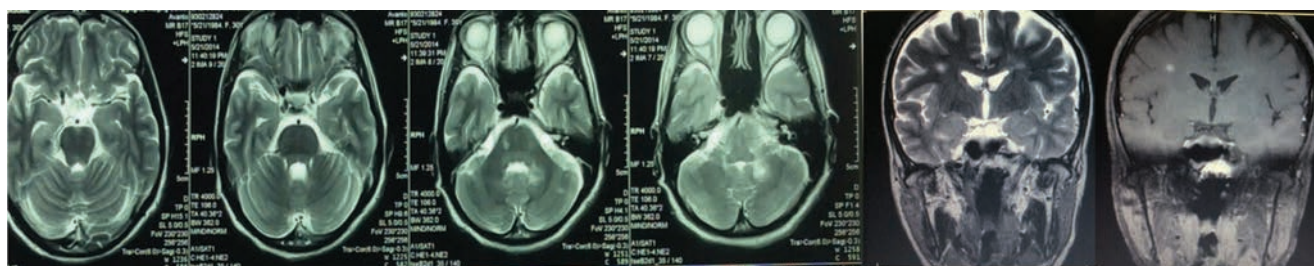


Figure 3. T2/W brain magnetic resonance imaging showing multiple hypersignal plaques in cerebellum, pons and periventricular cerebral white matter (first 5 panels), with enhancing on T1/W sequences with gadolinium (last panel).

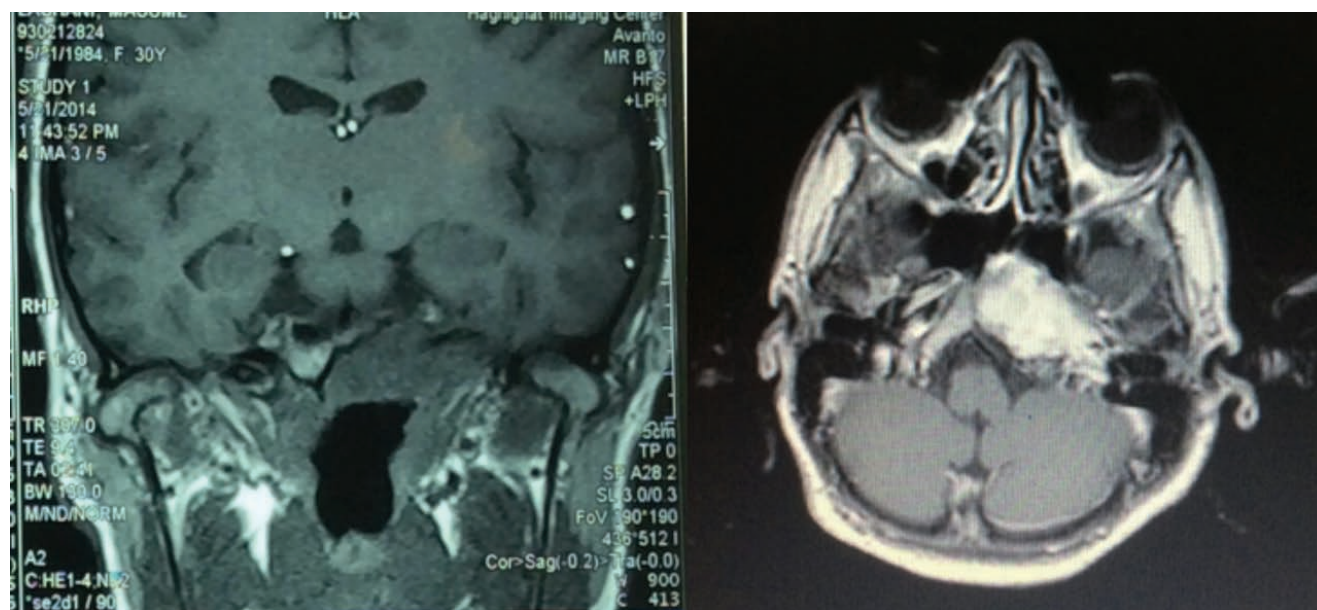


Figure 4. T1/W sequence with and without gadolinium showing an extra-axial lesion at left jugular foramina with avid enhancement.

References

1. Ferner RE, Huson SM, Evans DGR. Neurofibromatoses in clinical practice. London Dordrecht Heidelberg New York: Springer-Verlag; 2011.
2. Ferner RE, Hughes RAC, Weinman J. Intellectual impairment in neurofibromatosis 1. *J Neurol Sci* 1996;138:125-33.
3. Islam MP, Roach ES. Neurocutaneous syndromes. In: Daroff R, Fenichel G, Jankovic J, Mazziotta J, eds. *Bradley's neurology in clinical practice*. Vol 2. 6th ed. Amsterdam: Elsevier; 2012. pp 1515-1519.
4. Creange A, Zeller J, Rostaing-Rigattieri S, et al. Neurological complications of neurofibromatosis in adulthood. *Brain* 1999;122:473-81.
5. Houtchens MK, Lublin FD, Miller AE, Khoury SJ. Multiple sclerosis and other inflammatory demyelination disease of the CNS. In: Daroff R, Fenichel G, Jankovic J, Mazziotta J, eds. *Bradley's neurology in clinical practice*. Vol 2. 6th ed. Amsterdam: Elsevier; 2012. pp 1291-1292.
6. Perini, P, Gallo, P. The range of multiple sclerosis associated with neurofibromatosis type 1. *J Neurol Neurosurg Psychiatry* 2001;71:679-81.
7. Ferner RE, Hughes RA, Johnson MR. Neurofibromatosis 1 and multiple sclerosis. *J Neurol Neurosurg Psychiatry* 1995;58:582-5.
8. Johnson MR, Ferner RE, Bobrow M, Hughes RA. Detailed analysis of the oligodendrocyte myelin glycoprotein gene in four patients with neurofibromatosis 1 and primary progressive multiple sclerosis. *J Neurol Neurosurg Psychiatry* 2000;68:643-6.
9. Etemadifar M, Fatehi F, Sahraian MA, et al. Multiple sclerosis and neurofibromatosis type I: report of seven patients from Iran. *Mult Scler* 2009;15:1126-30.
10. Spinicci G, Valeria Cherchi M, et al., A case of neurofibromatosis and multiple sclerosis. *Neurol Sci* 2010;31:631-4.
11. Feuillet, L, Boudinet, H, Casseron, W, et al. Multiple sclerosis associated with neurofibromatosis type I. *Rev Neurol (Paris)* 2004;160:447-51.
12. Alfonso S, Roquer J, Pou A. Multiple sclerosis and neurofibromatosis 1. *Neurologia* 1996;11:233-5.
13. Masson C, Colombani JM. Neurofibromatosis I and multiple sclerosis. Apropos of a case. *Rev Neurol (Paris)* 1997;153:684-6.
14. Pal E, Gomori EE, Gáti I. Neurofibromatosis and glioblastoma in a case of multiple sclerosis. *Eur J Neurol* 2001;8:717-8.
15. Pipatpajong H, Phanthumchinda K. Neurofibromatosis type I associated multiple sclerosis. *J Med Assoc Thai* 2011;94:505-10.
16. Li Y, O'Connell P, Breindenbach HH, et al. Genomic organization of the neurofibromatosis 1 gene (NF1). *Genomics* 1995;25:9-18.
17. Hinks LJ, Price SE, Mason CR, et al. Single strand conformation analysis of two genes contained in the first intron of the neurofibromatosis type 1 gene in patients with multiple sclerosis. *Neuropathol Appl Neurobiol* 1995;21:201-7.