

MRI cortical feature of bulbar impairment in patients with amyotrophic lateral sclerosis

Graziella Donatelli^{a,b}, Elena Caldarazzo Ienco^c, Mauro Costagli^{a,d,*}, Gianmichele Migaletto^e, Paolo Cecchi^b, Gabriele Siciliano^c, Mirco Cosottini^{b,e}

^a Imago7 Research Foundation, Pisa, Italy

^b Neuroradiology Unit, Azienda Ospedaliero-Universitaria Pisana, Pisa, Italy

^c Neurology Unit, Department of Clinical and Experimental Medicine, University of Pisa, Pisa, Italy

^d Laboratory of Medical Physics and Magnetic Resonance, IRCCS Stella Maris, Pisa, Italy

^e Department of Translational Research and New Technologies in Medicine and Surgery, University of Pisa, Pisa, Italy

A B S T R A C T

The decline of voluntary bulbar functions such as speech and swallowing are among the clinical manifestations of amyotrophic lateral sclerosis (ALS) influencing a worst prognosis. Differential diagnosis between the contribution of upper motor neuron (UMN) and lower motor neuron degeneration to the bulbar impairment is often hard. Thinning and T2* hypointensity of the primary motor cortex have been recently suggested as possible MRI markers of UMN impairment in ALS patients, but little research has purposely targeted the orofacial region of the primary motor cortex (fM1). With the aim of finding an MRI marker of UMN impairment responsible for bulbar dysfunction, we investigated the T2* signal intensity of fM1 and the relationship with bulbar impairment in ALS patients. Fifty-five ALS patients were examined with 3T MRI. Their fM1 was evaluated both qualitatively in terms of T2* signal intensity and quantitatively by measuring its magnetic susceptibility with Quantitative Susceptibility Mapping (QSM). Bulbar functions were assessed clinically, by neurological examination and using the items 1–3 of the ALSFRS-R, and with neurophysiological tests.

The marked hypointensity of fM1 was detected in 25% of ALS patients, including all patients with bulbar onset, and was 74% sensitive, 100% specific and 91% accurate in diagnosing functional bulbar impairment. Such hypointensity involved the middle and ventral part of fM1 and was usually visible in both hemispheres. The magnetic susceptibility was significantly higher in patients with marked fM1 hypointensity than in the other patients ($p \leq .001$).

The relationship with clinical and neurophysiological data suggests that such feature could be a marker of UMN degeneration for voluntary bulbar functions.

1. Introduction

Amyotrophic lateral sclerosis (ALS) is a progressive and disabling neurological disorder with a wide spectrum of clinical phenotypes (Chiò et al., 2011; Kiernan et al., 2011). Pathological hallmarks of the disease include the degeneration of both the upper (UMN) and lower motor neurons (LMN). UMN pathology is reflected by the depopulation of Betz cells in the primary motor cortex (M1) and the axonal loss in the corticospinal tract (Kawamata et al., 1992; Wijesekera and Leigh, 2009), whereas the LMN degeneration is represented by the motor neuron loss in the motor nuclei of the brainstem and in the anterior horns of the spinal cord (Kawamata et al., 1992; Saberi et al., 2015). Differently from the assessment of the LMN degeneration that can be supported by electrophysiological tests (de Carvalho et al., 2008; Eisen and Swash, 2001), the evaluation of the UMN impairment is currently

mainly clinical (Brooks et al., 2000; de Carvalho et al., 2008). Eliciting UMN signs is difficult because of the disruption of the circuits involved in their release and the co-existence of LMN muscle wasting (Swash, 2012). Several neurophysiological and MR techniques have been used to assess signs of UMN degeneration in ALS patients (Huynh et al., 2016), but none of them are currently recommended for diagnosing UMN pathology (de Carvalho et al., 2008; Filippi et al., 2010).

The progressive disruption of bulbar functions reflected in speech and swallowing is a frequent feature in ALS patients, heavily affecting the quality of life and prognosis (Kiernan et al., 2011; Kühnlein et al., 2008; Leigh et al., 2003). The site of disease onset in ALS is an important prognostic indicator: the overall median survival from symptoms onset is lower for bulbar onset cases (2–3 years) with respect to limb onset cases (3–5 years) (Logroscino et al., 2008).

Bulbar impairment related to UMN degeneration reveals with

Abbreviations: ALS, amyotrophic lateral sclerosis; M1, primary motor cortex; fM1, orofacial region of the primary motor cortex; UMN, upper motor neuron; LMN, lower motor neuron; fMRI, functional magnetic resonance imaging

* Corresponding author at: Imago7 Research Foundation, Viale del Tirreno 331, 56128 Pisa, Italy.

E-mail address: mcostagli@imago7.eu (M. Costagli).

<https://doi.org/10.1016/j.nicl.2019.101934>

Received 20 November 2018; Received in revised form 8 July 2019; Accepted 13 July 2019

Available online 15 July 2019

2213-1582/© 2019 Published by Elsevier Inc. This is an open access article under the CC BY-NC-ND license

(<http://creativecommons.org/licenses/by-nc-nd/4.0/>).

spastic dysarthria, tongue spasticity, brisk gag and jaw jerk reflexes, palmomental reflex and pseudobulbar affect, whereas LMN degeneration results in flaccid dysarthria, tongue wasting, weakness and fasciculation (Kiernan et al., 2011; Kühnlein et al., 2008). The detection of signs related to UMN impairment in the bulbar region is anyway challenging (Körner et al., 2011), due to the difficulty to disentangle the selective relative contribution of UMN and LMN degeneration.

Recent MRI studies provided additional information to assess UMN pathology, suggesting the thinning and the T2* hypointensity of M1 as radiological markers of UMN impairment and neuroinflammation in ALS patients (Cosottini et al., 2016; Donatelli et al., 2018; Vázquez-Costa et al., 2018). Here, with the aim of finding an MRI marker of UMN impairment responsible for bulbar dysfunction in ALS patients at the single subject level, we (i) assessed the signal intensity in the orofacial region of M1 (fM1) using a 3D T2*-weighted sequence at 3 T, and (ii) investigated the relationship between fM1 signal intensity and bulbar impairment.

2. Materials and methods

2.1. Patient cohort

We selected all patients with probable or definite diagnosis of ALS (Brooks et al., 2000) clinically assessed in the Neurology Unit of the Pisa University Hospital and who underwent 3 T-MRI examination of the brain between December 2013 and December 2017. Patients with concomitant psychiatric disorders and dementia or whose MR images were heavily affected by artefacts were excluded. By following these criteria, 55 patients were included in this study: 30 males and 25 females, age 62 ± 9 years (mean \pm standard deviation).

Symptoms of bulbar impairment were evaluated at the time of the MRI exam and in clinical follow-up using the items 1–3 of the ALS Functional Rating Scale regarding speech, salivation and swallowing (Cedarbaum et al., 1999) (ALSFRS-R bulbar score, range 0–12, with lower scores reflecting greater disability). Signs of UMN impairment in the bulbar region were clinically evaluated at the time of the MRI exam by eliciting the palmomental reflex and assessing the pseudobulbar affect. Electromyography (EMG) of the tongue, available for 18 patients, and motor evoked potentials obtained by fM1 transcranial magnetic stimulation (TMS), available for two patients who had also EMG, were analysed.

Disease Duration (DD, number of months from the ALS symptoms onset to the MRI exam) and Disease Progression Rate (DPR), defined by the formula $DPR = (48 - ALSFRS-R)/DD$ (Walhout et al., 2015), were calculated. In patients with bulbar impairment at the time of the MRI exam, Bulbar Disease Duration was also computed and defined as the number of months from the bulbar symptom onset to the MRI exam. For patients without bulbar impairment at the time of the MRI exam, data of clinical follow-up were analysed and the possible eventual appearance of bulbar impairment was recorded together with the time lag from the MRI exam.

This study was approved by the local ethical committee; all participants gave their written informed consent.

2.2. Image acquisition, post-processing and assessment

2.2.1. Standard imaging

All MRI exams of patients were performed using a 3 T system (MR750 scanner, GE Healthcare, Chicago, IL) equipped with an 8-channel head coil. The standard MRI protocol included one 3D T1-weighted acquisition (Time of Repetition, TR = 8.2 ms; Time of Echo, TE = 3.2 ms; Inversion Time, TI = 450 ms; Flip Angle, FA = 12 deg.; spatial resolution = $1 \times 1 \times 1 \text{ mm}^3$, scan duration 4'33") and one 3D T2-weighted FLAIR sequence (TR = 7000 ms; TE = 114.9 ms; TI = 1943 ms; FA = 90 deg.; spatial resolution of reconstructed images = $0.5 \times 0.5 \times 0.6 \text{ mm}^3$, scan duration = 5'46").

2.2.2. Qualitative imaging

In all patients, 3D multi-echo T2*-weighted images were acquired, prescribed axially and targeting M1. Acquisition parameters were: TR = 68.3 ms; TE₁: Δ TE:TE₁₀ = 13:5.6:63.7 ms; FA = 15 deg.; spatial resolution of reconstructed images = $0.39 \times 0.39 \times 1 \text{ mm}^3$; scan duration = 4'22".

This set of images was used for radiological assessment based on visual inspection. Two experienced neuroradiologists, blinded to the clinical features of patients, independently evaluated fM1, which was defined on the basis of anatomical and radiological landmarks as the region of M1 located ventrally to the hand knob and functionally connected with the bulbar muscles (Penfield and Boldrey, 1937; Yousry et al., 1997). The right and left fM1 of each subject were analysed separately and along their entirety, and the T2* signal intensity of fM1 was graded after comparison to that of the postcentral cortex according to the following scores: 0, similar signal intensity; 1, mildly hypointense; 2, markedly hypointense (Fig. 1). For target regions where there was disagreement between the neuroradiologists' individual scores, a score reached in consensus was also given. In a following reading session, one neuroradiologist assessed again the whole set of T2*-weighted images to compute the intra-observer agreement.

2.2.3. Quantitative imaging

In 36 out of 55 patients another set of 3D multi-echo T2*-weighted images was acquired with parameters tailored to produce quantitative susceptibility maps (QSM). This sequence was prescribed axially and covered the brain from the vertex to the ponto-bulbar junction. Acquisition parameters were: TR = 68.1 ms; TE₁: Δ TE:TE₁₆ = 13:3.4:64.4 ms; FA = 15 deg.; spatial resolution = $0.94 \times 0.94 \times 1 \text{ mm}^3$; scan duration = 8'44". The magnitude and phase of the complex data underwent a well-established post-processing pipeline (Costagli et al., 2016) that generated an average T2*-weighted 3D image and one quantitative magnetic susceptibility (χ) map for each patient.

The set of χ maps was used to measure the magnetic susceptibility in fM1. One neuroradiologist manually drew ROIs on χ maps, one ROI for each fM1, in the location of the T2* hypointensity (score 1 and 2) or in the deep layers of a putative segment of fM1 if no signal changes were visible (score 0). The mean magnetic susceptibility in each ROI was recorded.

2.2.4. Distribution of T2* hypointensity within the primary motor cortex

The distribution map of T2* hypointensity was superimposed to a map of bulbar motor functions (a) to elucidate the distribution of mild and marked T2* hypointensity (score 1 and 2, respectively) within fM1 and (b) to compare the distribution of marked T2* hypointensity within the motor homunculus between patients with and without bulbar symptoms.

One healthy volunteer underwent a high-resolution fMRI protocol performed with a 7 T scanner (GE MR950) and including 2D Gradient-Recalled Echo (GRE) Echo Planar Imaging (EPI) sequences and a 3D T1-weighted acquisition. The fMRI acquisition consisted in a block-design experiment with task periods of 4 s each alternated to rest periods of 16 s. The subject performed five tasks involved in the voluntary control of motor bulbar functions consisting in lip pursing, vertical excursion of the tongue, vocalisation, swallowing and contraction of masticatory muscles. Four tasks consisting in the movement of the thumb and little finger of both hands were performed to better delineate the motor homunculus. For each task, areas of BOLD activation were superimposed on Montreal Neurological Institute (MNI) 152 standard space (Mazziotta et al., 1995).

The 3D multi-echo T2*-weighted sequences used for visual image analysis were also used to evaluate localisation and distribution of fM1 signal hypointensities. For each patient, one experienced neuroradiologist manually contoured these hypointensities onto the native T2* images by creating a binary mask. (a) In order to elucidate the distribution of mild and marked T2* hypointensity within fM1, the right

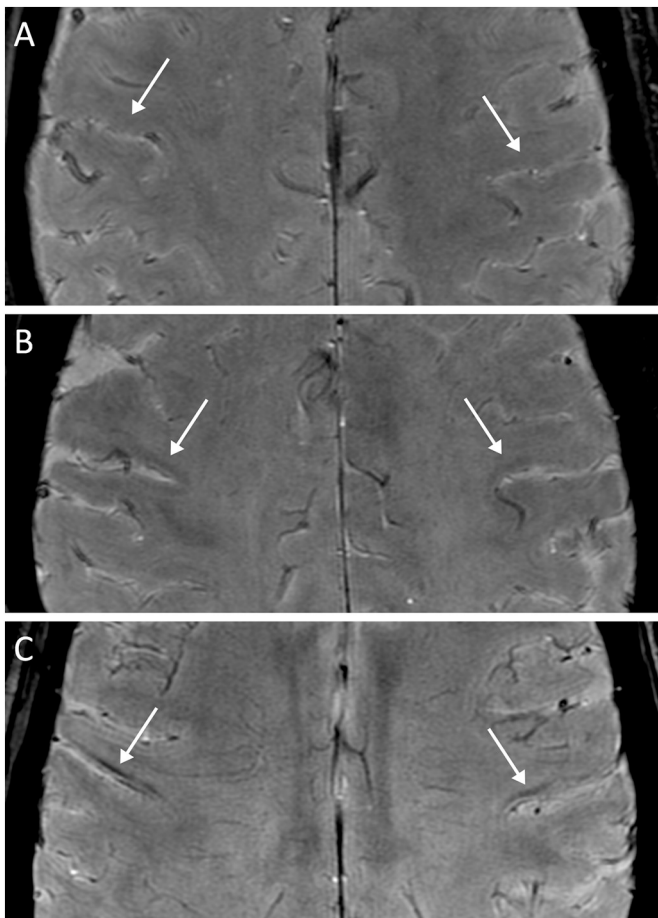


Fig. 1. T2*-weighted images of the primary motor cortex at the level of fM1 (arrows) in three ALS patients. The T2* signal intensity of the deeper layers of fM1 was classified as having score 0 if it was similar to that of the post-central cortex (A), score 1 if it was mildly reduced (B), and score 2 if it was markedly reduced (C).

ALS, amyotrophic lateral sclerosis; fM1, orofacial region of the primary motor cortex.

and left M1 of each subject were segmented and analysed separately. Besides the areas of mild or marked fM1 hypointensity, also the areas of marked T2* hypointensity in M1 subregions outside fM1 were segmented. These masks were grouped for the side and the degree of hypointensity and aligned to the MNI standard space. (b) To compare the distribution of T2* hypointensity within the motor homunculus between patients with and without bulbar symptoms, the areas of marked signal hypointensity were segmented along M1 entirety; the right and left M1 of each subject were analysed together. These masks were grouped based on the presence of bulbar symptoms and aligned to the MNI standard space. In both analyses and for each group, masks were summed to obtain a global localisation of fM1 hypointensities in our patients to be compared with the functional map of bulbar motor tasks obtained in the healthy subject.

Details of the MRI protocol and analysis are reported in online supplementary appendix.

2.3. Statistical analysis

The ALSFRS-R bulbar score was used as gold standard to identify subjects with bulbar functional impairment. For the qualitative analysis, patients who received score 2 in fM1 in at least one hemisphere were considered as having definite signal alterations; all other patients were considered as not having definite signal changes. Sensitivity,

specificity, positive predictive value, negative predictive value and diagnostic accuracy of the MR imaging were computed for each reader and reading session, and for the consensus reading. The inter-observer and intra-observer agreement for the qualitative image analysis were calculated with the Cohen's kappa coefficient.

χ values of fM1 (two measurements for each patient) were grouped based on the corresponding visual score, producing three different groups of data (score 0, 1 and 2). These data were then analysed using a linear mixed model with age and gender as covariates, and subject identifier as grouping factor; *p*-values were computed using ANOVA.

In the subgroup of ALS patients without bulbar symptoms at the time of the MRI exam, the Fisher's exact test was used to investigate the association between the visual scores and the development of bulbar impairment in the follow up time.

3. Results

3.1. Clinical data

Out of 55 patients, 19 had symptoms and 15 had also UMN signs of bulbar impairment at the time of the MRI exam. The ALSFRS-R bulbar score of the whole group of patients was 11 ± 1.7 (mean value \pm standard deviation), whereas the ALSFRS-R bulbar score of the subgroup of 19 patients with bulbar symptoms was 9.2 ± 1.7 .

The time lag between the diagnosis and the MR exam was on average 3 months. Epidemiological and clinical data are summarised in Table 1.

3.2. Imaging data

3.2.1. Qualitative imaging

fM1 was rated as markedly hypointense in 14 out of 55 patients (Fig. 2). All these 14 patients had symptoms of bulbar impairment at the time of the MRI exam (ALSFRS-R bulbar score = 8.7 ± 1.7), and all but one had also UMN signs of bulbar impairment (93%). In 12 of these patients the score was 2 in both right and left side. In one case, the hypointensity affected fM1 bilaterally and was associated with a marked T2 FLAIR hyperintensity confined in the location of both corticobulbar tracts, without signal changes in the other sub-regions of M1 and in the corticospinal tract (Fig. 3).

fM1 was rated as mildly hypointense in 10 patients (score 1); in 7 of these patients the score was 1 in both right and left side (Fig. 2). Only 1 patient of this group had bulbar symptoms (ALSFRS-R bulbar score = 10), and two patients without bulbar symptoms had the palmo-mental reflex or the pseudobulbar affect.

Table 1

Epidemiological and clinical data of ALS patients.

ALS patients	n = 55
Gender (male/female)	n = 30 / 25
Age ^a	62 \pm 9 yrs
Onset	n (%)
Bulbar	11 (20%)
Upper limbs	15 (27%)
Lower limbs	29 (53%)
ALSFRS-R ^a	41 \pm 4.4
ALSFRS-R bulbar score ^a	
In the whole group of ALS patients	11 \pm 1.7
In the sub-group of ALS patients with bulbar symptoms (n = 19)	9.2 \pm 1.7
Patients with bulbar UMN signs	n = 21
Disease duration (months) ^a	13.8 \pm 10.3
Disease progression rate ^a	0.7 \pm 0.7

ALS, amyotrophic lateral sclerosis; ALSFRS-R, ALS Functional Rating Scale Revised; UMN, upper motor neuron.

^a expressed as mean \pm standard deviation.

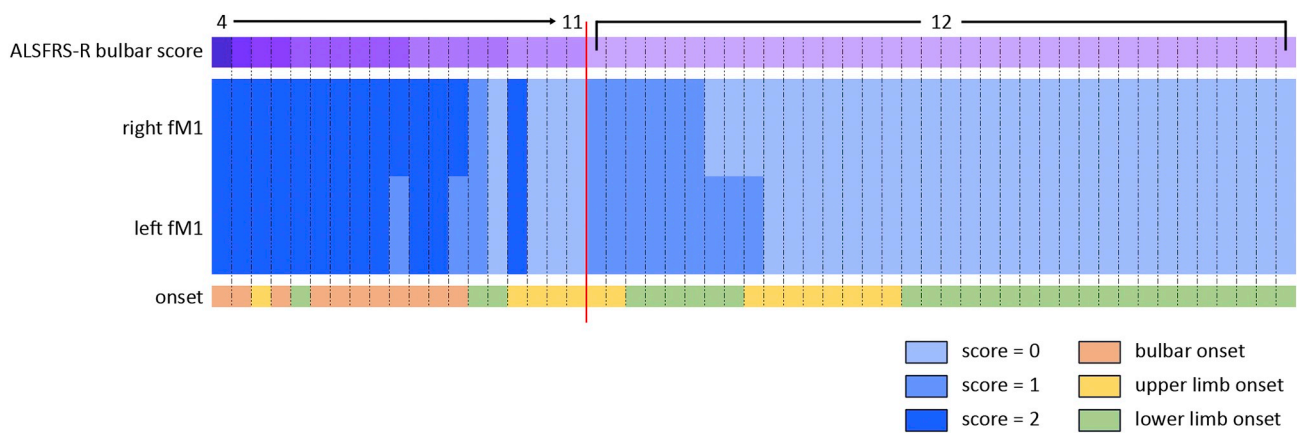


Fig. 2. The heat map represents the hypointensity scores recorded in the consensus reading in the right and left fM1 of every subject. Each column represents data of one patient, sorted on the basis of the ALSFRS-R bulbar score shown on the top of the figure. The red line divides patients with bulbar symptoms at the time of the MRI exam (ALSFRS-R bulbar score < 12, on the left) from patients without bulbar symptoms (on the right).

ALS, amyotrophic lateral sclerosis; fM1, orofacial region of the primary motor cortex.

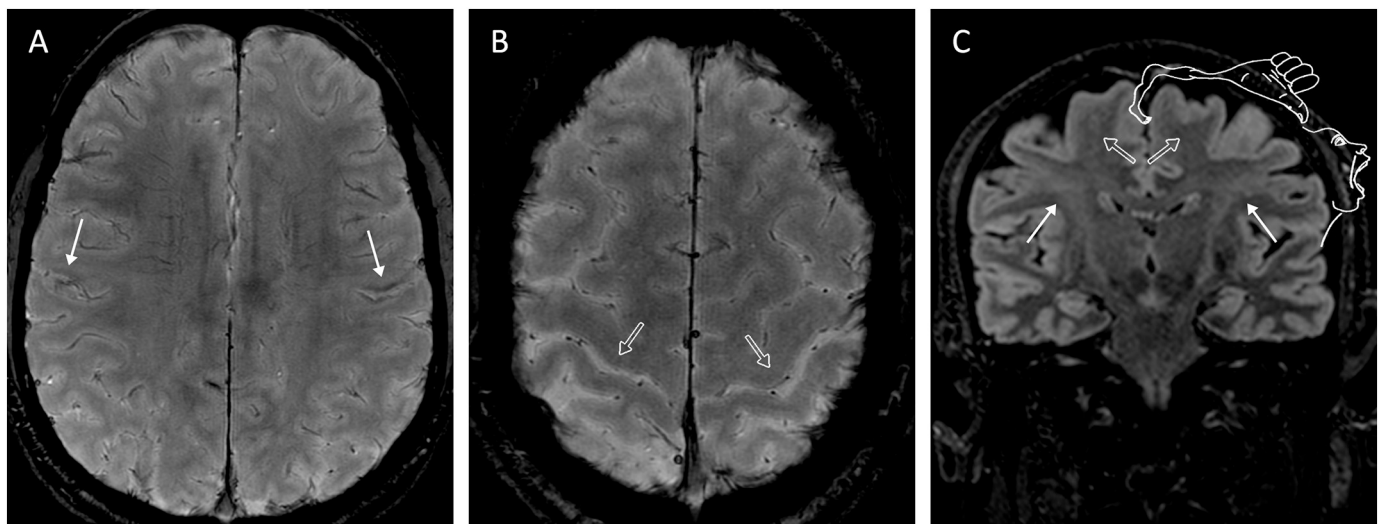


Fig. 3. Axial T2*-weighted images of the primary motor cortex (A and B) and a coronal T2 FLAIR image at the level of the corticospinal tract (C) of an ALS patient with bulbar impairment. In both hemispheres, the deep layers of the orofacial region of the primary motor cortex appear hypointense (A, arrows) and the white matter in the location of the corticobulbar bundle is hyperintense in the T2 FLAIR image (C, arrows). On the contrary, the primary motor cortex corresponding to the functional areas of limbs (B, outlined arrows) are neither thin nor hypointense compared to the post-central cortex and the white matter in the location of the corticospinal tract is not hyperintense (C, outlined arrows). The representation of the motor homunculus in C has been modified from Penfield and Rasmussen, 1950.

In the remaining 31 patients, fM1 received score 0 in both hemispheres (Fig. 2); among them, 4 patients had bulbar symptoms (ALSFRS-R bulbar score ≥ 10) and 6 patients had the palmental reflex or the pseudobulbar affect.

At visual image assessment, sensitivity, specificity, positive predictive value, negative predictive value and diagnostic accuracy of the marked T2* hypointensity in fM1 (score 2) in identifying patients with symptoms of bulbar impairment were respectively 0.74, 1, 1, 0.88 and 0.91 at the consensus reading; all other results are reported in Table 2. The intra-observer and inter-observer agreement were 0.95 and 0.76, respectively.

All patients with bulbar onset had marked fM1 hypointensity.

Among patients with symptoms of bulbar impairment at the time of the MRI exam, those with score 0 or 1 in fM1 had a mean Bulbar Disease Duration of 2 months (range 1–4 months); in patients with marked fM1 hypointensity (score 2), instead, the mean Bulbar Disease Duration was 9 months (range 2–17 months), with 5 patients (36%) having bulbar symptoms since < 6 months.

Table 2

Results of the visual image assessment of ALS patients.

	First reader, first reading session	Second reader	Consensus reading	First reader, second reading session
Sensitivity	0.68	0.63	0.74	0.74
Specificity	1	0.94	1	1
PPV	1	0.86	1	1
NPV	0.86	0.83	0.88	0.88
Diagnostic accuracy	0.89	0.84	0.91	0.91

ALS, amyotrophic lateral sclerosis; PPV, positive predictive value; NPV, negative predictive value.

3.2.2. Quantitative imaging

χ was significantly different among fM1 with different visual scores ($p < .0001$) (Fig. 4); the highest values were observed in the group with score 2 (0.080 ± 0.021 ppm in fM1 with score 2;

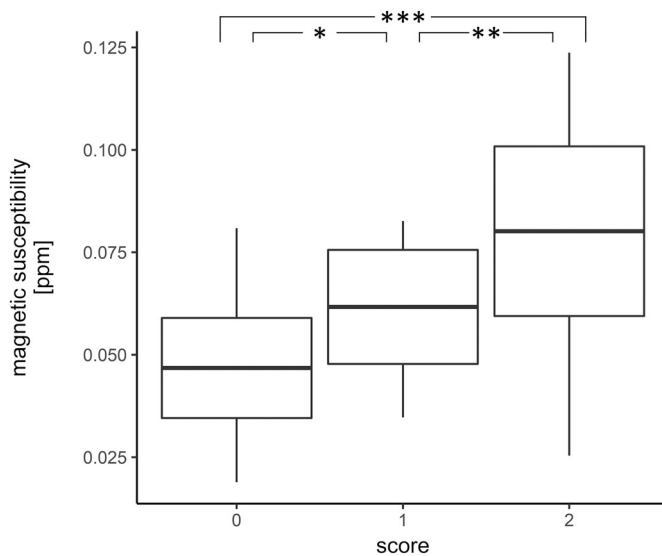


Fig. 4. Boxplot of magnetic susceptibility values recorded in fM1 of ALS patients. Data were grouped on the basis of the corresponding visual score; mean values and standard deviation are represented. * $p = .01$; ** $p = .001$; *** $p < .0001$.

ALS, amyotrophic lateral sclerosis; fM1, orofacial region of the primary motor cortex.

0.062 ± 0.014 ppm in fM1 with score 1; 0.047 ± 0.012 ppm in fM1 with score 0).

3.2.3. Distribution of T2* hypointensity within the primary motor cortex

Twenty-four out of 55 patients had mild or marked hypointensity in fM1 (score 1 and 2, respectively). The localisation of signal changes along fM1 was different in patients with mild hypointensity compared to patients with marked hypointensity. In patients with score 2, the hypointensity was visible as a thin and demarcated stripe which involved the deep layers of fM1 closer to the Sylvian fissure; this region corresponds to the cortical areas functionally related with speech, mastication and swallowing (Fig. 5A and C). On the contrary, in patients with mild fM1 hypointensity, the signal alteration was usually pale and close to the hand knob, without a significant involvement of the more ventral cortical areas related to the main bulbar functions (Fig. 5B and C).

Differently from the group of patients with bulbar symptoms, where the marked T2* hypointensity extensively involved fM1, in patients without bulbar symptoms the marked T2* hypointensity was located in the dorsal part of M1 without extending to fM1 (Fig. 6).

3.3. Neurophysiological findings in ALS patients with marked fM1 hypointensity

In the sub-group of 14 patients with bulbar symptoms and marked fM1 hypointensity, 5 patients had noteworthy neurophysiological data. Two patients underwent both EMG of tongue and TMS of fM1: in one patient they revealed a mild prolongation of the central motor conduction time with no signs of acute or chronic denervation, while in the other patient fasciculation potentials in the genioglossus muscle matched with a slightly abnormal central motor conduction time referred to the left side tongue. In the latter patient, the T2* hypointensity was more pronounced in the right fM1 than in the left one (Fig. 7).

In the other three patients who got only EMG of the tongue, no signs of denervation were recorded.

3.4. Clinical follow-up of ALS patients without bulbar impairment at the time of the MRI examination

Among patients with mild fM1 hypointensity (score 1, $n = 9$), 3 patients (33%) developed symptoms of bulbar impairment at a later time, whereas the remaining patients were still asymptomatic after a mean follow-up of 11 months (range 4–29).

Among patients with normal appearance of fM1 (score 0, $n = 27$), 6 patients (22%) developed bulbar symptoms at a later time, whereas 17 patients were still asymptomatic after a mean follow-up of 13 months (range 1–45). Clinical follow-up data of 4 patients were not available.

Among patients who had developed bulbar symptoms after the MRI exam, the percentage of patients with score 1 did not differ from that of patients with score 0 ($p = .69$).

4. Discussion

This study focused on assessing the T2* hypointensity of the deep layers of fM1 in ALS patients with bulbar impairment and on investigating the meaning of this signal alteration in light of clinical data.

The search for a non-invasive and reliable neuroimaging marker of UMN pathology in ALS patients has received renewed attention in the recent years with the advent of Ultra High Magnetic Field MR. Among MR tools, the T2* hypointensity of M1 has raised interest and has been suggested as a marker of UMN degeneration and neuroinflammation rather than a distinctive feature of all ALS patients (Cosottini et al., 2016; Vázquez-Costa et al., 2018). Such signal alteration occurs in the deeper layers of M1 (Cosottini et al., 2016), likely including the anatomical location of the Betz cells; it corresponds to paramagnetic tissue (Costagli et al., 2016) and co-localises with activated iron-loaded microglia (Kwan et al., 2012); moreover, magnetic susceptibility changes in the cortex correspond to the degree of microglial activation (Pallebage-Gamarallage et al., 2018).

The clinical UMN burden can differ from one body region to another (Körner et al., 2011) and the magnitude of hypointensity along M1 might be not uniform in the same patient (Vázquez-Costa et al., 2018). Because of the significant correlation between clinical UMN impairment of the limbs and T2* hypointensity of the corresponding regions of M1 (Cosottini et al., 2016), the cortical hypointensity can be a tool to assess the UMN degeneration in each region of the motor homunculus. In particular, it could be useful to detect the cortical involvement in orofacial symptoms of ALS patients, a topic that has not been completely elucidated.

Previous pathologic reports in ALS patients with bulbar involvement showed alterations in the motor nuclei of the lower cranial nerves, mainly in the hypoglossal nucleus (Brownell et al., 1970; Lawyer and Netsky, 1953). Besides this evidence of LMN pathology, a few patients suffering from motor neuron disease with bulbar signs and pyramidal tract degeneration but in the absence of motor cells loss in the hypoglossal nuclei were also described (Brownell et al., 1970), supporting the hypothesis that bulbar impairment can be related, at least in part, to UMN pathology.

In this scenario, we showed that in some patients the cortical hypointensity is detectable also in the orofacial region of the motor homunculus and that such radiological sign is related to the bulbar disability caused by UMN pathology. Indeed, the marked fM1 hypointensity (score 2) was located in the region of M1 functionally related with mastication, swallowing and phonation, and it can serve as an UMN sign of bulbar impairment. The T2* hypointensity corresponded to paramagnetic tissue, further supporting the hypothesis of cortical neuroinflammation associated with UMN impairment (Kwan et al., 2012).

In ALS patients, the relationship between the amount of T2* hypointensity or magnetic susceptibility of M1 and the clinical UMN burden of the corresponding body regions has been previously demonstrated for the limb impairment (Cosottini et al., 2015; Costagli

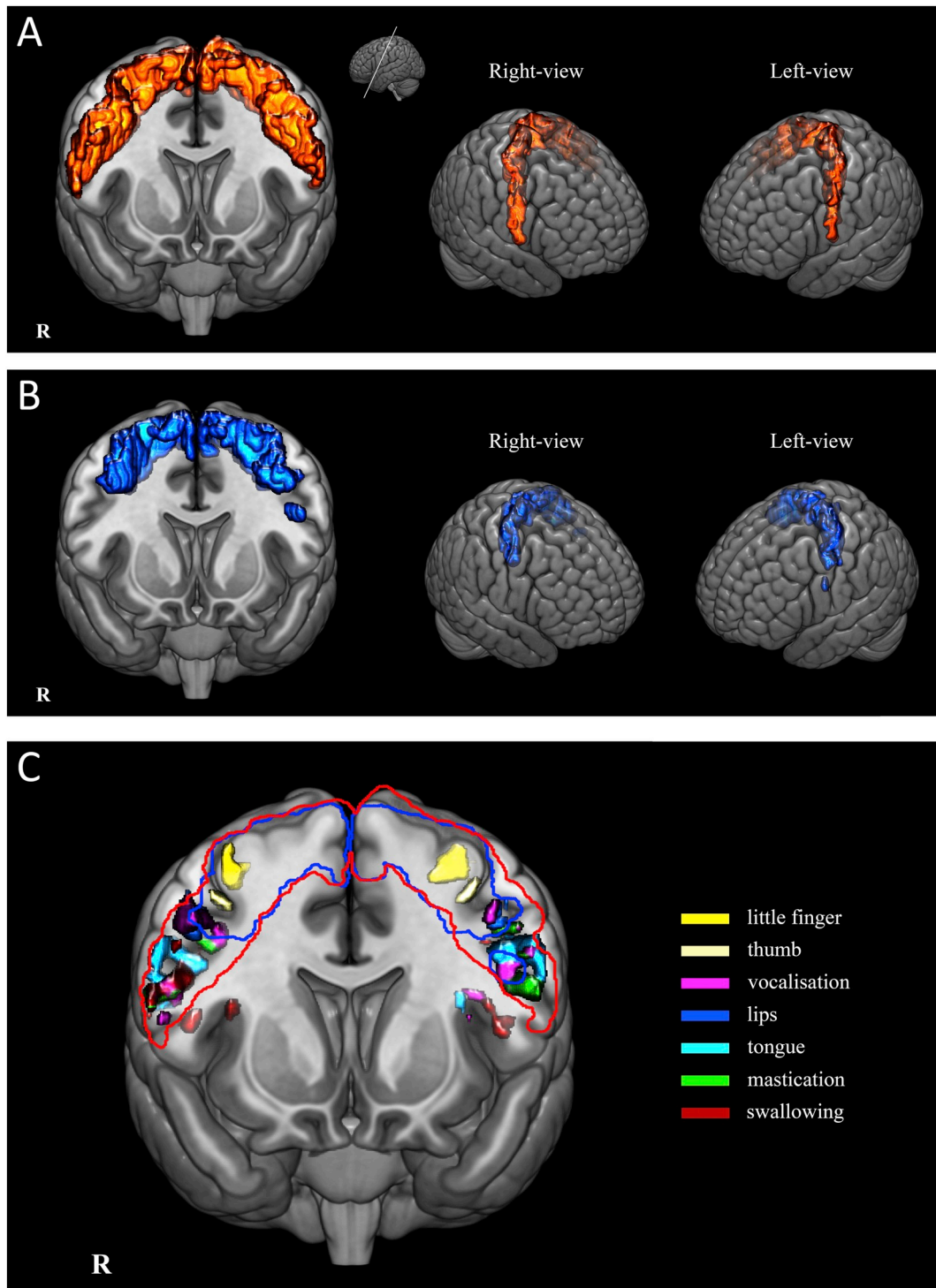


Fig. 5. Localisation of fM1 signal hypointensities of ALS patients on the functional map of bulbar motor tasks. Anatomical localisation of the marked (score 2; A, red) and mild (score 1; B, blue) fM1 hypointensities depicted in oblique coronal images at the level of the precentral gyrus and in three dimensional views. Patients were grouped according to the degree of hypointensity in fM1. In B the most ventral and focal area of mild hypointensity in the left hemisphere refers to two patients: the first had bulbar symptoms and marked hypointensity in the contralateral fM1; the second had unilateral focal area of mild hypointensity without bulbar impairment. Distribution of mild and marked fM1 hypointensities on the functional map of bulbar motor tasks (C). Compared to patients with mild fM1 hypointensity, in patients with marked hypointensity the signal change extended more ventrally, approaching the Sylvian fissure, and involved the region of the primary motor cortex corresponding to the functional areas of speech, mastication and swallowing. Using selective motor tasks, different areas of activation were revealed along fM1 which reflect the somatotopy described by [Penfield and Boldrey, 1937](#). In the dorsoventral direction, the functional motor area of the hand is followed by those of lips, tongue, vocalisation, masticatory muscles and swallowing. (For interpretation of the references to color in this figure legend, the reader is referred to the web version of this article.)

ALS, amyotrophic lateral sclerosis; fM1, orofacial region of the primary motor cortex.

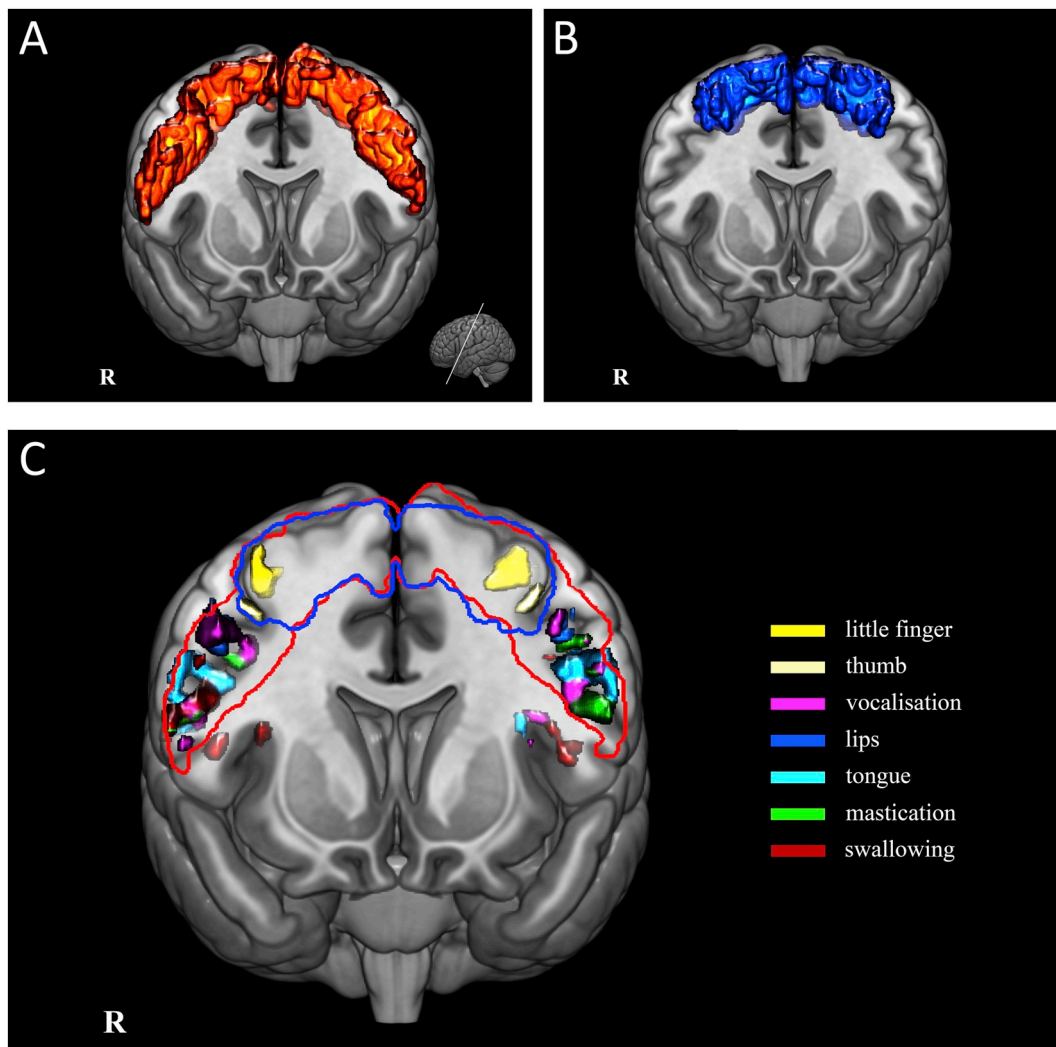


Fig. 6. Distribution of the marked T2* hypointensity of M1 in patients with and without bulbar symptoms (panels A and B, respectively), and map of bulbar functions (C). In the group of patients with bulbar symptoms (A) the marked T2* hypointensity extensively involved M1, including the most ventral part of fM1 that is the brain region in charge of the main bulbar motor functions (C). On the contrary, in patients without bulbar symptoms (B) the marked T2* hypointensity did not extend to fM1 and was visible only in the dorsal part of M1, which represents the voluntary muscles of the limbs. The red and blue outlines in C indicate the extent of marked T2* hypointensity in patients with and without bulbar symptoms, respectively. (For interpretation of the references to color in this figure legend, the reader is referred to the web version of this article.)

et al., 2016) but has never been explored for the bulbar dysfunction. The organisation of fM1 and the detection of signs and symptoms of UMN impairment in the bulbar region have some peculiarities that make this investigation very hard. Indeed, although the ALSFRS-R score does not clearly distinguish the individual contribution of the two motor neuron compartments to symptoms, it probably reflects largely the functional impairment related to LMN rather than UMN degeneration (Bede and Hardiman, 2014; Sorarù et al., 2010). Moreover, the cortical representation of voluntary bulbar motor functions is located in fM1 of both hemispheres even though with a contralateral prevalence (Cattaneo and Pavesi, 2014), and the identification of the side affected or more affected based on clinical signs or symptoms is very challenging.

Among patients with mild fM1 hypointensity (score 1), in only two cases the signal change was visible along fM1 more ventrally than usual. The first patient had bulbar symptoms and marked hypointensity on the contralateral fM1. The second patient, instead, had a focal and unilateral mild hypointensity without symptoms of bulbar impairment; this patient still did not present bulbar symptoms after 6 months follow-up, and the further clinical follow-up might provide additional information to speculate about a prognostic role of this radiological sign

in anticipating the clinical bulbar impairment.

From a clinical standpoint, signs related to LMN impairment of orofacial muscles are more frequently reported than those suggestive of UMN dysfunction (Körner et al., 2011; Zoccolella et al., 2006) also in patients with bulbar onset (Körner et al., 2011). With our method, we recorded a high incidence (74%) of cortical signal changes suggestive of UMN degeneration in patients with bulbar symptoms, thus supposing an underestimation of the reported data probably because of the difficulty in detecting bulbar UMN signs in the clinical examination (Körner et al., 2011).

Besides patients with clinical, neurophysiological and MRI data suggestive of bulbar dysfunction related to UMN degeneration, in our cohort there were also (i) patients with bulbar symptoms in the absence of marked fM1 hypointensity, and (ii) patients with a mild and pale fM1 hypointensity who had no symptoms of bulbar impairment. Some considerations can help in interpreting these results.

- (i) As mentioned above, the ALSFRS-R assesses the functional impairment and is likely affected by LMN dysfunction (Bede and Hardiman, 2014; Sorarù et al., 2010). Therefore, in some cases, the bulbar impairment revealed with the ALSFRS-R can be mainly

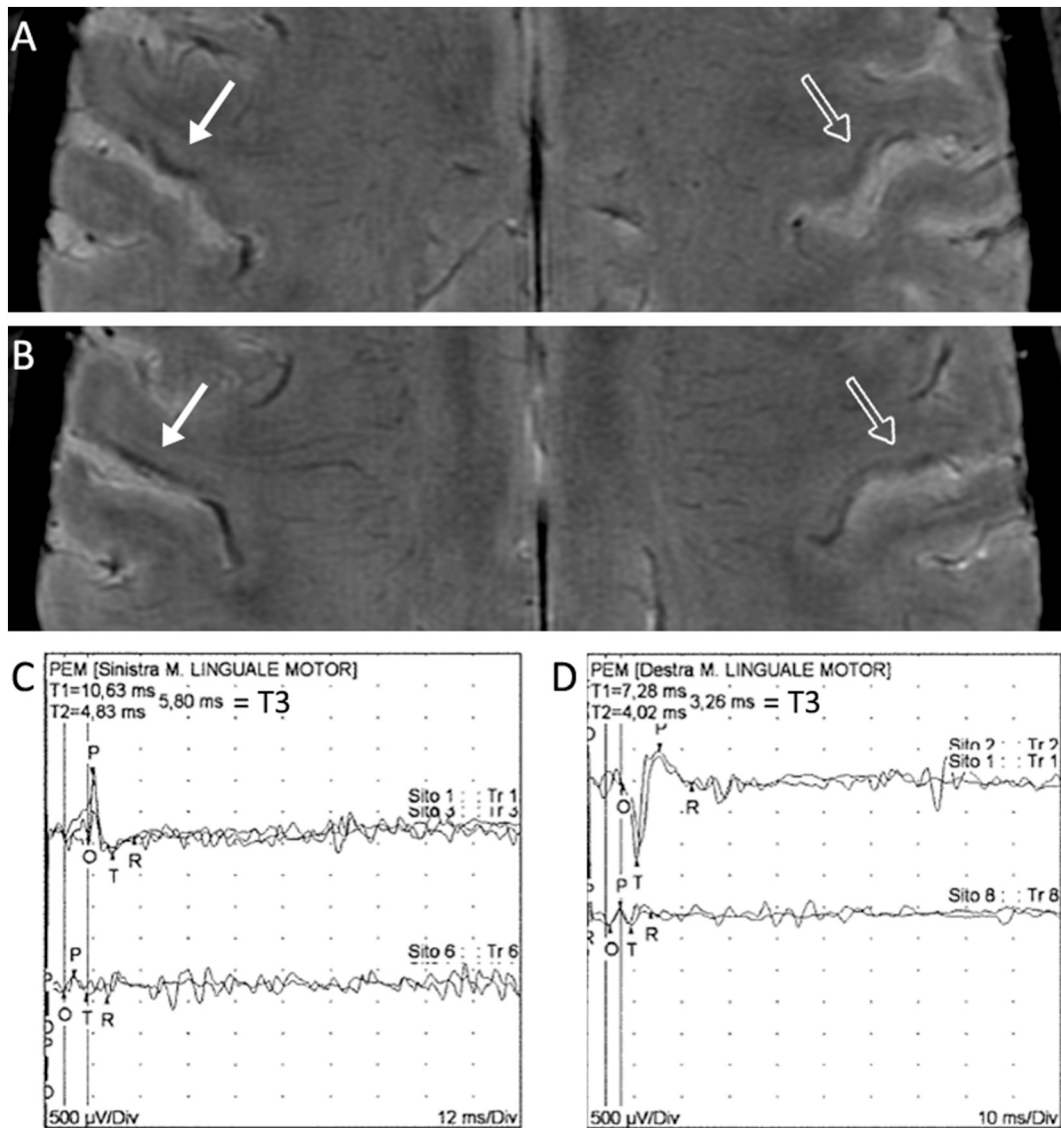


Fig. 7. Example of one ALS patient with bulbar impairment. In A and B, T2*-weighted images showed an asymmetry in the degree of hypointensity, being more marked in the right fM1 (arrow) than in the left fM1 (outlined arrow). Motor evoked potentials from tongue muscles (C: left, D: right). The coil was placed over the contralateral hemisphere, 4 cm from the vertex, and then at the mandible jaw to record respectively the total motor conduction time (TMCT = T1) and the direct peripheral motor conduction time (PMCT = T2). For each patient, the recording has been performed consecutively from both right and left tongue muscles by stimulating the contralateral motor cortex. Central motor conduction time (CMCT = T3) was then calculated by subtracting latencies obtained after nerve root stimulation from those after central stimulation (T3 = TMCT - PMCT). Increased TMCT and CMCT were recorded from left tongue muscle, reflecting the impairment of corticomotoneuronal connections.

ALS, amyotrophic lateral sclerosis; fM1, orofacial region of the primary motor cortex.

related to LMN pathology. Another issue is that MRI might not be able to detect the UMN pathology underlying light clinical impairment (Donatelli et al., 2018) and oncoming symptoms. In our study, indeed, patients with bulbar symptoms and mild or no T2* hypointensity had shorter Bulbar Disease Duration and greater ALSFRS-R bulbar score than patients with bulbar symptoms and marked T2* hypointensity in fM1. Moreover, the presence of the palmomental reflex or the pseudobulbar affect in 2 patients with bulbar symptoms and without marked fM1 hypointensity might further support the latter hypothesis, even though the ratio of patients with these features is similar to the reported prevalence of the palmomental reflex in the healthy population (Schott and Rossor, 2016).

(ii) In our cohort of patients, the marked hypointensity was present only in patients with bulbar symptoms, whereas the mild hypointensity in the most dorsal part of fM1 was usually visible in

patients without bulbar disability. Therefore, we suppose that the mild hypointensity is a physiological appearance of fM1 in some patients rather than a radiological sign of UMN degeneration. However, other interpretations cannot be definitely ruled out. (a) The items 1–3 of the ALSFRS-R investigate complex bulbar functions whose effectors are functionally located in the middle and ventral part of fM1; patients with marked fM1 hypointensity exhibited MR signal change specifically in this region. On the contrary, the mild hypointensity is usually pale, focal and located in the dorsal segment of fM1, where the functional representation of mimic muscles of the upper face is expected, with a negligible involvement of the brain region in charge of the main bulbar motor functions; therefore, the mild hypointensity might be related to UMN dysfunction of mimic muscle. (b) Alternatively, since UMN pathology and dysfunction have been reported also in patients without clinical evidence of UMN impairment or some months

before symptoms onset (Tsuchiya et al., 2002; Urban et al., 1998; Vucic et al., 2008), the mild hypointensity might be a pre-symptomatic marker of UMN-related bulbar impairment. The presence of the palmental reflex or the pseudobulbar affect in two patients with mild fM1 hypointensity who had not bulbar symptoms might support the latter hypothesis; however, the small number of patients does not allow to draw conclusions.

In our patient group, other two situations deserve to be discussed. First, 4 patients with a normal radiological appearance of fM1 and without bulbar symptoms had palmental reflex, which reflects the involvement of corticobulbar fibres. A recent work showed that this reflex is associated and possibly predictive of UMN signs in bulbar region (Arwas et al., 2018), however other studies observed that it is not specific for UMN dysfunction in ALS, as it was reported in many and diverse conditions including Alzheimer's disease, cerebrovascular disease, Down's syndrome, mass lesions and hydrocephalus (Schott and Rossor, 2016). The absence of bulbar symptoms and the lack of specificity of that reflex did not allow to recognise these cases as radiological misdiagnosis. Second, one patient with marked and bilateral fM1 hypointensity who reported slight bulbar symptoms did not show UMN signs of bulbar impairment. This situation represents the classical case where MRI could provide useful information in assessing the bulbar UMN burden in ALS patients.

Only a few MRI studies investigated the fM1 appearance in ALS patients. Using voxel-based morphometry or cortical thickness measures, some authors showed bilateral fM1 atrophy in patients with bulbar onset (Bede et al., 2013; Schuster et al., 2013) and bulbar UMN signs (Schuster et al., 2013), and association between fM1 atrophy and ALSFRS-R bulbar score (Bede et al., 2013; Walhout et al., 2015). Differently from these studies, we investigated a simple radiological sign, namely the T2* hypointensity of M1, which is easily and rapidly assessable at the single subject level using 3 T-MR systems, therefore readily implementable in the clinical routine. Based on our results, we propose this sign as an imaging marker of UMN degeneration also for bulbar motor functions. Therefore, because of its high sensitivity in detecting cortical hypointensity (Adachi et al., 2015; Cosottini et al., 2016), 3D multi-echo T2*-weighted sequences could become a useful tool to support the clinical evaluation of ALS patients and detect UMN contribution to bulbar symptoms; moreover, this sign might contribute to diagnose the ALS bulbar phenotype, with a possible prognostic value (Chiò et al., 2011).

The main limitation of this study is the use of ALSFRS-R as gold standard for assessing bulbar impairment in lack of extensive neurophysiological data and clinical signs of UMN impairment. The clinical evaluation of bulbar functions is mainly based on subjective feeling of disability. We used the presence of palmental reflex and pseudobulbar affect as signs of UMN impairment in the bulbar region, although they are not invariably specific for UMN degeneration. Indeed, they were reported in some other neurological conditions, also without clear involvement of the motor pyramidal tract (Ahmed and Simmons, 2013; Schott and Rossor, 2016), and in some healthy people, while their absence in disease states has also been described (Owen and Mulley, 2002). Coexisting neurophysiological alterations are usually not systematically explored whenever the diagnosis becomes defined, being the investigation methods uncomfortable and often not well tolerated by patients. Nonetheless, the availability of a complete set of clinical and neurophysiological data referred to bulbar muscles at baseline and in the follow-up could further support our results and provide additional information to investigate the role of T2*-weighted images in the pre-symptomatic stage of bulbar dysfunction.

5. Conclusion

This study showed that, using a 3 T-MR system, the marked and thin T2* hypointensity in fM1 is a frequent and easily detectable feature in

ALS patients with bulbar impairment. This signal alteration involves the middle and ventral part of fM1 and is usually visible in both hemispheres.

The relationship between imaging, clinical and neurophysiological data suggests the marked hypointensity of fM1 as a marker of UMN degeneration responsible for the impairment of voluntary bulbar motor functions.

Acknowledgments

The authors would like to thank Prof. F. Sartucci for TMS interpretation and P. Frumento for statistical assistance. This study was partially supported by institutional grant of University of Pisa, funded by the Italian Ministry of Education, University and Research, and by grant "RC 2018-2020" to IRCCS Stella Maris, funded by the Italian Ministry of Health.

Appendix A. Supplementary data

Supplementary data to this article can be found online at <https://doi.org/10.1016/j.nicl.2019.101934>.

References

- Adachi, Y., Sato, N., Saito, Y., Kimura, Y., Nakata, Y., Ito, K., Kamiya, K., Matsuda, H., Tsukamoto, T., Ogawa, M., 2015. Usefulness of SWI for the detection of iron in the motor cortex in amyotrophic lateral sclerosis. *J. Neuroimaging* 25, 443–451. <https://doi.org/10.1111/jon.12127>.
- Ahmed, A., Simmons, Z., 2013. Pseudobulbar affect: prevalence and management. *Ther. Clin. Risk Manag.* 9, 483–489. <https://doi.org/10.2147/TCRM.S53906>.
- Arwas, N., Leshno, A., Gotkine, M., 2018. The palmental reflex predicts earlier corticobulbar involvement in ALS. *Amyotroph. Lateral Scler. Frontotemporal Degener.* 19, 1–3. <https://doi.org/10.1080/21678421.2018.1497064>.
- Bede, P., Hardiman, O., 2014. Lessons of ALS imaging: pitfalls and future directions - a critical review. *Neuroimage Clin.* 4, 436–443. <https://doi.org/10.1016/j.nicl.2014.02.011>.
- Bede, P., Bokde, A., Elamin, M., Byrne, S., McLaughlin, R.L., Jordan, N., Hampel, H., Gallagher, L., Lynch, C., Fagan, A.J., Pender, N., Hardiman, O., 2013. Grey matter correlates of clinical variables in amyotrophic lateral sclerosis (ALS): a neuroimaging study of ALS motor phenotype heterogeneity and cortical focality. *J. Neurol. Neurosurg. Psychiatry* 84, 766–773. <https://doi.org/10.1136/jnnp-2012-302674>.
- Brooks, B.R., Miller, R.G., Swash, M., Munsat, T.L., World Federation of Neurology Research Group on Motor Neuron Diseases, 2000. El Escorial revisited: revised criteria for the diagnosis of amyotrophic lateral sclerosis. *Amyotroph. Lateral Scler. Other Motor Neuron Disord.* 1, 293–299. <https://doi.org/10.1080/146608200300079536>.
- Brownell, B., Oppenheimer, D.R., Hughes, J.T., 1970. The central nervous system in motor neuron disease. *J. Neurol. Neurosurg. Psychiatry* 33, 338–357.
- Cattaneo, L., Pavesi, G., 2014. The facial motor system. *Neurosci. Biobehav. Rev.* 38, 135–159. <https://doi.org/10.1016/j.neubiorev.2013.11.002>.
- Cedarbaum, J.M., Stambler, N., Malta, E., Fuller, C., Hilt, D., Thurmond, B., Nakanishi, A., 1999. The ALSFRS-R: a revised ALS functional rating scale that incorporates assessments of respiratory function. *BDNF ALS Study Group (phase III)*. *J. Neurol. Sci.* 169, 13–21.
- Chiò, A., Calvo, A., Moglia, C., Mazzini, L., Mora, G., PARALS Study Group, 2011. Phenotypic heterogeneity of amyotrophic lateral sclerosis: a population based study. *J. Neurol. Neurosurg. Psychiatry* 82, 740–746. <https://doi.org/10.1136/jnnp.2010.235952>.
- Cosottini, M., Frosini, D., Pesaresi, I., Donatelli, G., Cecchi, P., Costagli, M., Biagi, L., Ceravolo, R., Bonuccelli, U., Tosetti, M., 2015. Comparison of 3T and 7T susceptibility-weighted angiography of the substantia nigra in diagnosing Parkinson disease. *AJNR Am. J. Neuroradiol.* 36, 461–466. <https://doi.org/10.3174/ajnr.A4158>.
- Cosottini, M., Donatelli, G., Costagli, M., Caldarazzo Ienco, E., Frosini, D., Pesaresi, I., Biagi, L., Siciliano, G., Tosetti, M., 2016. High-resolution 7T MR imaging of the motor cortex in amyotrophic lateral sclerosis. *AJNR Am. J. Neuroradiol.* 37, 455–461. <https://doi.org/10.3174/ajnr.A4562>.
- Costagli, M., Donatelli, G., Biagi, L., Caldarazzo Ienco, E., Siciliano, G., Tosetti, M., Cosottini, M., 2016. Magnetic susceptibility in the deep layers of the primary motor cortex in amyotrophic lateral sclerosis. *Neuroimage Clin.* 12, 965–969. <https://doi.org/10.1016/j.nicl.2016.04.011>.
- de Carvalho, M., Dengler, R., Eisen, A., England, J.D., Kaji, R., Kimura, J., Mills, K., Mitsumoto, H., Nodera, H., Shefner, J., Swash, M., 2008. Electrodiagnostic criteria for diagnosis of ALS. *Clin. Neurophysiol.* 119, 497–503. <https://doi.org/10.1016/j.clinph.2007.09.143>.
- Donatelli, G., Retico, A., Caldarazzo Ienco, E., Cecchi, P., Costagli, M., Frosini, D., Biagi, L., Tosetti, M., Siciliano, G., Cosottini, M., 2018. Semiautomated evaluation of the primary motor cortex in patients with amyotrophic lateral sclerosis at 3T. *AJNR Am. J. Neuroradiol.* 39, 63–69. <https://doi.org/10.3174/ajnr.A5423>.

- Eisen, A., Swash, M., 2001. Clinical neurophysiology of ALS. *Clin. Neurophysiol.* 112, 2190–2201.
- Filippi, M., Agosta, F., Abrahams, S., Fazekas, F., Grosskreutz, J., Kalra, S., Kassubek, J., Silani, V., Turner, M.R., Masdeu, J.C., European Federation of Neurological Societies, 2010. EFNS guidelines on the use of neuroimaging in the management of motor neuron diseases. *Eur. J. Neurol.* <https://doi.org/10.1111/j.1468-1331.2010.02951.x>.
- Huynh, W., Simon, N.G., Grosskreutz, J., Turner, M.R., Vucic, S., Kiernan, M.C., 2016. Assessment of the upper motor neuron in amyotrophic lateral sclerosis. *Clin. Neurophysiol.* 127, 2643–2660. <https://doi.org/10.1016/j.clinph.2016.04.025>.
- Kawamata, T., Akiyama, H., Yamada, T., McGeer, P.L., 1992. Immunologic reactions in amyotrophic lateral sclerosis brain and spinal cord tissue. *Am. J. Pathol.* 140, 691–707.
- Kiernan, M.C., Vucic, S., Cheah, B.C., Turner, M.R., Eisen, A., Hardiman, O., Burrell, J.R., Zoing, M.C., 2011. Amyotrophic lateral sclerosis. *Lancet* 377, 942–955. [https://doi.org/10.1016/S0140-6736\(10\)61156-7](https://doi.org/10.1016/S0140-6736(10)61156-7).
- Körner, S., Kollwe, K., Fahlbusch, M., Zapf, A., Dengler, R., Krampfl, K., Petri, S., 2011. Onset and spreading patterns of upper and lower motor neuron symptoms in amyotrophic lateral sclerosis. *Muscle Nerve* 43, 636–642. <https://doi.org/10.1002/mus.21936>.
- Kühnlein, P., Gdynia, H.-J., Sperfeld, A.-D., Lindner-Pfleghar, B., Ludolph, A.C., Prosiegel, M., Riecker, A., 2008. Diagnosis and treatment of bulbar symptoms in amyotrophic lateral sclerosis. *Nat. Clin. Pract. Neurol.* 4, 366–374. <https://doi.org/10.1038/ncpneuro0853>.
- Kwan, J.Y., Jeong, S.Y., van Gelderen, P., Deng, H.-X., Quezado, M.M., Danielian, L.E., Butman, J.A., Chen, L., Bayat, E., Russell, J., Siddique, T., Duyen, J.H., Rouault, T.A., Floeter, M.K., 2012. Iron accumulation in deep cortical layers accounts for MRI signal abnormalities in ALS: correlating 7 tesla MRI and pathology. *PLoS One* 7, e35241. <https://doi.org/10.1371/journal.pone.0035241>.
- Lawyer, T., Netsky, M.G., 1953. Amyotrophic lateral sclerosis. *AMA Arch. Neurol. Psychiatr.* 69, 171–192.
- Leigh, P.N., Abrahams, S., Al-Chalabi, A., Ampong, M.-A., Goldstein, L.H., Johnson, J., Lyall, R., Moxham, J., Mustafa, N., Rio, A., Shaw, C., Willey, E., King's MND Care and Research Team, 2003. The management of motor neurone disease. *J. Neurol. Neurosurg. Psychiatry* 74 (Suppl. 4), iv32–iv47. https://doi.org/10.1136/jnnp.74.suppl_4.iv32.
- Logroscino, G., Traynor, B.J., Hardiman, O., Chio, A., Couratier, P., Mitchell, J.D., Swinger, R.J., Beghi, E., EURALS, 2008. Descriptive epidemiology of amyotrophic lateral sclerosis: new evidence and unsolved issues. *J. Neurol. Neurosurg. Psychiatry* 79, 6–11. <https://doi.org/10.1136/jnnp.2006.104828>.
- Mazziotta, J.C., Toga, A.W., Evans, A., Fox, P., Lancaster, J., 1995. A probabilistic atlas of the human brain: theory and rationale for its development. *The International Consortium for Brain Mapping (ICBM). NeuroImage* 2, 89–101.
- Owen, G., Mulley, G.P., 2002. The palmomental reflex: a useful clinical sign? *J. Neurol. Neurosurg. Psychiatry* 73, 113–115. <https://doi.org/10.1136/jnnp.73.2.113>.
- Pallebage-Gamarallage, M., Foxley, S., Menke, R.A.L., Huszar, I.N., Jenkinson, M., Tendler, B.C., Wang, C., Jbabdi, S., Turner, M.R., Miller, K.L., Ansoorge, O., 2018. Dissecting the pathobiology of altered MRI signal in amyotrophic lateral sclerosis: a post mortem whole brain sampling strategy for the integration of ultra-high-field MRI and quantitative neuropathology. *BMC Neurosci.* 19, 11. <https://doi.org/10.1186/s12868-018-0416-1>.
- Penfield, W., Boldrey, E., 1937. Somatic motor and sensory representation in the cerebral cortex of man as studied by electrical stimulation. *Brain* 60, 389–443. <https://doi.org/10.1093/brain/60.4.389>.
- Penfield, W., Rasmussen, T., 1950. *The Cerebral Cortex of Man*. Macmillan.
- Saberi, S., Stauffer, J.E., Schulte, D.J., Ravits, J., 2015. Neuropathology of amyotrophic lateral sclerosis and its variants. *Neurol. Clin.* 33, 855–876. <https://doi.org/10.1016/j.jnc.2015.07.012>.
- Schott, J.M., Rossor, M.N., 2016. The palmomental reflex: stop scratching around! *Pract. Neurol.* 16, 500–501. <https://doi.org/10.1136/practneurol-2016-001509>.
- Schuster, C., Kasper, E., Machts, J., Bittner, D., Kaufmann, J., Benecke, R., Teipel, S., Vielhaber, S., Prudlo, J., 2013. Focal thinning of the motor cortex mirrors clinical features of amyotrophic lateral sclerosis and their phenotypes: a neuroimaging study. *J. Neurol.* 260, 2856–2864. <https://doi.org/10.1007/s00415-013-7083-z>.
- Soraru, G., Ermani, M., Logroscino, G., Palmieri, A., D'Ascenzo, C., Orsetti, V., Volpe, M., Cima, V., Zara, G., Pegoraro, E., Angelini, C., 2010. Natural history of upper motor neuron-dominant ALS. *Amyotroph. Lateral Scler.* 11, 424–429. doi:<https://doi.org/10.3109/17482960903300867>.
- Swash, M., 2012. Why are upper motor neuron signs difficult to elicit in amyotrophic lateral sclerosis? *J. Neurol. Neurosurg. Psychiatry* 83, 659–662. <https://doi.org/10.1136/jnnp-2012-302315>.
- Tsuchiya, K., Ikeda, K., Mimura, M., Takahashi, M., Miyazaki, H., Anno, M., Shiotsu, H., Akabane, H., Niizato, K., Uchiyama, T., Tominaga, I., Nakano, I., 2002. Constant involvement of the Betz cells and pyramidal tract in amyotrophic lateral sclerosis with dementia: a clinicopathological study of eight autopsy cases. *Acta Neuropathol.* 104, 249–259. <https://doi.org/10.1007/s00401-002-0543-7>.
- Urban, P.P., Vogt, T., Hopf, H.C., 1998. Corticobulbar tract involvement in amyotrophic lateral sclerosis. A transcranial magnetic stimulation study. *Brain* 121 (Pt 6), 1099–1108. <https://doi.org/10.1093/brain/121.6.1099>.
- Vázquez-Costa, J.F., Mazón, M., Carreres-Polo, J., Hervás, D., Pérez-Tur, J., Martí-Bonmatí, L., Sevilla, T., 2018. Brain signal intensity changes as biomarkers in amyotrophic lateral sclerosis. *Acta Neurol. Scand.* 137, 262–271. <https://doi.org/10.1111/ane.12863>.
- Vucic, S., Nicholson, G.A., Kiernan, M.C., 2008. Cortical hyperexcitability may precede the onset of familial amyotrophic lateral sclerosis. *Brain* 131, 1540–1550. <https://doi.org/10.1093/brain/awn071>.
- Walhout, R., Westeneng, H.-J., Verstraete, E., Hendrikse, J., Veldink, J.H., van den Heuvel, M.P., van den Berg, L.H., 2015. Cortical thickness in ALS: towards a marker for upper motor neuron involvement. *J. Neurol. Neurosurg. Psychiatry* 86, 288–294. <https://doi.org/10.1136/jnnp-2013-306839>.
- Wijesekera, L.C., Leigh, P.N., 2009. Amyotrophic lateral sclerosis. *Orphanet J. Rare Dis.* 4 (3). <https://doi.org/10.1186/1750-1172-4-3>.
- Yousry, T.A., Schmid, U.D., Alkadhi, H., Schmidt, D., Peraud, A., Buettner, A., Winkler, P., 1997. Localization of the motor hand area to a knob on the precentral gyrus. A new landmark. *Brain* 120 (Pt 1), 141–157.
- Zoccollella, S., Beghi, E., Palagano, G., Fraddosio, A., Samarelli, V., Lamberti, P., Lepore, V., Serlenga, L., Logroscino, G., 2006. Signs and symptoms at diagnosis of amyotrophic lateral sclerosis: a population-based study in southern Italy. *Eur. J. Neurol.* 13, 789–792. <https://doi.org/10.1111/j.1468-1331.2006.01384.x>.