

Risk Factors for Rapid Chondrolysis After Partial Lateral Meniscectomy

A Scoping Review of the Literature

Charles Pioger,* MD, Adnan Saithna,[†] MD, Vikram Kandhari,* MS, DNB, Mathieu Thauinat,* MD, Thais D. Vieira,* MD, Benjamin Freychet,* MD, Florent Franck,* MD, and Bertrand Sonnery-Cottet,*[‡] MD

Investigation performed at the Centre Orthopedique Santy, FIFA Medical Center of Excellence, Hôpital Privé Jean Mermoz, Groupe Ramsay-Generale, Lyon, France

Background: The occurrence of rapid chondrolysis after partial lateral meniscectomy is rare. The pathophysiology, risk factors, and outcomes of treatment have not been established.

Purpose: The primary aim of this study was to perform a scoping review of the literature to determine the potential risk factors and pathogenesis of rapid chondrolysis. The secondary objective was to report outcomes of treatment.

Study Design: Systematic (scoping) review.

Methods: A scoping review of the literature was conducted in accordance with the framework of Arksey and O'Malley. A search strategy based on the terms "chondrolysis" AND "knee," "chondrolysis" AND "meniscus," and "chondral damage" AND "lateral meniscus" was applied to the PubMed database on March 31, 2020. All relevant studies were included. Patient demographics and clinical data were extracted from these studies and analyzed in order to investigate the potential risk factors, pathogenesis, and outcomes of treatment for rapid chondrolysis.

Results: Five articles (22 cases) featuring rapid chondrolysis in the lateral compartment after partial lateral meniscectomy were identified and included. The condition occurred most frequently in patients who were young (mean age, 25.6 years), male (20/22 cases; 91%), and participating in high-intensity sports (19/22 cases; 86.4%) within 1 year of the index procedure. Half of the included study population underwent surgery for a radial tear. All professional athletes (13/13) returned to the preinjury level of sport. All authors of included studies suggested that the main causal risk factor was mechanical focal cartilage overload in the lateral compartment of the knee.

Conclusion: Rapid chondrolysis after partial lateral meniscectomy is a rare condition that typically occurs within 12 months of the index procedure. Younger age, male sex, high-intensity sports participation, and some meniscal tear patterns (eg, radial tear) are potentially important risk factors. Return-to-sport rates at short-term follow up are high, but no long-term studies were identified. The pathogenesis of rapid chondrolysis seems to relate to mechanical focal cartilage overload.

Keywords: knee; arthroscopy; rapid chondrolysis; lateral meniscus; meniscectomy

Treatment of meniscal tears with arthroscopic meniscectomy is among the most frequently performed procedures in orthopaedic surgery. Partial lateral meniscectomy (PLM) performed in stable knees is associated with high satisfaction rates (>95%)⁹ and a high number of symptom-free patients (79.9%) at a minimum follow-up of 10 years.⁹ There are also numerous studies reporting favorable outcomes at short-term follow-up.^{20,21,29,36} However,

in contrast to these generally good results, there are reports of rapid chondrolysis (RC) after PLM.^{2,8,19,22,35}

Chondrolysis of the knee after PLM refers to rapid loss of articular cartilage in the lateral compartment, resulting in knee pain and persistent swelling.^{2,8,19,22,35} Figure 1 demonstrates the typical radiological features and arthroscopic findings associated with RC in a 22-year-old soccer player who had undergone PLM of the right knee (at another institution) 8 months before presentation to our clinic. He had a history of persistent pain and swelling. There was no evidence of ligamentous injury, and he had normal limb alignment.

The Orthopaedic Journal of Sports Medicine, 9(2), 2325967120981777

DOI: 10.1177/2325967120981777

© The Author(s) 2021

This open-access article is published and distributed under the Creative Commons Attribution - NonCommercial - No Derivatives License (<https://creativecommons.org/licenses/by-nc-nd/4.0/>), which permits the noncommercial use, distribution, and reproduction of the article in any medium, provided the original author and source are credited. You may not alter, transform, or build upon this article without the permission of the Author(s). For article reuse guidelines, please visit SAGE's website at <http://www.sagepub.com/journals-permissions>.

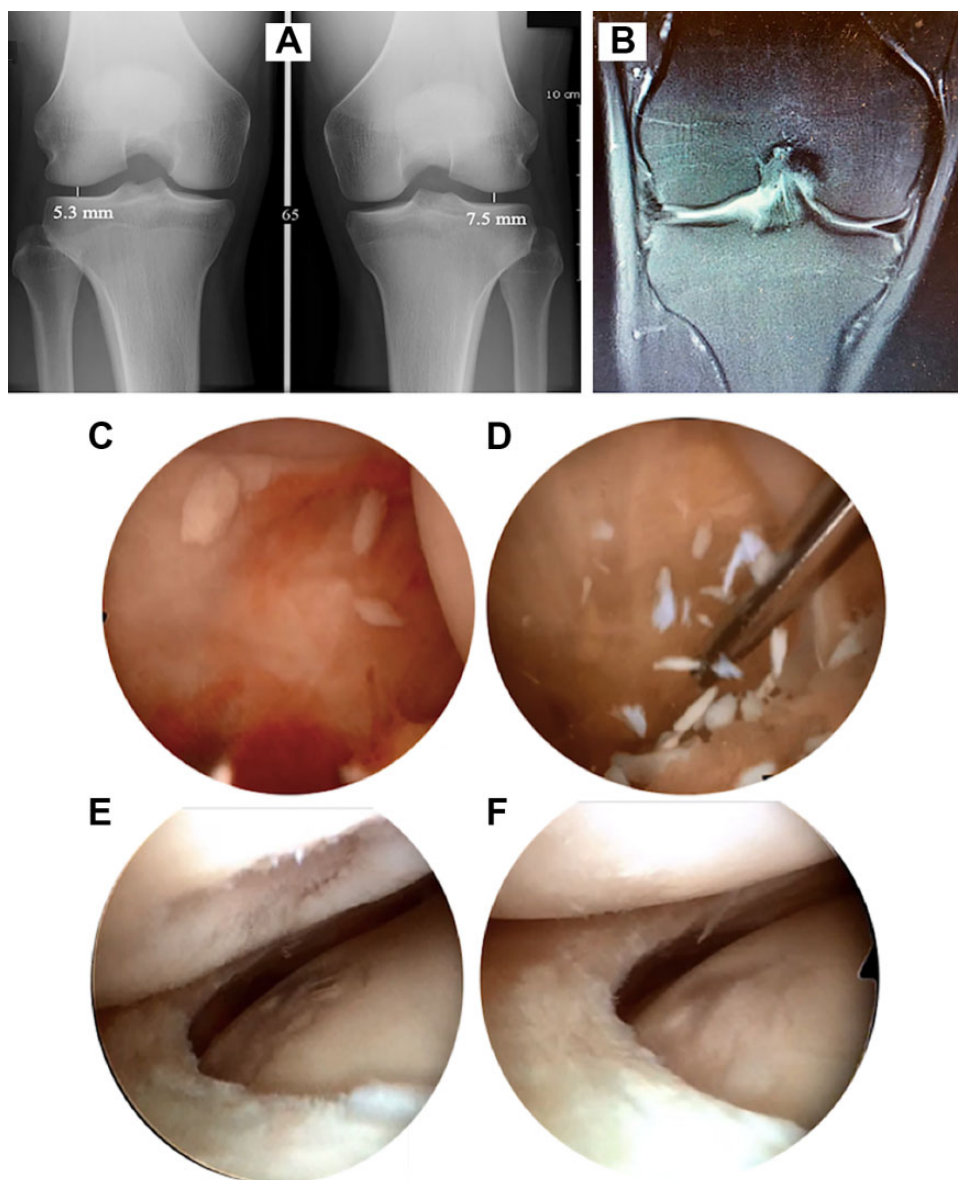


Figure 1. (A) Clinical suspicion of rapid chondrolysis was raised because radiographs (Schuss views) demonstrated 30% narrowing of the lateral compartment joint space as compared with the left knee (lateral compartment joint space, 7.5 mm in the left knee and 5.3 mm in the right). (B) Furthermore, magnetic resonance images at the same time demonstrated evidence of previous lateral meniscectomy and effusion. The patient went on to have arthroscopic evaluation, which revealed (C, D) abundant loose cartilaginous debris, (E) Outerbridge grade 4 changes on the lateral femoral condyle, and (F) grade 3 changes on the lateral tibial plateau.

The occurrence of this condition gives rise to the juxtaposition of typically excellent outcomes in the majority of patients who undergo this frequently performed

procedure versus this rare complication of undefined etiology and unknown risk factors.

†Address correspondence to Bertrand Sonnery-Cottet, MD, 24 Avenue Paul Santy, 69008 Lyon, France (email: sonnerycottet@aol.com) (Twitter: @Sonnerycottet; @c_pgr).

*Centre Orthopedique Santy, FIFA Medical Centre of Excellence, Groupe Ramsay-Generale de Sante, Hôpital Privé Jean Mermoz, Lyon, France.

†Kansas City University of Medicine and Biosciences, Kansas City, Kansas, USA.

Final revision submitted July 8, 2020; accepted August 27, 2020.

One or more of the authors has declared the following potential conflict of interest or source of funding: B.S.-C. is a paid consultant for and receives royalties and research support from Arthrex. M.T. is a paid consultant for Arthrex. AOSSM checks author disclosures against the Open Payments Database (OPD). AOSSM has not conducted an independent investigation on the OPD and disclaims any liability or responsibility relating thereto.

The primary aim of this scoping review was to examine the extent, range, and quality of the evidence available to explain the pathophysiology and potential risk factors for RC after PLM. The secondary aim was to report outcomes of treatment for RC.

METHODS

A scoping review of the literature was conducted in accordance with the methodological framework of Arksey and O'Malley³ and the PRISMA-ScR (Preferred Reporting Items for Systematic Reviews and Meta-Analyses Extension for Scoping Reviews). A scoping review methodology was selected because this approach is considered to have great utility for addressing an exploratory research question. However, some limitations with this methodology can lead to a broader and less defined approach and some inconsistencies with the search that will require larger teams to review the search results.^{3,10,24} The study protocol was prospectively registered with the Open Science Framework study registry before commencing data collection.

The 5-stage methodological framework of Arksey and O'Malley³ comprises the following steps: (1) identification of a research question; (2) identification of the relevant studies; (3) the selection of studies to be included in the review; (4) data extraction from the included studies; and (5) collating, summarizing, and reporting of the results of the review.

Identification of the Research Question

The research question was as follows: What is known from the existing literature regarding the pathophysiology and risk factors for RC after PLM?

Identifying Relevant Studies

Relevant studies were identified by applying the search strategy to the PubMed database. This comprised the following keywords with automatic mapping to Medical Subject Headings terms: "chondrolysis" AND "knee," "chondrolysis" AND "meniscus," and "chondral damage" AND "lateral meniscus." The search was conducted on March 31, 2020, by 2 independent investigators (C.P. and V.K.). Both investigators reviewed the titles and abstracts of all identified records, and potentially eligible articles were retrieved for full-text review. The reference lists of articles included at the full-text review stage were screened to identify any additional eligible studies for review.

Study Selection

All identified clinical studies and case series reporting RC after lateral meniscal tear and/or PLM were included. Articles were excluded only if a history of inflammatory arthritis or intra-articular local anesthetic administration was reported, because each is recognized to be independently associated with RC.^{7,13,27,30} Disagreement between

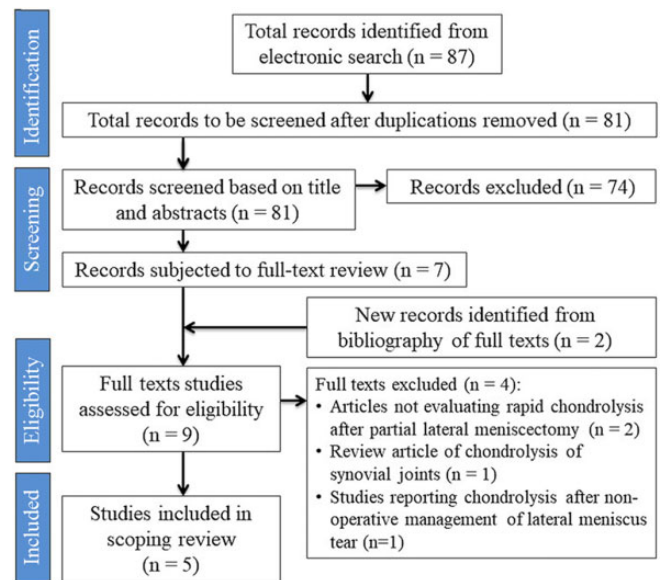


Figure 2. Flow diagram of identification, screening, and selection of studies.

reviewers regarding study eligibility was resolved through discussion with the senior author (B.S.-C.).

Data Extraction

The following data were extracted from each study and charted in Excel 2011 (Microsoft Corp): demographic characteristics of the patients, type and level of sports participation, duration of follow-up, Outerbridge grade in the lateral compartment as documented at the time of PLM, limb alignment, time from PLM to diagnosis of RC, subsequent treatment undertaken, clinical outcomes, and the cause of lateral compartment RC reported.

Collating, Summarizing, and Reporting the Results

Owing to the small number of published studies and the heterogeneity among them, no statistical analyses were performed. Instead, the findings were summarized through a narrative analysis of the published literature. The risk of bias in case series was assessed using the MINORS (Methodological Index for Non-randomized Studies) tool.³⁴ The level of evidence of each article was classified according to the 2011 adjusted criteria of the Oxford Centre for Evidence-Based Medicine.¹⁸ The quality of evidence for each potential risk factor studied was assessed using the criteria of the GRADE (Grading of Recommendations Assessment, Development and Evaluation) Working Group.^{15,31}

RESULTS

Application of the search strategy and eligibility criteria resulted in the inclusion of 5 articles (totaling 22 cases of RC). Figure 2 demonstrates the flow of studies. The publication dates of the studies ranged from 1998 to 2014.

TABLE 1
Demographics and Clinical Characteristics of Included Patients With Rapid Chondrolysis After Partial Lateral Meniscectomy^a

	Charrois (1998) ⁸	Ishida (2006) ¹⁹	Alford (2005) ²	Mariani (2008) ²²	Sonnery-Cottet (2014) ³⁵
No. of cases	4	1	2	5	10 (2 bilateral cases)
Sex	3 M, 1 F	1 M	2 M	5 M	7 M (2 bilateral cases), 1 F
Mean age, y	29.5	17	29.5	26.8	25.2
Type of sports	1 boxing, 1 handball, 2 leisure	1 basketball	1 runner, 1 soccer	5 soccer	4 handball, 2 rugby, 4 soccer
Level of play	2 competitive, 2 recreational	1 competitive	1 recreational, 1 competitive	5 professional	8 professional (10 cases)
Limb alignment ^b	1 varus (NA), 3 NA	1 varus (178°)	1 varus (176°), 1 NA	5 varus (NA)	6 neutral, 4 valgus (NA)
Level of evidence	4	5	5	4	4

^aF, female; M, male; NA, not available.

^bHip-knee-ankle angle in parentheses.

TABLE 2
Quality Assessment of Included Case Series Using the MINORS^a

MINORS Criterion	Charrois ⁸ (1998)	Mariani ²² (2008)	Sonnery-Cottet ³⁵ (2014)
Level of evidence (study design)	4 (case series)	4 (case series)	4 (case series)
Clearly stated aim	2	2	2
Inclusion of consecutive patients	NA	2	2
Prospective data collection	0	0	0
End points appropriate to study aim	0	0	0
Unbiased assessment of study endpoint	0	0	0
Follow-up period appropriate to study aim	2	2	2
<5% lost to follow-up	2	2	2
Prospective calculation of study size	0	0	0
Adequate control group	NA	NA	NA
Contemporary groups	NA	NA	NA
Baseline equivalence of groups	NA	NA	NA
Adequate statistical analyses	NA	NA	NA
Total score (maximum: 16)	6	8	8

^aMINORS, Methodological Index for Non-randomized Studies; NA, not available.

TABLE 3
Quality of Evidence for All Possible Risk Factors for Rapid Chondrolysis^a

Risk factor	Risk of Bias	Inconsistency	Indirectness	Imprecision	GRADE Score
Young age	Negligible	Negligible	Serious	Very serious	Very low
Male sex	Serious	Serious	Serious	Very serious	Very low
High-intensity sports participation	Negligible	Negligible	Serious	Very serious	Very low
Mechanical overload	Negligible	Negligible	Serious	Very serious	Very low
Rotational laxity	Very serious	Very serious	Serious	Very serious	Very low

^aGRADE, Grading of Recommendations, Assessment, Development and Evaluation.

Three studies were case series (level 4 evidence),^{8,22,35} and the remaining 2 were case reports (level 5 evidence).^{2,19}

Basic Characteristics of the Studies

Table 1 presents population characteristics, including demographic data, type and level of sports participation, and limb alignment. Of the 22 total cases, 20 (91%) were

male. In all studies, the mean age of patients was <30 years, but the range was 16 to 43 years. Fifteen cases (68.2%) involved professional athletes, and the other 7 (31.8%) comprised patients who participated in sports for recreational purposes or at a competitive level.

The methodological quality of the case series (as evaluated by the MINORS tool) varied between 6 and 8, indicating a high risk of bias (Table 2). The strength of the evidence available to determine potential risk factors for

TABLE 4
PLM Indication, Management, and Chondrolysis Onset^a

	Charrois (1998) ⁸	Ishida (2006) ¹⁹	Alford (2005) ²	Mariani (2008) ²²	Sonnery-Cottet (2014) ³⁵
Type of lateral meniscal tear	1 radial tear, 1 radial tear + horizontal tear, 1 horizontal tear, 1 complex tear	NA	1 complex tear, 1 complex tear with several flaps	3 radial tears, 1 horizontal tear, 1 flap tear	5 radial tears (no extension to the posterior meniscal rim), 5 NA (MRI: no complete resection)
Associated lesions	No ligament or cartilage defect	No ligament or cartilage defect	No ligament or cartilage defect	No ligament or cartilage defect	No ligament or cartilage defect
Surgical procedure	1 PLM, 1 meniscectomy of the MH, 1 meniscectomy of the AH, 1 PLM with Ho:YAG laser	1 PLM	2 subtotal lateral meniscectomy	5 PLM with shaver and scissors	5 PLM with no extension to the posterior meniscal rim
Chondrolysis presentation after PLM, mean (range), mo	7 (5-8)	7	6 (5-6)	8.2 (6-12)	4.6 (3-6)
Chondrolysis grade	At time of AL: grades 3 and 4 ^b	At time of AL (7 mo after PLM): grade 3 ^b	At second arthroscopy (5 and 10 mo after PLM): grades 2-4 ^b	At time of AL: grades 2 and 3 with grade 4 ^b on the central area of lateral tibial plateau in all cases	At last follow-up: grades 2-4 ^c

^aAH, anterior horn of the lateral meniscus; AL, arthroscopy lavage; Ho:YAG, holmium:yttrium-aluminum-garnet; MH, middle horn of the lateral meniscus; MRI, magnetic resonance imaging; NA, not available; PLM, partial lateral meniscectomy.

^bOuterbridge classification.

^cKellgren-Lawrence classification.

TABLE 5
Chondrolysis Management and Outcomes^a

	Charrois (1998) ⁸	Ishida (2006) ¹⁹	Alford (2005) ²	Mariani (2008) ²²	Sonnery-Cottet (2014) ³⁵
Treatment strategy	Initial nonoperative treatment: corticosteroid injection (3 of 4 cases). AL in all patients (mean, 6 mo)	AL at 7 mo	AD at 5 and 10 mo after PLM. Meniscal transplant + osteochondral graft to lateral femoral condyle at 5 and 10 mo after PLM	AL (mean 8 mo) with open retensioning of posterior meniscofemoral capsule, in all cases	Nonoperative for 2-3 mo: corticosteroid/hyaluronic acid injection with isokinetic rehabilitation. AL if no response to treatment
RTS from surgery	Case 1: reduced sports activity (from competitive to recreational). Cases 2-4: NA	Case 1: Reduced sports activity (from competitive to recreational)	Case 1: RTS at 16 mo (same preinjury competitive level). Case 2: RTS at 16 mo (same preinjury recreational level)	Cases 1-5: RTS between 4 and 5 mo, at professional level	Cases 1-10: RTS at professional level at mean 8 mo (range, 5-12 mo)
Clinical follow-up, mean (range), mo	30.5 (14-48)	12	30 (24-36)	28.4 (14-48)	81.6 (36-156)
Evaluation at last follow-up	Persistent pain (n = 2); persistent pain and swelling (n = 1); HTO (n = 1)	Symptom-free (n = 1)	Pain-free with full ROM (n = 2)	Symptom-free, sports activities at professional level without any restrictions (n = 5)	Symptom-free, sports activities without any restrictions at professional level (n = 6); retired owing to age (n = 1); retired early because of increased lateral knee pain (bilateral case; n = 1)

^aAD, diagnostic arthroscopy; AL, arthroscopic lavage; HTO, high tibial osteotomy; NA, not available; PLM, partial lateral meniscectomy; ROM, range of motion; RTS, return to sport.

TABLE 6
Suggested Pathophysiology of Rapid Chondrolysis
After Partial Lateral Meniscectomy as Postulated
by Authors of the Included Studies

	Hypothesis		
	Mechanical Overloading	Increased Rotational Laxity	Other
Charrois (1998) ⁸	✓	×	×
Ishida (2006) ¹⁹	✓	×	×
Alford (2005) ²	✓	×	×
Mariani (2008) ²²	✓	✓	×
Sonnery-Cottet (2014) ³⁵	✓	×	×

RC was very low based on assessment using GRADE recommendations (Table 3).

The main symptoms after RC were persistent pain and joint effusion, leading to decreased sports activity. Table 4 depicts the spectrum of meniscal lesions encountered, treatment undertaken, and evolution of cartilage damage experienced by the patients in the individual studies. It is potentially important that 45.5% (10/22) of patients underwent PLM for a radial tear. In the remaining patients, complex lateral meniscal tears were found in 4 cases and horizontal lesions in 2 patients, and the type of tear was not published in 6 cases. Table 5 presents details of the treatment provided and the outcomes, including return-to-sport data. All professional athletes in this scoping review (13/13) were able to return to competition at the preinjury levels of sport, including both of the bilateral cases. Of the remaining 7 patients, 2 returned to preinjury level of sport and 2 reduced their sports activity, while information about return to sport was missing for 3 patients. Sonnery-Cottet et al³⁵ noted that 6 of 8 professional soccer players were able to continue sports participation at the same level at a mean follow-up of 6.75 years (1 player retired because of his age, and 1 ended his career because of knee pain).

All of the authors reviewed suggested a possible causal mechanism for the development of RC. These data are presented in Table 6. In summary, there was universal agreement that mechanical overload was an important factor in the pathogenesis of RC. Mariani et al²² stated that patients had increased rotational laxity and magnetic resonance imaging (MRI) evidence of posterolateral corner injury, however this finding was not reported by any of the other authors.

DISCUSSION

The main findings of this scoping review are that RC is a rare condition that may occur after PLM, typically within 1 year of the index procedure, and that it predominantly affects young men participating in high-intensity sports. A further important finding was that return to the preinjury level of sport is frequent. Specifically, all professional

athletes in this scoping review were able to return to their preinjury levels of sport at a mean of 8 months after RC management, although never before the fourth postoperative month. Sonnery-Cottet et al³⁵ noted that 6 of 8 professional athletes in their series were still competing at the same level at a mean follow-up of 81.6 months, despite grade 3-4 Kellgren-Lawrence changes in the lateral compartment. However, return to sport was not universal in recreational athletes.

An additional important finding was that all of the authors postulated that the pathophysiological process for RC has a mechanical basis and that excessive focal cartilage loading is the trigger.^{2,19,22,35,37} It is well recognized that meniscal resection negatively affects the stress distribution and load transmission within the knee. However, it is of particular relevance in the lateral compartment because the lateral femoral condyle and lateral tibial plateau are convex and rely considerably on the presence of the meniscus for joint congruity. As a result, the meniscus bears 70% of the load transmitted through the lateral compartment of the knee. In comparison, in the medial compartment, only 50% of the load is borne by the meniscus³² because the convex femoral condyle articulates with the relatively congruous and concave tibial plateau. Consequently, the lateral compartment is more vulnerable than the medial compartment to degenerative changes after partial meniscectomy or meniscal tear and thus tends to deteriorate much faster.⁵ Murakami et al²⁵ also reported in a 2018 MRI study with T2 mapping that resection of any lateral meniscal segment may cause early cartilage degeneration. These observations could also explain why outcomes of PLM are inferior^{1,12,16,17,26} and why early return to sports after PLM in professional or competitive athletes is notably more challenging when compared with partial medial meniscectomy.

Specifically, Nawabi et al²⁶ cited a higher risk of adverse symptoms during the early recovery phase after PLM as compared with patients undergoing medial meniscectomy. Among 42 elite athletes who had undergone PLM, 69% experienced chronic effusion and/or persistent joint-line pain.²⁶ In the same study, the relative rate of return to preinjury levels was 6 times greater after medial meniscectomy than PLM. These findings were supported by Aune et al,⁴ who indicated that 38% of National Football League athletes were unable to return to play at their previous levels after partial and isolated lateral meniscectomy; however, there was no mention of RC. In a retrospective case-control study,⁶ the Tegner activity scores of 31 competitive athletes were evaluated before and after isolated PLM. The authors cited a decrease from a mean score of 7.2 (competitive sports) to 5.7 (recreational sports) at a mean follow-up of 8 years.⁶ Additionally, Ford et al¹⁴ suggested that concern is warranted in returning athletes to sport activities after PLM of an isolated radial tear attributed to isokinetic torque deficits. The authors postulated that athletes who returned to sport 3 months after PLM may employ compensation strategies with landing as compared with the uninjured limb, which could lead to poor outcomes.

Regardless of the compartment, a meniscal tear or partial meniscectomy alters the geometry and shape of the

meniscus and reduces its functional capacity. The severity of the deficit is dependent on the tear morphology, with some tear patterns, such as radial tears extending to the periphery and root tears, being equivalent to a total meniscectomy in terms of the resultant increase in joint contact forces.^{23,28} Based on this concept, it is perhaps unsurprising that half of the study population had a radial tear at the time of PLM. Although the study population was too small to make firm conclusions in this regard, it is likely that tear patterns with the most severe biomechanical consequences confer an increased risk of RC because of the potential for significant cartilage overload. However, it is important to note that RC has occurred even after a limited PLM, as demonstrated from our patient in Figure 1.

Once the cartilage is overloaded, chondrocyte death and cartilage matrix damage may occur.¹¹ The injured cartilage releases debris into the synovial fluid, which is phagocytosed by synovial macrophages, amplifying the synovitis. In response, synovial cells produce catabolic and proinflammatory mediators (cytokines, collagenases) that boost the production of proteolytic enzymes responsible for cartilage breakdown, creating a positive feedback loop³³ that may ultimately lead to RC.

Although a common denominator identified in this review was that the authors of all studies postulated that the pathophysiology of RC was based on mechanical overload, Mariani et al²² suggested that posterolateral corner laxity may be important in the development of RC after PLM. The authors identified rotational laxity (positive dial test at 30° of knee flexion) and MRI evidence of posterolateral corner injury (lax fibular collateral ligament and increased signal at the popliteus musculotendinous junction) in 5 professional soccer players with RC after a PLM. They proposed that rotational laxity could increase the shear stresses in the articular cartilage during high-performance sport activities, and they performed arthroscopic lavage with open retensioning of the posterior meniscomfemoral capsule in all patients to address laxity.²² In contrast to Mariani et al, other authors reported no evidence of ligamentous/capsular injury or rotational laxity on physical examination or MRI evaluation in patients with RC.^{35,37} In summary, it appears that there is consensus that mechanical overload is the primary causal factor, but it is important to carefully assess the posterolateral corner in any patient presenting with RC.

The main limitation of this scoping review was that published reports of RC are rare; therefore, there was limited available evidence overall. Furthermore, it may be the case that the condition is underrecognized (owing to a lack of previous publications on this topic), and as such, a reliable estimate of the true incidence after PLM cannot be determined. Additionally, all articles had small study populations, were retrospective, and had a high risk of bias. The duration of follow-up was also limited, so it was not possible to establish whether RC predisposes to a requirement for arthroplasty surgery at a young age. Although a range of treatment options was reported, there was insufficient evidence to determine the role of each, and no firm recommendations can be made. Furthermore, the overall strength of the evidence as assessed using the GRADE tool was very

low. Despite these limitations, the review provides useful information for counseling patients before PLM, highlights patients potentially at risk, and guides realistic expectations of outcomes of treatment for RC.

CONCLUSION

RC after PLM is a rare condition that typically occurs within 12 months of the index procedure. Younger age, male sex, high-intensity sports participation, and some meniscal tear patterns (eg, radial tear) are potentially important risk factors. Return-to-sport rates at short-term follow-up are high, but no long-term studies were identified. All authors of the included studies postulated that the pathogenesis of RC relates to mechanical focal cartilage overload.

REFERENCES

1. Abdou P, Turner MS, Pettersson H, Lindstrand A, Stenström A, Swanson AJ. A long-term follow-up study of total meniscectomy in children. *Clin Orthop Relat Res*. 1990;257:166-170.
2. Alford JW, Lewis P, Kang RW, Cole BJ. Rapid progression of chondral disease in the lateral compartment of the knee following meniscectomy. *Arthroscopy*. 2005;21(12):1505-1509.
3. Arksey H, O'Malley L. Scoping studies: towards a methodological framework. *Int J Soc Res Methodol*. 2005;8(1):19-32.
4. Aune KT, Andrews JR, Dugas JR, Cain EL. Return to play after partial lateral meniscectomy in National Football League athletes. *Am J Sports Med*. 2014;42(8):1865-1872.
5. Bedi A, Kelly N, Baad M, et al. Dynamic contact mechanics of radial tears of the lateral meniscus: implications for treatment. *Arthroscopy*. 2012;28(3):372-381.
6. Bonneux I, Vandekerckhove B. Arthroscopic partial lateral meniscectomy long-term results in athletes. *Acta Orthop Belg*. 2002;68(4):356-361.
7. Buchko JZ, Gurney-Dunlop T, Shin JJ. Knee chondrolysis by infusion of bupivacaine with epinephrine through an intra-articular pain pump catheter after arthroscopic ACL reconstruction. *Am J Sports Med*. 2015;43(2):337-344.
8. Charrois O, Ayrat X, Beaufils P. Rapid chondrolysis after arthroscopic external meniscectomy. Apropos of 4 cases [article in French]. *Rev Chir Orthop Reparatrice Appar Mot*. 1998;84(1):88-92.
9. Chatain F, Adeleine P, Chambat P, Neyret P; Société Française d'Arthroscopie. A comparative study of medial versus lateral arthroscopic partial meniscectomy on stable knees: 10-year minimum follow-up. *Arthroscopy*. 2003;19(8):842-849.
10. Colquhoun HL, Levac D, O'Brien KK, et al. Scoping reviews: time for clarity in definition, methods, and reporting. *J Clin Epidemiol*. 2014;67(12):1291-1294.
11. Ewers BJ, Dvoracek-Driksna D, Orth MW, Haut RC. The extent of matrix damage and chondrocyte death in mechanically traumatized articular cartilage explants depends on rate of loading. *J Orthop Res*. 2001;19(5):779-784.
12. Feeley BT, Lau BC. Biomechanics and clinical outcomes of partial meniscectomy. *J Am Acad Orthop Surg*. 2018;26(24):853-863.
13. Fester EW, Noyes FR. Postoperative chondrolysis of the knee: 3 case reports and a review of the literature. *Am J Sports Med*. 2009;37(9):1848-1854.
14. Ford KR, Minning SJ, Myer GD, Mangine RE, Colosimo AJ, Hewett TE. Landing adaptations following isolated lateral meniscectomy in athletes. *Knee Surg Sports Traumatol Arthrosc*. 2011;19(10):1716-1721.
15. Guyatt GH, Oxman AD, Vist GE, et al. GRADE: an emerging consensus on rating quality of evidence and strength of recommendations. *BMJ*. 2008;336(7650):924-926.

16. Haviv B, Bronak S, Kosashvili Y, Thein R. Which patients are less likely to improve during the first year after arthroscopic partial meniscectomy? A multivariate analysis of 201 patients with prospective follow-up. *Knee Surg Sports Traumatol Arthrosc.* 2016; 24(5):1427-1431.
17. Hede A, Larsen E, Sandberg H. Partial versus total meniscectomy: a prospective, randomised study with long-term follow-up. *J Bone Joint Surg Br.* 1992;74(1):118-121.
18. Howick J, Chalmers I, Glasziou P, et al; Oxford Centre for Evidence-Based Medicine. Explanation of the 2011 Oxford Centre for Evidence-Based Medicine (OCEBM) levels of evidence. Published 2011. <https://www.cebm.net/index.aspx?o=5653>
19. Ishida K, Kuroda R, Sakai H, Doita M, Kurosaka M, Yoshiya S. Rapid chondrolysis after arthroscopic partial lateral meniscectomy in athletes: a case report. *Knee Surg Sports Traumatol Arthrosc.* 2006; 14(12):1266-1269.
20. Jaureguito JW, Elliot JS, Lietner T, Dixon LB, Reider B. The effects of arthroscopic partial lateral meniscectomy in an otherwise normal knee: a retrospective review of functional, clinical, and radiographic results. *Arthroscopy.* 1995;11(1):29-36.
21. Lysholm J, Gillquist J. Arthroscopic meniscectomy in athletes. *Am J Sports Med.* 1983;11(6):436-438.
22. Mariani PP, Garofalo R, Margheritini F. Chondrolysis after partial lateral meniscectomy in athletes. *Knee Surg Sports Traumatol Arthrosc.* 2008;16(6):574-580.
23. Messner K, Gao J. The menisci of the knee joint: anatomical and functional characteristics, and a rationale for clinical treatment. *J Anat.* 1998;193(pt_2):161-178.
24. Munn Z, Peters MDJ, Stern C, Tufanaru C, McArthur A, Aromataris E. Systematic review or scoping review? Guidance for authors when choosing between a systematic or scoping review approach. *BMC Med Res Methodol.* 2018;18(1):143.
25. Murakami K, Arai Y, Ikoma K, et al. Total resection of any segment of the lateral meniscus may cause early cartilage degeneration: Evaluation by magnetic resonance imaging using T2 mapping. *Medicine (Baltimore).* 2018;97(23):e11011.
26. Nawabi DH, Cro S, Hamid IP, Williams A. Return to play after lateral meniscectomy compared with medial meniscectomy in elite professional soccer players. *Am J Sports Med.* 2014;42(9):2193-2198.
27. Noyes FR, Fleckenstein CM, Barber-Westin SD. The development of postoperative knee chondrolysis after intra-articular pain pump infusion of an anesthetic medication: a series of twenty-one cases. *J Bone Joint Surg Am.* 2012;94(16):1448-1457.
28. Ode GE, Van Thiel GS, McArthur SA, et al. Effects of serial sectioning and repair of radial tears in the lateral meniscus. *Am J Sports Med.* 2012;40(8):1863-1870.
29. Osti L, Liu SH, Raskin A, Merlo F, Bocchi L. Partial lateral meniscectomy in athletes. *Arthroscopy.* 1994;10(4):424-430.
30. Provencher MT, Navaie M, Solomon DJ, Smith JC, Romeo AA, Cole BJ. Joint chondrolysis. *J Bone Joint Surg Am.* 2011;93(21):2033-2044.
31. Schünemann HJ, Best D, Vist G, Oxman AD; GRADE Working Group. Letters, numbers, symbols and words: how to communicate grades of evidence and recommendations. *CMAJ.* 2003;169(7):677-680.
32. Seedhom BB, Dowson D, Wright V. Proceedings: functions of the menisci. A preliminary study. *Ann Rheum Dis.* 1974;33(1):111.
33. Sellam J, Berenbaum F. The role of synovitis in pathophysiology and clinical symptoms of osteoarthritis. *Nat Rev Rheumatol.* 2010;6(11):625-635.
34. Slim K, Nini E, Forestier D, Kwiatkowski F, Panis Y, Chipponi J. Methodological Index for Non-randomized Studies (MINORS): development and validation of a new instrument. *ANZ J Surg.* 2003;73(9):712-716.
35. Sonnery-Cottet B, Archbold P, Thauan M, Carnesecchi O, Tostes M, Chambat P. Rapid chondrolysis of the knee after partial lateral meniscectomy in professional athletes. *Knee.* 2014;21(2):504-508.
36. Stein T, Mehling AP, Welsch F, von Eisenhart-Rothe R, Jäger A. Long-term outcome after arthroscopic meniscal repair versus arthroscopic partial meniscectomy for traumatic meniscal tears. *Am J Sports Med.* 2010;38(8):1542-1548.
37. Thauan M, Archbold P, Conteduca J, Chatellard R, Sonnery-Cottet B. Rapid chondrolysis following an unoperated lateral meniscus tear in a young professional rugby player. *Orthop Traumatol Surg Res.* 2014;100(4):445-448.