



Use of extracorporeal membrane oxygenation in the management of severe tracheobronchial injuries

Bruno Maineri Pinto¹, Diego Corsetti Mondadori², William Lorenzi²,
Alisson Marques Quintao³, Mauricio Guidi Saueressig²

TO THE EDITOR,

Tracheobronchial injuries are rare entities that are associated with high morbidity and mortality. Therefore, their early and prompt diagnosis is essential to readily allow for the correct choice of therapeutic approach.^(1,2) Complex cases may require the use of extracorporeal membrane oxygenation (ECMO), enabling the use of low airway pressures, thus allowing for a safe surgical procedure.^(3,4) In this sense, herein, we describe three cases of patients with airway lesions, in which venovenous ECMO (V-V ECMO) was used as support for surgical treatment.

Initially, we present a 19-year-old female patient, a victim of a car accident, admitted to a trauma hospital in need of orotracheal intubation and pleural drainage due to bilateral pneumothorax. After 15 days of hospitalization, air leaks persisted through both surgical drains; thus, she underwent fiberoptic bronchoscopy, which revealed a laceration of the trachea that started in the cervical region and extended to the right main bronchus, with concomitant esophageal rupture. Due to the severity of the tracheoesophageal lesion and the difficulty in maintaining a safe airway, the patient was transferred to a tertiary hospital 15 days after the initial care. Shortly after arriving at the hospital, the staff unsuccessfully attempted to position the orotracheal tube in the left main bronchus and, due to the difficulty in maintaining satisfactory ventilation and the presence of respiratory acidosis and hypoxemia (pH 7.1; pO₂ 65.2 mmHg; pCO₂ 109 mmHg, PaO₂/FiO₂ ratio 76 mmHg), it was decided that V-V ECMO should be indicated. The right common femoral vein was cannulated for venous blood drainage, as was the right internal jugular vein for return of oxygenated blood, with 23 Fr and 19 Fr cannulas, respectively. Support was initiated with a blood flow of 4 L/min and a gas flow of 5 L/min. Upon immediate stabilization of the patient's oxygenation, surgical correction was planned for the following day through a right thoracotomy and cervicotomy to close the tracheal laceration with the interposition of an intercostal muscle flap due to complete necrosis of the membranous tissue, in addition to an esophagectomy. ECMO was continued for 20 days, ensuring flap healing by low ventilatory pressures. The patient evolved favorably and was discharged on the 58th day of hospitalization.

The second case was of a 36-year-old female patient with Steinert's myotonic dystrophy who underwent surgical resection of a large mass in the right hemithorax, diagnosed

as pulmonary sarcoma, and neoadjuvant radiotherapy. In the transoperative period, all lobes were found to be affected, and for this reason, a pneumonectomy was performed. Following extubation on the first postoperative day, the patient required new orotracheal intubation 2 days later due to acute respiratory failure and septic shock. She underwent tracheostomy and remained on ventilatory support for 14 days. On the 28th postoperative day, she again presented hemodynamic instability and respiratory failure, thus requiring mechanical ventilation. Chest X-ray showed a reduction in the air-fluid level in the right lung and consolidations in the left lung. Bronchoscopy revealed a 5 mm fistula in the right bronchial stump. Drainage of the right pleural cavity and subsequent installation of the V-V ECMO was carried out due to hypoxemia and hypercarbia (pH 7.09; pCO₂ 101 mmHg; PaO₂/FiO₂ 122 mmHg), in addition to significant air leakage through the fistula. The right and left femoral veins were cannulated since the jugular veins presented thrombosis. ECMO was required for a total period of 12 days, and, 4 days later, a classical pleurostomy was performed. The patient was discharged after 79 days of hospitalization.

The last case involved a 36-year-old male patient with odynophagia and dental infection who, after seeking medical care, received symptomatic medications and antibiotic therapy. After seven days, he exhibited clinical worsening associated with fever, which led him to undergo a new medical evaluation. Cervical and thoracic computed tomography were compatible with descending necrotizing mediastinitis: collection with gaseous content in the cervical region, extending to the pre-esophageal region. The patient was referred to a tertiary hospital, where he was submitted to a cervicotomy for drainage of the cervical abscess, and a right posterolateral thoracotomy, with drainage of the pleura and mediastinum. In the first days after the procedure, he evolved favorably; however, on the 4th postoperative day, the patient presented air leakage through the chest drains, as well as contralateral pneumothorax. Fiberoptic bronchoscopy revealed a fistula in the right main bronchus, in addition to a large amount of purulent secretion. The orotracheal tube was placed in the left main bronchus, and conservative treatment was performed initially. However, a worsening of ventilatory parameters was observed, with arterial blood gases presenting a PaO₂/FiO₂ ratio of 126 mmHg, associated with bilateral pneumonia. Thus, a V-V ECMO with cannulation of the right and left femoral veins was installed due to cervical infection. Immediately after

1. Serviço de Cirurgia Torácica, Hospital Geral de Caxias do Sul, Caxias do Sul (RS), Brasil.

2. Serviço de Cirurgia Torácica, Grupo de Transplante Pulmonar, Hospital de Clínicas de Porto Alegre, Porto Alegre (RS), Brasil.

3. Hospital Arnaldo Gavazza Filho, Ponto Nova (MG), Brasil.

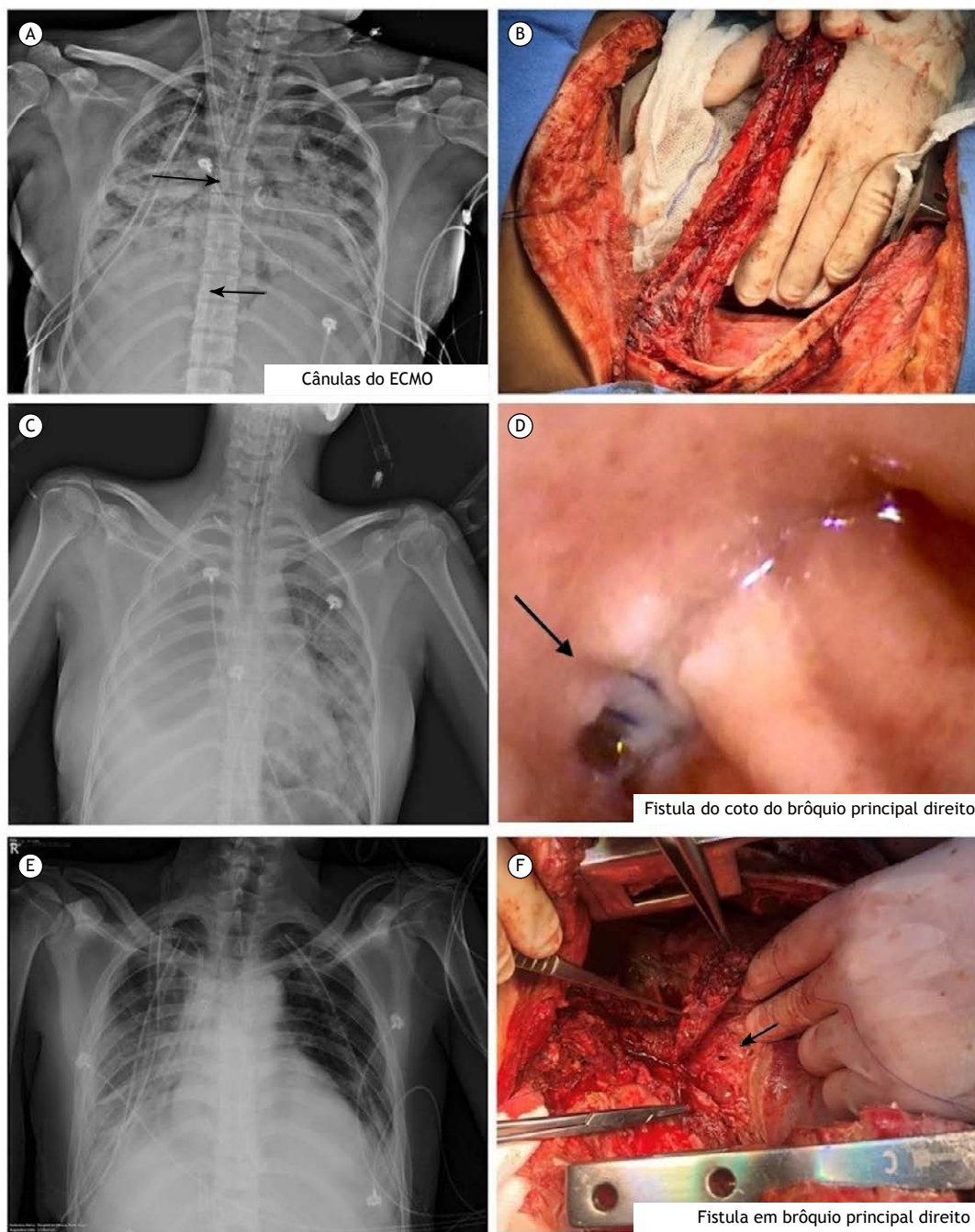


Figure 1. Images of the described case reports. Case 1: (A) chest X-ray with arrows indicating the position of the ECMO cannulas; (B) intercostal muscle flap. Case 2: (C) chest X-ray evidencing the pneumonectomy cavity to the right and pulmonary consolidations to the left; (D) right main bronchus stump with arrows indicating the location of the fistula. Case 3: (E) chest X-ray after cannulation of the right and left femoral veins; (F) arrow indicating the location of the fistula during the transoperative period.

placement of the ECMO, a new surgical approach was conducted, with debridement of the edges of the fistulas and placement of an intercostal muscle flap over the defects of the right main bronchus. ECMO was continued for another 12 days, which allowed for early extubation on the 2nd postoperative day and the maintenance of low ventilatory pressures in the airway, ensuring the healing of the repaired fistula.

Even today, the vast majority of surgeries involving the airways do not require extracorporeal support to be performed. Nevertheless, in complex injuries, the use of ECMO may be necessary in order for surgical repair to be carried out.⁽⁵⁾ This method has proven to be a useful tool in the therapeutic arsenal of the thoracic surgeon, and case reports around the world confirm its feasibility and safety.^(6,7,8) Unfortunately, in Brazil, this

technique is still costly, being, therefore, little used in such situations.⁽⁹⁾ A brief literature review revealed that only one healthcare service in our country reported two cases where ECMO was used for complex oncological resections involving the airways.⁽¹⁰⁾ Thus, we believe that our thoracic surgery service is the first to report three cases of patients who used ECMO for the surgical correction of airway injuries. In our experience, this method seems to be a satisfactory and safe option for ventilatory support in patients undergoing complex

surgeries, enabling the use of low airway pressures and ensuring adequate postoperative healing.

AUTHOR CONTRIBUTIONS

BMP: writing and reviewing the manuscript. DCM: supervising the editing of the manuscript. WL: reviewing the manuscript. AMQ: writing and reviewing the manuscript. MGS: reviewing and approval of the final manuscript.

REFERENCES

1. Prokakis C, Koletsis EN, Dedeilias P, Fligou F, Filos K, Dougenis D. Airway trauma: a review on epidemiology, mechanisms of injury, diagnosis and treatment. *J Cardiothorac Surg.* 30 Jun 2014; 9:117. <https://doi.org/10.1186/1749-8090-9-117>.
2. Shekar K, Foot C, Fraser J, Ziegenfuss M, Hopkins P, Windsor M. Bronchopleural fistula: an update for intensivists. *J Crit Care.* Mar 2010; 25(1):47-55. <https://doi.org/10.1016/j.jcrc.2009.05.007>.
3. Korvenoja P, Pitkänen O, Berg E, Berg L. Venovenous extracorporeal membrane oxygenation in surgery for bronchial repair. *Ann Thorac Surg.* 2008;86:1348-9. <https://doi.org/10.1016/j.athoracsur.2008.04.018>.
4. Hoetzenecker K, Klepetko W, Keshavjee S, Cypel M. Extracorporeal support in airway surgery. *J Thorac Dis.* Jul 2017; 9(7):2108-2117. <https://dx.doi.org/10.21037%2Fjtd.2017.06.17>.
5. Kim CW, Kim DH, Son BS, Cho JS, Kim YD, I H et al. The Feasibility of Extracorporeal Membrane Oxygenation in the Variant Airway Problems. *Ann Thorac Cardiovasc Surg.* 2015; 21(6): 517-22. <https://doi.org/10.5761/atcs.0a.15-00073>.
6. Antonacci F, De Tisi C, Donadoni I, Maurelli M, Lotti G, Taccone FS et al. Venovenous ECMO during surgical repair of tracheal perforation: A case report. *Int J Surg Case Rep.* 2018; 42:64-66. <https://dx.doi.org/10.1016%2Fj.ijscr.2017.11.036>.
7. Daoud O, Augustin P, Mordant P, Lasocki S, Al-Attar N, Maury JM et al. Extracorporeal membrane oxygenation in 5 patients with bronchial fistula with severe acute lung injury. *Ann Thorac Surg.* Jul 2011; 92(1):327-30. <https://doi.org/10.1016/j.athoracsur.2011.01.060>.
8. Redwan B, Ziegeler S, Freermann S, Nique L, Semik M, Lavae-Mokhtari M et al. Intraoperative venovenous extracorporeal lung support in thoracic surgery: a single-centre experience. *Interact Cardiovasc Thorac Surg.* Dec 2015; 21(6):766-772. <https://doi.org/10.1093/icvts/ivv253>.
9. Peek GJ, Mugford M, Tiruvoipati R, et al. Efficacy and economic assessment of conventional ventilatory support versus extracorporeal membrane oxygenation for severe adult respiratory failure (CESAR): a multicentre randomised controlled trial. *Lancet.* 17 Oct 2009; 374(9698):1351-1363. doi:10.1016/S0140-6736(09)61069-2.
10. Reis FPD, Costa AN, Lauricella LL, Terra RM, Pêgo-Fernandes PM. Intraoperative support with venovenous extracorporeal membrane oxygenation for complex thoracic oncologic resection. *J Bras Pneumol.* 20 Jan 2020; 46(1):e20180416. <https://doi.org/10.1590/1806-3713/e20180416>.