

Case Report

Primary tuberculous osteomyelitis of the mandible: A rare case report

J. Kannaperuman¹, Gowri Natarajarathinam², Anusha V. Rao³, Sudha Palanimuthu⁴

¹Director, ³Consultant Orthodontist, ⁴Consultant Dental Surgeon, Nala Dental Hospital, Madurai, ²Consultant Prosthodontist, Rajan Dental Institute, Chennai, India

ABSTRACT

Tuberculosis (TB) has become a rare disease in the developed countries but it is still a serious problem in developing countries. Incidence of tuberculous osteomyelitis of the jaw bones is very low. This rare incidence is the primary reason that this lesion gets mis-diagnosed many times. Here we report the diagnosis, treatment and follow-up of a case, which is a classical presentation of tuberculous osteomyelitis of mandible. Primary tuberculous osteomyelitis is a very rare entity but in the recent times, increased incidence of TB as a coinfection of HIV, has posed a big challenge in developing countries. If not diagnosed, at the right time, this can lead to serious complications like internal organ damage, tuberculous meningitis etc., Early diagnosis of tuberculous osteomyelitis will certainly reduce the morbidity of this disease condition.

Key Words: Osteomyelitis mandible, primary tuberculosis, tuberculous osteomyelitis

Received: July 2012

Accepted: January 2013

Address for correspondence:

Dr. Gowri Natarajarathinam,
Consultant Prosthodontics,
Rajan Dental Institute,
No. 56, RK Salai,
Mylapore, Chennai,
Tamil Nadu, India.
E-mail: gowri.nat@gmail.com

INTRODUCTION

Tuberculosis (TB) has become a rare disease in the developed countries, but it remains a serious problem in developing countries. A report says that every year, about 20 million prevalent cases and 8 million new cases are reported. WHO has documented that approximately 3 million people die annually of TB, and this is more common in developing countries.^[1] TB is a dangerous disease, and the resurgence of this disease has been an issue as it is associated with HIV infection. This is otherwise called latent TB. TB presents itself in two forms, primary and secondary. Primary occurs through direct infection and secondary through lymph nodes. Osteomyelitis caused by TB is very rare. Incidence of tuberculous osteomyelitis of the jaw bones is very low.^[2-6] This rare incidence is the primary reason that this lesion gets misdiagnosed often. Herein we have reported the diagnosis,

treatment, and follow-up of a case, which is a classical presentation of tuberculous osteomyelitis of mandible.

CASE REPORT

A 13-year-old female of Asian Indian origin reported to our hospital for evaluation of swelling and pain on the right side submandibular region of the face. History obtained from the parents revealed that the swelling was present for past 2 months. The patient was prescribed multiple courses of antibiotics, but there was no significant improvement. The patient was moderately built, nourished, and afebrile at the time of examination. The patient gave a history of generalized weakness, weight loss for 2 months, and pain associated with the swelling.

General physical and systemic examinations did not give any significant diagnostic information. Extra oral examination revealed a unilateral diffuse solitary swelling over the right submandibular region of mandible measuring 2 × 3 cm in size. The overlying skin was normal in color, but swelling was tender on palpation with a discharging sinus [Figure 1]. On pressing the swelling, thick yellow pus discharge with blood was noticed. Margins of sinus opening were hyperemic. Multiple cervical lymph nodes

Access this article online



Website: <http://drj.mui.ac.ir>

on the right submandibular group of lymph nodes were enlarged and tender. A panoramic radiograph revealed an ill-defined, radiolucent, osteolytic lesion surrounding the developing right permanent second molar [Figure 2]. A provisional diagnosis of residual chronic dento alveolar abscess was made, while the differential diagnosis included tuberculous osteomyelitis of mandible or malignant bone tumor.

Her chest radiograph did not reveal any evidence of TB [Figure 3]. Hematological finding included WBC counts of 8800 cells/mm³ and Hb of 11.50 gm/dl. Erythrocyte sedimentary rate raised to 38 mm and Mantoux test was 10 × 10 mm. Her serum HIV test was negative. Magnetic resonance imaging of neck showed evidence of osteomyelitis of right mandible involving the inferior margin of distal body of the mandible (from 2nd molar root abscess) [Figures 4-6]. The length of the tract measured 2.34 cm and thickness was 0.6 cm. Computed tomography (CT) scan showed

enlarged submandibular lymph nodes measuring 1 × 1 cm (nonspecific lymphadenitis).

Fine needle aspiration cytology of the swelling was also performed. A typical caseous material with white cheesy appearance was aspirated, which on microscopic examination demonstrated necrotic calls, a large number of neutrophils, few lymphocytes, and few clusters of epitheloid cells, suggesting tuberculoid or caseating granuloma. Right submandibular lymphadenopathy was also noted. Based on the above clinical findings, corroborated by history and various investigations, a diagnosis of primary tuberculous osteomyelitis of mandible was made.

Sinus tract excision with scooping of the cavity was done under local anesthesia. An extraoral submandibular incision was given to approach the mandible in the affected site. Necrotized bone was found distal to 46, involving the body of mandible with sequestrum formation in the angle area. The lesion was surgically drained and curetted and sent for histopathological examination.

The patient was started on standard antitubercular chemotherapy (2HRZE/4HR). The dosage was INH

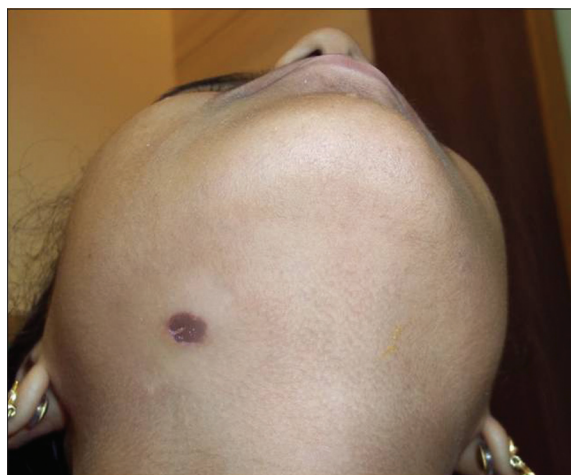

Figure 1: Extra-oral sinus opening

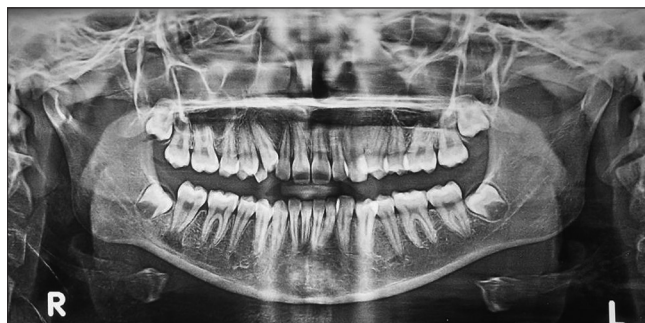

Figure 2: Pre-treatment OPG

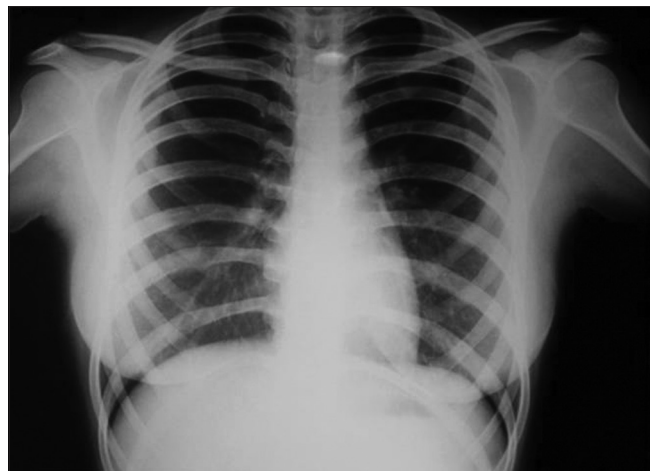


Figure 3: Chest X-ray (No signs of pulmonary TB)

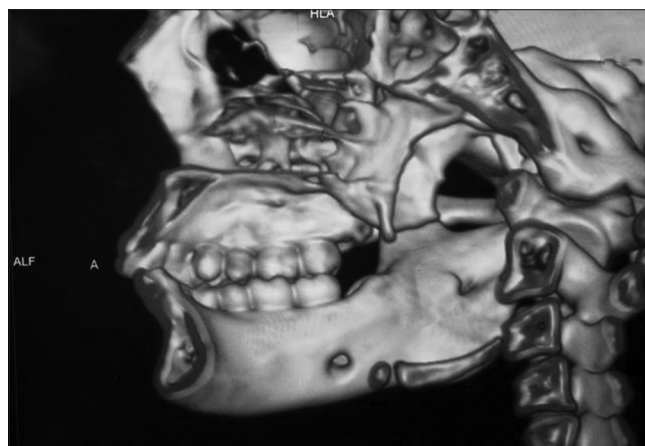


Figure 4: MRI showing osseous defect in mandible

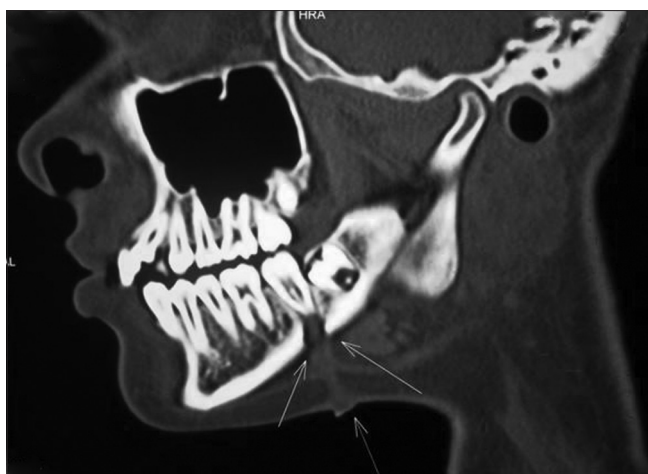


Figure 5: MRI showing osseous defect in mandible

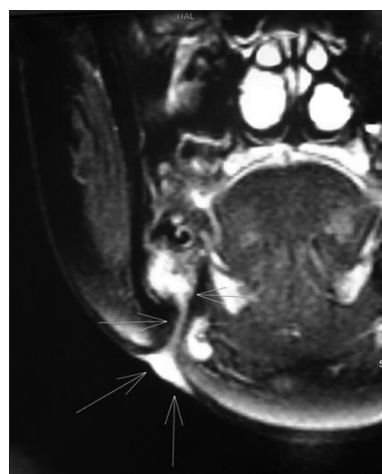


Figure 6: MRI showing osseous defect in mandible

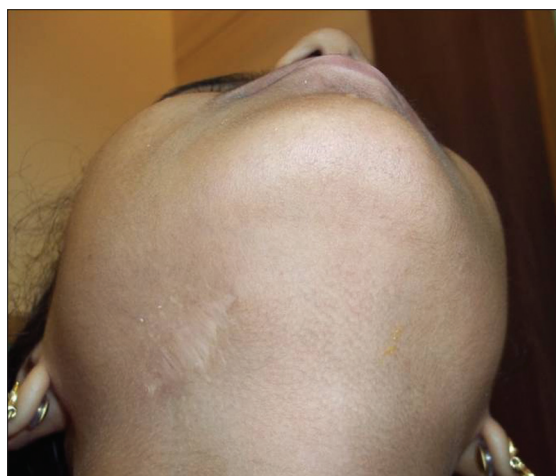

Figure 7: Complete healing post treatment

75 mg, rifampicin 150 mg, ethambutol 275 mg, and pyrazinamide 400 mg. After 2 months of therapy, she improved markedly with decrease in swelling. Panoramic radiograph shows radio-opacity in relation to 47 (bone formation). She is under regular follow-up with continuation of AKT [Figure 7].

DISCUSSION

Oral lesions of TB are not common, but have a spectrum of manifestations. Most common symptoms of tuberculous infection that occur in the oral cavity are ulcers, granulomas, pain and swelling, loosening of tooth, and displacement of tooth buds.^[7,8] Occasionally, the salivary glands and the temporo-mandibular joint is also involved. The incidence of TB in the jaw bones is very low, with mandible having a higher frequency than maxilla.^[9] The common route of infection according to Chaudhary *et al.*, open pulp of a carious

tooth, an extraction socket or perforation of a newly erupting tooth that can be exposed to infected sputum.^[1] It can also be an extension of the soft tissue lesion above the bone or hematogenous transfer.

In this case, the chest X-ray did not show any pulmonary infection. It is then speculated the infection may have been a spread from the recent extraction or an exacerbation of a latent infection due to any history of trauma. Radiographically, TB lesions does not present in a specific form. It appears as a blurry radiolucency with erosion of cortex.^[10,11] The bone is gradually replaced by granulomatous tissue. Until it presents as an intra or extra oral sinus, the lesion remains as a painless swelling or a cold abscess. This makes it even more important to diagnose, as there has been even conditions like pathological fracture of mandible reported earlier. Because of low index of suspicion, tuberculous lesion is often neglected or misdiagnosed.

CONCLUSION

Primary tuberculous osteomyelitis is a very rare entity, but, in the recent times, increased incidence of TB as a co-infection of HIV poses a big challenge in developing countries. If not diagnosed at the right time, this can lead to serious complications like internal organ damage and tuberculous meningitis. Early diagnosis of tuberculous osteomyelitis will certainly reduce the morbidity of this disease condition.

REFERENCES

1. Chaudhary S, Kalra N, Gomber S. Tuberculous osteomyelitis of the mandible: A case report in a 4-year old child. *Oral Surg Oral Med Oral Pathol Oral Radiol Endod* 2004;97:603-6.

2. Hock-Liew E, Shin-Yu L, Chuang-Hwa Y, Wei-Jen C. Oral tuberculosis. *Oral Surg Oral Med Oral Pathol Oral Radiol Endod* 1996;81:415-20.
3. Gupta MK, Singh M. Primary tuberculosis of mandible. *Indian Pediatr* 2007;44:53-4.
4. Dinkar AD, Prabhudessai V. Primary tuberculous osteomyelitis of the mandible: A case report. *Dentomaxillofac Radiol* 2008;37:415-20.
5. Chapotel S. Tuberculose mandibulaire. *Rev Odont* 1930;51:444-5.
6. Bhatt AP, Jayakrishnan A. Tuberculous osteomyelitis of the mandible: A case report. *Int J Paediatr Dent* 2001;11:304-8.
7. Darlington CC, Salman I. Oral tuberculous lesions. *Am Rev Tuberc* 1937;35:147-9.
8. Tanchester D, Sarin S. Dental lesions in relation to pulmonary tuberculosis. *J Dent Res* 1937;16:69-70.
9. Gupta KB, Manchanda M, Yadav SPS, Mittal A. Tubercular osteomyelitis of mandible. *Indian J Tuberc* 2005;52:147-50.
10. Fukuda J, Shingo Y, Miyako H. Primary tuberculous osteomyelitis of the mandible. A case report. *Oral Surg Oral Med Oral Pathol* 1992;73:278-80.
11. Meng CM. Tuberculosis of the mandible. *J Bone Joint Surg Am* 1940;22:17-27.

How to cite this article: Kannaperuman J, Natarajathinam G, Rao AV, Palanimuthu S. Primary tuberculous osteomyelitis of the mandible: A rare case report. *Dent Res J* 2013;10:283-6.

Source of Support: Nil. **Conflict of Interest:** None declared.