

# NEUROPATHY, ATAXIA, AND RETINITIS PIGMENTOSA SYNDROME: A MULTIDISCIPLINARY DIAGNOSIS

Leire Juaristi, MD, Cristina Irigoyen, MD, PhD, Jorge Quiroga, MD

**Purpose:** To report a case of neuropathy, ataxia, and retinitis pigmentosa syndrome, a rare and undiagnosed disease in ophthalmology due to the need for multidisciplinary evaluation.

**Methods:** Multimodal testing was performed, including neurologic, ophthalmologic, and genetic assessments. The neurologic tests comprised electromyogram and muscle biopsy; the ophthalmologic examination consisted of slit-lamp and fundus examinations, optical coherence tomography, visual field testing, and electrophysiology tests such as a full-field electroretinogram and multifocal electroretinogram; and genetic tests were performed for spinocerebellar ataxia. In addition, the patient underwent magnetic resonance imaging, an electrocardiogram, cerebrospinal fluid analysis with lactate levels, and a blood workup including antineuronal, antithyroid peroxidase, antinuclear, antimitochondrial, and antitransglutaminase antibodies and fat-soluble vitamins (A, D, E, K).

**Results:** The ocular fundus examination showed bone spicules with retinal pigment epithelium alteration, optic nerve pallor, and arterial attenuation. Optical coherence tomography demonstrated macular atrophy. Visual field testing revealed concentric reduction. Electrophysiology examinations showed involvement of rods and cones in both eyes. The muscle biopsy was compatible with mitochondrial disease, and electromyogram demonstrated sensory axonal damage. However, genetic tests for spinocerebellar ataxia were negative. Magnetic resonance imaging showed cerebellar atrophy, whereas the electrocardiogram did not detect any abnormalities. Cerebrospinal fluid lactate levels were above normal but antibody levels in blood were normal.

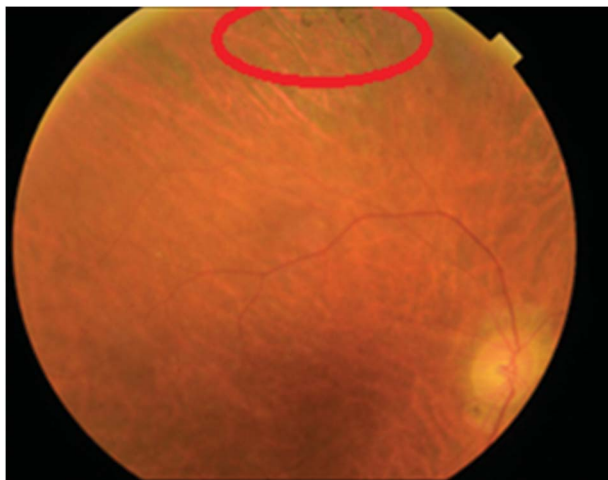
**Conclusion:** This is the first report of macular atrophy demonstrated by optical coherence tomography in a patient with neuropathy, ataxia, and retinitis pigmentosa syndrome. For the diagnosis, a multidisciplinary team including a neurologist, a geneticist, and an ophthalmologist was essential. Patients with suspected mitochondrial disease could greatly benefit from an ophthalmology examination like that conducted in this case because it was the key factor that led to the suspicion of syndromic disease, and ultimately the diagnosis.

**RETINAL CASES & BRIEF REPORTS** 15:486–489, 2021

*From the Department of Ophthalmology, Donostia University Hospital, Donostia - San-Sebastian, Spain.*

Neuropathy, ataxia, and retinitis pigmentosa (NARP) syndrome is a progressive neurodegenerative disorder caused by abnormalities in mitochondrial energy generation. Clinical symptoms can be heterogeneous. It is considered a rare disease due to its low incidence rate, which is

unknown but, according to “Orphanet,” is estimated to be approximately 1 to 9 per 100,000. This report illustrates a case of NARP diagnosis in a patient who presented with nyctalopia and neurologic disease referred for an ophthalmologic examination, and NARP syndrome was suspected after this examination. Specifically, macular atrophy was seen in optical coherence tomography, a previously unreported sign in a patient with this syndrome.



**Fig. 1.** Retinal pigment epithelium alteration with round pigment clumps in the midperiphery, papillary pallor, and arteriolar attenuation.

### Case Report

A 53-year-old male patient was diagnosed with cerebellar syndrome (dysarthria, nystagmus, and ataxia) in 2008 and with sensorineural hearing loss in 2009. There was no family history of other neurologic disease or deafness. Initially, a complete study was performed with a single finding of cerebellar atrophy on the brain magnetic resonance imaging. The genetic testing was negative for spinocerebellar ataxia, and levels of cerebrospinal fluid lactate, antibodies (antineuronal, antithyroid peroxidase, antinuclear, antimitochondrial, and antitransglutaminase), and fat-soluble vitamins (A, D, E, and K), and electrocardiogram findings were normal.

Two years later, the patient showed worsening symptoms with dysdiadochokinesia, hyporeflexia in the lower limbs, and alteration of the deep sensitivity of feet with bilateral Babinski signs. Due to this, the diagnosis of cerebellar syndrome was reconsidered, and complementary tests were performed, suspecting late-onset Friedreich ataxia. The molecular genetic study performed to rule out Friedreich ataxia (FXN gene mutations) was negative. Nevertheless, this time, the cerebrospinal fluid analysis showed a slight increase in lactate levels. Electromyogram findings were compatible with sensory axonal polyneuropathy and the muscle biopsy to rule out mitochondrial disease was suggestive of this type of disease. At this stage, the patient was referred to the ophthalmology department for nyctalopia.

The patient had 20/25 corrected Snellen visual acuity in both eyes. The eye fundus showed retinal pigment epithelium alteration with round pigment clumps in the midperiphery (circles in Figures 1 and 2), retinal pigment epithelium macular alteration

with papillary (optic nerve) pallor, and arteriolar attenuation (Figure 1).

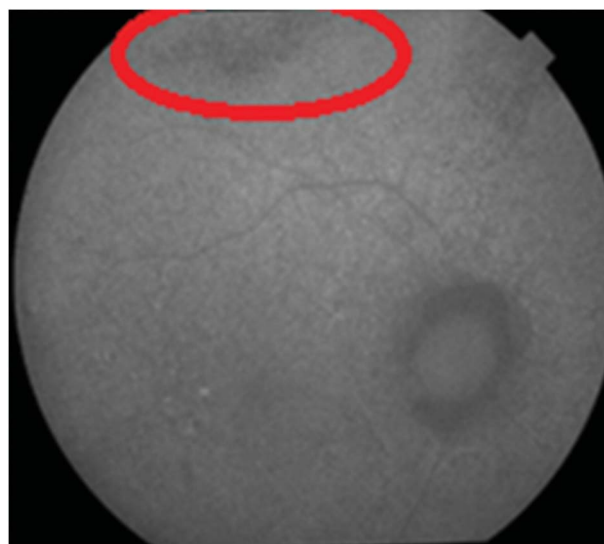
Autofluorescence imaging revealed hyperautofluorescence and hypoautofluorescence granular patterns in the posterior pole and vascular arcades. Optical coherence tomography showed generalized macular atrophy (Figure 3). The visual field test confirmed a concentric reduction in visual field, and the 20 central degrees of vision remaining largely intact, compatible with the patient's nyctalopia (Figure 4).

Suspecting retinitis pigmentosa, complementary examinations were conducted in the ophthalmology department. The electrophysiological study showed a diffuse alteration in both retinas, including the cone and rod systems from moderate to severe degree. The "a" and "b" wave amplitudes were severely reduced (Figures 5 and 6). Based on these findings, we were able to confirm the diagnosis of retinitis pigmentosa.

### Discussion

The neurologic and ophthalmologic findings in our case are compatible with NARP syndrome (neurogenic muscular weakness, ataxia, and retinitis pigmentosa) due to a progressive neurodegenerative disorder caused by abnormalities in mitochondrial energy generation. Nonetheless, in such cases, it may be that the only symptoms are visual ones, and this must be taken into account when making the differential diagnosis.

MT-ATP6 is the only gene related to NARP syndrome. The m.8993T > C/G mutation is the most prevalent, described by Thorburn et al.<sup>1</sup> Nowadays, several mutations are known to cause the syndrome: m.8839G > C,<sup>2</sup> m.8989 G > C,<sup>3</sup> m.8618insT, p.Thr33Hisfs\*32,<sup>4</sup> and 9185T > C.<sup>5</sup> If no variant of pathogenic MT-ATP6 is identified, however, mitochondrial genome analysis should be performed.<sup>5</sup>

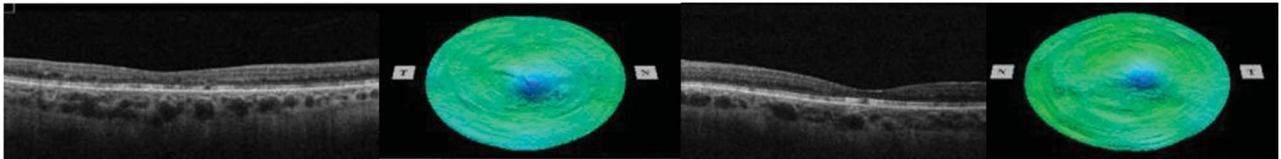


**Fig. 2.** Hyperautofluorescence and hypoautofluorescence granular patterns in posterior pole.

None of the authors has any financial/conflicting interests to disclose.

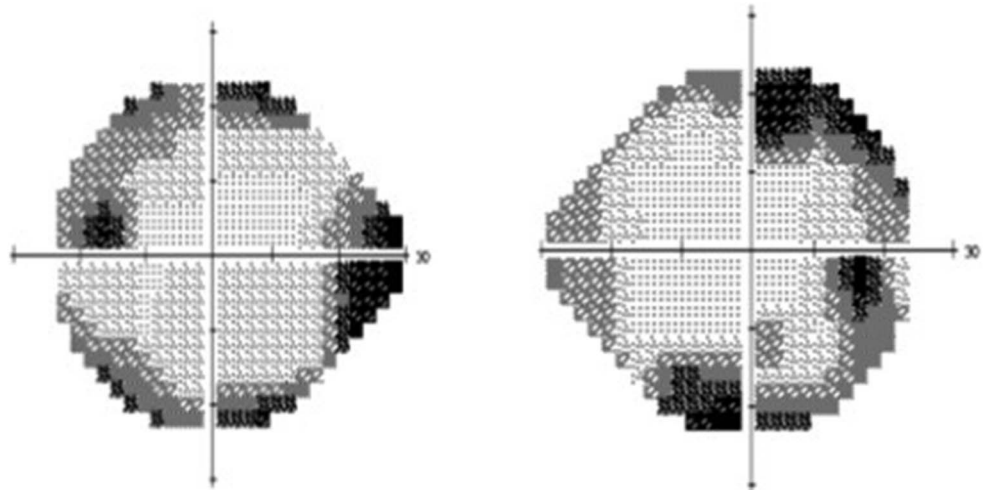
Reprint requests: Leire Juaristi, MD; e-mail: ljuaristi001@gmail.com

This is an open-access article distributed under the terms of the Creative Commons Attribution-Non Commercial-No Derivatives License 4.0 (CCBY-NC-ND), where it is permissible to download and share the work provided it is properly cited. The work cannot be changed in any way or used commercially without permission from the journal.

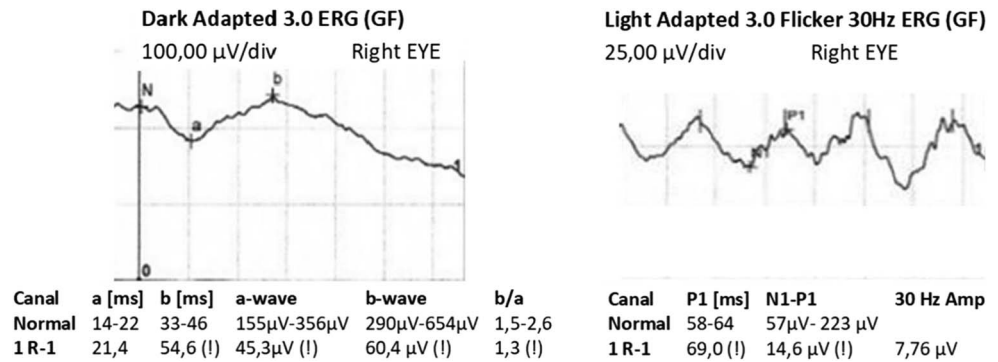


**Fig. 3.** Macular optical coherence tomography of both eyes: generalized macular atrophy with greater thinning in the outer nuclear layers and a defect in the ellipsoid zone. The outer limiting membrane is intact.

**Fig. 4.** Visual field testing of both eyes (24: 2): concentric decrease, leaving 20 central degrees largely intact, compatible with nyctalopia.



**Fig. 5.** Full-field electroretinogram of the right eye: significant decrease in rod response amplitude, with slight delay in the latency as well as in the combined response. Photopic response shows a moderate amplitude decrease.



There is no specific treatment for NARP syndrome. It is important that individuals affected are monitored (every 6–12 months) to detect progression and the appearance of any new symptoms.

**Conclusion**

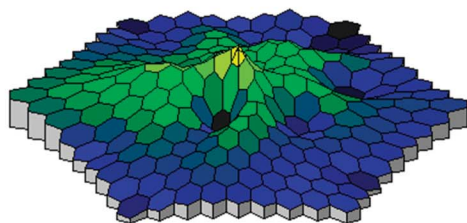

Many patients with suspicion of mitochondrial disease could benefit from a fundus examination as performed in this case because it yielded the key findings that led us to suspect NARP syndrome.

Optical coherence tomography revealed macular atrophy, a previously unreported sign in a patient with this syndrome.

The multidisciplinary diagnosis was fundamental, and achieved through collaboration between the neurology, ophthalmology, and genetics departments. We also believe that it is necessary to perform MT-ATP6 gene sequencing in patients with NARP syndrome when the gene is not identified.

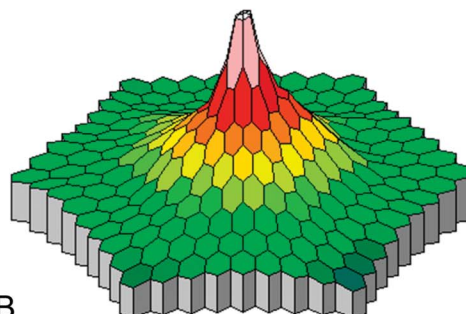

**Key words:** mitochondrial disease, NARP syndrome, retinitis pigmentosa.

3D Amplitudes P1

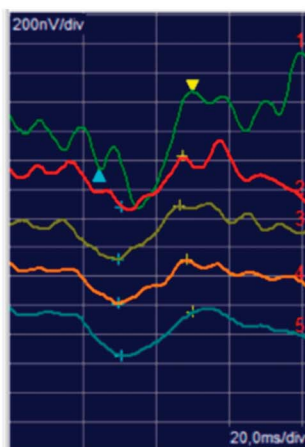


A

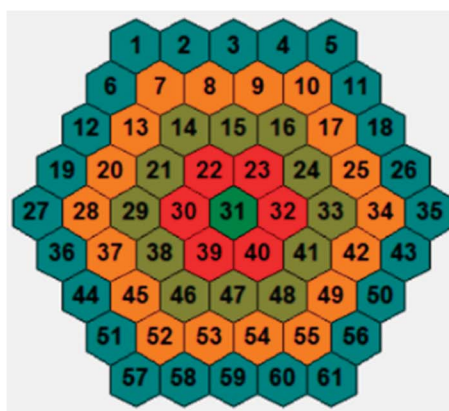
3D Amplitudes P1 (Normal DB)



B



C



**Fig. 6.** **A.** Multifocal electroretinogram of our patient. **B.** Normal multifocal electroretinogram. **C.** Response density in the rings of our patient, showing a marked decrease in response density in Rings 3, 4, and 5, and greater preservation of the P1 amplitude in the central rings, although a moderate decrease in response density was also observed in this region.

References

1. Thorburn DR, Rahman J, Rahman S. Mitochondrial DNA-associated Leigh syndrome and NARP. In: Adam MP, Ardinger HH, Pagon RA, et al, eds. GeneReviews [Internet]. Seattle, WA: University of Washington, Seattle; 2003:1993–2018. Available at: <http://www.ncbi.nlm.nih.gov/books/NBK1173/>. Accessed September 28, 2017.
2. Blanco-Grau A, Bonaventura-Ibars I, Coll-Cantí J, et al. Identification and biochemical characterization of the novel mutation m.8839G>C in the mitochondrial ATP6 gene

- associated with NARP syndrome. *Genes Brain Behav* 2013;12:812–820.
3. Duno M, Wibrand F, Baggesen K, et al. A novel mitochondrial mutation m.8989G>C associated with neuropathy, ataxia, retinitis pigmentosa—the NARP syndrome. *Gene* 2013;515:372–375.
4. López-Gallardo E, Emperador S, Solano A, et al. Expanding the clinical phenotypes of MT-ATP6 mutations. *Hum Mol Genet* 2014;23:6191–6200.
5. Pitceathly RD, Murphy SM, Cottenie E, et al. Genetic dysfunction of MT-ATP6 causes axonal Charcot-Marie-Tooth disease. *Neurology* 2012;79:1145–1154.