



Case Report

Helicobacter cinaedi-infected chronic subdural hematoma mimicking an expanding hematoma: A case report

Tomoaki Akiyama, Hirotochi Imamura, Nobuyuki Fukui, Nobuyuki Sakai

Department of Neurosurgery, Kobe City Medical Center General Hospital, Kobe, Hyogo, Japan.

E-mail: *Tomoaki Akiyama - akiyama.tomoaki@gmail.com; Hirotochi Imamura - i-hiro@zg7.so-net.ne.jp; Nobuyuki Fukui - nfukui@kuhp.kyoto-u.ac.jp; Nobuyuki Sakai - n.sakai@siren.ocn.ne.jp



*Corresponding author:

Tomoaki Akiyama,
Department of Neurosurgery,
Kobe City Medical Center
General Hospital, Kobe, Hyogo,
Japan.

akiyama.tomoaki@gmail.com

Received : 20 April 2021

Accepted : 18 May 2021

Published : 14 June 2021

DOI

10.25259/SNI_387_2021

Quick Response Code:



ABSTRACT

Background: We present the rare case of a spontaneous intracranial subdural empyema caused by *Helicobacter cinaedi* in a preexisting chronic subdural hematoma (CSDH).

Case Description: A 72-year-old man with a history of the right CSDH that remained radiologically unchanged for the past 2 years with conservative management was transferred to our hospital because of fever and convulsive seizure. Systemic sources of infection were not identified. Fever and extremely high levels of serum C-reactive protein (CRP) spontaneously improved without antibacterial therapy. One month after the fever disappeared, brain computed tomography (CT) showed an increase in CSDH size. Mildly elevated CRP levels persisted without fever. Interval changes in shape on CT and hyperintense signals on diffusion-weighted magnetic resonance imaging (DWI) within the CSDH were observed with no neurological deficits. Five months later, the patient underwent craniotomy for a progressively enlarged CSDH. An infected organized hematoma was found, and copious pus was evacuated. Subsequently, an infected subdural hematoma (ISH) was diagnosed. Although bacterial cultures of the purulent specimen were negative, *H. cinaedi* was identified by gene sequencing analysis. Six months post antibiotic therapy, the ISH was under control, and abnormal DWI signals disappeared.

Conclusion: To the best of our knowledge, this is the first report of ISH caused by *H. cinaedi*. This case suggests that ISH can follow a chronic course, mimicking the progressive expansion of subdural hematoma, and that *H. cinaedi* should be considered as a causative organism of ISH especially when conventional cultures are negative.

Keywords: Chronic subdural hematoma, *Helicobacter cinaedi*, Infected subdural hematoma, Subdural empyema

INTRODUCTION

Infected subdural hematoma (ISH) caused by hematogenous chronic subdural hematoma (CSDH) infection is a rare clinical entity of intracranial subdural empyema,^[4] and few reports are available on *Helicobacter cinaedi* central nervous system infections.^[1,7,12,14,15,18,20] *H. cinaedi* is an enterohepatic Gram-negative spiral bacillus, and infections with its pathogens have been attracting attention over the past two decades, especially in Japan.^[2,10] We present a case of subdural empyema in the preexisting CSDH, mimicking spontaneous hematoma enlargement in the chronic clinical course in an adult. This is the first report of *H. cinaedi*-associated ISH.

This is an open-access article distributed under the terms of the Creative Commons Attribution-Non Commercial-Share Alike 4.0 License, which allows others to remix, tweak, and build upon the work non-commercially, as long as the author is credited and the new creations are licensed under the identical terms.

©2021 Published by Scientific Scholar on behalf of Surgical Neurology International

CASE DESCRIPTION

A 72-year-old man with well-controlled type 2 diabetes mellitus, and an implantable cardioverter-defibrillator implantation for Brugada syndrome underwent regular follow-up computed tomography (CT) to evaluate asymptomatic right posttraumatic CSDH. The patient received no anticoagulant drugs. The CSDH remained unchanged over the past 2 years with conservative management.

After 10 days of intermittent fever, the patient was transferred to our hospital because of fever and subsequent seizure in the left upper extremity. On admission, the patient's temperature was 37.5 °C, and a blood test showed leukocyte levels of 7500/mm³ and C-reactive protein (CRP) levels of 33.26 mg/dL. Serological tests for human immunodeficiency virus were negative. The patient was not immunocompromised or had not been given immunosuppressive drugs. The brain CT image demonstrated no change in the right CSDH [Figure 1a], and contrast-enhanced CT of the chest and abdomen revealed no abnormal findings. Head magnetic resonance imaging (MRI) showed that the subdural hematoma was uniformly hypointense on diffusion-weighted imaging (DWI) and hyperintense with multiple intrahematoma loculations on fluid-attenuated inversion recovery (FLAIR) [Figure 1b and c]. The bacteriological examinations, including repeat blood cultures (3 times at 72 h) and urine culture, were negative, and fever and extremely high CRP levels gradually improved without antibacterial therapy. We concluded that a high fever with CSDH induced a low seizure threshold and the anticonvulsant drug with levetiracetam 1000 mg daily controlled the symptoms. After 1 month, the serum CRP level remained between 5 and 16 mg/dL without fever, and the superior component of the CSDH gradually increased in volume [Figure 1d]. After 5 months, the CSDH transformed into a biconvex shape on CT, and FLAIR and DWI demonstrated heterogeneous hyperintense signals corresponding to hematoma enlargement [Figure 2a-c]. A gadolinium-enhanced T1-weighted image showed a thickened enhancement of the hematoma capsule [Figure 2d]. Although the patient presented with no

neurological deficits, it was necessary to differentiate between the progressive expansion of the CSDH and ISH associated with high inflammatory marker levels. Craniotomy was undergone under general anesthesia. After the dural incision on the subdural mass, a thickened, hardened, and yellowish outer membrane of the hematoma capsule was observed. When the outer membrane was incised, pus was collected [Figure 3a], and a specimen was taken for the microbiological laboratories. Abscess cavity irrigation and drainage tube placement were performed. The inferior component of the subdural hematoma consisted of an organized hematoma [Figure 3b]. The inner membrane of the capsule strongly adhered to the underlying cerebral cortex. The organized hematoma and hematoma capsule were not removed to prevent injury to the cortex and spread the infection into the extracapsular subdural space. The definitive diagnosis was intracranial subdural empyema with organized CSDH. Histopathological analysis of the outer membrane of the hematoma capsule revealed fibrous hypertrophy and inflammatory changes. Gram staining of the pus showed no bacteria. Considering the chronic course and negative Gram stain results, the attenuated strain of bacteria was determined to be the causative organism, and the patient started on an antibiotic regimen of intravenous cefazoline (2 g every 12 h). One day postoperatively, MRI revealed near-complete disappearance of the DWI hyperintense lesion within the CSDH [Figure 4a] and no extracapsular perforation of the infection. However, on postoperative day 10, despite the purulent specimen cultures showing no bacterial strain growth, *H. cinaedi* was detected by broad range 16S ribosomal RNA gene polymerase chain reaction (PCR) combined with sequencing from the pus. Cefazoline was exchanged for intravenous ceftriaxone (2 g every 24 h). The pus and swab culture observation period was extended to 14 days, and no growth of *H. cinaedi* was observed. Drainage for 10 days and antibiotic intravenous infusion therapy for 4 weeks resulted in normal serum CRP levels [Figure 4b and 5]. The patient was discharged without neurological sequelae and continued to receive oral minocycline (200 mg every 12 h), leading to complete resolution of the subdural empyema 6 months postsurgery [Figure 4c-d].

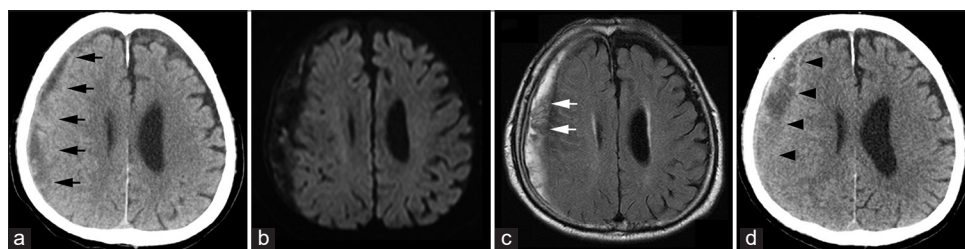


Figure 1: (a) Head computed tomography (CT) shows right chronic subdural hematoma (CSDH) (black arrows). (b and c) Magnetic resonance imaging demonstrates uniform hyperintensity on diffusion-weighted imaging and hyperintensity with intrahematoma membrane structures on fluid-attenuated inversion recovery (white arrows). (d) One-month follow-up CT after the abatement of fever indicates a slight increase (black arrowheads) in the CSDH size.

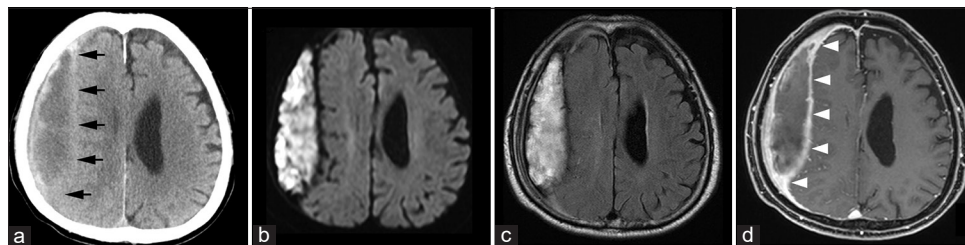


Figure 2: (a) Head computed tomography reveals a further increase in volume and a biconvex shape of the chronic subdural hematoma (black arrows). (b and c) Magnetic resonance imaging demonstrates an expanding subdural hematoma with no surrounding edema on fluid-attenuated inversion recovery and heterogeneous hyperintense signals corresponding to the expansive component of the subdural hematoma on diffusion-weighted imaging. (d) Postgadolinium T1-weighted image shows enhancement of the thickened hematoma capsule (white arrowheads).

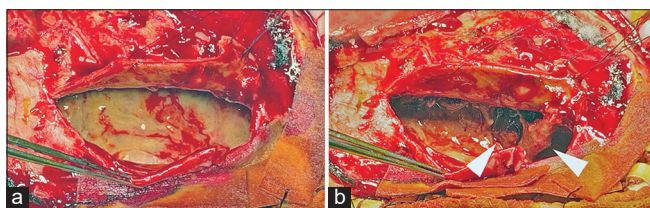


Figure 3: Intraoperative images. (a and b) After opening the thick outer membrane of the capsule, a large amount of yellowish purulent pus was observed followed by an organized hematoma (white arrowheads).

DISCUSSION

The present case has two clinically important points. First, subdural empyema developed in the preexisting CSDH and followed a chronic course without neurological deficits. Second, *H. cinaedi* central nerve system infections should be considered, especially in conventional culture-negative cases.

CSDH is a common disease in neurosurgical practice, while ISH in adults is clinicopathological rare, with only 41 reports available in the literature.^[3,4,9,19] ISH acquires an infection hematogenously through the hematoma capsule of a preexisting CSDH as opposed to a typical intracranial subdural empyema, which develops through the direct extension of neurosurgical procedures, sinusitis, otitis media, mastoiditis, and skull trauma.^[4] Although ISH shows heterogeneous patterns on CT and MRI, the hyperintensity within the hematoma on DWI and biconvex shape of the hematoma on CT can help diagnose an infected hematoma.^[4,13,19] In our case, we presumed that the infection spreads from the bacteremia to the subdural hematoma capsule. However, there was no distinct bacteremia source or specific changes in the hematoma shape on CT or the intracapsular hyperintensity on DWI during the first admission, suggesting that the patient had not developed ISH at this time. Considering the spontaneous improvement of fever and elevation of the CRP level without antibiotic therapy, the host immune response possibly resolved the bacteremia,

but the lack of a prompt antibiotic treatment may have led to bacterial hematogenous dissemination to the CSDH capsule. The interval changes in shape on CT and the signals on DWI within the subdural lesion in subsequent months indicated that the preexisting CSDH transformed into an empyema. ISH commonly presents with rapid progression and with a high mortality rate.^[4] Thickened and hardened encapsulation of the hematoma due to inflammatory changes reportedly prevented the infection from spreading into the arachnoid membrane and brain parenchyma, resulting in focal infection and mild symptoms.^[6,19] Compared to the previous reports,^[3,4,9,19] our case followed a chronic course with the longest duration with no neurological deficits. Consequently, it was difficult to differentiate an infectious hematoma from a spontaneous hematoma expansion preoperatively.

H. cinaedi is an enterohepatic Gram-negative spiral bacillus first reported by Fennell *et al.* in 1984.^[5] Initial reports showed an association between *H. cinaedi* and an immunocompromised host. However, recently, this pathogen was detected among immunocompetent patients with skin, enteric, or bloodstream infections with a prevalence rate of 0.06–0.25% in all blood cultures and 0.22–2.2% in blood culture-positive cases in Japan.^[2,10] To date, the frequency of *H. cinaedi* infection globally is unknown. The vast majority of the literature reporting this pathogen over the past two decades originated from Japan, and there are no data to explain the difference in occurrences of *H. cinaedi* infection between Japan and other parts of the world. Detecting *H. cinaedi* infection by conventional culture methods is difficult because this organism generally requires a relatively prolonged incubation time and a particular culture system.^[8,10,11,16] Thus, identifying *H. cinaedi* using PCR is recommended for a definitive diagnosis.^[8,17,18] In our case, each blood culture observation period (three cultures) was 7 days, and blood was not tested using PCR during the first admission. Thus, we might have overlooked *H. cinaedi* bacteremia. Finally, *H. cinaedi* was detected as the causative organism by PCR analysis of the pus samples from the surgical specimens but not by culture, despite no prior antimicrobial exposure.

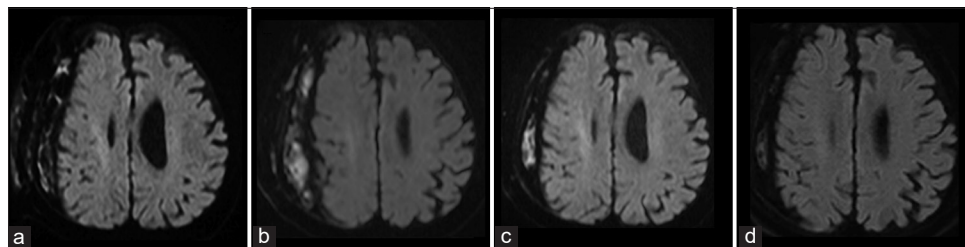


Figure 4: Head diffusion-weighted magnetic resonance imaging confirms a gradual decrease in the hyperintense signals (indicating the abscess) and, finally, the complete disappearance of the infected subdural hematoma. (a) Two days after surgery, (b) 1 month later, (c) 3 months later, and (d) 6 months later.

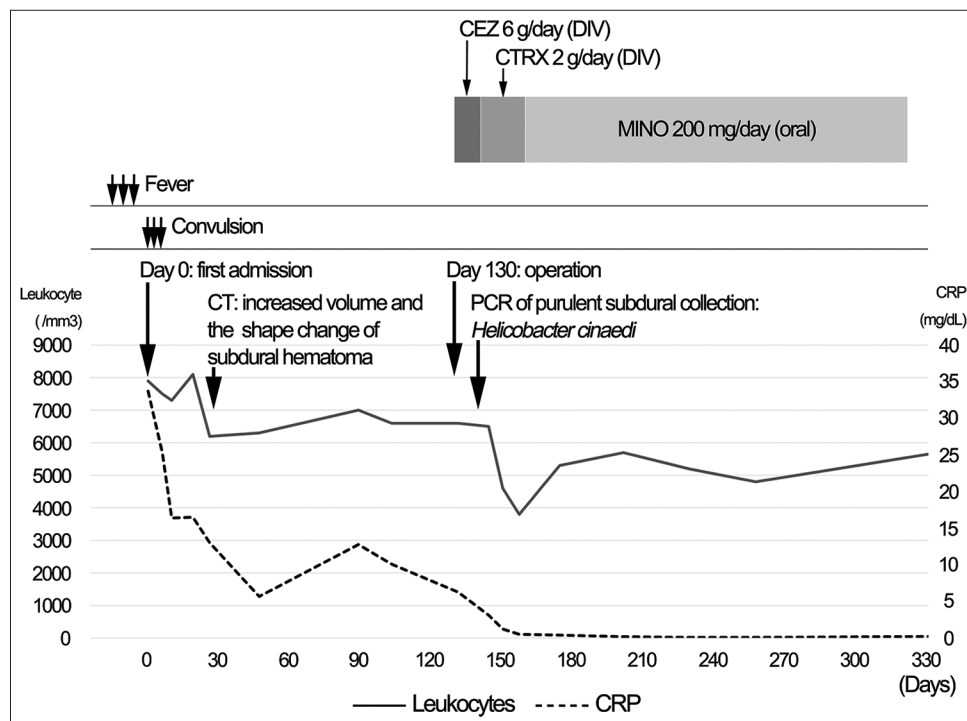


Figure 5: The clinical course of the patient. CEZ: Cefazolin, DIV: Drip infusion in vein, CTRX: ceftriaxone, MINO: Minocycline, CT: Computed tomography, PCR: Polymerase chain reaction, CRP: C-reactive protein.

Regarding *H. cinaedi* central nervous system infections, seven reports have been published, including a case of subdural empyema.^[1,7,12,14,15,18,20] To the best of our knowledge, this is the first report of an ISH caused by *H. cinaedi*.

The optimal surgical strategy for ISH has not been clarified because of its rarity.^[4] Craniotomy was selected considering the organized expansive CSDH and ISH as a differential diagnosis and consequently allowed for maximal drainage. Standardized treatment of the antibiotic regimen and duration against *H. cinaedi* has also yet been established. DWI can help monitor the therapeutic response in the ISH.^[13] Because the cultures had no microorganisms, the antibacterial regimen was determined based on previous literature that provided *H. cinaedi* antimicrobial susceptibility testing

results in Japan.^[8] After identifying *H. cinaedi* as the ISH causing pathogen, we chose a 3-week course of antibiotherapy with intravenous ceftriaxone, followed by 20 weeks of oral minocycline until the DWI hyperintense signals within CSDH corresponding to the abscess completely disappeared.

CONCLUSION

We describe a rare case of *H. cinaedi* infection in a preexisting CSDH. ISH can follow a chronic course with mild inflammatory markers, mimicking spontaneous hematoma expansion. In addition, *H. cinaedi* should be a suspected pathogen, especially when conventional cultures of blood or surgical specimens fail.

Declaration of patient consent

The authors certify that they have obtained all appropriate patient consent.

Financial support and sponsorship

Nil.

Conflicts of interest

There are no conflicts of interest.

REFERENCES

- Abiko S, Nakamura I, Yamaguchi Y, Ohkusu K, Hirayama Y, Matsumoto T. The first case report of cerebral cyst infection due to *Helicobacter cinaedi*. *Jpn J Infect Dis* 2017;70:210-12.
- Araoka H, Baba M, Kimura M, Abe M, Inagawa H, Yoneyama A. Clinical characteristics of bacteremia caused by *Helicobacter cinaedi* and time required for blood cultures to become positive. *J Clin Microbiol* 2014;52:1519-22.
- Brin C, Sougakoff W, Bielle F, Abi Jaoude S, Bonnet I, Haddad E, et al. Unusual subdural empyema in a homeless patient diagnosed by molecular approach: A case report. *BMC Infect Dis* 2020;20:357.
- Dabdoub CB, Adorno JO, Urbano J, Silveira EN, Orlandi BM. Review of the management of infected subdural hematoma. *World Neurosurg* 2016;87:663.e661-8.
- Fennell CL, Totten PA, Quinn TC, Patton DL, Holmes KK, Stamm WE. Characterization of *Campylobacter*-like organisms isolated from homosexual men. *J Infect Dis* 1984;149:58-66.
- Hamada J, Ichimura H, Ushio Y. Huge subdural empyema with unusual presentation in infant-case report. *Neurol Med Chir (Tokyo)* 1993;33:40-3.
- Hayashi T, Tomida J, Kawamura Y, Yoshida M, Yokozawa I, Kaneko S. Unusual manifestation of *Helicobacter cinaedi* infection: A case report of intracranial subdural empyema and bacteremia. *BMC Infect Dis* 2017;17:40.
- Kawamura Y, Tomida J, Morita Y, Fujii S, Okamoto T, Akaike T. Clinical and bacteriological characteristics of *Helicobacter cinaedi* infection. *J Infect Chemother* 2014;20:517-26.
- Konno T, Yamada K, Kasahara S, Umeda Y, Oyake M, Fujita N. Transformation from chronic subdural hematoma into subdural empyema following cat bites: A case report. *Rinsho Shinkeigaku* 2015;55:657-60.
- Matsumoto T, Goto M, Murakami H, Tanaka T, Nishiyama H, Ono E, et al. Multicenter study to evaluate bloodstream infection by *Helicobacter cinaedi* in Japan. *J Clin Microbiol* 2007;45:2853-7.
- Miyake N, Chong Y, Nishida R, Nagasaki Y, Kibe Y, Kiyosuke M, et al. A dramatic increase in the positive blood culture rates of *Helicobacter cinaedi*: The evidence of differential detection abilities between the Bactec and BacT/Alert systems. *Diagn Microbiol Infect Dis* 2015;83:232-3.
- Morikawa M, Hirabayashi K, Akagawa D, Ishida T. A case of neonatal meningitis caused by *Helicobacter cinaedi*. *J Jpn Soc Neonatal Health Dev* 2020;32:98-102.
- Narita E, Maruya J, Nishimaki K, Heianna J, Miyauchi T, Nakahata J, et al. Case of infected subdural hematoma diagnosed by diffusion-weighted imaging. *Brain Nerve* 2009;61:319-23.
- Okubo H, Goto M, Sato M, Sugiyama T, Kawano M, Matsunaga T, et al. *Helicobacter cinaedi* meningitis: A case report and review of previous cases. *J Neurol Sci* 2014;347:396-7.
- Orlicek SL, Welch DF, Kuhls TL. Septicemia and meningitis caused by *Helicobacter cinaedi* in a neonate. *J Clin Microbiol* 1993;31:569-71.
- Oyama K, Khan S, Okamoto T, Fujii S, Ono K, Matsunaga T, et al. Identification of and screening for human *Helicobacter cinaedi* infections and carriers via nested PCR. *J Clin Microbiol* 2012;50:3893-900.
- Rampini SK, Bloemberg GV, Keller PM, Buchler AC, Dollenmaier G, Speck RF, et al. Broad-range 16S rRNA gene polymerase chain reaction for diagnosis of culture-negative bacterial infections. *Clin Infect Dis* 2011;53:1245-51.
- Sugiyama A, Mori M, Ishiwada N, Himuro K, Kuwabara S. First adult case of *Helicobacter cinaedi* meningitis. *J Neurol Sci* 2014;336:263-4.
- Tamai S, Watanabe T, Ichinose T, Murakami KI, Ueno M, Munemoto S, et al. Morphological characteristics of infected subdural hematoma: Comparison with images of chronic subdural hematoma. *Clin Neurol Neurosurg* 2020;194:105831.
- Uwamino Y, Muranaka K, Hase R, Otsuka Y, Hosokawa N. Clinical features of community-acquired *Helicobacter cinaedi* bacteremia. *Helicobacter* 2016;21:24-8.

How to cite this article: Akiyama T, Imamura H, Fukui N, Sakai N. *Helicobacter cinaedi*-infected chronic subdural hematoma mimicking an expanding hematoma: A case report. *Surg Neurol Int* 2021;12:288.