



CORRESPONDENCE

Septic cavernous sinus thrombosis and blindness following odontogenic infection

KEYWORDS

blindness;
odontogenic infection;
septic cavernous sinus
thrombosis

Septic cavernous sinus thrombosis (SCST) is a rare and severe complication following odontogenic infection.¹ The irregularly shaped cavernous sinus is a collection of thin wall veins comprising trabeculae that are highly prone to bacterial infection and emboli formation. The facial veins and pterygoid plexus receive blood from this region. Infections of the orbits, middle face, nose, tonsil, soft palate, and jaws can spread to the cavernous sinus by this route.² The sequelae of SCST often result in impaired eyeball movement, vision loss, and death.³ A 47-year-old woman presented with a painful swelling in her left middle face for 4 days. On clinical examination, left side periorbital swelling and ptosis, impaired vision acuity, conjunctiva edema, and limited eyeball movement were identified (Figures 1A and 1B). Computed tomography revealed fluid-like material accumulation in the left maxillary sinus, with destruction of the medial wall and orbital floor. In addition, extraocular muscle compression and displacement were observed. Irregular enhancement was identified along the left lateral side of the sella turcica (Figures 1C and 1D). The orthopantomogram revealed a periodontally compromised tooth of #26. Serology tests showed an elevated white blood cell count (11,870/ μ L) and C-reactive protein level (12.09 mg/dL). Furthermore, pyrexia (39.1°C) and tachycardia (109 beats/min) were observed, indicating impending sepsis progress. After emergent orbit decompression, functional endoscopic sinus surgery, and

extraction of #26 with debridement, the patient continued to receive antibiotic coverage (Teicoplanin, 400 mg, Piperacillin/Tazobactam, 4 g/0.5 g) and steroid treatment (Solumedrol, 250 mg, q6h for 3 days, tapered to prednisolone 60 mg, qd). The swelling largely subsided on Day 5 after the surgery; however, vision improved only minimally. In the 4th month of follow-up, entropion, absence of light perception and pupil light reflex, and minimal ophthalmoplegia were observed in the left eye (Figures 1E and 1F). In the past, septic dural sinus thrombosis was potentially lethal; however, antibiotics now offer a cure.¹ Certain vital structures, such as cranial nerves III, IV, VI, V1, and V2 and the internal carotid artery, pass through the cavernous sinus. The anatomical proximity of these structures explains the severe neurologic sequelae following SCST.² SCST treatments incorporate antibiotics, debridement, steroid, and anticoagulant therapy.⁴ Antibiotic coverage should be implemented immediately once a diagnosis is established. Vancomycin combined with a third to fourth generation cephalosporin is recommended. Surgery is crucial for infection source removal. However, debridement of the cavernous sinus is infrequently executed because of unwarranted complications.⁵ Steroids are used because of the antiinflammatory effect that is considered beneficial for the recovery of neurological deficits.³ In this case, emergent antibiotics institution combined with interdisciplinary debridement prevented further sepsis progressing. We administered high-dose steroids and did not use anticoagulants on the insistence of the patient. Nevertheless, the left eye healed with some morbidity. Blindness, mydriasis, and mild ophthalmoplegia indicated damage of cranial nerves II, III, and IV, respectively. We presumed that severe swelling and compression of the extraocular muscles compromised the surrounding blood supply to the optic nerve. Awareness of these unfamiliar sequelae of maxillofacial infection should be emphasized.

<http://dx.doi.org/10.1016/j.jds.2015.10.002>

1991-7902/Copyright © 2015, Association for Dental Sciences of the Republic of China. Published by Elsevier Taiwan LLC. This is an open access article under the CC BY-NC-ND license (<http://creativecommons.org/licenses/by-nc-nd/4.0/>).

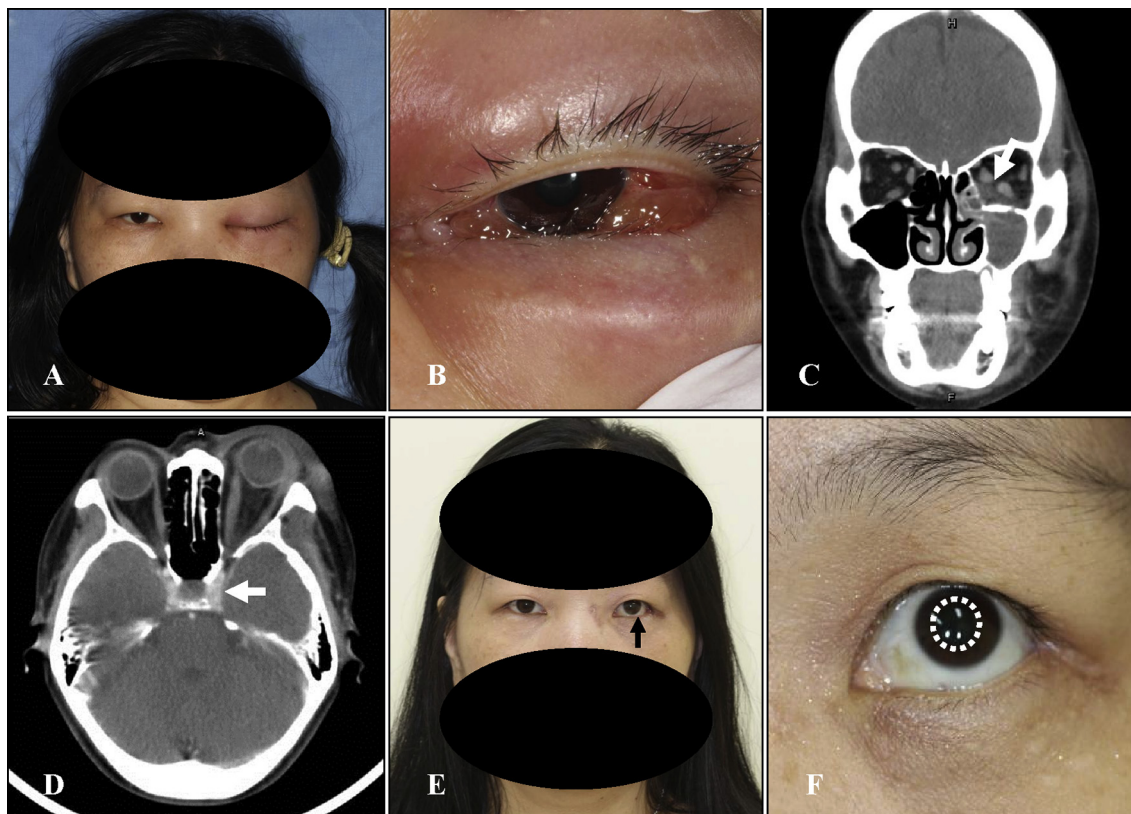


Figure 1 Clinical and radiographic photographs of the patient. (A) Severe swelling of the left face and ptosis of the left eye. (B) Chemosis of the left conjunctiva and cornea. (C) Coronal view of contrast-enhanced computed tomography. The left maxillary sinus is filled with fluid-like material, and the ethmoid sinus is affected. The arrow indicates extraocular muscle swelling and displacement. (D) Axial view of irregular enhancement and bulging along the left lateral side of the sella turcica (as indicated by the arrow). (E) At the 4-month follow-up, the swelling has subsided with little orbit decompression scarring. The black arrow indicates entropion. (F) Mild ophthalmoplegia is observed, particularly on upward gaze. The dotted line indicates mydriasis and no light perception in the left eye.

Conflicts of interest

The authors have no conflicts of interest relevant to this article.

References

- Colbert S, Cameron M, Williams J. Septic thrombosis of the cavernous sinus and dental infection. *Br J Oral Maxillofac Surg* 2010;49:e25–6.
- Harris FS, Rhoton AL. Anatomy of the cavernous sinus. A microsurgical study. *J Neurosurg* 1976;45:169–80.
- Ogundiya DA, Keith DA, Mirowski J. Cavernous sinus thrombosis and blindness as complications of an odontogenic infection: report of a case and review of literature. *J Oral Maxillofac Surg* 1989;47:1317–21.
- Liu C, Bayer A, Cosgrove SE, et al. Clinical practice guidelines by the infectious diseases society of America for the treatment of methicillin-resistant *Staphylococcus aureus* infections in adults and children: executive summary. *Clin Infect Dis* 2011;52: 285–92.
- Pouloupoulos M, Finelli PF. Neurological complications with acute sphenoid sinusitis a surgical emergency? *Neurocrit Care* 2007;7: 169–71.

Pai-Tai Tsai
Yuan-Wu Chen*

Division of Oral and Maxillofacial Surgery, Department of
Dentistry, Tri-Service General Hospital DDS, Taipei Medical
University, Taipei City, Taiwan, ROC

Dental School, National Defense Medical Center, Taiwan,
ROC

*Corresponding author. Division of Oral and Maxillofacial
Surgery of Tri-Service General Hospital, 2F, Number 325,
Section 2, Chenggong Road, Neihu District, Taipei City 114,
Taiwan, ROC.

E-mail address: h6183@yahoo.com.tw (Y.-W. Chen)

Received 22 September 2015

Final revision received 14 October 2015

Available online 17 December 2015