



Asymptomatic Presacral Paraganglioma: Management of an Unpredictable Intraoperative Finding

Athina A. Samara, MD¹ Alexandros Diamantis, MD, MSc¹ Dimitrios Symeonidis, MD, PhD¹
Athanasios Anagnostou, MD¹ Andreas Marios Diamantis, MD¹ Georgios Mavrovounis¹
Konstantinos Tepetes, MD, FACS, FEBS¹

¹ Department of Surgery, University Hospital of Larissa, Larissa, Greece

Address for correspondence Athina A. Samara, MD, Tsamadou 2 str., Larissa 41222, Greece (e-mail: at.samara93@gmail.com).

Surg J 2020;6:e131–e134.

Abstract

Keywords

- ▶ paraganglioma
- ▶ secreting tumor
- ▶ presacral paragangliomas
- ▶ 131-I MIBG
- ▶ neoplasm

Paragangliomas are rare neuroendocrine tumors originating from the embryological neural crest. We report a rare case of a patient with an asymptomatic presacral mass (incidentaloma) who experienced an unpredictable intraoperative hypertensive crisis after manipulation of the tumor. Presacral neoplasms pose a diagnostic and therapeutic challenge due to their obscure anatomical location and the difficulty in performing an R0 excision. Furthermore, the management of asymptomatic paragangliomas requires a high level of clinical suspicion and expertise due to potential life-threatening intraoperative complications.

Paragangliomas are rare neuroendocrine neoplasms arising from extra-adrenal neural crest-derived cells of the sympathetic and parasympathetic nervous system. When paragangliomas are located in the adrenal medulla, they are termed as pheochromocytomas.¹ Their incidence is estimated to be approximately two to eight cases per million¹ with most cases considered sporadic, thus, they can be part of a familial syndrome such as neurofibromatosis, MEN 2 (multiple endocrine neoplasia 2), Carney–Stratakis dyad, von Hippel–Lindau disease, etc.² Paragangliomas occur most commonly in the head and neck region, but can be found anywhere along the sympathetic chain.³ Symptoms of catecholamine secretions such as hypertension, hyperhidrosis, and hyperglycemia can be present.⁴ While only 15% of the patients remain asymptomatic, patients are typically diagnosed during imaging conducted for other medical purposes.³ Presacral paragangliomas are rarer still and pose a diagnostic and therapeutic challenge due to their obscure anatomical location and the difficulty of performing an R0 resection.⁵

We present a rare case report of an asymptomatic presacral mass causing an unpredictable acute hypertensive crisis intraoperatively, which is unmanageable with medical treatment.

Case Report

An asymptomatic 65-year-old Caucasian male presented with a pelvic mass which had been diagnosed during a routine lower abdomen ultrasonography due to benign prostatic hypertrophy. A digital rectal examination revealed a mass displacing the posterior rectum wall, without involving the rectal mucosa. Upon physical examination there were no signs of “Café au lait spots,” other signs of neurofibromatosis, or other familial syndromes associated with neuroendocrine tumors. The patient’s past medical history revealed both arterial hypertension and benign prostatic hyperplasia.

Lower abdomen magnetic resonance imaging (MRI) revealed a well-circumscribed heterogeneous signal intensity mass arising from the intraforaminal segment of the S3 nerve root, measuring 7.5 × 6.4 × 7.7 cm (▶ Fig. 1). Displacement of the rectum was observed with no signs of invasion. According to the radiologist, these findings indicated a possible malignant peripheral nerve sheath tumor.


The patient underwent an open anterior surgical approach. Unexpectedly, after entering the presacral space and manipulating the identified lesion, acute hypertensive crisis (systolic blood pressure: 300 mm Hg) and tachycardia with documented pulses >210 occurred. Due to failure in controlling

received
February 1, 2020
accepted after revision
April 8, 2020

DOI <https://doi.org/10.1055/s-0040-1712545>.
ISSN 2378-5128.

Copyright © 2020 by Thieme Medical Publishers, Inc., 333 Seventh Avenue, New York, NY 10001, USA.
Tel: +1(212) 760-0888.

License terms



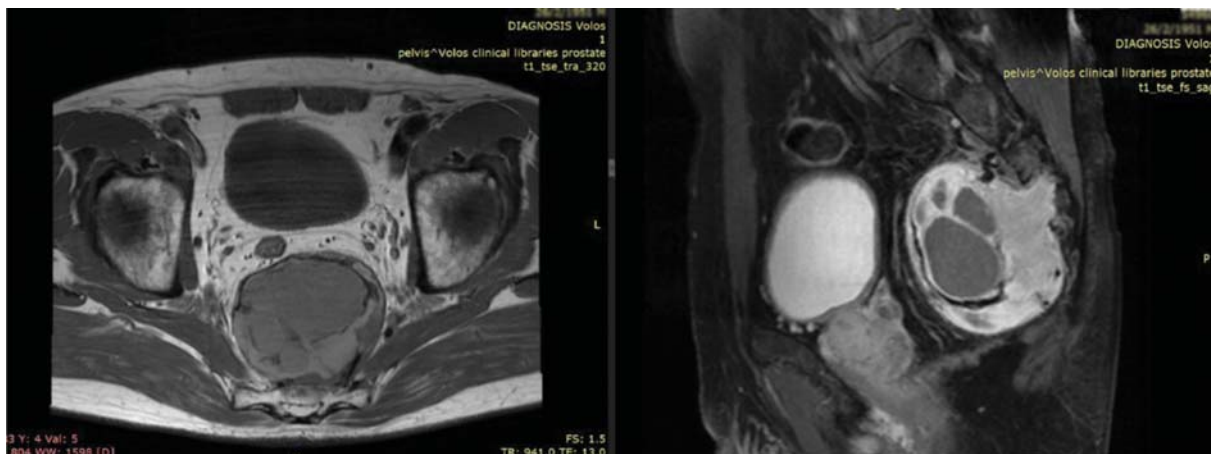


Fig. 1 Lower abdomen magnetic resonance imaging (MRI). A well-circumscribed heterogeneous signal intensity mass arising from the intraforaminal segment of the S3 nerve root, measuring $7.5 \times 6.4 \times 7.7$ cm.

and normalizing the patient's tension and heart rhythm, the operation was terminated without excising the mass. Postoperatively, all necessary exams were conducted to identify a catecholamine-secreting tumor. Over a 24-hour period urine catecholamines were measured at 1,313 mg (three times above the normal rate), adrenaline at 257 μ g (10 times above the normal rate), noradrenaline at 130 μ g, and dopamine at 918 μ g (two times above the normal rate). CT scans of the head, neck, chest, and abdomen were performed to exclude the possibility of neural crest tumors in other sites. This was followed by the initiation of treatment with α -blockers (phenoxybenzamine) and β -blockers (propranolol). After 5 days the patient was discharged and given instructions to continue his treatment with both α and β -blockers.

One month later a second laparotomy was performed. The lesion was fully excised but due to profuse, uncontrollable bleeding of the presacral venous plexus the abdomen was packed, and the patient was sent to the intensive care unit (ICU). After a 24-hour period, the unpacking procedure

was performed and was uneventful, and the patient was transferred to the Surgery Department. Following a full recovery, the patient was discharged on the eighth postoperative day.

Upon histological examination, characteristics of a paraganglioma with the typical zellballen cells were identified. Nuclear atypia and pleomorphism were present; mitotic activity was high (10/10 high power fields X 40 Zeiss) and vascular invasion was also observed. Immunohistochemically, the tumor was SMA (-), HMB45 (-), AE1 (-), AE3 (-), CKIT (-), MELAN A (-), DESMIN (-), CD68 (-), EMA (-), VIMENTIN (+), and S100 (+). Tumor analysis of succinate dehydrogenase (SDH) subunits was not available in the Pathology Laboratory of our hospital.

Three months later, the patient's urine catecholamines were normalized. Thus, the following MRI revealed signs of high contrast material uptake with a 1-cm diameter, in the anatomical position of the previously excised lesion (**Fig. 2**). SPECT-CT (single-photon emission computed tomography [CT]) with ^{99m}Tc -Tektrotyd had shown a small intake in the area of the

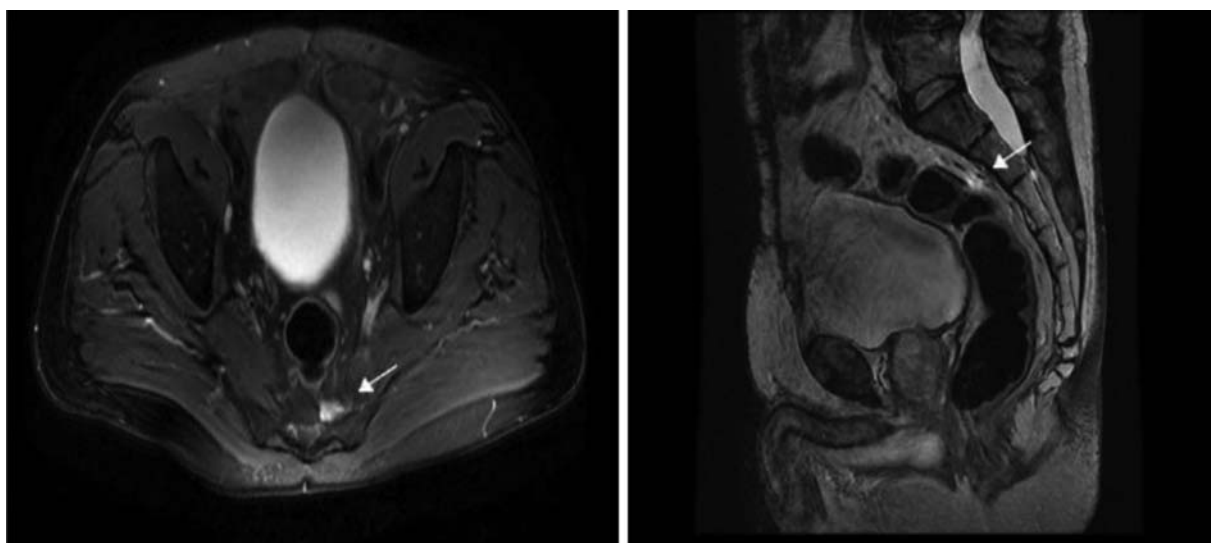


Fig. 2 MRI (after 3 months): High contrast material uptake approximately 1 cm diameter in the anatomical position of the excised lesion (white arrow). MRI, magnetic resonance imaging.

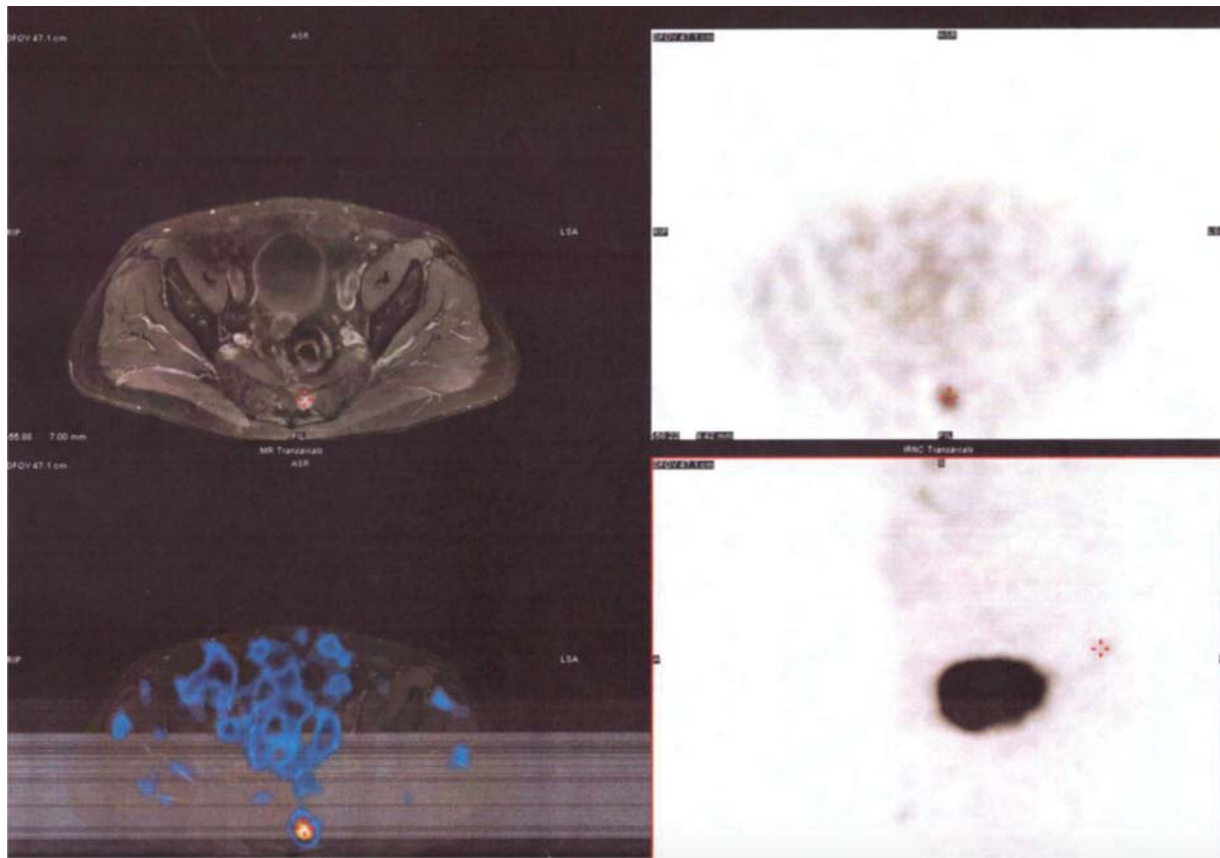


Fig. 3 SPECT-CT (Single-photon emission computed tomography) with ^{99m}Tc -Tektrotyd: small intake in the area of the resection (red cross).

resection (► **Fig. 3**). Three cycles of ^{131}I -metaiodobenzylguanidine (^{131}I -MIBG) treatment followed, and in a SPECT-CT conducted 1 month later, there was no radiodrug intake. The patient has since been closely followed-up, undergoing MRI and urine catecholamine tests twice per year; 4 years later the patient remains disease-free.

In accordance with the existing guidelines on pheochromocytoma and paraganglioma management, genetic testing for SDH was recommended to the patient. Taking into consideration that the patient had no children or other first-degree relatives, and the high cost of the test which the patient was unable to afford, he refused genetic testing. A shared decision was reached to proceed with close biochemistry and radiological follow-up of the patient on a biannual basis.

Discussion

Pheochromocytomas and paragangliomas (PPGLs) are neuroendocrine tumors arising from adrenomedullary chromaffin cells and extra-adrenal chromaffin cells respectively, which produce catecholamines. Approximately 80 to 85% of chromaffin-cell tumors are pheochromocytomas, whereas only 15 to 20% are paragangliomas. The exact prevalence, however, remains unclear, with 0.05 to 0.1% detected in autopsy studies, which went undetected during the individual's life.⁶ While up to 40% of the patients possess a familial mutation in a known susceptibility gene—which is more

than any other solid tumor—most cases are considered to be sporadic.⁷

Compared with pheochromocytomas, only 1% of paragangliomas are functional and produce catecholamines, with the majority being asymptomatic or having mass effects such as vague abdominal pain.² In patients with a paraganglioma located below the neck level, the classic signs and symptoms associated with catecholamine excess include headache (26%), palpitations (21%), sweating (25%), and episodic hypertension (64%); however, only one-third of patients will suffer from these symptoms. Other less obvious symptoms associated with catecholamine excess include hyperglycemia, panic attacks, fever, weight loss, myocardial infarctions, osteolytic bone metastases, and Raynaud's phenomenon.⁸

At least 10% of pheochromocytomas and sympathetic paragangliomas are malignant, although rates of malignancy differ according to the patient's hereditary background. Lymph nodes, skeleton, liver, and lungs are the most frequent sites of metastases.⁹ CT with contrast provides an excellent initial method for the localization of paragangliomas (sensitivity 88–100%) and an MRI can be useful when a CT is contraindicated.⁶ The use of ^{123}I -MIBG¹ scintigraphy is recommended as a functional imaging modality in patients with either metastatic PPGLs or an increased risk for metastatic disease, multifocal, and recurrent disease.⁶ In addition, a 18F-FDG PET/CT (18F-fluorodeoxyglucose positron emission tomography/computed tomography) scan is recommended in patients with metastatic disease.⁶

Primary surgical excision remains the treatment of choice for resectable paragangliomas.¹⁰ Therapeutic use of ¹³¹I-MIBG could offer a safe and effective option for patients with unresectable or metastatic PPGLs.^{11–13} Preoperative preparation is crucial to decrease the intraoperative hypertensive spikes, and minimize the perioperative adverse events and overall morbidity.¹⁴

Interval surveillance of these patients is similar to every other patient with neuroendocrine tumors. Following an R0 excision, blood pressure and levels of catecholamines or chromogranin (in patients with normal catecholamines preoperatively) should be measured every 3 months during the first year, every 6 months until the third year, and then annually for up to 10 years. In addition, abdominal/pelvic CT or MRI scans with contrast, or FDG-PET/CT scans can be considered. These follow-up exams can be performed at an earlier stage if symptoms dictate it. Moreover, patients with hereditary paraganglioma may require more frequent follow-up.¹⁰

In this report, in addition to presenting a rare case, we would like to focus on the surgeon's dilemma regarding the optimal surgical approach for the patient, which as the MRI dictates (►Fig. 1), would ideally be an en-bloc sacrectomy below the segment S2. However, this approach would lead to excess morbidity and deterioration of the patient's quality of life, due to the inevitable injury of the sacral nerve plexus.^{15,16} Therefore, after discussing all possible alternatives with the patient, he was first treated through excision of the mass, and subsequently, the residual disease was treated with ¹³¹I-MIBG therapy which showed a remarkable response.

Conclusion

Presacral paragangliomas pose both a diagnostic and therapeutic challenge because of the obscure anatomical location and the difficulty in obtaining an R0 excision. Furthermore, a high level of clinical suspicion of a possible secreting tumor, as well as expertise in management is required due to potential life-threatening intraoperative complications.

Conflict of Interest

All authors have no conflict of interest to disclose.

References

- Delellis RA, Lloyd RV, Heitz PU, et al. World Health Organization Classification of Tumours. Pathology and Genetics of Tumours of Endocrine Organs. Lyon: IARC Press; 2004

- Mantas D, Kandilis A, Charalampoudis P. Nonfunctioning symptomatic paraganglioma: is there an optimal follow-up for patients with extra-adrenal benign paragangliomas. *J Surg Case Rep* 2014; 2014(09):rju092
- Pedroso C, Robalo R, Sereno P, Barros C, Marques C. A rare abdomino-pelvic tumor: paraganglioma. *Acta Med Port* 2015; 28(01):114–116
- Guo Q, Li B, Guan J, Yang H, Wu Y. Intraoperative diagnosis of functional retroperitoneal multiple paraganglioma: a case report. *Oncol Lett* 2012;4(04):829–831
- Saxena D, Pandey A, Bugalia RP, et al. Management of presacral tumors: our experience with posterior approach. *Int J Surg Case Rep* 2015;12:37–40
- Lenders JW, Duh QY, Eisenhofer G, et al; Endocrine Society. Pheochromocytoma and paraganglioma: an endocrine society clinical practice guideline. *J Clin Endocrinol Metab* 2014;99(06):1915–1942
- Fishbein L. Pheochromocytoma and paraganglioma: genetics, diagnosis, and treatment. *Hematol Oncol Clin North Am* 2016; 30(01):135–150
- Lee JA, Duh QY. Sporadic paraganglioma. *World J Surg* 2008;32(05):683–687
- Plouin PF, Amar L, Dekkers OM, et al; Guideline Working Group. European Society of Endocrinology Clinical Practice Guideline for long-term follow-up of patients operated on for a pheochromocytoma or a paraganglioma. *Eur J Endocrinol* 2016;174(05): G1–G10
- NCCN Clinical Practice Guidelines in Oncology (NCCN Guidelines). *J Natl Compr Canc Netw* 2018;16(06):693–702
- Carrasquillo JA, Pandit-Taskar N, Chen CC. I-131 metaiodobenzyl guanidine therapy of pheochromocytoma and paraganglioma. *Semin Nucl Med* 2016;46(03):203–214
- van Hulsteijn LT, Niemeijer ND, Dekkers OM, Corssmit EP. (131)I-MIBG therapy for malignant paraganglioma and pheochromocytoma: systematic review and meta-analysis. *Clin Endocrinol (Oxf)* 2014;80(04):487–501
- Jimenez C, Erwin W, Chasen B. Targeted radionuclide therapy for patients with metastatic pheochromocytoma and paraganglioma: from low-specific-activity to high-specific-activity Iodine-131 metaiodobenzylguanidine. *Cancers (Basel)* 2019;11(07):E1018
- Ramachandran R, Rewari V. Factors affecting the haemodynamic behaviour of patients undergoing pheochromocytoma and paraganglioma removal: a review. *Cardiovasc Endocrinol* 2017;6(02): 73–80
- Dziki Ł, Włodarczyk M, Sobolewska-Włodarczyk A, et al. Presacral tumors: diagnosis and treatment—a challenge for a surgeon. *Arch Med Sci* 2019;15(03):722–729
- Sasikumar A, Bhan C, Jenkins JT, Antoniou A, Murphy J. Systematic review of pelvic exenteration with en bloc sacrectomy for recurrent rectal adenocarcinoma: R0 resection predicts disease-free survival. *Dis Colon Rectum* 2017;60(03):346–352