

# Eosinophilic gastroenteritis presenting as upper gastrointestinal hematoma and ulcers after endoscopic biopsy

## A case report and literature review

Biqin Chen, MD<sup>a</sup>, Zhao Yang, MD<sup>a</sup>, Heng Lu, MD<sup>b</sup>, Cheng Wei, MD<sup>c</sup>, Fangyu Wang, PhD<sup>a,\*</sup>, Chang Liu, PhD<sup>b,\*</sup>

### Abstract

**Rationale:** Eosinophilic gastroenteritis (EG) is a gastrointestinal disorder characterized by eosinophilic infiltration with various manifestations. The diagnosis is usually confirmed by an endoscopic biopsy, which is considered a safe and routine procedure for the majority.

**Patient concerns:** We report a 54-year-old male who was presented with intermittent periumbilical pain and melena, and only revealed verrucous gastritis by endoscopy.

**Diagnoses:** The patient's condition worsened two days after the endoscopic biopsy, and another endoscopy found hematoma and ulcers in upper gastrointestinal tract. He was diagnosed with EG by the pathological analysis of biopsy specimen.

**Interventions:** Oral methylprednisolone and Montelukast were prescribed.

**Outcomes:** The patient got remission after initiation of the treatment.

**Lessons:** This case highlights an extremely rare but potentially severe complication of endoscopic biopsies in patients with EG. Physicians should be cautious with hematoma or ulceration, and consider it in such patients who undergo this procedure.

**Abbreviations:** CRP = C-reactive protein, CT = computed tomography, IgE = immunoglobulin, EG = eosinophilic gastroenteritis, NSAIDs = nonsteroidal antiinflammatory drugs, WBC = white cell count.

**Keywords:** biopsy, eosinophilic gastroenteritis, gastric hematoma, ulcers

## 1. Introduction

Eosinophilic gastroenteritis (EG) is a rare gastrointestinal disease which is characterized by eosinophilic infiltration of gastrointestinal tract and eosinophilia. The etiology and pathogenesis remains unclear, and the diagnosis mainly depends on the

examination of endoscopy and biopsy. Generally, upper gastrointestinal hematoma and ulceration was a rare situation occurred after this procedure, and even less reported in patients with EG. Here we will present a case of EG with submucosal gastric hematoma and multiple ulcers in the stomach and duodenum following endoscopic biopsy.

Editor: Somchai Amorniyotin.

Funding: This work was supported by the National Natural Science Foundation of China (No. 81570506).

Consent: The patient signed informed consent for the publication of this case report and all accompanying images.

The authors have no conflicts of interest to disclose.

<sup>a</sup> Department of Gastroenterology and Hepatology, Jinling Hospital, School of Medicine, Southern Medical University, <sup>b</sup> Department of Gastroenterology and Hepatology, Jinling Hospital, <sup>c</sup> Department of Gastroenterology and Hepatology, Jinling Hospital, School of Medicine, Nanjing University, Nanjing, Jiangsu, China.

\* Correspondence: Fangyu Wang, Department of Gastroenterology and Hepatology, Jinling Hospital, School of Medicine, Southern Medical University, Nanjing 210002, Jiangsu, China (e-mail: wangfy65@nju.edu.cn); Chang Liu, Department of Gastroenterology and Hepatology, Jinling Hospital, Nanjing 210002, Jiangsu, China (e-mail: liuchang\_gj@163.com).

Copyright © 2017 the Author(s). Published by Wolters Kluwer Health, Inc. This is an open access article distributed under the terms of the Creative Commons Attribution-Non Commercial-No Derivatives License 4.0 (CCBY-NC-ND), where it is permissible to download and share the work provided it is properly cited. The work cannot be changed in any way or used commercially without permission from the journal.

Medicine (2017) 96:37(e8075)

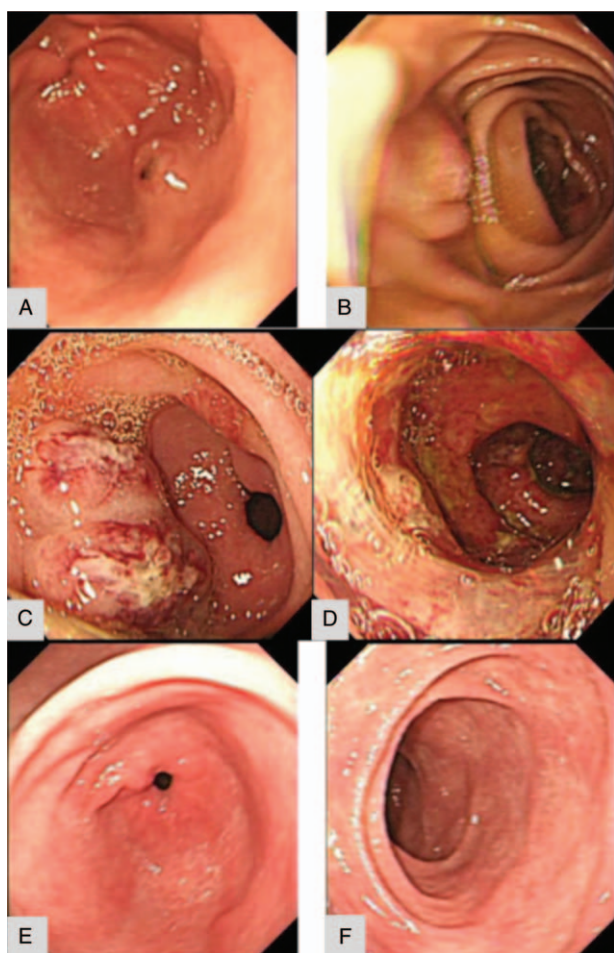
Received: 16 April 2017 / Received in final form: 19 August 2017 / Accepted: 23 August 2017

<http://dx.doi.org/10.1097/MD.0000000000008075>

## 2. Case presentation

A 54-year-old man was admitted to our hospital with intermittent periumbilical pain and melena of a month's duration. He denied fever, nausea, vomiting, diarrhea and purulent stools. And he unintentionally lost about 5 kg over the past 1 month. Before his admission, the result of his abdominal ultrasound examination in the local hospital was inconspicuous, except for mesenteric lymph node tumescence in the right lower quadrant. He was allergic to trimethoprim but denied a history of allergies to other medication or food, and his father died from asthma. He also denied use of nonsteroidal antiinflammatory drugs (NSAIDs). However, he had smoked a pack of cigarette and drank about 0.2 kg a day for over 30 years.

His blood pressure was 132/84 mm Hg, heart rate 72 beats per minute, and respiratory rate 14 breaths per minute. Our physical examination revealed mild abdominal tenderness, especially for the lower and left quadrant, and no abdominal guarding or rebound tenderness. Laboratory examination results were as following: white cell count (WBC) was  $21.8 \times 10^9/L$ , neutrophils was 87%, eosinophils was 1.2%, the hemoglobin was 144 g/L, and coagulation function was normal. Blood glucose, electrolytes, aminotransferases, bilirubin, and other liver function



**Figure 1.** (A and B) Initial upper gastrointestinal endoscopy only showed verrucous gastritis. (C) The second endoscopy four days later revealed swollen and inflamed mucosal changes with gastric hematoma and (D) multiple ulcers in the stomach and duodenum. (E and F) The endoscopy after 3 months found great improvement in lesions of both stomach and duodenum.

indicators were within normal limits; C-reactive protein (CRP) was 53.5 mg/L (normal range, 0–8 mg/L) and immunoglobulin E (IgE) 113.0 IU/mL (normal range, 0–100 IU/mL), autoantibody was negative and fecal occult blood testing was positive. Parasitologic examination and bacterial culture of stool results were normal. A computed tomography (CT) scan of the abdomen and mesenteric CT angiography was negative for mass lesions or

lymphadenopathy. The first upper gastrointestinal endoscopy examination 1 day before admission only discovered verrucous gastritis (Fig. 1 A and B). Meanwhile, antral biopsy was performed and identified negative for *Helicobacter pylori*. The endoscopist did not observe excessive bleeding, ulcer, or hematoma during the procedure. There was no evidence of vascular malformation in the stomach or duodenum. Then he received antibiotic and proton pump inhibitor therapy.

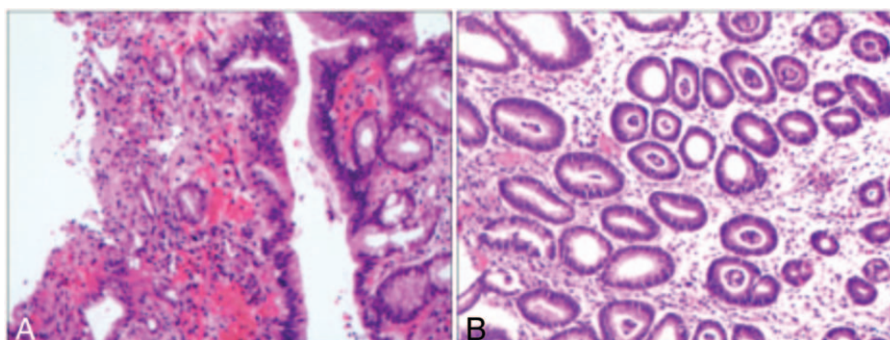
Nevertheless, the patient's condition seemed to exacerbate 2 days after the examination of endoscopy, presenting with nausea, vomiting, and dark red liquid drained out from nasogastric tube. So a repeated upper endoscopy was performed 2 days later, showing swollen and inflamed mucosal changes with ulcerations in the stomach and duodenum and gastric hematoma in the submucosa layer (Fig. 1C and D).

The initial biopsy revealed gastric mucosa with extensive eosinophilic infiltrate in the lamina propria (Fig. 2A). For the evaluation of allergy, we performed an inhale and food allergen detection, which only showed dust mite positive.

Based on the extraordinary eosinophilic infiltration in the gastric mucosa, high serum level of IgE, and the absence of secondary cause, a diagnosis was made of eosinophilic gastroenteritis. Accordingly, oral methylprednisolone (30 mg daily) and montelukast (4 mg daily) were prescribed, and gradually the patient's symptom alleviated with leukocytes, neutrophils, CRP significantly decreased. Endoscopy 3 months after initiation of the treatment revealed remarkable improvement in lesions of the stomach and duodenum (Fig. 1E and F). Histopathologic evaluation of mucosal biopsy specimens demonstrated a large proportion of clearing of the eosinophilic infiltration (Fig. 2B).

### 3. Discussion

Eosinophilic gastroenteritis (EG) is an unusual disorder in the gastrointestinal tract. The estimated incidence of EG is about 1 to 20 cases per 100,000 patients.<sup>[1]</sup> The most commonly affected organs are the stomach and small intestine, although the esophagus, large intestine and rectum may as well as be involved to different degree.<sup>[2,3]</sup> Klein et al<sup>[4]</sup> divided EG into 3 major pathological types: mucosal, muscular, and subserosal. EG is usually detected during endoscopic investigation in adults for abdominal pain or diarrhea.<sup>[5,6]</sup> Clinical presentation may vary depending on locations and depth of involvement of the gastrointestinal tract, including dyspepsia, abdominal cramps, diarrhea, gastrointestinal bleeding, abdominal tympany, and allergic enterocolitis. The exact etiology remains unclear until



**Figure 2.** (A) Pathological examination of first biopsy showed gastric mucosa with extensive eosinophilic infiltrate in the lamina propria. (B) Analysis of biopsy 3 months later demonstrated a large proportion of clearing of the eosinophilic infiltration (H&E staining,  $\times 200$ ).

now, though many patients with EG are reported to have a history of seasonal allergies, food sensitivities, eczema, asthma, or atopy.<sup>[7,8]</sup>

In 1990, Talley et al<sup>[9]</sup> suggested the following diagnostic criteria: the presence of gastrointestinal symptoms, eosinophilic infiltration of one or more sites of the gastrointestinal tract revealed by biopsies, or characteristic radiologic results with peripheral eosinophilia, and no evidence of parasitic or extraintestinal diseases. It is apparent that endoscopic biopsy plays a key role in the diagnosis of EG.

In general, upper endoscopy with biopsy is a safe procedure which has a low risk of complications. The relatively common adverse events are bleeding or perforation. Nevertheless, clinically significant bleeding is estimated to be less than 0.5% in all cold mucosal biopsies.<sup>[10]</sup> It has been reported that anticoagulant therapy and NSAIDs increase the incidence of self-limiting bleeding after endoscopic biopsy,<sup>[11]</sup> and NSAIDs are also related with spontaneous ulcer and nonulcer gastrointestinal hemorrhage.<sup>[12]</sup> Gastric or intraduodenal hematoma (IDH) is a rare complication for the procedure. The incidence of biopsy-induced IDH is not considerably clear and is evaluated to be approximately 1 out of 1250 to 1 out of 1900.<sup>[13]</sup> In contrast, gastric hematoma related with endoscopic biopsy is barely reported throughout the whole world. The duodenum is vulnerable to injury and bleeding due to rich blood supply in submucosa and its relatively immobile position.<sup>[14]</sup> The mucosa can potentially be sheared off the fixed submucosa during biopsy, leading to extensive bleeding of the submucosal vessels.<sup>[15]</sup>

In the case above, the patient presented without previous history of a bleeding disorder, taking anticoagulant or NSAIDs. All standard coagulation parameters were within the normal range. Meanwhile, upper mesenteric ischemia was excluded with negative result of CT angiography. The infection of *H pylori* or other bacteria and parasites had been ruled out as well. As for systemic disorders, no evidence was found to support the diagnosis of hypereosinophilic syndrome, hematological diseases, malignancy, connective tissue diseases, vasculitides, or Crohn disease. Review of the biopsy showed no evidence of transected or lacerated blood vessels. So there was no evidence that vascular integrity was disrupted to produce the bleeding by the biopsy. But we believe that ulcer and hematoma were related to biopsies with the following reasons: initial endoscopy revealed no ulcerative or hemorrhagic lesions; second endoscopy showed gastric hematoma and upper gastrointestinal ulcerations; there was association between the lesion area and the site of biopsies. However, the mechanism of tissue damage in this case is still not clear. One possible mechanism is associated with type I IgE mediated. A history of hypersensitivity and atopy, as well as positive results for food antigens and increased IgE levels, demonstrates that allergic IgE mediated mechanism make significant sense in EG.<sup>[16,17]</sup> In addition, a number of mediators, such as eosinophilic cationic protein and eosinophilic peroxidase, are released by eosinophils and known to be tissue toxins.<sup>[18]</sup> Similarly, eosinophils can generate diverse cytokines such as interleukin-1 and transforming growth factors, which may induce injury of tissue in the gastrointestinal tract.<sup>[19]</sup> Accordingly, we speculate that endoscopic biopsy may be an inducement to aggravate the condition of this patient with EG. The injury caused by biopsies may have triggered and amplified a progressive inflammation, finally culminating in EG with submucosal hematoma, and hematoma would gradually rupture to form an ulcer, which may subsequently cause bleeding.

There is no consensus about the optimal treatment of patients with EG. Identifying the food allergens and taking an eliminated dietary can alleviate the symptoms of the disorder. However, complete remission is usually achieved with amino acid-based elemental diets.<sup>[20]</sup> If dietary therapy is not practical or has failed to improve the disease, steroids are supposed to be the mainstay of treatment in these cases.<sup>[21]</sup> Other remedies, such as montelukast (leukotriene receptor antagonist), ketotifen and sodium chromoglycate (mast cell-stabilizing agents and antihistamine), and suplatast tosilate (antiallergic drug that suppresses cytokines production), have been reported to be effective in the management of some cases.<sup>[22–24]</sup> Initial studies paid attention to the potential effects of anti-IL-5, anti-CCR3 antagonists, and anti-eotaxin-1.<sup>[25–27]</sup> Surgery is generally avoided, except for intestinal perforation or obstruction. In our case under discussion, the patient gets full remission from receiving oral corticosteroid and montelukast.

In conclusion, we report an unusual case of EG, which developed as upper gastrointestinal submucosal hematoma and multiple ulcers following endoscopic biopsy. This case highlights an extremely rare but potentially severe complication of a routine procedure in EG. Physicians should be cautious with hematoma or ulceration, and consider it in such patients who undergo endoscopy and mucosal biopsies.

## References

- Persic M, Stimac T, Stimac D, et al. Eosinophilic colitis: a rare entity. *J Pediatr Gastroenterol Nutr* 2001;32:325–6.
- Naylor AR. Eosinophilic gastroenteritis. *Scott Med J* 1990;35:163–5.
- Lee CM, Changchien CS, Chen PC, et al. Eosinophilic gastroenteritis: 10 years experience. *Am J Gastroenterol* 1993;88:70–4.
- Klein NC, Hargrove RL, Slesinger MH, et al. Eosinophilic gastroenteritis. *Medicine (Baltimore)* 1970;49:299–319.
- Straumann A. Idiopathic eosinophilic gastrointestinal diseases in adults. *Best Pract Res Clin Gastroenterol* 2008;22:481–96.
- Cello JP. Eosinophilic gastroenteritis—a complex disease entity. *Am J Med* 1979;67:1097–104.
- Kelly KJ. Eosinophilic gastroenteritis. *J Pediatr Gastroenterol Nutr* 2000;30(suppl):S28–35.
- von Wattenwyl F, Zimmermann A, Netzer P. Synchronous first manifestation of an idiopathic eosinophilic gastroenteritis and bronchial asthma. *Eur J Gastroenterol Hepatol* 2001;13:721–5.
- Talley NJ, Shorter RG, Phillips SF, et al. Eosinophilic gastroenteritis: a clinicopathological study of patients with disease of the mucosa, muscle layer, and subserosal tissues. *Gut* 1990;31:54–8.
- Friedel DM. Big bleed after endoscopic mucosal biopsy. *South Med J* 2009;102:129.
- Shiffman ML, Farrel MT, Yee YS. Risk of bleeding after endoscopic biopsy or polypectomy in patients taking aspirin or other NSAIDs. *Gastrointest Endosc* 1994;40:458–62.
- Lanas A, Sekar MC, Hirschowitz BI. Objective evidence of aspirin use in both ulcer and nonulcer upper and lower gastrointestinal bleeding. *Gastroenterology* 1992;103:862–9.
- Sahn B, Anupindi SA, Dadhania NJ, et al. Duodenal hematoma following EGD: comparison with blunt abdominal trauma-induced duodenal hematoma. *J Pediatr Gastroenterol Nutr* 2015;60:69–74.
- Zinelis SA, Hershenson LM, Ennis MF, et al. Intramural duodenal hematoma following upper gastrointestinal endoscopic biopsy. *Dig Dis Sci* 1989;34:289–91.
- Szajewska H, Albrecht P, Ziolkowski J, et al. Intramural duodenal hematoma: an unusual complication of duodenal biopsy sampling. *J Pediatr Gastroenterol Nutr* 1993;16:331–3.
- Melamed I, Feanny SJ, Sherman PM, et al. Benefit of ketotifen in patients with eosinophilic gastroenteritis. *Am J Med* 1991;90:310–4.
- Elkon KB, Sher R, Seftel HC. Immunological studies of eosinophilic gastro-enteritis and treatment with disodium cromoglycate and beclomethasone dipropionate. *S Afr Med J* 1977;52:838–41.
- Keshavarzian A, Saverymattu SH, Tai PC, et al. Activated eosinophils in familial eosinophilic gastroenteritis. *Gastroenterology* 1985;88:1041–9.

- [19] Moqbel R, Levi-Schaffer F, Kay AB. Cytokine generation by eosinophils. *J Allergy Clin Immunol* 1994;94(6 Pt 2):1183–8.
- [20] Justinich C, Katz A, Gurbindo C, et al. Elemental diet improves steroid-dependent eosinophilic gastroenteritis and reverses growth failure. *J Pediatr Gastroenterol Nutr* 1996;23:81–5.
- [21] Rothenberg ME. Eosinophilic gastrointestinal disorders (EGID). *J Allergy Clin Immunol* 2004;113:11–28. 29.
- [22] Perez-Millan A, Martin-Lorente JL, Lopez-Morante A, et al. Subserosal eosinophilic gastroenteritis treated efficaciously with sodium cromoglycate. *Dig Dis Sci* 1997;42:342–4.
- [23] Bolukbas FF, Bolukbas C, Uzunkoy A, et al. A dramatic response to ketotifen in a case of eosinophilic gastroenteritis mimicking abdominal emergency. *Dig Dis Sci* 2004;49:1782–5.
- [24] Schwartz DA, Pardi DS, Murray JA. Use of montelukast as steroid-sparing agent for recurrent eosinophilic gastroenteritis. *Dig Dis Sci* 2001;46:1787–90.
- [25] Oh HE, Chetty R. Eosinophilic gastroenteritis: a review. *J Gastroenterol* 2008;43:741–50.
- [26] Komai M, Tanaka H, Nagao K, et al. A novel CC-chemokine receptor 3 antagonist, Ki19003, inhibits airway eosinophilia and subepithelial/peribronchial fibrosis induced by repeated antigen challenge in mice. *J Pharmacol Sci* 2010;112:203–13.
- [27] Baruch-Morgenstern NB, Shik D, Moshkovits I, et al. Paired immunoglobulin-like receptor A is an intrinsic, self-limiting suppressor of IL-5-induced eosinophil development. *Nat Immunol* 2013;15:36–44.