

ORIGINAL RESEARCH

Automatic classification of autism spectrum disorder in children using cortical thickness and support vector machine

Letizia Squarcina¹  | Guido Nosari¹ | Riccardo Marin²  | Umberto Castellani² | Marcella Bellani³ | Carolina Bonivento⁴ | Franco Fabbro⁵ | Massimo Molteni⁴ | Paolo Brambilla^{1,6} 

¹ Department of Pathophysiology and Transplantation, University of Milan, Via Festa del Perdono, 7, 20122 Milan, Italy

² Department of Informatics, University of Verona, Verona, Italy

³ Department of Neurosciences, Biomedicine and Movement Sciences, Section of Psychiatry, University of Verona, Verona, Italy

⁴ IRCCS "E. Medea", Polo Friuli Venezia Giulia, San Vito al Tagliamento (PN), Italy

⁵ Department of Medicine, University of Udine, Udine, Italy

⁶ Department of Neurosciences and Mental Health Department of Neurosciences and Mental Health, Fondazione IRCCS Ca' Granda Ospedale Maggiore Policlinico, via Francesco Sforza 28, 20122 Milan, Italy

Correspondence

Letizia Squarcina, Department of Pathophysiology and Transplantation, University of Milan, Via Festa del Perdono, 7, 20122 Milan, Italy.
Email: letizia.squarcina@unimi.it

[Correction added on 30 August 2021, after first online publication: Peer review history statement has been added.]

Abstract

Objective: Autism spectrum disorder (ASD) is a neurodevelopmental condition with a heterogeneous phenotype. The role of biomarkers in ASD diagnosis has been highlighted; cortical thickness has proved to be involved in the etiopathogenesis of ASD core symptoms. We apply support vector machine, a supervised machine learning method, in order to identify specific cortical thickness alterations in ASD subjects.

Methods: A sample of 76 subjects (9.5 ± 3.4 years old) has been selected, 40 diagnosed with ASD and 36 typically developed subjects. All children underwent a magnetic resonance imaging (MRI) examination; T1-MPRAGE sequences were analyzed to extract features for the characterization and parcellation of regions of interests (ROI); average cortical thickness (CT) has been measured for each ROI. For the classification process, the extracted features were used as input for a classifier to identify ASD subjects through a "learning by example" procedure; the features with best performance was then selected by "greedy forward-feature selection." Finally, this model underwent a leave-one-out cross-validation approach.

Results: From the training set of 68 ROIs, five ROIs reached accuracies of over 70%. After this phase, we used a recursive feature selection process in order to identify the eight features with the best accuracy (84.2%). CT resulted higher in ASD compared to controls in all the ROIs identified at the end of the process.

Conclusion: We found increased CT in various brain regions in ASD subjects, confirming their role in the pathogenesis of this condition. Considering the brain development curve during ages, these changes in CT may normalize during development. Further validation on a larger sample is required.

KEYWORDS

autism spectrum disorder, cortical thickness, magnetic resonance imaging, supervised machine learning, support vector machine

This is an open access article under the terms of the [Creative Commons Attribution License](https://creativecommons.org/licenses/by/4.0/), which permits use, distribution and reproduction in any medium, provided the original work is properly cited.

© 2021 The Authors. *Brain and Behavior* published by Wiley Periodicals LLC

1 | INTRODUCTION

Autism spectrum disorder (ASD) is a neurodevelopmental condition that includes a wide phenotypic range (Lord et al., 2000): There is now a single diagnosis of autism spectrum disorder in DSM 5 that replaces the different subdivisions—autistic disorder, Asperger's disorder, and pervasive developmental disorder—not otherwise specified (PDD-NOS). The main clinical features of ASD are early-onset impairment in social communication, repetitive behaviors, and restricted interests (Honey et al., 2012). ASD has a complex pathophysiology that has not been completely elucidated. Combinations of environmental and genetic factors causing aberrant development of brain regions have been linked to the disorder (Bhandari et al., 2020; Emberti et al., 2019), which usually onsets in the early years of life (Emberti et al., 2019). In the last decades, a dramatic increase in ASD prevalence has been recorded, being estimated to one subject in 59 (Baio et al., 2018). Such an evidence could be partially related to the recent innovations in diagnostic criteria, but could also account for a higher attention on this condition and a real increase in incidence (Tordjman et al., 2014). Therefore, the construction and validation of diagnostic resources aimed to address early tailored treatment strategies is a striking target of the current research. Most diagnostic procedures rely on standardized assessment tests and on clinical observation (Bishop et al., 2008). Machine learning (ML) techniques applied to brain magnetic resonance imaging (MRI) could likely help to identify disease-specific biomarkers. ML methods aim to automatically identify patterns from data, without any a-priori knowledge. Patterns learnt from the training set are then used to infer models, which are applied to new, unseen data (Squarcina et al., 2019). According to a recent review (Moon et al., 2019) ML approaches have proved to be reliable especially in studies on structural MRI (sMRI). Support vector machine (SVM) is a supervised ML method which has proved to be considerably effective, and it is commonly used for classification purposes in biological assessment (Cortes & Vapnik, 1995; Lee et al., 2019; Vapnik, 2013). In recent years, various studies have focused on the SVM classification of ASD from sMRI data, confirming the reliability of such an approach with satisfying accuracy outcomes. Although results show some heterogeneity, classification accuracy can reach values over 90% (Almeida et al., 2017; Bi et al., 2018; Chaddad et al., 2017; Demirhan, 2018; Ecker et al., 2010; Hoefl et al., 2011; Retico et al., 2016; Sabuncu & Konukoglu, 2015; Subbaraju et al., 2015; Xiao et al., 2017), confirmed also by a recent systematic review and meta-analysis (Moon et al., 2019). Studies demonstrated that a multivariate approach may be of benefit in the study of ASD: in example, Rakic and colleagues (2020) showed that using functional MRI together with structural MRI consistently improves performances.

ML studies highlight the involvement of various brain areas in ASD, especially in hippocampus and corpus callosum (Bi et al., 2018; Demirhan, 2018; Fu et al., 2021; Hoefl et al., 2011; Richards et al., 2020), cingulate and temporal regions (Almeida et al., 2017; Retico et al., 2016). Subcortical and limbic areas also resulted relevant for the classification (Sarovic et al., 2020), with an accuracy of around 80%.

Significant outcomes

Support vector machine (SVM), a supervised machine learning technique, provides a relevant and innovative approach in detecting biomarkers in Autism Spectrum Disorder (ASD). The present study detected an increased cortical thickness (CT) in ASD children compared to typically developed subjects in cortical areas putatively involved in the pathogenesis of ASD core symptoms.

Our findings suggest the trajectory of brain development of ASD children distances itself from typically developing children, especially in brain regions which are involved in information processing, social relationships and decision making.

Limitations

The main limitation is related to the small sample size of participant groups; the present findings, therefore, need to be replicated in a larger sample in order to validate the present SVM method.

Previous evidence describes conflicting results regarding cortical thickness (CT) (Moon et al., 2019), reporting both increase and reduction in CT in different brain regions (Chung et al. 2005; Hyde et al., 2010; Misaki et al., 2012; Pagnozzi et al., 2018; Sarovic et al., 2020; Scheel et al., 2011) in ASD subjects. Cortical development trajectories in ASD subjects report an early hyperplasia in the first years of life (Brun et al., 2009; Carper & Courchesne, 2005; Carper et al., 2002), followed by nearly normalization in successive stages (Hyde et al., 2010); this suggests that a process of early brain overgrowth, followed by volume plateau and decline, could be considered a biologic hallmark of this disease. Thickness alterations in specific brain regions seem to have a specific correlation with clinical features: frontal lobes thickness is likely associated with more severe social impairment (Richter et al., 2015; van Rooij et al., 2018) and repetitive behaviors (Kohls et al., 2014); temporal lobe and anterior cingulate cortex thickness correlates with motor stereotype severity (Hardan et al., 2009), attention, and executive functions (Achiron et al., 2013; Urbain et al., 2016); and orbitofrontal thickness is presumably implied in social cognition (Chung et al., 2005; Jiao et al., 2010) and theory of mind impairment (Girgis et al., 2007). Other studies support the role of CT as a functional biomarker; more specifically, increased thickness was found to be associated with more compromised language skills (Sharda et al., 2016., 2017) and global performance (Moradi et al., 2017; Sato et al., 2013). The deviation from the physiological cortical growth trajectory could reflect a structural and functional disruption in the connectivity network (Lewis & Elman, 2008), producing a functional performance ineffective for "high level" integration and processing (Narzisi et al., 2013; Wass, 2011). According to this and other evidence from the literature, it has been hypothesized that delayed maturation of the cortex could be a core feature of ASD pathogenesis (Raznahan et al., 2011; Shaw et al., 2008).

In this study, we aimed to apply SVM classification on CT, which seems to be a sensitive clinical biomarker for specific ASD traits (Gebauer et al., 2015) and has been hypothesized to be directly related to dendritic arborization and pruning (Huttenlocher et al., 1990). Unlike other works in the field, our aim was to identify a small number of specific brain areas which differentiate the most between patients with autism and controls: this could shed some light on the biologic etiology of the disease.

2 | AIMS OF THE STUDY

With this work, we aim to automatically identify brain regions potentially affected by ASD. The identification of brain imaging markers for autism may be of great importance for defining the etiology of the disorder. We aim to use a completely automatic machine learning method to exclude any bias given by a-priori hypotheses.

3 | METHODS

3.1 | Data set

We selected a sample of 76 children, 40 diagnosed with ASD (36 males, 8.9 ± 3.5 years old) and 36 typically developed subjects (31 males, 9.5 ± 3.4 years old). Children were recruited at "La Nostra Famiglia," Scientific Institute IRCCS "E. Medea," Piasani di Prato, Udine, Italy. Recruitment procedures were similar to a previous work from our group (Mengotti et al., 2011). The ASD diagnosis fulfilled the DSM-IV criteria and the autism diagnostic observation schedule (ADOS) was validated through a consensus meeting between a child psychiatrist and a child psychologist. Illness severity was determined using the childhood autism rating scale (CARS). None of the patients had comorbid attention deficit hyperactivity disorder (ADHD), seizure disturbance, or any other associated disorder known to cause autism. Typically developed subjects, chosen as a control group, were not suffering from any major medical, neurological or developmental problem. The subjects had no history of seizures or head injuries. None of the children was taking or had ever taken any psychotropic medications. Intelligence quotient (IQ) was determined with the Leiter-R or the Griffiths or the Wechsler intelligence scale for children (WISC) IV scales.

All children underwent an MRI examination, mostly under sedation because of their young age or inability to remain still. MRI scans were checked for abnormalities by an experienced radiologist and no evidence of gross central nervous system abnormalities was detected.

Demographic and clinical information on the sample is reported in Table 1. There was no difference in age or IQ between patients with autism or controls.

The research was approved by the Ethics Committee of the Scientific Institute IRCCS "E. Medea,"

TABLE 1 Demographic and clinical information

	Typically developed subjects (N = 36)	ASD patients (N = 40)
Age (SD)	9.5 (3.4)	8.9 (3.5)
Sex	28 males	36 males
IQ	80.9 (15.3)	74.0 (19.5)
ADOS total score	–	14.5 (3.6)
NEPSY attention/executive	–	81.0 (19.5)
NEPSY sensomotory	–	82.0 (7.6)
NEPSY visuospatial	–	88.0 (26.4)
NEPSY memory	–	78.3 (14.0)

Abbreviations: ADOS, autism diagnostic observation schedule; NEPSY, a developmental NEuroPSYchological assessment; SD, standard deviation.

3.2 | Image acquisition

MRI scans were acquired using a 1.5T Siemens Magnetom Symphony Maestro Class, Syngo MR 2002B. A 3D T1 sequence (sagittal plane) was acquired covering the entire brain (TR = 1750 ms, TE = 3.93 ms, flip angle = 15°, FOV = 238 × 238, slice thickness = 1.25 mm, 120 slices, matrix size = 410 × 512, TI = 1100). Data were visually inspected for artifacts and image quality.

3.3 | Feature extraction

T1-MPRAGE images were analyzed to extract features for the characterization of cortical structures. Brain cortex parcellation was computed using FreeSurfer software package (version 4.3.1 <http://surfer.nmr.mgh.harvard.edu/>). A mesh of the pial surface and of the boundaries between white matter (WM) and gray matter (GM) are calculated for every hemisphere. The shortest distance between each vertex of a mesh to the complementary surface has been calculated and linked to the vertex as CT. Then the meshes are automatically divided into gyral based regions of interest (ROIs) using the Desikan-Killiany atlas included in FreeSurfer (Desikan et al., 2006).

The characterization of cortical ROIs has been done by measuring their average CT, which was then normalized in respect to brain total cortical volume. Possible influences of age differences in CT are taken into account using the generalized linear model (GLM) approach: data were linearly fit to a model and residues, that is, the portion of data not explicable by age, were retained for further analysis.

3.4 | Classification procedure

The extracted features were used as input for a classifier to detect subjects with autism by adopting a learning by example procedure. SVM provide a classification method that projects data to higher

dimensional spaces, with the aim of distinguishing more easily, in respect to the original space, samples belonging to different classes. SVM perform a linear separation between classes, exploiting the principle of maximum margin, to find the best hyperplane in terms of classes' separation. In SVM, a parameter is present (usually known as C) which controls the relationship between the error of classification and the generalizability of the model: a large C gives a high penalty to misclassified samples during the in-training phase, and could lead to overfitting. On the other hand, small values of C could produce an underfitted model.

In this study, SVM will be implemented with LIBSVM toolbox (Chang & Lin, 2001). We chose to use RBF as kernel, and the two free parameters C and σ will be tuned using a grid-search, as described in Section 2.6.

3.5 | Feature selection

The group of features that achieved best performance was identified by greedy forward-feature selection, where the best performing feature is combined with already selected features iteratively. Formally, the feature set is initialized $F = \{f_0\}$. Then, the following steps are iterated:

- find the feature j to add to F with best performance (in our case, accuracy has been used as measure of performance)
- add f_j to the feature set $F = \{f_0, f_j\}$
- repeat until $F = \{f_0, \dots, f_N\}$.

This approach has the complex of $O(N^2)$ with N as total number of features. In our case, $N = 68$, which is the total number of features considered. The final number K of features in F depends on the accuracy of the classification at each iteration, so $1 < K < N$.

3.6 | Parameters selection and validation

In order to achieve the best performances with the SVM method, we chose the parameters C and σ which maximized classification accuracy. In particular, we used a grid-search approach: a set of 17 exponentially spaced values for the parameter C and 19 exponentially spaced values for the parameter σ were provided to the classifier. All the configurations and their total accuracy have been evaluated. Finally, we used a leave-one-out cross-validation approach: the model was trained on all the available samples except one, which was then used as the verification element. This process was iterated on the whole dataset, excluding a sample each time. The overall performance evaluation was obtained by checking how many elements were correctly classified, and which lead to a general view of the predictive model performances. For completeness and to exclude bias introduced with the choice of the cross-validation procedure, we also performed a N -fold cross-validation, results of which are reported in the supporting information.

The mean CT of the ROI identified by the classifier has been compared between groups (t -test, $\alpha = 0.05$).

TABLE 2 Results over features

ROI	Accuracy	Sensitivity	Specificity
Right SFG	0.776	0.725	0.833
Right LO	0.724	0.725	0.722
Right PO	0.724	0.700	0.750
Left LOF	0.711	0.800	0.611
Left pericalcarine	0.711	0.700	0.722
8 features concatenated	0.842	0.800	0.889

Abbreviations: LO, lateral occipital; LOF, lateral orbito-frontal; PO, pars orbitalis; ROI, region of interest; SFG, superior frontal gyrus.

4 | RESULTS

MRI data resulted of good quality after visual inspection. All 68 ROIs obtained from the Desikan-Killiany FreeSurfer atlas (Desikan et al., 2006) were considered in the first run of RBF-SVM. Five ROIs, listed in Table 2, reached accuracies of over 70%. In particular, with the right hemisphere superior frontal thickness the classifier obtained an accuracy of 77.6% with a specificity of 83.3% and a sensitivity of 72.5%. After this phase, we used a recursive feature selection process, with the aim of identifying the eight features which, concatenated, gave the best accuracy. The best accuracy obtained with this process was 84.2%, reached concatenating the gray matter thickness of the following eight ROIs: right hemisphere superior frontal gyrus, right hemisphere medial orbital frontal cortex, right hemisphere postcentral gyrus, left hemisphere frontal pole, left hemisphere middle temporal gyrus, right hemisphere entorhinal cortex, right hemisphere insula, right hemisphere middle temporal gyrus. The most discriminant regions are represented in Figure 1.

Average CT resulted higher in ASD in respect to controls in all the ROIs identified by the classifier (Table 3). This difference reached statistical significance in right superior frontal gyrus, pars orbitalis, middle temporal gyrus, entorhinal cortex, insula, and left middle temporal gyrus.

5 | DISCUSSION

ASD has a complex etiology. Combinations of environmental, metabolic, and genetic factors causing aberrant development of brain regions have been linked to the disorder (Agostoni et al., 2017; Esposito et al., 2021). According to our results, subjects with ASD showed selective alterations of cortical areas involved in information processing associated with interpersonal relationship, "self vs. non-self" discrimination, language and motricity in a broad sense. Such findings are consistent with current literature evidence (Cogill & Wang, 2016; Crippa et al., 2015; Zocante et al., 2010), which highlighted a putative involvement of the aforementioned areas in the pathogenesis of ASD symptoms, therefore confirming the reliability of SVM approaches in order to identify early diagnostic marker in

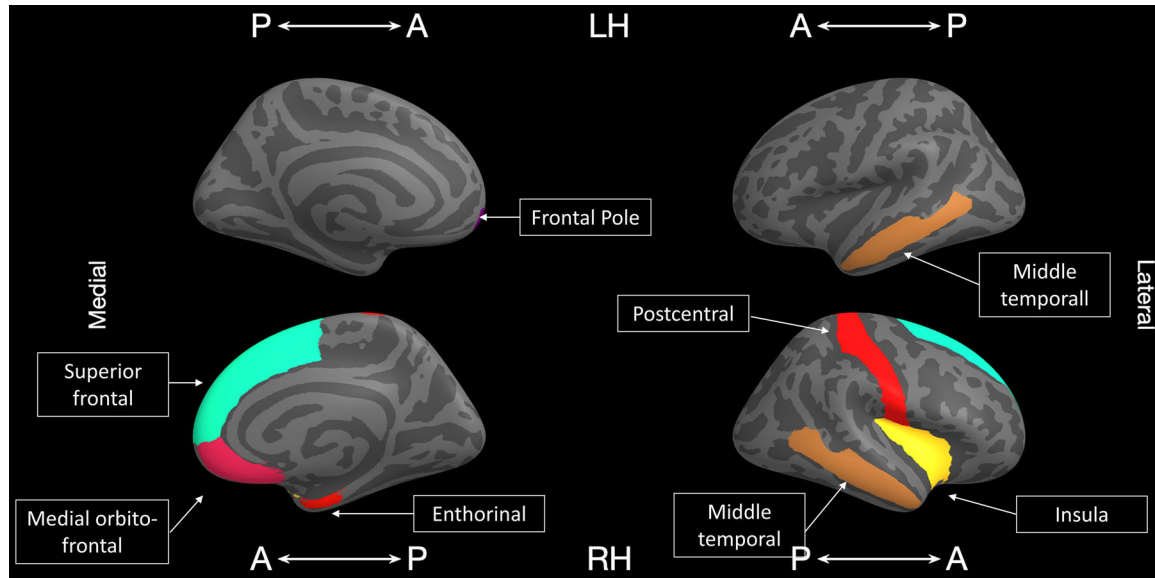


FIGURE 1 The most discriminant region when considering one region at a time resulted to be the right superior frontal gyrus (highlighted in light blue) with an accuracy of 77.6%. The accuracy reached 83% when concatenating the following regions: right superior frontal gyrus (light blue), right medial orbito-frontal cortex (magenta), right entorhinal cortex (red), right postcentral gyrus (red), right insula (yellow), right middle temporal gyrus (orange), left middle temporal gyrus (orange), left frontal pole (violet). LH = left hemisphere; RH = right hemisphere; A-P = antero-posterior. P-A = postero-anterior. This image was obtained with the tool available at https://developmentalimagingmcri.github.io/freesurfer_statsurf_display/

TABLE 3 Mean cortical thickness in ASD and CT and comparison between groups

ROI	CT ASD patients (mean ± SD)	CT Typically developed subjects (mean ± SD)	<i>p</i>
Right SFG	3.32 (0.31)	3.17 (0.29)	0.043
Right LO	2.62 (0.25)	2.52 (0.20)	0.054
Right PO	3.35 (0.41)	3.16 (0.42)	0.047
Left LOF	3.19 (0.33)	3.06 (0.29)	0.065
Left pericalcarine	1.81 (0.22)	1.75 (0.21)	0.20
Right MOF	3.12 (0.36)	3.02 (0.32)	0.19
Right PG	2.41 (0.21)	2.34 (0.19)	0.11
Left FP	3.64 (0.46)	3.50 (0.53)	0.22
Left MTG	3.33 (0.29)	3.18 (0.31)	0.039
Right MTG	3.40 (0.25)	3.19 (0.33)	0.002
Right EC	3.73 (0.39)	3.43 (0.56)	0.008
Right insula	3.57 (0.25)	3.39 (0.37)	0.017

Abbreviations: ASD, autism spectrum disorder; CT, cortical thickness; EC, entorhinal cortex; FP, frontal pole; LO, lateral occipital; LOF, lateral orbitofrontal; MOF, middle orbital frontal; MTG, middle temporal gyrus; PG, postcentral gyrus; PO, pars orbitalis; ROI, region of interest; SD, standard deviation; SFG, superior frontal gyrus.

Regions whose thickness differs significantly between HC and ASD are highlighted in bold. *p*-values not corrected for multiple comparisons.

ASD. The best accuracy obtained in our study was reached by the concatenation of gray matter thickness values of the following ROIs: right superior frontal gyrus, medial orbital frontal cortex, postcentral gyrus and left frontal pole, middle temporal gyrus, entorhinal cortex, insula, right hemisphere, and temporal gyrus, consistently with previous findings, which identified medial, ventromedial, and dorsolateral regions of the frontal lobe as being associated with ASD-related neuroanatomical abnormalities (Irimia et al., 2018). More specifically, the right medial orbital sulcus has been postulated to be implicated in ASD-related social impairment (Amaral et al., 2008), selectively in repetitive or stereotyped behaviors, in the abnormal actions of obsessive-compulsive disorder (Atmaca et al., 2007; Whiteside et al., 2004), in decision making and in expectation rewarding (Kringelbach, 2005), all of which are impaired in ASD. The straight gyrus (gyrus rectus) is involved in attentional control and its functions are tightly integrated with those of orbital cortex (Nestor et al., 2015) and it has been found to exhibit bilateral structural abnormalities in ASD (Irimia et al., 2018). The inferior frontal gyrus, known for being crucially involved in expressive language function and therefore functionally impaired in ASD (Redcay, 2008) has been previously found to be abnormal in autism both in terms of morphology (Levitt et al., 2003; Nordahl et al., 2017), GM thickness (Jiao et al., 2010) and WM connectivity (Irimia et al., 2018; Pardini et al., 2009) making it a point of interest of crucial importance for distinguishing between ASD and typically developing children when using SVM (Ecker et al., 2010). Various authors (Retico et al., 2016; Spera et al., 2019) focused on GM thickness, reporting a significantly increased GM volume in ASD children with respect to control subjects, eminently in bilateral

superior frontal gyrus, precuneus, and superior temporal gyrus. In contrast, GM was found to be depleted in ASD patients in other areas right inferior temporal gyrus. In agreement with the majority of CT studies, we found increased thickness in various regions for ASD children. The use of automatic methods allows the identification of brain markers, which can shed light on the etiology of the disease. The fact that concatenating different features reaches a better accuracy than considering single features at once, hints to a disruption of a whole network instead of focal alterations in brain structure. This is in accordance to the view of ASD as a connectivity disorder, which seems to be confirmed by several studies employing functional MRI; current literature evidence suggests a broad disruption in local and diffuse connectivity between networks in ASD, resulting in both under- and overconnectivity patterns (Hull et al., 2017; Mohammad-Rezazadeh et al., 2016). It has also to be noted that the frontal regions seem to be crucial in the disorder: the frontal gyrus is both the region with the highest accuracy and selected by the greedy-forward feature selection process.

It has to be noted that the regions identified with the greedy-forward feature selection procedure are different from the region which reached high accuracies when considered singularly. This is because the automatic selection procedure considered all the 68 ROIs originally identified, and the accuracy of the combination of different features is not necessarily related to the accuracy of the single region taken separately. Moreover, the final number of regions selected depends on the accuracy of the different combinations used in the selection procedures: in our case, the best accuracy was obtained when considering eight features: considering less or more features resulted in worse accuracy.

The main limitation of this work is related to the small sample size of participant groups; the present findings, therefore, need to be replicated in order to validate our SVM method and this work should be considered as a starting point to develop new studies with this method and with a larger sample size. A recent review of the literature on machine learning applied to structural MRI images of ASD subjects (Nogay & Adeli, 2020) showed that, although results reached generally good accuracy, results tend to be related to the sample size, which is an aspect which must be taken into account. Moreover, it has to be considered that in this work we did not have an independent sample to perform a test of our classifier performance: this is a frequent limitation of medical studies, which then should be addressed in future studies as well. Larger datasets would also allow other meaningful applications of machine learning approaches, as multi-class classification or stratification of the dataset in multiple groups, which may add meaning from a clinical and therapeutic point of view.

6 | CONCLUSION

In this work, we demonstrated that it is possible to identify ASD patients using CT data, without the need of a-priori clinical knowledge. We confirm the hypothesis that the trajectory of development of ASD

children distances itself from typically developing children and, in particular, it is possible to identify subtle changes in brain regions which are crucial for behavior and decision making. We confirm previous findings in the literature, and moreover we identified a small number of brain regions whose CT has the potential to be a biomarker for autism.

ACKNOWLEDGMENTS

PB was partially supported by grants from the Italian Ministry of Health (RF-2016-02364582).

CONFLICT OF INTEREST STATEMENT

The authors declare no conflict of interest

PEER REVIEW

The peer review history for this article is available at <https://publons.com/publon/10.1002/brb3.2238>.

DATA AVAILABILITY STATEMENT

The data that support the findings of this study are available from the corresponding author upon reasonable request.

ORCID

Letizia Squarcina  <https://orcid.org/0000-0001-6209-4629>

Riccardo Marin  <https://orcid.org/0000-0003-2392-4612>

Paolo Brambilla  <https://orcid.org/0000-0002-4021-8456>

REFERENCES

- Achiron, A., Chapman, J., Tal, S., Bercovich, E., Hararai, G., & Anat, A. (2013). Superior temporal gyrus thickness correlates with cognitive performance in multiple sclerosis. *Brain Structure and Function*, 218(4), 943–950. <https://doi.org/10.1007/s00429-012-0440-3>
- Agostoni, C., Nobile, M., Ciappolino, V., Delvecchio, G., Tesei, A., Turolo, S., Crippa, A., Mazzocchi, A., Altamura, C. A., & Brambilla, P. (2017). The role of omega-3 fatty acids in developmental psychopathology: A systematic review on early psychosis, autism, and ADHD. *International Journal of Molecular Sciences*, 18(12), 2608. <https://doi.org/10.3390/ijms18122608>
- Almeida, A., Velasco, N., & Romero, E. (2017). A multidimensional feature space for automatic classification of autism spectrum disorders (ASD). In Romero, E., Lepore, N., Brieve, J., Larrabide, I. (Eds.), *Proceedings of the 12th International Symposium on Medical Information Processing and Analysis*, International Society for Optics and Photonics, <https://doi.org/10.1117/12.2256952>.
- Amaral, D. G., Schumann, C. M., & Nordahl, C. W. (2008). Neuroanatomy of autism. *Trends in Neuroscience*, 31, 137–145. <https://doi.org/10.1016/j.tins.2007.12.005>
- Atmaca, M., Yildirim, H., Ozdemir, H., Tezcan, E., & Poyraz, A. K. (2007). Volumetric MRI study of key brain regions implicated in obsessive-compulsive disorder. *Progress in Neuro-Psychopharmacology & Biological Psychiatry*, 31, 46–52. <https://doi.org/10.1016/j.pnpbp.2006.06.008>
- Baio, J., Wiggins, L., Christensen, D. L., Maenner, M. J., Daniels, J., Warren, Z., Kurzius-Spencer, M., Zahorodny, W., Robinson, C., Rosenberg White, T., Durkin, M. S., Imm, P., Nikolaou, L., Yeargin-Allsopp, M., Lee, L.-C., Harrington, R., Lopez, M., Fitzgerald, R. T., Hewitt, A., ... Naarden Braun Dowling, N. F. (2018). Prevalence of autism spectrum disorder among children aged 8 years: Autism and developmental disabilities monitoring network, 11 sites, United States, 2014. *MMWR Surveillance Summaries*, 67, 1–23. <https://doi.org/10.15585/mmwr.ss6706a1>

- Bhandari, R., Paliwal, J. K., & Kuhad, A. (2020) Neuropsychopathology of autism spectrum disorder: Complex interplay of genetic, epigenetic, and environmental factors. *Advances in Neurobiology*, 24, 97–141. https://doi.org/10.1007/978-3-030-30402-7_4
- Bi, X. A., Wang, Y., Shu, Q., Sun, Q., & Xu, Q. (2018). Classification of autism spectrum disorder using random support vector machine cluster. *Frontiers in Genetics*, 9, 18. <https://doi.org/10.3389/fgene.2018.00018>
- Bishop, S., Luyster, R., Richler, J., & Lord, C. (2008). Autism spectrum disorders in infants and toddlers. In Chawarska, K., Klin, A., Volkmer, F. (Eds.), *Diagnostic assessment* (pp. 23–49). Guildford
- Brun, C. C., Nicolson, R., Leporé, N., Chou, Y. Y., Vidal, C. N., & DeVito, T. J. (2009). Mapping brain abnormalities in boys with autism. *Human Brain Mapping*, 30(12), 3887–3900. <https://doi.org/10.1002/hbm.20814>
- Carper, R. A., & Courchesne, E. (2005). Localized enlargement of the frontal cortex in early autism. *Biological Psychiatry*, 57(2), 126–133. <https://doi.org/10.1016/j.biopsych.2004.11.005>
- Carper, R. A., Moses, P., Tigue, Z. D., & Courchesne, E. (2002). Cerebral lobes in autism: Early hyperplasia and abnormal age effects. *Neuroimage*, 16(4), 1038–1051. <https://doi.org/10.1006/nimg.2002.1099>
- Chaddad, A., Desrosiers, C., & Toews, M. (2017). Multi-scale radiomic analysis of sub-cortical regions in MRI related to autism, gender and age. *Scientific Reports*, 7, 45639. <https://doi.org/10.1038/srep45639>
- Chang, C. C., & Lin, C. J. (2001) LIBSVM: A library for support vector machines. <http://www.csie.ntu.edu.tw/~cjlin/libsvm>
- Chung, M. K., Robbins, S. M., Dalton, K. M., Davidson, R. J., Alexander, A. L., & Evans, A. C. (2005). Cortical thickness analysis in autism with heat kernel smoothing. *Neuroimage*, 25(4), 1256–1265. <https://doi.org/10.1016/j.neuroimage.2004.12.052>
- Cogill, S., & Wang, L. (2016). Support vector machine model of developmental brain gene expression data for prioritization of autism risk gene candidates. *Bioinformatics*, 32(23), 3611–3618.
- Cortes, C., & Vapnik, V. (1995). Support-vector networks. *Machine Learning*, 20, 273–297. <https://doi.org/10.1007/BF00994018>
- Crippa, A., Salvatore, C., Perego, P., Forti, S., Nobile, M., Molteni, M., & Castiglioni, I. (2015). Use of machine learning to identify children with autism and their motor abnormalities. *Journal of Autism and Developmental Disorders*, 45(7), 2146–2156. <https://doi.org/10.1007/s10803-015-2379-8>
- Demirhan, A. (2018). The effect of feature selection on multivariate pattern analysis of structural brain MR images. *Physica Medica*, 47, 103–111. <https://doi.org/10.1016/j.ejmp.2018.03.002>
- Desikan, R. S., Sagonne, F., Fischl, B., Quinn, B. T., Dickerson, B. C., Blacker, D., Buckner, R. L., Dale, A. M., Maguire, R. P., Hyman, B. T., Albert, M. S., & Killiany, R. J. (2006). An automated labeling system for subdividing the human cerebral cortex on MRI scans into gyral based regions of interest. *Neuroimage*, 31(3), 968–980. <https://doi.org/10.1016/j.neuroimage.2006.01.021>
- Ecker, C., Marquand, A., Mourão-Miranda, J., Johnston, P., Daly, E. M., Brammer, M. J., Maltezos, S., Murphy, C. M., Robertson, D., Williams, S. C., & Murphy, D. G. (2010). Describing the brain in autism in five dimensions: Magnetic resonance imaging-assisted diagnosis of autism spectrum disorder using a multiparameter classification approach. *Journal of Neuroscience*, 30(32), 10612–10623. <https://doi.org/10.1523/JNEUROSCI.5413-09.2010>
- Emberti, G. L., Mazzone, L., Benvenuto, A., Fasano, A., Alcon, A. G., Kraneveld, A., Moavero, R., Raz, R., Riccio, M. P., Siracusano, M., Zachor, D. A., Marini, M., & Curatolo, P. (2019) Risk and protective environmental factors associated with autism spectrum disorder: Evidence-based principles and recommendations. *Journal of Clinical Medicine*, 8(2), 217. <https://doi.org/10.3390/jcm8020217>
- Esposito, C. M., Buoli, M., Ciappolino, V., Agostoni, C., & Brambilla, P. (2021) The role of cholesterol and fatty acids in the etiology and diagnosis of autism spectrum disorders. *International Journal of Molecular Sciences*, 22(7), 3550. <https://doi.org/10.3390/ijms22073550>
- Fu, Y., Zhang, J., Li, Y., Shi, J., Zou, Y., Guo, H., Li, Y., Yao, Z., Wang, Y., & Hu, B. (2021) A novel pipeline leveraging surface-based features of small subcortical structures to classify individuals with autism spectrum disorder. *Progress in Neuro-Psychopharmacology & Biological Psychiatry*, 104, 109989. <https://doi.org/10.1016/j.pnpbp.2020.109989>
- Gebauer, L., Foster, N. E. V., Vuust, P., & Hyde, K. L. (2015). Is there a bit of autism in all of us? Autism spectrum traits are related to cortical thickness differences in both autism and typical development. *Research in Autism Spectrum Disorders*, 13–14, 8–14. <https://doi.org/10.1016/j.rasd.2014.12.013>
- Girgis, R. R., Minshew, N. J., Melhem, N. M., Nutche, J. J., Keshavan, M. S., & Hardan, A. Y. (2007). Volumetric alterations of the orbitofrontal cortex in autism. *Progress in NeuroPsychopharmacology and Biological Psychiatry*, 31(1), 41–45. <https://doi.org/10.1016/j.pnpbp.2006.06.007>
- Hardan, A. Y., Libove, R. A., Keshavan, M. S., Melhem, N. M., & Minshew, N. J. (2009). A preliminary longitudinal magnetic resonance imaging study of brain volume and cortical thickness in autism. *Biological Psychiatry*, 66, 320–326. <https://doi.org/10.1016/j.biopsych.2009.04.024>
- Hoefel, F., Walter, E., Lightbody, A. A., Hazlett, H. C., Chang, C., Piven, J., & Reiss, A. L. (2011). Neuroanatomical differences in toddler boys with fragile X syndrome and idiopathic autism. *Archives of General Psychiatry*, 68, 295. <https://doi.org/10.1001/archgenpsychiatry.2010.153>
- Honey, E., Rodgers, J., & McConachie, H. (2012). Measurement of restricted and repetitive behaviour in children with autism spectrum disorder: Selecting a questionnaire or interview. *Research in Autism Spectrum Disorders*, 6, 757–776. <https://doi.org/10.1016/j.rasd.2011.10.011>
- Hull, J. V., Dokovna, L. B., Jacokes, Z. J., Torgerson, C. M., Irimia, A., & Van Horn, J. D. (2017). Resting-state functional connectivity in autism spectrum disorders: A review. *Front Psychiatry*, 7, 205. <https://doi.org/10.3389/fpsy.2016.00205> [published correction appears in *Front Psychiatry*. 2018;22(9), 268]
- Huttenlocher, P. R., Levine, S. C., Huttenlocher, J., & Gates, J. (1990) Discrimination of normal and at-risk preschool children on the basis of neurological tests. *Developmental Medicine and Child Neurology*, 32(5), 394–402. <https://doi.org/10.1111/j.1469-8749.1990.tb16958.x>
- Hyde, K. L., Samson, F., Evans, A. C., & Motttron, L. (2010). Neuroanatomical differences in brain areas implicated in perceptual and other core features of autism revealed by cortical thickness analysis and voxel-based morphometry. *Human Brain Mapping*, 31, 556–566
- Irimia, A., Lei, X., Torgerson, C. M., Jacokes, Z. J., Abe, S., & Van Horn, J. D. (2018) Support vector machines, multidimensional scaling and magnetic resonance imaging reveal structural brain abnormalities associated with the interaction between autism spectrum disorder and sex. *Frontiers in Computational Neuroscience*, 12, 93. <https://doi.org/10.3389/fncom.2018.00093>
- Jiao, Y., Chen, R., Ke, X., Chu, K., Lu, Z., & Herskovits, E. H. (2010). Predictive models of autism spectrum disorder based on brain regional cortical thickness. *Neuroimage*, 50(2), 589–599. <https://doi.org/10.1016/j.neuroimage.2009.12.047>
- Kohls, G., BE Y., & Schultz, R. T. (2014) Striatal development in autism: Repetitive behaviors and the reward circuitry. *Biological Psychiatry*, 76(5), 358–359. <https://doi.org/10.1016/j.biopsych.2014.07.010>
- Kringelbach, M. L. (2005). The human orbitofrontal cortex: Linking reward to hedonic experience. *Nature Reviews Neuroscience*, 6, 691–702. <https://doi.org/10.1038/nrn1747>
- Lee, S. H., Maenner, M. J., & Heilig, C. M. (2019). A comparison of machine learning algorithms for the surveillance of autism spectrum disorder. *PLoS One*, 14(9), e0222907. <https://doi.org/10.1371/journal.pone.0222907>
- Levitt, J. G., Blanton, R. E., Smalley, S., Thompson, P. M., Guthrie, D., McCracken, J. T., Sadoun, T., Heinichen, L., & Toga, A. W. (2003) Cortical sulcal maps in autism. *Cerebral Cortex*, 13(7), 728–735.
- Lewis, J. D., & Elman, J. L. (2008). Growth-related neural reorganization and the autism phenotype: A test of the hypothesis that altered brain

- growth leads to altered connectivity. *Developmental Science*, 11(1), 135–155. <https://doi.org/10.1111/j.1467-7687.2007.00634.x>
- Lord, C., Rutter, M., DiLavore, P. C., & Risi, S. (2000). *The Autism Diagnostic Observation Schedule*. Western Psychological Services.
- Mengotti, P., D'Agostini, S., Terlevic, R., De Colle, C., Biasizzo, E., Londero, D., Ferro, A., Rambaldelli, G., Balestrieri, M., Zanini, S., Fabbro, F., Molteni, M., & Brambilla, P. (2011). Altered white matter integrity and development in children with autism: A combined voxel-based morphometry and diffusion imaging study. *Brain Research Bulletin*, 84(2), 189–195. <https://doi.org/10.1016/j.brainresbull.2010.12.002>
- Misaki, M., Wallace, G. L., Dankner, N., Martin, A., & Bandettini, P. A. (2012). Characteristic cortical thickness patterns in adolescents with autism spectrum disorders: Interactions with age and intellectual ability revealed by canonical correlation analysis. *Neuroimage*, 60(3), 1890–1901. <https://doi.org/10.1016/j.neuroimage.2012.01.120>
- Mohammad-Rezazadeh, I., Frohlich, J., Loo, S. K., & Jeste, S. S. (2016). Brain connectivity in autism spectrum disorder. *Current Opinion in Neurology*, 29(2), 137–147. <https://doi.org/10.1097/WCO.0000000000000301>
- Moon, S. J., Hwang, J., Kana, R., Torous, J., & Kim, J. W. (2019). Accuracy of machine learning algorithms for the diagnosis of autism spectrum disorder: Systematic review and meta-analysis of brain magnetic resonance imaging studies. *JMIR Mental Health*, 6(12), e14108. <https://doi.org/10.2196/14108>
- Moradi, E., Khundrakpam, B., Lewis, J. D., Evans, A. C., & Tohka, J. (2017). Predicting symptom severity in autism spectrum disorder based on cortical thickness measures in agglomerative data. *Neuroimage*, 144(Pt A), 128–141. <https://doi.org/10.1016/j.neuroimage.2016.09.049>
- Narzisi, A., Muratori, F., Calderoni, S., Fabbro, F., & Urgesi, C. (2013). Neuropsychological profile in high functioning autism spectrum disorders. *Journal of Autism and Developmental Disorders*, 43(8), 1895–1909. <https://doi.org/10.1007/s10803-012-1736-0>
- Nestor, P. G., Nakamura, M., Niznikiewicz, M., Levitt, J. J., Newell, D. T., Shenton, M. E., & McCarley, R. W. (2015). Attentional control and intelligence: MRI orbital frontal gray matter and neuropsychological correlates. *Behavioural Neurology*, 2015, 1. <https://doi.org/10.1155/2015/354186>
- Nogay, H. S., & Adeli, H. (2020). Machine learning (ML) for the diagnosis of autism spectrum disorder (ASD) using brain imaging. *Reviews in the Neurosciences*, 31, 825–841. <https://doi.org/10.1515/revneuro-2020-0043>
- Nordahl, C. W., Dierker, D., Mostafavi, I., Schumann, C. M., Rivera, S. M., Amaral, D. G., & Van Essen, D. C. (2017). Cortical folding abnormalities in autism revealed by surface-based morphometry. *Journal of Neuroscience*, 27(43), 11725–11735. <https://doi.org/10.1523/JNEUROSCI.0777-07.2007>
- Pagnozzi, A. M., Conti, E., Calderoni, S., Fripp, J., & Rose, S. E. (2018). A systematic review of structural MRI biomarkers in autism spectrum disorder: A machine learning perspective. *International Journal of Developmental Neuroscience*, 71, 68–82. <https://doi.org/10.1016/j.ijdevneu.2018.08.010>
- Pardini, M., Garaci, F. G., Bonzano, L., Roccatagliata, L., Palmieri, M. G., Pompili, E., Coniglione, F., Krueger, F., Ludovici, A., Floris, R., Benassi, F., & Emberti Gialloreti, L. (2009). White matter reduced streamline coherence in young men with autism and mental retardation. *European Journal of Neurology*, 16, 1185–1190. <https://doi.org/10.1111/j.1468-1331.2009.02699.x>
- Rakić, M., Cabezas, M., Kushibar, K., Oliver, A., & Lladó, X. (2020). Improving the detection of autism spectrum disorder by combining structural and functional MRI information. *Neuroimage: Clinical*, 25, 102181. <https://doi.org/10.1016/j.nicl.2020.102181>
- Raznahan, A., Lerch, J. P., Lee, N., Greenstein, D., Wallace, G. L., Stockman, M., Clasen, L., Shaw, P. W., & Giedd, J. N. (2011). Patterns of coordinated anatomical change in human cortical development: A longitudinal neuroimaging study of maturational coupling. *Neuron*, 72(5), 873–884. <https://doi.org/10.1016/j.neuron.2011.09.028>
- Redcay, E. (2008). The superior temporal sulcus performs a common function for social and speech perception: Implications for the emergence of autism. *Neuroscience and Biobehavioral Reviews*, 32, 123–142. <https://doi.org/10.1016/j.neubiorev.2007.06.004>
- Retico, A., Gori, I., Giuliano, A., Muratori, F., & Calderoni, S. (2016). One-class support vector machines identify the language and default mode regions as common patterns of structural alterations in young children with autism spectrum disorders. *Frontiers in Neuroscience*, 10, 306. <https://doi.org/10.3389/fnins.2016.00306>
- Richards, R., Greimel, E., Kliemann, D., Koerte, I. K., Schulte-Körne, G., Reuter, M., & Wachinger, C. (2020). Increased hippocampal shape asymmetry and volumetric ventricular asymmetry in autism spectrum disorder. *Neuroimage: Clinical*, 26, 102207. <https://doi.org/10.1016/j.nicl.2020.102207>
- Richter, J., Henze, R., Vomstein, K., Stieltjes, B., Parzer, P., Haffner, J., Brandeis, D., & Poustka, L. (2015). Reduced cortical thickness and its association with social reactivity in children with autism spectrum disorder. *Psychiatry Research*, 234(1), 15–24. <https://doi.org/10.1016/j.psychres.2015.06.011>
- Sabuncu, M. R., & Konukoglu, E. (2015). Clinical prediction from structural brain MRI scans: A large-scale empirical study. *Neuroinformatics*, 13, 31–46. <https://doi.org/10.1007/s12021-014-9238-1>
- Sarovic, D., Hadjikhani, N., Schneiderman, J., Lundström, S., & Gillberg, C. (2020). Autism classified by magnetic resonance imaging: A pilot study of a potential diagnostic tool. *International Journal of Methods in Psychiatric Research*, 29(4), 1–18. <https://doi.org/10.1002/mpr.1846>
- Sato, J. R., Hoexter, M. Q., Oliveira, P. P. Jr, Brammer, M. J., Murphy, D., & Ecker, C. (2013). Inter-regional cortical thickness correlations are associated with autistic symptoms: A machine-learning approach. *Journal of Psychiatric Research*, 47(4), 453–459. <https://doi.org/10.1016/j.jpsychores.2012.11.017>
- Scheel, C., Rotarska-Jagiela, A., Schilbach, L., Lehnhardt, F. G., Krug, B., Vogele, K., & Tepest, R. (2011). Imaging derived cortical thickness reduction in high-functioning autism: Key regions and temporal slope. *Neuroimage*, 58(2), 391–400. <https://doi.org/10.1016/j.neuroimage.2011.06.040>
- Sharda, M., Foster, N. E. V., Tryfon, A., Krissy, A. R., Doyle, T., Ouimet, T., Anagnostou, E., Evans, A. C., Zwaigenbaum, L., Lerch, J. P., Lewis, J. D., & Hyde, K. L., for (2017). Language ability predicts cortical structure and covariance in boys with autism spectrum disorder. *Cerebral Cortex*, 27(3), 1849–1862. <https://doi.org/10.1093/cercor/bhw024>
- Sharda, M., Khundrakpam, B. S., Evans, A. C., & Singh, N. C. (2016). Disruption of structural covariance networks for language in autism is modulated by verbal ability. *Brain Structure and Function*, 221(2), 1017–1032. <https://doi.org/10.1007/s00429-014-0953-z>
- Shaw, P., Kabani, N. J., Lerch, J. P., Eckstrand, K., Lenroot, R., Gogtay, N., Greenstein, D., Clasen, L., Evans, A., Rapoport, J. L., Giedd, J. Y., & Wise, S. P. (2008). Neurodevelopmental trajectories of the human cerebral cortex. *Journal of Neuroscience*, 28, 3586–3594. <https://doi.org/10.1523/JNEUROSCI.5309-07.2008>
- Spera, G., Retico, A., Bosco, P., Ferrari, E., Palumbo, L., Oliva, P., Muratori, F., & Calderoni, S. (2019). Evaluation of altered functional connections in male children with autism spectrum disorders on multiple-site data optimized with machine learning. *Frontiers in Psychiatry*, 10, 620. <https://doi.org/10.3389/fpsy.2019.00620>
- Squarcina, L., Dagnew, T. M., Rivolta, M. W., Bellani, M., Sassi, R., & Brambilla, P. (2019). Automated cortical thickness and skewness feature selection in bipolar disorder using a semi-supervised learning method. *Journal of Affective Disorders*, 256, 416–423. <https://doi.org/10.1016/j.jad.2019.06.019>
- Subbaraju, V., Sundaram, S., Narasimhan, S., & Suresh, M. B. (2015). Accurate detection of autism spectrum disorder from structural MRI using extended metacognitive radial basis function network. *Expert Systems with Applications*, 42, 8775–8790. <https://doi.org/10.1016/j.eswa.2015.07.031>

- Tordjman, S., Somogyi, E., Coulon, N., Kermarrec, S., Cohen, D., Bronsard, G., Bonnot, O., Weismann-Arcache, C., Botbol, M., Lauth, B., Ginchat, V., Roubertoux, P., Barburth, M., Kovess, V., Geoffroy, M.-M., & Xavier, J. (2014). Gene \times Environment interactions in autism spectrum disorders: Role of epigenetic mechanisms. *Frontiers in Psychiatry*, *5*, 53. <https://doi.org/10.3389/fpsy.2014.00053>
- Urbain, C., Vogan, V. M., Ye, A. X., Pang, E. W., Doesburg, S. M., & Taylor, M. J. (2016). Desynchronization of fronto-temporal networks during working memory processing in autism. *Human Brain Mapping*, *37*(1), 153–164. <https://doi.org/10.1002/hbm.23021>
- van Rooij, D., Anagnostou, E., Arango, C., Auzias, G., Behrmann, M., Busatto, G. F., Calderoni, S., Daly, E., Deruelle, C., Di Martino, A., Dinstein, I., Souza Duran, F. L., Durston, S., Ecker, C., Fair, D., Fedor, J., Fitzgerald, J., Freitag, C. M., Gallagher, L., ... Buitelaar J. K. (2018) Cortical and subcortical brain morphometry differences between patients with autism spectrum disorder and healthy individuals across the lifespan: Results from the ENIGMA ASD working group. *American Journal of Psychiatry*, *175*(4), 359–369. <https://doi.org/10.1176/appi.ajp.2017.17010100>
- Vapnik, V. (2013). *The nature of statistical learning theory*. Springer Science & Business Media.
- Wass, S. (2011) Distortions and disconnections: Disrupted brain connectivity in autism. *Brain and Cognition*, *75*(1), 18–28. doi:10.1016/j.bandc.2010.10.005 <https://doi.org/10.1016/j.bandc.2010.10.005>
- Whiteside, S. P., Port, J. D., & Abramowitz, J. S. (2004). A meta-analysis of functional neuroimaging in obsessive-compulsive disorder. *Psychiatry Research*, *132*, 69–79. <https://doi.org/10.1016/j.psychres.2004.07.001>
- Xiao, X., Fang, H., Wu, J., Xiao, C., Xiao, T., Qian, L., Liang, F., Xiao, Z., Chu, K. K., & Ke, X. (2017). Diagnostic model generated by MRI-derived brain features in toddlers with autism spectrum disorder. *Autism Research*, *10*, 620–630. <https://doi.org/10.1002/aur.1711>
- Zocante, L., Viviani, A., Ferro, A., Cerini, R., Cerruti, S., Rambaldelli, G., Bellani, M., Dusi, N., Perlini, C., Boscaini, F., Pozzi Mucelli, R., Tansella, M., Dalla Bernardina, B., & Brambilla, P. (2010) Increased left parietal volumes relate to delayed language development in autism: A structural mri study. *Functional Neurology*, *25*(4), 217–21.

SUPPORTING INFORMATION

Additional supporting information may be found online in the Supporting Information section at the end of the article.

How to cite this article: Squarcina, L., Nosari, G., Marin, R., Castellani, U., Bellani, M., Bonivento, C., Fabbro, F., Molteni, M., & Brambilla, P. (2021). Automatic classification of autism spectrum disorder in children using cortical thickness and support vector machine. *Brain and Behavior*, *11*, e2238. <https://doi.org/10.1002/brb3.2238>