



Contents lists available at ScienceDirect

## International Journal of Surgery Case Reports

journal homepage: [www.casereports.com](http://www.casereports.com)

# Associating liver partition and portal vein ligation for a patient with hepatocellular carcinoma with a background of hepatitis B related fibrotic liver



Nam Hung Chia<sup>a</sup>, Eric C.H. Lai<sup>b</sup>, Wan Yee Lau<sup>c,\*</sup>

<sup>a</sup> Department of Surgery, Queen Elizabeth Hospital, Hong Kong SAR, China

<sup>b</sup> Department of Surgery, Pamela Youde Nethersole Eastern Hospital, Hong Kong SAR, China

<sup>c</sup> Faculty of Medicine, The Chinese University of Hong Kong, Shatin, Hong Kong SAR, China

## ARTICLE INFO

### Article history:

Received 4 July 2014

Received in revised form 30 October 2014

Accepted 2 November 2014

Available online 8 November 2014

### Keywords:

ALPPS

PPVE

Trisectionectomy

Future liver remnant

Hepatocellular carcinoma

Hepatitis B

## ABSTRACT

**INTRODUCTION:** Associating liver partition and portal vein ligation for staged hepatectomy (ALPPS) has recently been developed for patients with predicted insufficient future liver remnant volumes to induce more rapid hepatic hypertrophy and increase resectability. In the medical literature, the use of ALPPS in hepatocellular carcinoma (HCC) has rarely been reported.

**PRESENTATION OF CASE:** We reported the use of ALPPS in a patient with primarily unresectable HCC arising from a background of hepatitis B related liver fibrosis. Preoperative computed tomography (CT) showed 2 large conglomerated tumors measuring 16 cm × 10.5 cm in liver segments 5, 6, 7 and 8, and at least 3 satellite nodules with the largest one measuring 3 cm around the main tumor and another 4 cm tumor in segment 4. Right trisectionectomy after ALPPS was successfully performed. He was discharged from hospital on postoperative day 13 after the second operation. Follow-up CT scan at 6 weeks after the second operation showed further hypertrophy of the liver remnant and no liver recurrence.

**DISCUSSION:** Our case showed that this novel strategy is feasible even in the context of a background of chronic hepatitis B related liver fibrosis, although the hypertrophy rate was a little bit slower and the time needed was longer.

**CONCLUSION:** ALPPS is also feasible in liver fibrosis. It gives hope to patients with HCC who previously were considered as having unresectable diseases. More studies are needed to further evaluate the effectiveness and oncological outcomes of ALPPS from these patients.

© 2014 The Authors. Published by Elsevier Ltd. on behalf of Surgical Associates Ltd. This is an open access article under the CC BY-NC-ND license (<http://creativecommons.org/licenses/by-nc-nd/3.0/>).

## 1. Introduction

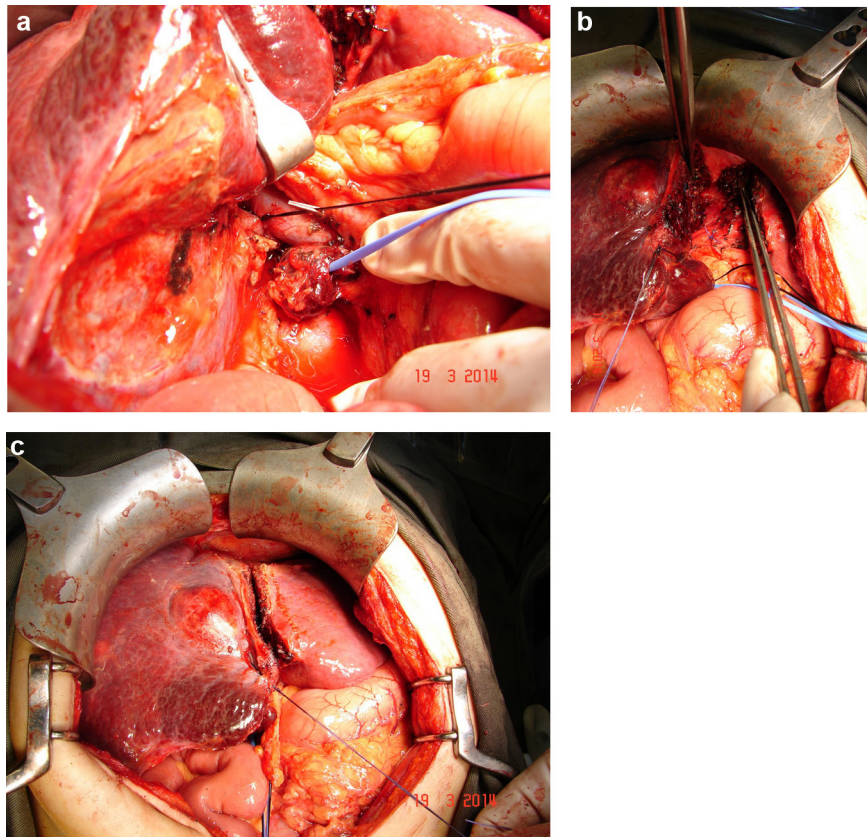
Trisectionectomy has been associated with higher complication rates and increased postoperative liver dysfunction/failure than liver resections involving lesser volumes. Preoperative portal vein embolization (PPVE) and portal vein ligation (PVL) have been used to induce hepatic hypertrophy of future liver remnant and to reduce the risk of post-hepatectomy liver failure in patients who have insufficient future liver remnants.<sup>1,2</sup> To induce more rapid hepatic hypertrophy and to increase resectability, associating liver partition and portal vein ligation for staged hepatectomy (ALPPS) has recently been developed. This technique was first carried out by Dr. Hans Schlitt from Regensburg in 2007 and it was first presented in a German Congress in 2010.<sup>3</sup> The procedure requires

liver parenchymal transection just to the right of the umbilical fissure with simultaneous right portal vein ligation during the first stage of the operation, followed about one to two weeks later by completion right trisectionectomy. The novelty of ALPPS is the marked percentage gain of patients to resectability. To the best of our knowledge, no prospective studies comparing traditional methods (PPVE, PVL or two staged hepatectomy strategy) with ALPPS are now available. The retrospective study of Schadde et al. showed the extrapolated growth rate in ALPPS was 11 times higher (34.8 ml/day) than PPVE/PVL (3 ml/day).<sup>4</sup> Despite the sudden increase in reports on ALPPS during the last 2 years, a lot of questions concerning the safety and effectiveness of ALPPS remained unanswered. Currently, ALPPS is still considered to be in an early development phase, and its indications and techniques are not standardized.

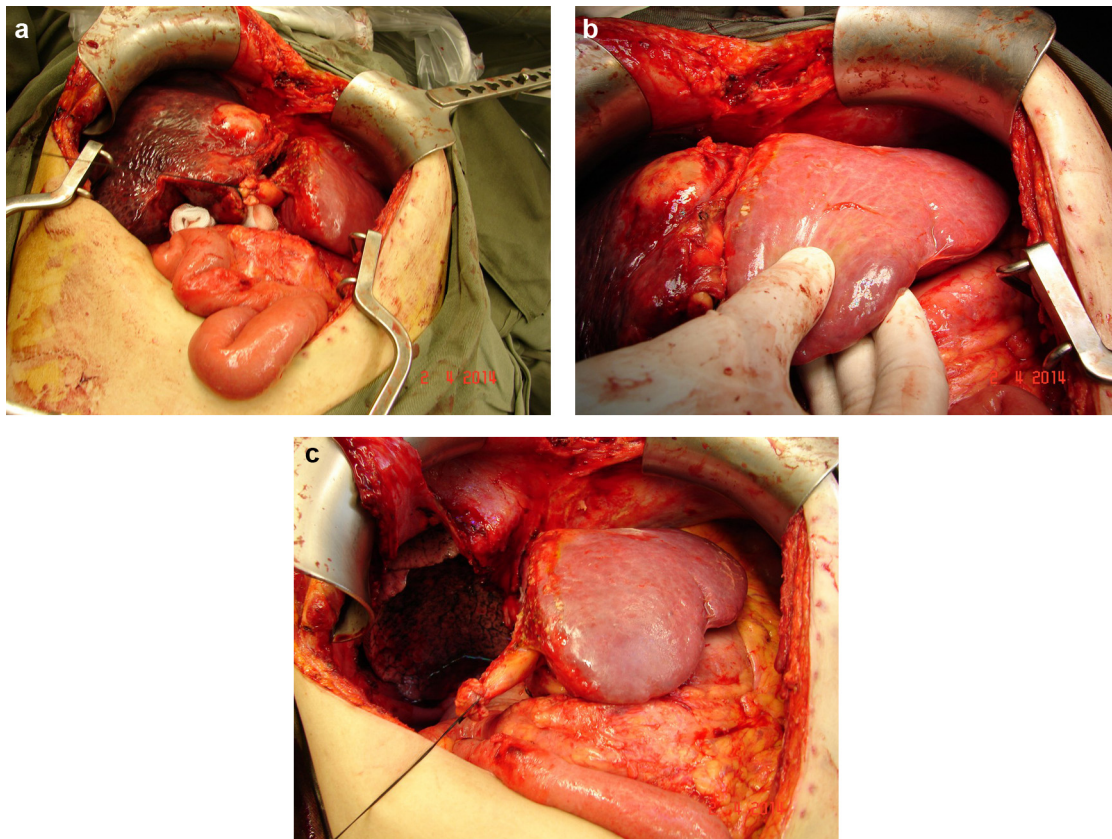
In the literature, the use of ALPPS in hepatocellular carcinoma (HCC) has rarely been reported. The majority of reports were on colorectal liver metastases and hilar cholangiocarcinoma arising in normal livers. We reported the use of ALPPS in a patient with a large HCC with hepatitis B related liver fibrosis.

\* Corresponding author at: Faculty of Medicine, The Chinese University of Hong Kong, Shatin, New Territories, Hong Kong SAR, China. Tel.: +852 2632 2626; fax: +852 2637 7974.

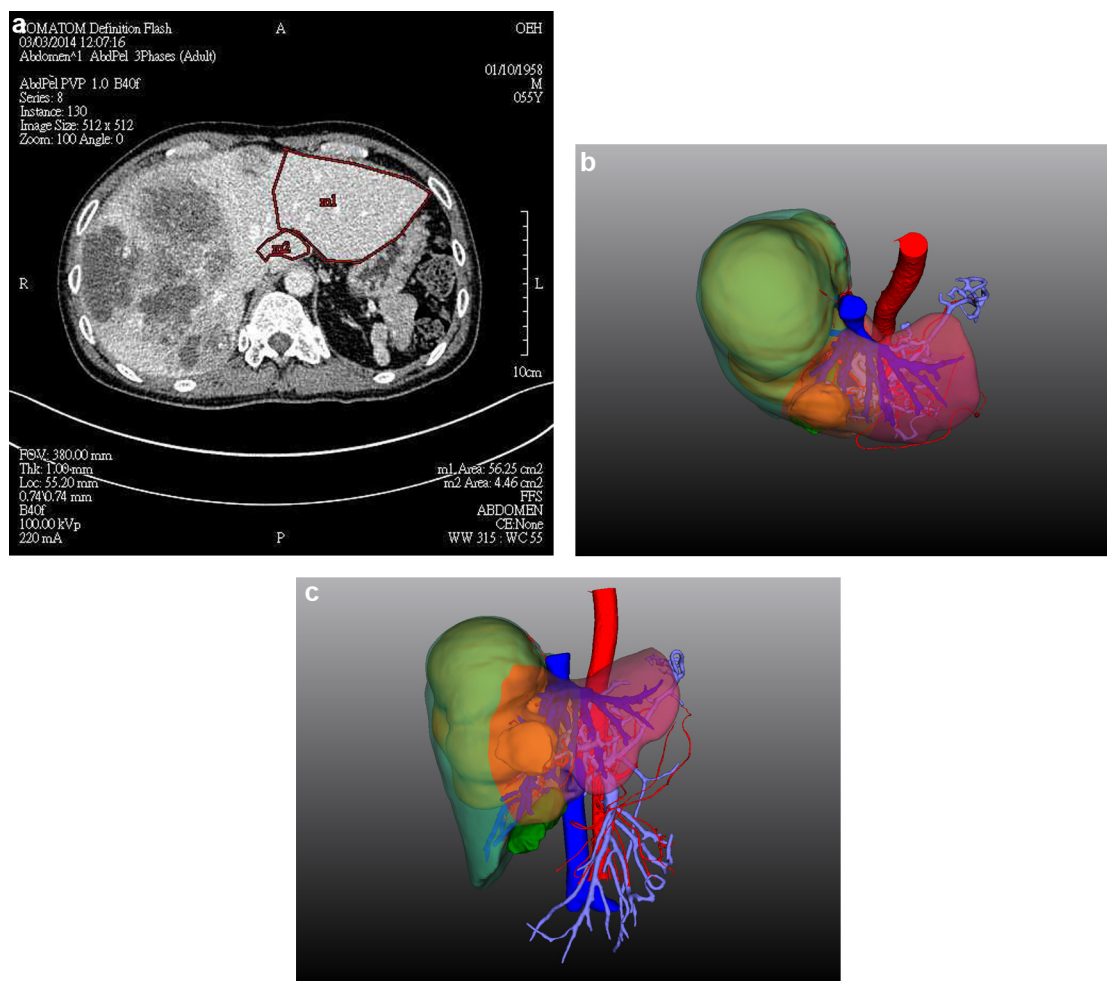
E-mail address: [josephlau@cuhk.edu.hk](mailto:josephlau@cuhk.edu.hk) (W.Y. Lau).



**Fig. 1.** (a) Right portal vein ligation in first stage of operation. (b) Liver parenchymal transection for right trisectionectomy (segments 4–8) at the right side of the falciform ligament. (c) Operative view after the first stage of operation.



**Fig. 2.** (a) Operative view during the second stage of operation. (b) Significant hypertrophy of segments 2 and 3 in the second stage of operation. (c) Post completion right trisectionectomy in the second stage of operation.



**Fig. 3.** (a) CT scan with volumetry before the first stage of operation. (b) CT scan with 3D reconstruction before the first stage of operation. (c) CT scan with 3D reconstruction before the first stage of operation.

## 2. Presentation of case

A 55-year-old male presented with epigastric discomfort and recent weight loss of 4.5 kg. He had a history of hepatitis B related cirrhosis and a history of splenectomy for traumatic injury many years ago. His contrast enhanced computed tomography (CT) showed 2 large conglomerated tumors, one measuring 16 cm × 10.5 cm in segments 5, 6, 7 and 8, and another 4 cm in segment 4. There were at least 3 satellite nodules around the main tumor, with the largest one measuring 3 cm. His liver function showed bilirubin, 7 μmol/L; albumin, 31 g/L; prothrombin time, 13.5-s; creatinine, 77 μmol/L; hemoglobin, 14.1 g/dL; platelet count,  $435 \times 10^9 \text{ L}^{-1}$ . Indocyanine green retention rate at 15 min (ICG-R15) was 9.3%. Alpha-fetoprotein (AFP) level was 3044 ng/ml. Entecavir (Baraclude) was started before the operation.

### 2.1. Procedure: upper midline incision was used in the first operation

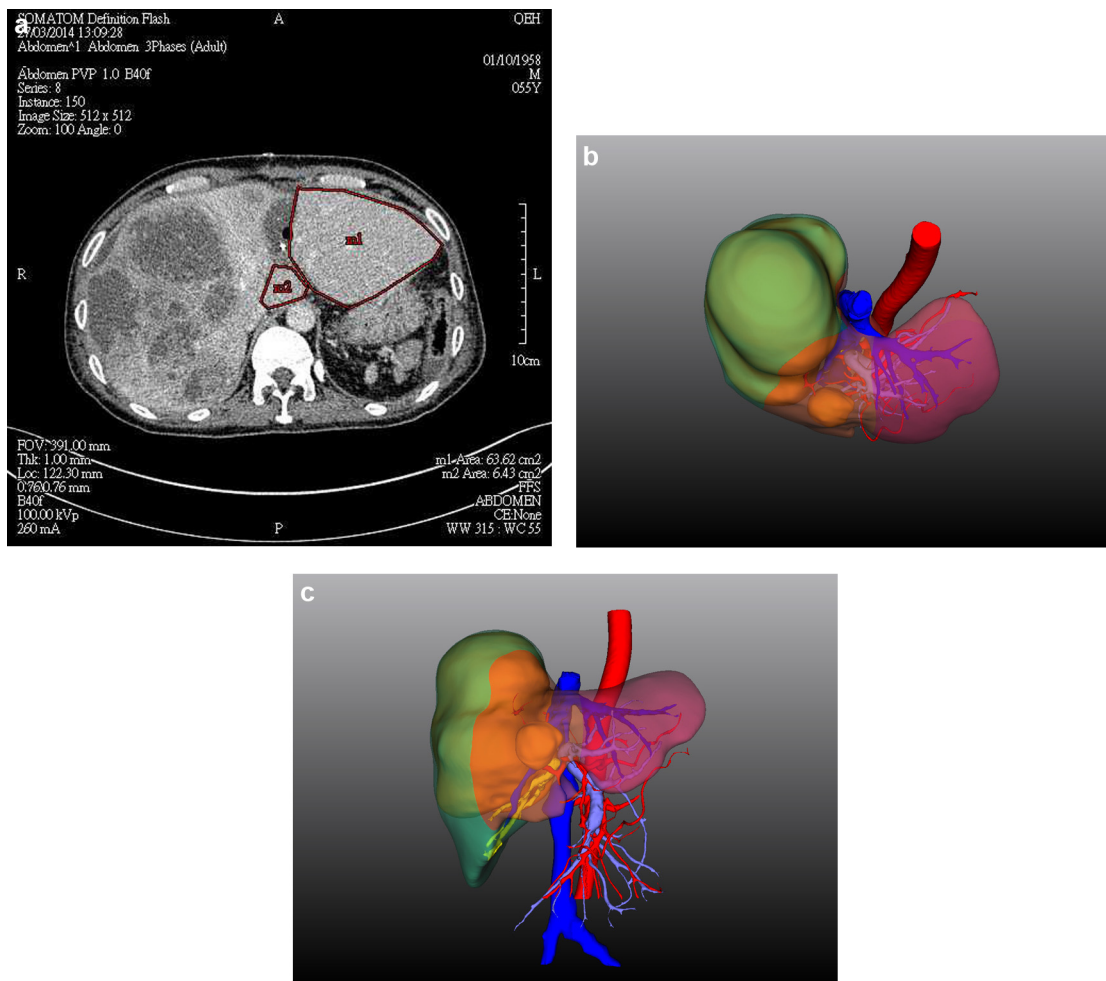
At the first operation only the round ligament and the falciform ligament were divided and both sides of the liver were not mobilized. A thorough exploration and intraoperative ultrasound (IOUS) were used to assess and stage the liver tumors. Cholecystectomy was performed before the right hilar dissection. The right portal vein was ligated with strong silk tie and was not divided. The right hepatic artery and the right hepatic duct were identified, were not isolated separately, and marked with vessel loops. Liver

parenchymal transection was carried out on the right side of the falciform ligament using a CUSA (Cavitron Ultrasonic Surgical Aspirator). The segment 4 pedicles were transected with endostaplers. A leak test was performed via the cystic duct and it confirmed no bile leakage in the liver transection plane. No wrapping/interposition material at the transection surface was used. A silicone drain was inserted near the transection surface (Fig. 1a–c).

After CT scan with volumetric assessment, the second phase of the operation was performed 14 days after the first operation. In the second operation, a right transverse abdominal incision was added in addition to the midline incision in the first operation. The right liver was then mobilized from the inferior vena cava (IVC), and all the retrohepatic veins draining the right liver were ligated and divided. The right hepatic duct, right portal vein, right hepatic artery, right hepatic vein and middle hepatic vein were divided with endostaplers and the tumor-bearing liver was removed with a 11.5 cm × 6 cm patch of diaphragm. The diaphragm was repaired directly without any mesh. A 16Fr chest drain was inserted (Fig. 2a–c). No Pringle maneuver was needed during these two operations.

### 2.2. Volumetric assessment

CT scan with volumetry assessment was performed before the first operation and at completion of surgery. 3-Dimensional (3D) CT scan reconstruction was also performed using Yortal 3D reconstruction system (Yortal Digital Medical Imaging Tech Co. Ltd.,



**Fig. 4.** (a) CT scan with volumetry at 8 days after the first stage of operation. (b) CT scan with 3D reconstruction at 8 days after the first stage of operation. (c) CT scan with 3D reconstruction at 8 days after the first stage of operation.

China). The preoperative remnant liver volume to total liver volume ratio (RLV/TLV) ratio was 26.9%. After 8 days, the RLV/TLV ratio increased to 37.4%. The FLV (segments 2, 3 and part of segment 1) increased from 383 ml to 532 ml (Figs. 3a–c and 4a–c).

### 2.3. Operative parameters and post-operative course

At the first operation, the operating time was 231 min, and blood loss was 500 ml. At the second operation, the operating time was 198 min, and blood loss was 700 ml. No perioperative blood transfusion was needed. The patient resumed oral diet intake on post-operative day 2 after the first and the second operations. He had a transient increase in drain output of ascitic fluid after the second operation, which subsided with medical treatment. His liver function recovered gradually and he had no bile leak. The patient was discharged home on postoperative day 13 after the second operation.

### 2.4. Histopathology

Histopathology confirmed a 16.5 cm × 10.5 cm × 18 cm HCC in the right liver and a 3.2 cm HCC in segment 4, with Edmondson & Steiner grade 3 and pT3a. These were extensive tumor necrosis and presence of microscopic vascular invasion but no definite portal vein tumor thrombus. The resection margins were clear. The liver parenchyma showed chronic hepatitis changes with bridging fibrosis.

### 2.5. Follow-up

Follow-up CT scan at 6 weeks after the second operation showed further hypertrophy of the liver remnant. There was no recurrence (Fig. 5). He remained well at 2 months after the ALPPS. The AFP level at 6 weeks after operation was 6 ng/ml.

## 3. Discussion

ALPPS has been adopted all over the world in the past 2 years, even though the oncological long-term results remain unknown, and benefit for patients is still questionable. Even if the oncologic outcomes are acceptable, it remains controversial whether the gain in quality of life and survival could balance the high risks of complication and mortality. The current evidence suggested that ALPPS offered a better chance of complete resection in patients who had primarily unresectable liver tumors at the cost of high operation morbidity and mortality. The morbidity rate has been reported to be as high as 70%, with high rates of procedure-related deaths of about 15%.<sup>4–9</sup> Bile leakage from the raw surface of the liver and septic events secondary to ischemic necrosis of liver were the most common complications. Another major question which remained unanswered is whether stimulation of liver hypertrophy could also accelerate tumor progression. This is a question which has been debated since the time of PPVE/PVL techniques. Many reports showed accelerated tumor growth after PPVE is of major

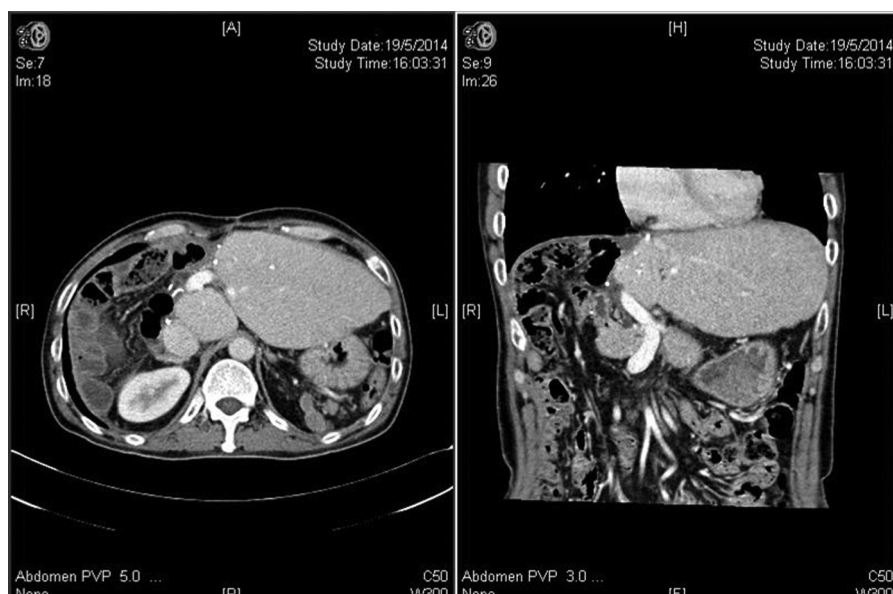


Fig. 5. Follow-up CT scan at 6 weeks after the 2nd operation showing further hypertrophy of the liver remnant and no disease recurrence.

concern and requires consideration of post-PVE chemotherapy.<sup>10,11</sup> Thus, ALPPS also has a potential to promote tumor recurrence and progression. Recently, Oldhafer et al. reported that for the 10 patients with unresectable colorectal liver metastases who underwent ALPPS, 6 of the 7 patients who had a follow-up of at least 3 months developed tumor recurrence in the liver. In addition, 3 of the 7 patients developed lung metastases, which appeared earlier than the liver metastases in 2 of the 3 patients. The remaining patient with a follow-up of 3 months had no radiological recurrent disease, but had increasing carcinoembryonic antigen (CEA) levels.<sup>12</sup> Whether the rapid hypertrophy itself promotes tumor recurrence remains uncertain and this requires further investigation.

Several series in the medical literature described a median of 74–110% increase in FRL volume at a median of 9–15 days between the 2 steps of the operation.<sup>4–9</sup> These livers were mainly normal liver. Our case showed that this novel strategy was feasible even with a chronic hepatitis B related liver fibrosis, although the hypertrophy rate was slower and the time frame needed for the 2 stages of operation was longer.

In conclusion, ALPPS is also feasible in hepatitis B related liver fibrosis. It gives a hope of cure for patients with unresectable disease. More studies are needed to further evaluate its effectiveness and oncological outcomes.

#### Conflict of interest

All authors had no conflict of interest.

#### Funding

There is no financial support for this study.

#### Ethical approval

Not applicable.

#### Open Access

This article is published Open Access at [sciedirect.com](http://sciedirect.com). It is distributed under the [IJSCR Supplemental terms and conditions](#), which permits unrestricted non commercial use, distribution, and reproduction in any medium, provided the original authors and source are credited.

#### Authors contribution

Chia NH: patient management, surgery, acquisition of data and editing the article.

Lai ECH: analysis and interpretation of data, drafting and editing the article.

Lau WY: literature review, decision making and final revision of the article.

#### References

- Makuuchi M, Thai BL, Takayasu K, Takayama T, Kosuge T, Gunvén P, et al. Pre-operative portal embolization to increase safety of major hepatectomy for hilar bile duct carcinoma: a preliminary report. *Surgery* 1990;**107**:521–7.
- Capussotti L, Muratore A, Baracchi F, Lelong B, Ferrero A, Regge D, et al. Portal vein ligation as an efficient method of increasing the future liver remnant volume in the surgical treatment of colorectal metastases. *Arch Surg* 2008;**143**:978–82.
- Schnitzbauer AA, Lang SA, Goessmann H, Nadalin S, Baumgart J, Farkas SA, et al. Right portal vein ligation combined with in situ splitting induces rapid left lateral liver lobe hypertrophy enabling 2-staged extended right hepatic resection in small-for-size settings. *Ann Surg* 2012;**255**:405–14.
- Schadde E, Ardiles V, Slankamenac K, Tschuor C, Sergeant G, Amacker N, et al. ALPPS offers a better chance of complete resection in patients with primarily unresectable liver tumors compared with conventional-staged hepatectomies: results of a multicenter analysis. *World J Surg* 2014;**38**:1510–9.
- Vennarecci G, Laurenzi A, Levi Sandri GB, Busi Rizzi E, Cristofaro M, Montalbano M, et al. The ALPPS procedure for hepatocellular carcinoma. *Eur J Surg Oncol* 2014;**40**:982–8.
- Li J, Girotti P, Königsrainer I, Ladurner R, Königsrainer A, Nadalin S. ALPPS in right trisectionectomy: a safe procedure to avoid postoperative liver failure? *J Gastrointest Surg* 2013;**17**:956–61.
- Alvarez FA, Ardiles V, Sanchez Claria R, Pekolj J, de Santibañes E. Associating liver partition and portal vein ligation for staged hepatectomy (ALPPS): tips and tricks. *J Gastrointest Surg* 2013;**17**:814–21.
- Torres OJ, Fernandes Ede S, Oliveira CV, Lima CX, Waechter FL, Moraes-Junior JM, et al. Associating liver partition and portal vein ligation for staged hepatectomy (ALPPS): the Brazilian experience. *Arq Bras Cir Dig* 2013;**26**:40–3.
- Ielso B, Caruso R, Ferri V, Quijano Y, Duran H, Diaz E, et al. ALPPS procedure: our experience and state of the art. *Hepatogastroenterology* 2013;**60**:2069–75.
- Hoekstra LT, van Lienden KP, Doets A, Busch OR, Gouma DJ, van Gulik TM. Tumor progression after preoperative portal vein embolization. *Ann Surg* 2012;**256**:812–7.
- Simoneau E, Aljiffry M, Salman A, Abualhassan N, Cabrera T, Valenti D, et al. Portal vein embolization stimulates tumour growth in patients with colorectal cancer liver metastases. *HPB (Oxford)* 2012;**14**:461–8.
- Oldhafer KJ, Donati M, Jenner RM, Stang A, Stavrou GA. ALPPS for patients with colorectal liver metastases: effective liver hypertrophy, but early tumor recurrence. *World J Surg* 2014;**38**:1504–9.