


CASE REPORT

Pleural metastasis detected by transesophageal endoscopic ultrasonography

Surinder S Rana,*  Parikshaa Gupta,† Ravi K Sharma* and Rajesh Gupta‡

Departments of *Gastroenterology, †Cytology and Gynaecologic Pathology and Surgery, Post Graduate Institute of Medical Education and Research and

‡Department of Surgery, Post Graduate Institute of Medical Education and Research (PGIMER), Chandigarh, India

Key words

adenocarcinoma, ascites, endosonography, pleura, pleural effusion.

Accepted for publication 4 January 2019.

Correspondence

Dr Surinder S Rana, Department of Gastroenterology, Post Graduate Institute of Medical Education and Research, Chandigarh 160 012, India.

Email: drsurinderrana@yahoo.co.in

Declaration of conflict of interest: There are no conflicts of interest and no financial disclosures to be made.

Author contribution: Surinder Singh Rana contributed to the design, collection, and interpretation of data and drafting of manuscript. Parikshaa Gupta, Ravi Sharma, and Rajesh Gupta contributed to the collection and interpretation of data.

Introduction

The underlying etiology of ascites and pleural effusion can be diagnosed in majority of patients with the cytological and biochemical analysis of ascitic and pleural fluid. However, in some patients, repeated fluid analysis is inconclusive, and these patients usually require surgical or laparoscopic techniques to establish the underlying etiology. In this report, we report a 62-year-old male with malignant pleural effusion as well as ascites that was diagnosed by endoscopic ultrasound guided fine needle aspiration of the pleural deposit.

Case report

A 62-year-old male presented elsewhere with abdominal distension. Computed tomography demonstrated ascites and right-sided pleural effusion. Ascitic fluid analysis showed exudative fluid with negative malignant cytology and an elevated adenosine deaminase level (ADA) of 47 IU per liter. Polymerase chain reaction testing for *Mycobacterium tuberculosis* was positive in the ascitic fluid. There was no response to 3 weeks of antitubercular therapy (ATT), and the patient needed therapeutic paracentesis for increasing abdominal distension. Repeat ascitic and

Abstract

Patients with pleural effusion and inconclusive repeated pleural fluid biochemical and cytological analysis are a diagnostic dilemma that is usually solved by invasive procedures such as diagnostic thoracoscopy. We report a 62-year-old male with malignant pleural effusion as well as ascites who was diagnosed using endoscopic ultrasound-guided fine-needle aspiration of pleural deposit. We also report contrast enhanced endoscopic ultrasound findings of pleural deposits.

pleural fluid analysis demonstrated elevated ADA and negative malignant cytology. Endoscopic ultrasound (EUS) was conducted to evaluate for peritoneal deposits. The linear echoendoscope was nonnegotiable across the gastroesophageal junction (GEJ). EUS conducted from the GEJ showed a markedly thickened fourth layer of stomach along with right-sided pleural effusion. In addition, well-defined, rounded, and hypochoic pleural deposits were noted in the mediastinodiaphragmatic recess (Fig. 1a; arrows). On contrast EUS, pleural deposits showed peripheral enhancement (Fig. 1b; arrows). EUS-guided fine-needle aspiration (FNA) was performed with a 22 G needle using a 10 mL syringe for suction (Fig. 1c), and cytological examination demonstrated the presence of tumor cells with nuclear pleomorphism, suggestive of metastatic adenocarcinoma (Fig. 1d; May Grunwald Giemsa, 20×). ATT was stopped, and the patient was referred to oncology services for further management.

Discussion

Ascites and pleural effusion can occur because of numerous etiologies. The cytological and biochemical analysis of ascitic and pleural fluid can provide an underlying etiology of ascites as well

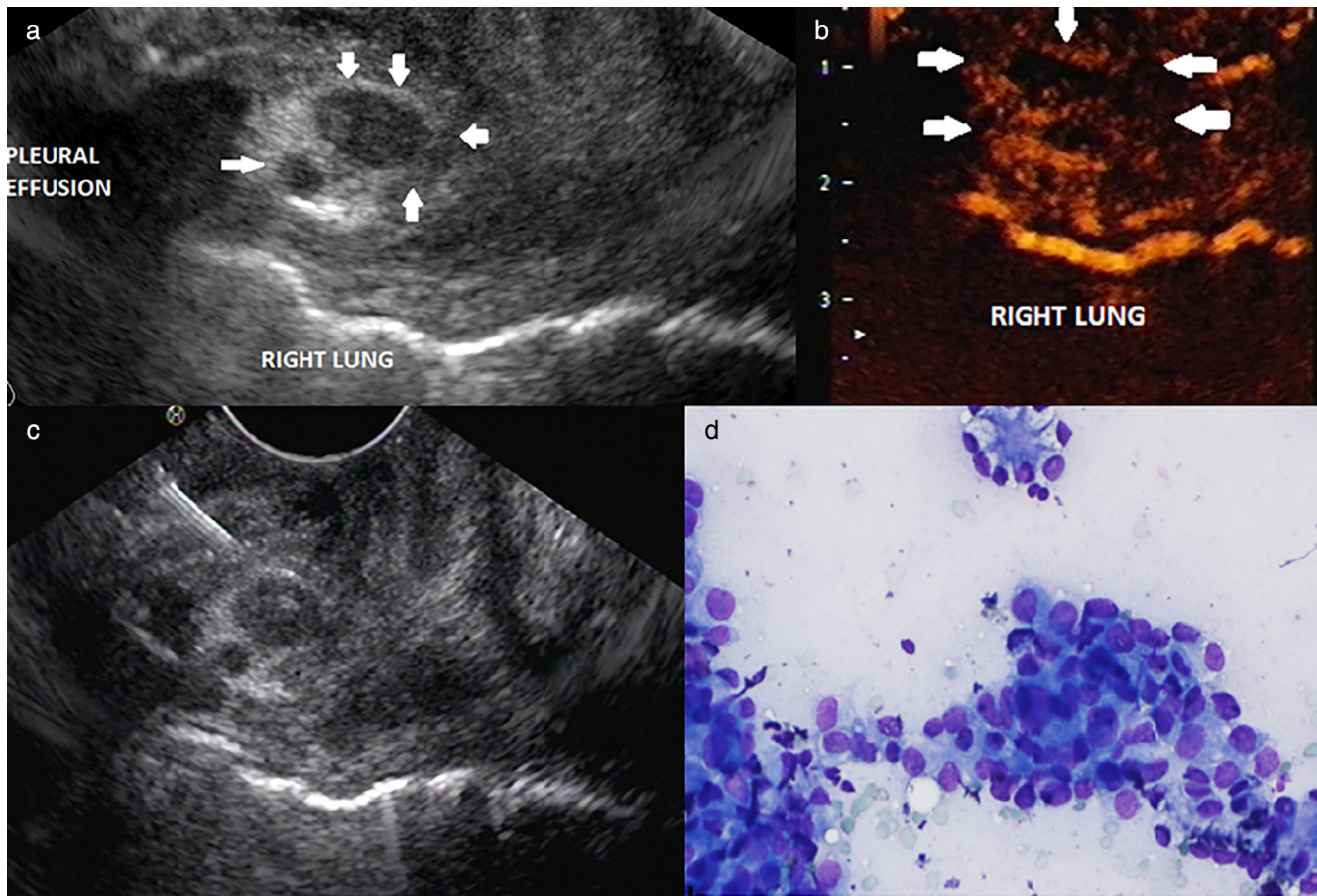


Figure 1 (a) Endoscopic ultrasound (EUS): Well-defined, rounded, and hypoechoic pleural deposits in the mediastinodiaphragmatic recess (arrows). (b) Contrast EUS: Pleural deposits showed peripheral enhancement (arrows). (c) EUS-guided fine-needle aspiration of pleural deposits being performed with a 22 G needle. (d) Cytological examination demonstrated the presence of tumor cells with nuclear pleomorphism, suggestive of metastatic adenocarcinoma (May Grunwald Giemsa, 20x).

as pleural effusion in the majority of patients.¹ However, in some patients, repeated fluid analysis is inconclusive, and these patients continue to be a diagnostic dilemma, which is usually solved by invasive procedures like diagnostic laparoscopy or thoracoscopy.

Patients with malignant as well as tubercular ascites and pleural effusion have peritoneal, pleural, and omental deposits.^{1,2} These peritoneal as well as pleural deposits are too small to be visualized and sampled on conventional cross-sectional imaging.^{1–3} However, EUS provides high-resolution images because of the close proximity of the transducer to the imaged organ and can therefore visualize these small deposits. Studies have shown that EUS can help in identifying as well as sampling small peritoneal deposits with high accuracy.^{1–4}

EUS is also a better modality to evaluate mediastinum, pleura, and pleural effusion from the esophagus.⁵ The visualization of the mediastinal aspect of pleura is easily accomplished by EUS, whereas complete examination of diaphragmatic and costal pleura is difficult, but a considerable amount of pleura can be visualized on EUS in cases of pleural effusion as fluid provides a good window for EUS

examination.⁵ It has also been shown that the minimal amount of pleural fluid which cannot be tapped or aspirated by any other imaging modality can be safely aspirated under EUS guidance.¹ The septae in the pleural fluid can also be better visualized on EUS, along with better visualization of the collapsed lung with color Doppler. Moreover, the risk of pneumothorax is minimal as the puncture of pleura is performed under vision, with a negligible risk of puncture of the underlying lung.

EUS can also help in the detection of pleural deposits that can be sampled under real-time guidance. However, there are limited data on the safety and efficacy of EUS-guided FNA of pleural deposits in undiagnosed pleural effusion. A case series of four patients published in abstract form demonstrated that EUS-guided FNA of pleural deposits can be safely performed and can establish a diagnosis in patients with undiagnosed pleural effusion.⁶ On EUS, the mediastinal aspect of pleura is easily visualized, and in the presence of pleural effusion, visualization is improved dramatically as fluid provides an excellent window for ultrasound. The anechoic pleural fluid provides a clear background for excellent visualization of the pleural deposits.

References

- 1 Rana SS, Sharma R, Gupta R. Endoscopic ultrasound-guided transesophageal thoracentesis for minimal pleural effusion. *Indian J. Gastroenterol.* 2018; **37**: 231–4.
- 2 Rana SS, Bhasin DK, Srinivasan R, Singh K. Endoscopic ultrasound-guided fine needle aspiration of peritoneal nodules in patients with ascites of unknown cause. *Endoscopy.* 2011; **43**: 1010–13.
- 3 Sharma V, Rana SS, Ahmed SU, Guleria S, Sharma R, Gupta R. Endoscopic ultrasound-guided fine-needle aspiration from ascites and peritoneal nodules: a scoping review. *Endosc. Ultrasound.* 2017; **6**: 382–8.
- 4 Levy MJ, Abu Dayyeh BK, Fujii LL *et al.* Detection of peritoneal carcinomatosis by EUS fine-needle aspiration: impact on staging and resectability (with videos). *Gastrointest. Endosc.* 2015; **81**: 1215–24.
- 5 Sharma M, Rameshbabu CS. Endoscopic ultrasound-guided evaluation of the pleura and cases of pleural effusion. *Lung India.* 2017; **34**: 441–7.
- 6 Sharma M, Somani P. Endoscopic ultrasound-guided fine needle aspiration of pleural deposits. *Endosc. Ultrasound.* 2017; **6** (Suppl. 2): S51.