

# Balloon atrial septostomy and transition of subcutaneous to intravenous prostacyclin infusion for rescuing advanced right heart failure in idiopathic pulmonary arterial hypertension: a case report

Kae-Woei Liang<sup>1,2</sup> and Kuo-Yang Wang<sup>1,3\*</sup> 

<sup>1</sup>Cardiovascular Center, Taichung Veterans General Hospital, No. 1650, Sec. 4, Taiwan Boulevard, Taichung 40705, Taiwan; <sup>2</sup>Department of Medicine, School of Medicine, National Yang Ming University, No. 155, Sec. 2, Linong St. Taipei 11221, Taiwan; and <sup>3</sup>Center for Pulmonary Hypertension and Pulmonary Vascular Disease, School of Medicine and the Affiliated Hospital, China Medical University, Critical Care Center Building 15F, No. 2, Xueshi Road, North District, Taichung 40447, Taiwan

Received 26 October 2019; first decision 19 November 2019; accepted 12 February 2020; online publish-ahead-of-print 3 May 2020

## Background

Intravenous (IV) prostacyclin analogues infusion and balloon atrial septostomy (BAS) are two important treatment options for managing advanced right heart failure in patients with idiopathic pulmonary arterial hypertension (IPAH). References and protocols are rare for dose titrations and transitions between subcutaneous and IV prostacyclin in functional Class IV IPAH patients. Balloon atrial septostomy is rarely done in very few expert centres.

## Case summary

A young female with IPAH who had received maximal medication including subcutaneous prostacyclin analogues injection was admitted due to advanced right heart failure. She received ascites drainage twice. Later, we directly switched the administration route of prostacyclin from subcutaneous to IV at a ratio of 1:1 instantly. Such rapid conversion led her into a state of profound hypotension and drowsy consciousness, which was resolved after escalating IV inotropics and reducing prostacyclin dosage. Five days later, she received BAS under the guidance of intracardiac echocardiography. Her urine output increased and dyspnoea improved gradually. Six months later, clinical worsening happened again with increase of ascites and dyspnoea. She underwent 2nd and 3rd session of graded BAS with relief of symptoms again. She received permanent transition to IV prostacyclin analogues infusions via a peripherally inserted central catheter after three sessions of BAS.

## Discussion

Balloon atrial septostomy is effective in stabilizing the critical right heart failure in IPAH patients but should be intended as a bridge to lung transplant procedure. Transition from subcutaneous to IV prostacyclin is helpful but needs to be titrated in proper aliquots and time intervals to avoid abrupt haemodynamic changes.

## Keywords

Balloon atrial septostomy • Case report • Idiopathic pulmonary arterial hypertension • Intracardiac echocardiography • Prostacyclin analogues

## Learning points

- Balloon atrial septostomy is effective in stabilizing functional Class IV idiopathic pulmonary arterial hypertension (IPAH) patients with critical right heart failure and massive ascites but should be intended as a bridge procedure before lung transplant.
- Transition from subcutaneous to intravenous prostacyclin analogue infusion is helpful in functional Class IV IPAH but needs to be titrated in proper aliquots and time intervals to avoid abrupt haemodynamic changes.

\* Corresponding author. Tel: +886-4-23592525-3121, Email: [wky830@gmail.com](mailto:wky830@gmail.com)

Handling Editor: Timothy Tan

Peer-reviewers: Luca Arcari and Alberto Bouzas-Mosquera

Compliance Editor: Stefan Simovic

Supplementary Material Editor: Peregrine Green

© The Author(s) 2020. Published by Oxford University Press on behalf of the European Society of Cardiology.

This is an Open Access article distributed under the terms of the Creative Commons Attribution Non-Commercial License (<http://creativecommons.org/licenses/by-nc/4.0/>), which permits non-commercial re-use, distribution, and reproduction in any medium, provided the original work is properly cited. For commercial re-use, please contact [journals.permissions@oup.com](mailto:journals.permissions@oup.com)

## Introduction

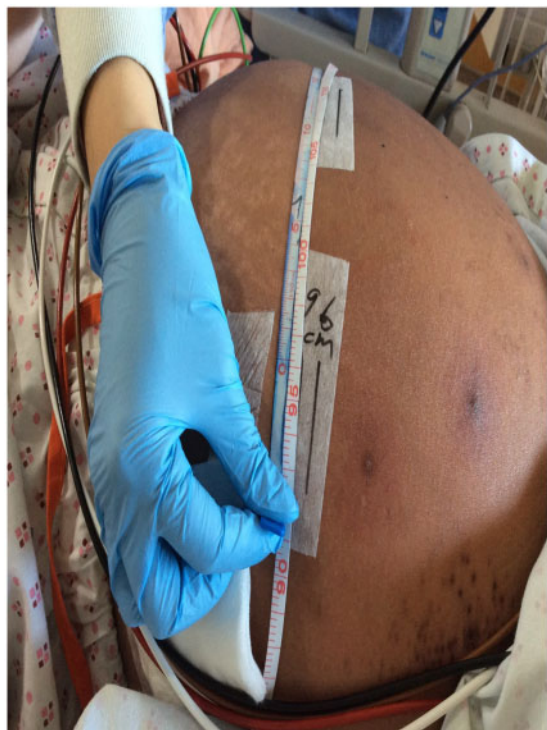Managements of advanced right heart failure in patients with idiopathic pulmonary arterial hypertension (IPAH) typically include the following: inotropic support with intensive care unit monitoring, intravenous (IV) prostacyclin analogues, balloon atrial septostomy (BAS), extracorporeal membrane oxygenation (ECMO), and lung transplantation.<sup>1,2</sup> References and protocols are rare for dose titrations and transitions between subcutaneous and IV prostacyclin in functional Class IV IPAH patients.<sup>3,4</sup> Balloon atrial septostomy is rarely done, and if so, only in very few expert centres.<sup>5</sup> Herein, we reported a young lady with IPAH and advanced right heart failure presenting with massive ascites, oliguria, and hypotension. Her conditions were successfully managed with a switch of administrating prostacyclin analogue from the subcutaneous to the IV route and BAS guided by intracardiac echocardiography (ICE).

## Timeline

Time	Events
1st index event (December 2018) admission	Ascites drainage at emergency room (ER)
1st index admission Day 1	Hypotension, use of intravenous (IV) inotropics at cardiac care unit (CCU)
1st index admission Day 3, 10:00 a.m.	Ascites drainage
1st index admission Day 3, 06:30 p.m.	Converted the treprostinil from the sc. to the IV route, instant direct 1:1 dosage and route conversion produced a profound hypotension and drowsy consciousness
1st index admission Day 8	Performed 1st session of balloon atrial septostomy (BAS)
1st index admission Days 10–11	Transitions from IV to sc. treprostinil injection in aliquots
6 months after the 1st index event, 2nd index admission (June 2019) Days 1–3	Ascites drainage, transitions from sc. to IV treprostinil
2nd index admission Day 5	Performed 2nd session of BAS
2nd index admission Days 8–10	Transitions from IV to sc. treprostinil injection
7 months after 1st index event, 3rd index admission (July 2019)	
3rd index admission Day 8	3rd session of BAS
8 months after 1st index event, 4th index admission (August 2019)	
4th index admission, Day 2	Peripherally inserted central catheter line inserted
Days 2–4	Permanent transitions from sc. to IV treprostinil injection
1 year after 1st index event (December 2019)	Alive, with functional Class III symptoms

## Case presentation

A 43-year-old lady with IPAH had received maximal target medication including oral phosphodiesterase Type 5 inhibitor, endothelin receptor blocker, and subcutaneous prostacyclin analogue (treprostinil) injection. The patient did not have remarkable past medical history except IPAH. In June 2018, she had high-risk warning signs including mean right atrium (RA) pressure of 21 mmHg and NT-pro brain natriuretic peptide (BNP) of 1930 pg/mL and started receiving subcutaneous treprostinil injection (with dosages gradually titrated up to 90 ng/kg/min). Though on maximal medical treatment, she had worsening right heart failure with massive ascites (*Figure 1*), peripheral oedema, oliguria, and hypotension and was admitted in December 2018 (1st index admission). Upon admission, her systolic blood pressure was 85 mmHg, pulse rate 105 b.p.m., pulse oximetry 88% in room air, and urine output 250 mL/12 h. Physical examination revealed a jugular venous giant V wave with estimated pressure of more than 25 cmH<sub>2</sub>O and a grade II pansystolic murmur and a palpable heave at left lower sternal border. Laboratory data showed mild jaundice with total bilirubin of 1.4 mg/dL, hypokalaemia of 2.9 mEq/L, and elevated NT-pro BNP of 4157 pg/mL. She received ascites drainage of 2500 mL in two sessions. Transthoracic echocardiogram revealed marked dilated RA, right ventricle (RV), and small and compressed left atrium (LA), left ventricle (LV) (*Figure 2A*). To improve subcutaneous absorption of treprostinil, the site of injection site was moved from the ascites-distended abdomen to her arm. On the 3rd day of admission, we converted the treprostinil administration from the subcutaneous to the IV route; however, the instant direct 1:1 dosage and route conversion produced a profound hypotension (systolic blood pressure 60 mmHg) and drowsy consciousness. After reducing the IV treprostinil dosage from 90 to 65 ng/kg/min and upscaling the IV inotropic, her blood pressure stabilized, and consciousness regained within 2 h. On the 4th and 7th days of admission, we titrated up IV treprostinil in steps from 65 to 82 ng/kg/min. On the 8th day of admission, we performed standard right and left heart catheterization via bilateral femoral vessels. An ICE catheter (AcuNac catheter, Siemens, Mountain View, CA, USA) was introduced via the left femoral vein into RA and the image was displayed on an ACUSON SC 2000 System (Siemens). Using real-time ICE guidance, the inter-atrial septum and fossa ovalis could be visualized clearly (*Supplementary material online, Video S1*). We used a transseptal Brockenbrough needle and a Mullins sheath (Medtronic, Minneapolis, MN, USA) to probe the inter-atrial septum (*Supplementary material online, Video S2*) and enter the LA cavity. Then, the atrial septum was dilated with a 5 mm × 8 cm Mustang balloon (Boston Scientific, Marlborough, MA, USA) (*Figure 2B*) under ICE guidance (*Figure 2C* and *Supplementary material online, Video S3*). Inter-atrial shunting from right to left was established (*Figure 2D*) with a consequence of a successful drop in mean RA pressure from 19 to 12 mmHg, and an increase of systemic cardiac output from 2.5 to 3.8 L/min (*Table 1*). Urine output increased, ascites relieved, and dyspnoea improved day by day. Finally, before hospital discharge, the patient requested shifting the IV treprostinil to subcutaneous route for easier self-care at home. This time, we used 10 ng/kg/min aliquots shifts at 2 h intervals and spent 2 days to change back to



**Figure 1** The young lady with idiopathic pulmonary arterial hypertension had advanced right heart failure with massive ascites and distended abdomen.

subcutaneous route without haemodynamic changes. In total, the patient removed 10 kg of fluid and reduced 20 cm of abdominal girth at the time of discharge. She was registered as a candidate for lung transplant 2 months later. However, she had clinical worsening presenting with an increase of ascites with distended abdomen again 6 months after the 1st index event. Transthoracic echocardiogram revealed patency of the right to left inter-atrial shunt but decrease in the atrial septostomy size to 0.4 cm in diameter. Again, we used 10 ng/kg/min aliquots shifts at 3 h intervals and spent 3 days to change the treprostinil from subcutaneous to IV route without haemodynamic changes. Then, we did 2nd session of BAS with a 6 mm balloon and reduced the mean RA pressure from 16 to 13 mmHg and arterial oximetry from 90% to 87%. She was discharged uneventfully after reducing 3 kg of extra fluid and 6 cm of abdominal girth. The 3rd session of BAS with a 7 mm balloon was done 1 month later. Moreover, we permanently transitioned the subcutaneous treprostinil to IV route via a peripherally inserted central catheter (PICC) 1 month after finishing three sessions of BAS. She is still alive with functional Class III symptoms 1 year after the 1st index event (December 2019).

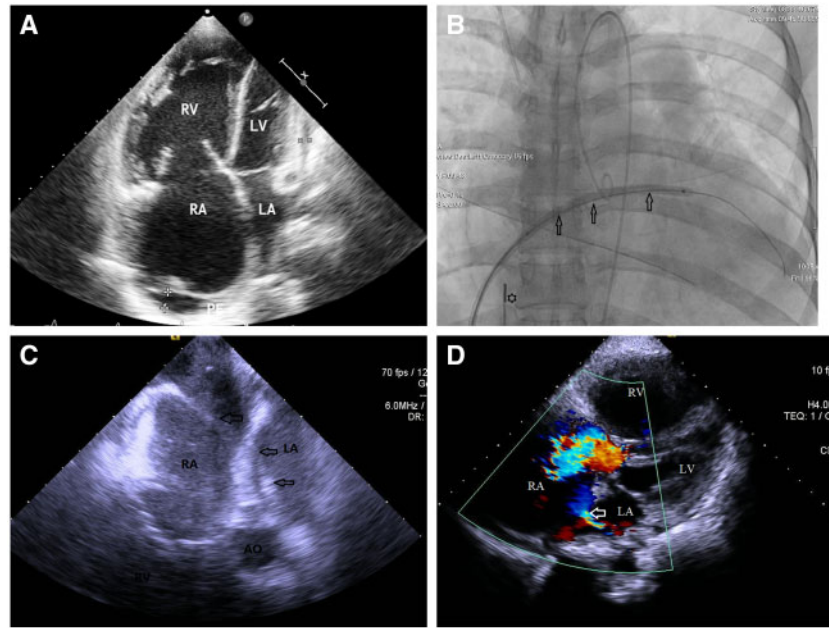
## Discussion

Managing the advanced right heart failure in patients with IPAH includes inotropic support, parenteral prostacyclin analogues, BAS,

ECMO, and lung transplantation; nevertheless, the reported mortality rate remains >40%.<sup>1,2</sup> Our patient presented with massive ascites, hypotension, oliguria, all of which predicted a poor prognosis. We successfully stabilized the patient by switching the administration of prostacyclin analogues from the subcutaneous to the IV route, up-titrating the dosages, and later performed the BAS to de-compress the RA/RV, increase preload to LV, and increase systemic cardiac output and oxygen delivery.

Balloon atrial septostomy is rarely performed nowadays and is done only in a few expert centres. Technical and safety issues are the major concern. We carried out the transseptal puncture guided under ICE, which allowed visualizing the inter-atrial septum clearly (Figure 2C and Supplementary material online, Videos S1–S3) and avoided intubation.<sup>5</sup> Our patient had a baseline mean RA pressure of 19 mmHg and pulse oximetry of 88% at room air. The conditions were close to the tolerable threshold for creating a right-to-left atrial shunt.<sup>6</sup> Therefore, we chose a more conservative approach using a 5 mm balloon dilatation, which successfully decreased her mean RA pressure from 19 to 12 mmHg, and increased her systemic cardiac output from 2.5 to 3.8 L/min (Table 1). Based on this and our previous case experiences, the palliative effect of creating a right to left inter-atrial shunting in IPAH patients with advanced right heart failure was limited to ~6 months.<sup>5</sup> Repeated BAS is helpful once clinical deterioration recurs but registry for lung transplant candidate is a mandate.

There were very few protocols and references for dose titrations of prostacyclin analogues and their transitions from subcutaneous to IV route in functional Class IV IPAH patients.<sup>3,4</sup> Alkukhun *et al.*<sup>3</sup> reported safe transitions from subcutaneous to IV treprostinil with a mean dosing down-adjusted for 14 ng/kg/min and a median transition duration of 42 h. Moreover, there was no study proving that transition from subcutaneous to IV treprostinil is helpful in IPAH patients with advanced right heart failure. We only extrapolated from the clinical proven survival benefit of IV epoprostenol infusion in functional Class IV IPAH patients.<sup>7</sup> The only equal bioavailability data of subcutaneous and IV treprostinil was at a very low dosage of 10 ng/kg/min conducted in healthy volunteers.<sup>8</sup> Another assumption is that subcutaneous absorption of treprostinil will be decreased due to peripheral vascular constriction and poor tissue perfusion in advanced heart failure status. Our initial transition approach was an instant and direct 1:1 dosage conversion, which led to a profound hypotension and drowsy consciousness. It implies that the bioavailability is higher via the IV than the subcutaneous route at the same treprostinil dosage in this critically ill IPAH patient. After reducing the IV dose of treprostinil and increasing inotropics, her consciousness returned clear and blood pressure stabilized within 2 h. Conversion back to subcutaneous route before discharging from hospital was at the request of the patient for easier access site care at home. Moreover, a long-term indwelling catheter increased chances of systemic infection especially in humid weather at a tropical country. It is difficult to indefinitely administer a very short half-life, temperature-sensitive prostacyclin analogue such as epoprostenol in a tropical country. Therefore, we compromised by using a PICC to deliver the IV treprostinil in the long run.



**Figure 2** (A) Baseline transthoracic echocardiogram showing a markedly dilated right atrium and right ventricle and compressed left atrium and left ventricle. (B) Balloon atrial septostomy was performed with a 5 mm × 8 cm balloon dilating the inter-atrial septum. Arrows: balloon inflation and spanning across the inter-atrial septum. \*Intracardiac echocardiogram catheter. (C) Intracardiac echocardiogram showing the balloon inflation and spanning across the inter-atrial septum. Arrows: balloon spanning across the inter-atrial septum. (D) Post-balloon atrial septostomy, the transthoracic echocardiogram showing a right to left shunting at the inter-atrial septum level. Arrow: right to left shunting at the inter-atrial septum. AO, aorta; LA, left atrium; LV, left ventricle; RA, right atrium; RV, right ventricle.

**Table 1** Haemodynamic data before and after 1st balloon atrial septostomy

	Baseline	Post-BAS
Arterial O <sub>2</sub> saturation (%) in room air	88%	85%
PA pressure (mean, mmHg)	55	53
PVR (WU)	19	16
Systemic cardiac output (L/min)	2.5	3.8
Qp/Qs	1	0.68
RA pressure (mean, mmHg)	19	12
LVEDP (mmHg)	10	12

BAS, balloon atrial septostomy; LVEDP, left ventricle end-diastolic pressure; PA, pulmonary artery; PVR, pulmonary vascular resistance; Qp, pulmonary blood flow; Qs, systemic blood flow; RA, right atrium.

## Conclusion

Balloon atrial septostomy is effective in stabilizing the critical and advanced right heart failure in IPAH patients but should be intended as a bridge to lung transplant only procedure. Repeated BAS is helpful once clinical deterioration recurs in the waiting period before

transplant. Transition from subcutaneous to IV prostacyclin is helpful but needs to be titrated in proper aliquots and time intervals to avoid abrupt haemodynamic changes.

## Lead author biography



Dr Kuo-Yang Wang, MD, is a graduate of National Defense Medical College in Taiwan and received his post-doctoral fellowship at University of Pennsylvania. Dr Wang received his Cardiology training in 1980s and continuously served in Taichung Veterans General Hospital till 2018, where he set up a Pulmonary Hypertension Center and cared many pulmonary hypertension patients, including primary and secondary causes. He now moves

to China Medical University Hospital, Taichung, where he leads the Center for Pulmonary Hypertension and Pulmonary Vascular Disease and continuously takes care of pulmonary hypertension patients.

## Supplementary material

Supplementary material is available at *European Heart Journal - Case Reports* online.

**Slide sets:** A fully edited slide set detailing this case and suitable for local presentation is available online as [Supplementary data](#).

**Consent:** The author/s confirm that written consent for submission and publication of this case report including image(s) and associated text has been obtained from the patient in line with COPE guidance.

**Conflict of interest:** none declared.

## References

- Galie N, Humbert M, Vachiery JL, Gibbs S, Lang I, Torbicki A, Simonneau G, Peacock A, Vonk Noordegraaf A, Beghetti M, Ghofrani A, Gomez Sanchez MA, Hansmann G, Klepetko W, Lancellotti P, Matucci M, McDonagh T, Pierard LA, Trindade PT, Zompatori M, Hoeper M. 2015 ESC/ERS Guidelines for the diagnosis and treatment of pulmonary hypertension: the Joint Task Force for the Diagnosis and Treatment of Pulmonary Hypertension of the European Society of Cardiology (ESC) and the European Respiratory Society (ERS): Endorsed by Association for European Paediatric and Congenital Cardiology (AEPC), International Society for Heart and Lung Transplantation (ISHLT). *Eur Heart J* 2016;**37**:67–119.
- Hoeper MM, Benza RL, Corris P, de Perrot M, Fadel E, Keogh AM, Kuhn C, Savale L, Klepetko W. Intensive care, right ventricular support and lung transplantation in patients with pulmonary hypertension. *Eur Respir J* 2019;**53**:1801906.
- Alkukhun L, Bair ND, Dweik RA, Tonelli AR. Subcutaneous to intravenous prostacyclin analog transition in pulmonary hypertension. *J Cardiovasc Pharmacol* 2014;**63**:4–8.
- Sofer A, Ryan MJ, Tedford RJ, Wirth JA, Fares WH. A systematic review of transition studies of pulmonary arterial hypertension specific medications. *Pulm Circ* 2017;**7**:326–338.
- Chen YW, Pan HC, Wang KY, Liang KW. Consecutive sessions of rescue balloon atrial septostomy for an idiopathic pulmonary arterial hypertension patient with refractory right heart failure—usefulness of intracardiac echocardiography guidance. *Acta Cardiol Sin* 2017;**33**:310–314.
- Sandoval J, Rothman A, Pulido T. Atrial septostomy for pulmonary hypertension. *Clin Chest Med* 2001;**22**:547–560.
- McLaughlin VV, Shillington A, Rich S. Survival in primary pulmonary hypertension: the impact of epoprostenol therapy. *Circulation* 2002;**106**:1477–1482.
- Laliberte K, Arneson C, Jeffs R, Hunt T, Wade M. Pharmacokinetics and steady-state bioequivalence of treprostinil sodium (Remodulin) administered by the intravenous and subcutaneous route to normal volunteers. *J Cardiovasc Pharmacol* 2004;**44**:209–214.